

# Initial COVID Hydroxychloroquine Failure Responds to Interferon and Tocilizumab.

Richard M Fleming, PhD, MD, JD (✉ [DrRichardMFleming@gmail.com](mailto:DrRichardMFleming@gmail.com))

FHHI-OI-Camelot <https://orcid.org/0000-0001-9964-1518>

Matthew R Fleming, BS, BA, NRP

FHHI-OI-Camelot <https://orcid.org/0000-0002-9974-0468>

---

## Case Report

**Keywords:** SARS-CoV-2, CoVid-19, FMTVDM, Ferritin, IL-6, NCT04349410

**Posted Date:** October 30th, 2020

**DOI:** <https://doi.org/10.21203/rs.3.rs-98569/v1>

**License:**   This work is licensed under a Creative Commons Attribution 4.0 International License.

[Read Full License](#)

---

# Abstract

Currently there is no established treatment protocol for SARS-2 (CoVid-19). Proponents of hydroxychloroquine (HCQ) argue that early intervention may sufficiently prevent replication of the virus and avoid the need for hospitalization. In instances where viral replication continues and the patient develops CoViD pneumonia (CVP), such patients – particularly with comorbidities – are prone to develop an InflammoThrombotic response similar to cytokine release syndrome (CRS). We present one such patient who failed HCQ treatment and was subsequently treated successfully with an interleukin-6 inhibitor and interferon.

## Clinical Case

A 73-year old obese (170 cm, 95.4 kg) Cuban male (E.G.) developed fatigue, hyposmia, and dyspnea. He was not aware of any exposure to individuals with CoVid-19. His medical history revealed no other comorbidities other than his age and weight. He was taking no medications. A nasal swab for PCR was obtained and he was started on hydroxchloroquine (HCQ) 200 mg po BID along with 50 mg po elemental zinc daily.

He returned 4-days later with worsening dyspnea and was admitted following FMTVDM [1] imaging to evaluate the severity of corona virus pneumonia (CVP) inflammation. The initial quantification revealed two specific areas in the right lung fields (Figure 1) where an inflammatory response was present.

Following measurements, he was admitted and started on Tocilizumab 762.2 mg IV repeated one time 8-hours later (Treatment arm 7), Interferon alpha-2b 5 million units per nebulizer BID (Treatment arm 9), Atrovent nebulizer treatments q 4-hours, and SQ heparin 5000 Unit q 12-hours per NCT04349410. The patient was initially positioned in the prone position with O2 monitoring.

His initial IL-6 level was 16 pg/ml [2], and ferritin 379 ng/ml, with a normal range fibrinogen level.

During the first 48-hours he reported improvement in breathing and was repositioned to a supine position.

Following 72-hours of treatment he underwent repeat FMTVDM (Figure 1) imaging which showed improvement in CVP inflammation, matching his improved symptoms, and follow up blood tests including an IL-6 of 10 pg/ml and ferritin of 224 ng/ml. The initial PCR test for SARS-2 returned positive.

The patient continued to improve and was discharged on the 8<sup>th</sup> day post admission.

## Discussion

SARS-2 attaches to human cells through a variety of receptors including ACE-2. Respiratory cells are particularly vulnerable and evidence indicates that sufficient viral replication has occurred within 96-hours to become clinically significant [3].

HCQ proponents have argued that initiation of HCQ must begin immediately once the clinician thinks the patient has SARS-2. Arguably treatment may have been started too late for HCQ to provide clinical benefit or the patient might have benefitted from a combination of HCQ and interferon in the prehospital setting [4].

Viruses including SARS-2 are one of many factors involved in InflammoThrombotic reactions produced by the immune system [5] resulting in inflammation and blood clots [6] that have proven to be associated with deaths in SARS-2 patients.

Measurement of this InflammoThrombotic response [1] makes it possible to determine treatment response in SARS-2 patients. In this instance, the patient was evaluated and admitted for treatment following failure of HCQ. This treatment consisted of prone positioning, use of beta-2 bronchodilator nebulizer treatment, administration of low dose heparin to reduce the potential formation of thrombi, and the initiation of both interferon (IFN) and interleukin-6 inhibitor (IL6-I) treatments.

Treatment with IFN is common in Cuba and when combined with an IL6-I appears to be promising. Currently only 100 deaths from CoVid have been reported in Cuba and this may represent the benefit of using IFN and IL6-I's. While this represents only one such case example, it emphasizes the importance of objectively evaluating CoVid-19 patients and initiating treatment intervention early.

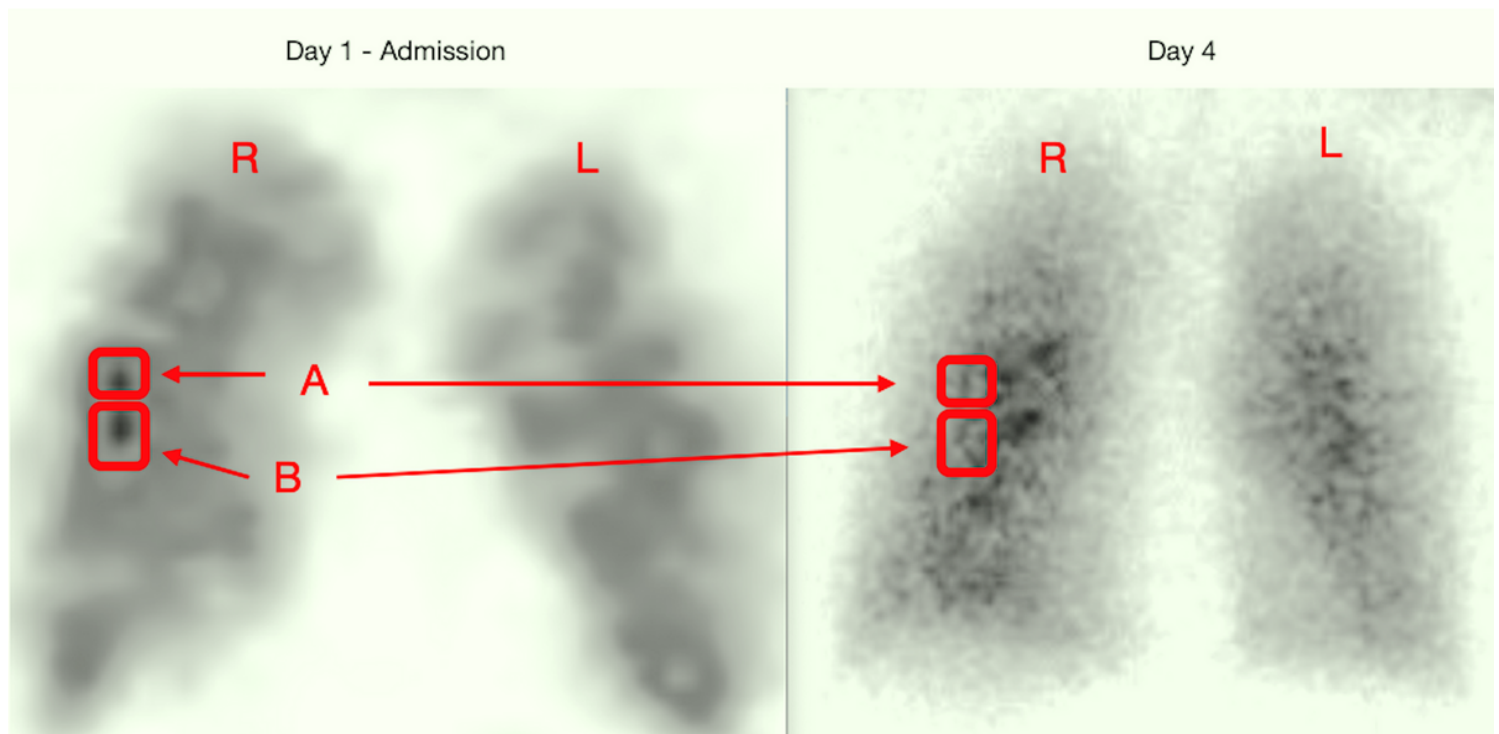
## Declarations

Acknowledgement: FMTVDM patent was issued to author and made available free of cost to participating NCT04349410 sites. The reproduction of this figure is authorized by first author.

## References

1. The Fleming Method for Tissue and Vascular Differentiation and Metabolism (FMTVDM) using same state single or sequential quantification comparisons. Patent Number 9566037. Issued 02/14/2017 <https://patents.google.com/patent/US9566037B2/en>
2. Zhang C, Wu Z, Li J-W, Zhao H, Wang G-Q. Cytokine release syndrome in severe COVID-19: interleukin-6 receptor antagonist tocilizumab may be the key to reduce mortality. International Journal of Antimicrobial Agents 2020. DOI:10.1016/ijantmicag.2020.105954.
3. Sacks CA. SARS-CoV-2 Infection of Airway Cells. N Engl J Med 2020;383(10):969.
4. Yang A, Yang C, Yang B. Use of hydroxychloroquine and interferon alpha-2b for the prophylaxis of COVID-19. Medical Hypothesis. org/10.1016/j.mehy.2020.109802
5. Fleming RM. Chapter 64. The Pathogenesis of Vascular Disease. Textbook of Angiology. John C. Chang Editor, Springer-Verlag New York, NY. 1999, pp. 787-798. doi:10.1007/978-1-4612-1190-7\_64.
6. Wichmann D, Sperhake J-P, Lütgehetmann M, et al. Autopsy Findings and Venous Thromboembolism in Patients With COVID-19. A Prospective Cohort Study. Annals of Internal Medicine 2020. 6 May 2020. DOI: 10.7326/M20-2003.

## Figures



**Figure 1**

Measurement of SARS-2 Pneumonia (CVP) Inflammation. Legend: Initial CVP in the right lung measured 170 in region A and 180 in region B. After 72-hours of treatment, improvement was seen with

measurements of 125 for region A and 128 in region B. The right (R) and left (L) lung fields are marked accordingly.

## Supplementary Files

This is a list of supplementary files associated with this preprint. Click to download.

- [IRBConsentForm.pdf](#)