

Sagittal Surgical Resection for Treatment of Rib Tumors Involving Vertebral Bodies

Bin Liu

Tumor Hospital of Guangxi Medical University

Zhenchao Yuan (✉ ZhenchaoYuan2018@yeah.net)

Tumor Hospital of Guangxi Medical University

Technical innovations

Keywords: rib tumors, sagittal surgical resection, recurrence, complication

Posted Date: October 23rd, 2020

DOI: <https://doi.org/10.21203/rs.3.rs-94551/v1>

License:   This work is licensed under a Creative Commons Attribution 4.0 International License. [Read Full License](#)

Abstract

Purpose: The purpose of this study was to review recent clinical cases of patients treated in our care center who underwent a sagittal resection for rib tumors involving vertebral bodies, and to explore the local control after operation and related complications.

Methods: We retrospectively reviewed the hospitalization and post-operative follow-up records for all patients treated for rib tumors involving vertebral bodies in our center.

Results: Sagittal surgical resection was conducted in 5 patients aged 34–65 years. Two patients had primary rib tumors and three had metastases at this site. Sagittal surgical resection was achieved in all cases by the removal of two to three affected ribs and associated vertebrae. There were no instances of perioperative mortality. Major complications occurred in 3 of 5 patients after this sagittal surgical resection, including 1 case of postoperative hemorrhage, 1 case of cerebrospinal fluid leakage, and 1 case of hardware failure.

Conclusion: The sagittal resection procedure is a helpful means of preventing the local recurrence of rib tumors, however the surgery has a high rate of complications and thus it is important to fully assess indications on an individual patient basis.

Background

Rib tumors involving the thoracic vertebral bodies are locally aggressive tumors with a high rate of recurrence. It is therefore of particular importance that an appropriate surgical approach be used to correctly establish the tumor margins. Recent decades have yielded remarkable advances in the treatment of spinal tumors. Total en bloc spondylectomy (TES) has been performed worldwide since the early 1980s, markedly reducing the risk of local recurrence in patients with spinal tumors[1–3]. According to WBB (Weinstein-Boriani-Biagini) staging, a sagittal surgical resection operation is recommended for all rib tumors with spinal involvement. Sagittal surgical resection for rib tumors involving the thoracic vertebrae is an aggressive surgical technique in which both the tumor and one or multiple affected vertebral bodies are removed in order to achieve a negative margin. Beyond the application of this approach for treating locally aggressive tumors and metastatic tumor, the main indication for its use is as a means of treating primary malignant tumors. This surgical strategy is often associated with major complications in the early or late postoperative periods. The goal of this study was to review and share our experiences with the sagittal surgical resection technique for treating rib tumors involving the thoracic vertebral bodies, and to report our short-term results.

Patients And Methods

Between January 2016 and October 2018, five patients with primary or secondary multi-level rib tumors involving the thoracic vertebral bodies underwent sagittal surgical resection and subsequent reconstructive surgery in our center. All the patients were available for follow-up. Institutional Review Board approval was obtained for this study, and all patients provided appropriate informed consent. Study inclusion criteria were as follows: (1) primary rib tumor involving the thoracic vertebral bodies; (2) solitary metastatic lesions in carefully selected patients; (3) involvement of one or multiple thoracic vertebral bodies. The exclusion criteria were as follows: (1) multiple organ metastases; (2) invasion of adjacent visceral organs; (3) inability to safely tolerate the operation.

Surgical technique

The sagittal surgical resection was performed according to standard operation protocols. The main procedures are as follows: first, the en bloc removal of the rib tumor, posterior vertebral elements (spinous process, laminae), and the anterior portion was performed via a single posterior-lateral approach followed by mechanical stabilization of the site

with screws and posteriorly-positioned rods, as well as fusion with a bone graft. Adjuvant chemotherapy treatment was carried out if necessary after operation.

Operative risks

Sagittal surgical resection is an aggressive procedure that requires the extensive dissection of the ribs and partial thoracic vertebral bodies. The main risks of the operation are:

- In order to ensure complete tumor resection, any involved pleura should be removed which may result in postoperative local pulmonary adhesion.
- During the resection procedure, it is necessary to ligate the affected and adjacent segmental vessels in order to prevent injury to the thoracic aorta and the inferior vena cava during the operation.
- During the resection procedure, intercostal nerves involved in the tumor must be ligated in order to prevent nerve dysfunction caused by excessive traction of the spinal cord.
- It is necessary to remove the pedicle of vertebral lamina and one side of the vertebral arch during this sagittal surgery, so that the ventral blood vessels of the spinal cord can be fully exposed, and local coagulation is needed to prevent shock induced by low blood volume both during and after the operation.
- It is recommended that this surgical sagittal resection procedure be conducted using a combination of blunt and sharp incisions using different thickness bone knives in order to prevent hemorrhage caused by damage to the thoracic aorta and inferior vena cava.
- In this study, less than 1/3 of each vertebral body was excised, and anterior column reconstruction was not performed. Part of the column structure was retained, with posterior column reconstruction being performed via rod fixation and adjacent vertebral bodies stabilized via bone graft fusion. This approach is important, and bone graft range must be maintained in order to prevent fixation hardware failure.

Results

The age range of the 3 males and 2 females included in this study was 34–65 years. Two patients had primary rib tumors while the remaining three had metastatic rib tumors. The rib tumor was located at the (left or right) eleventh rib in two patients, at the left third and fourth ribs in one patient, and at the right thoracic level in six or ten. Surgery was performed via a posterior approach-assisted lateral approach. Sagittal surgical resection was successfully achieved in all cases. The only major complication during surgery was a hemorrhage caused by segmental vascular avulsion in one patient, and this improved after symptomatic blood transfusion. One other patient experienced cerebrospinal fluid leakage after surgery that required surgical revision. One patient experienced a later complication of hardware failure leading to scoliosis. The recurrence of local lesions was not observed within the follow-up period of this study [Table 1].

Table 1
Patient characteristics

Patient No.	Age(year)/ Gender	Tumor type	location	Treatment	Complication	Follow-up(months)	Local recurrence
1	58/Female	B-cell lymphoma	Left-eleventh	Surgery + Chemotherapy	Hardware fixation failed	18	No
2	65/Female	chondrosarcoma	Left-Third and Fourth	Surgery	postoperative bleeding	30	No
3	50/Male	chondrosarcoma	Right eleventh	Surgery	None	25	No
4	43/Male	rectal adenocarcinoma	Right-Sixth	Surgery + Chemotherapy	Cerebrospinal fluid Leakage	28	No
5	34/Male	undifferentiated sarcoma	Right-Tenth	Surgery + Chemotherapy	None	24	No

Case Presentation

A 50 year old man suffered from low back pain radiating to the right lower abdomen for 6 months before admission. Neurological examination was normal. Computed tomography

(CT) and magnetic resonance imaging (MRI) of the thoracic spine revealed right rib invading thoracic spine T11 and the thoracic rib joint, with no invasion of the surrounding large vessels or spinal cord [Figure 1]. CT-guided biopsy revealed the presence of a chondrosarcoma. Pathological biopsy suggested that the tumor was insensitive to both radiotherapy and chemotherapy. The resection operation was performed via the posterior approach-assisted lateral approach: the laminae and facets were removed bilaterally as one unit, the nerve roots at T10, T11, and T12 were cut unilaterally, we dissected the tumor from the blood vessels, and made cuts through T9-T10 and the L2-L3 partial disks. The lateral aspects of the T10-T12 vertebral bodies were then released, and the rib tumor with the involved vertebra was removed en bloc without violation of the tumor. Stabilization was achieved using transpedicular screws from T9 through L1 combined with a posterior lateral bone graft fusion of the vertebral body [Figure 2]. No postoperative complications occurred within 1 week of the operation. At last visit, 25 months after surgery, CT scans showed no evidence of tumor recurrence, and fixation hardware appeared to be appropriately positioned.

Discussion

Rib tumors invading the spine were previously considered to be a significant challenge for surgical treatment due to their high rate of recurrence. However, with the development of spinal instrumentation and surgical techniques, there have been several reports of successful en bloc resection of rib tumors invading local vertebrae, resulting in a lower recurrence rate and facilitating the long-term survival of patients[4]. Based on these previous reports, our center has begun performing sagittal surgical resection as a means of treating primary rib tumors or secondary rib metastases involving thoracic rib, with the present report intended to share our findings.

Sagittal surgical resection is a margin-based or extensive resection strategy in which whole tumors undergo resection. The present study specifically focused on cases with rib invasion of the thoracic and rib joints, but without anterior large vessel involvement. According to the WBB surgical staging system for primary bone tumors of the spine, when a tumor occupies zones 2–5 or 8–11, a sagittal resection should be performed (provided at least one zone is free of the tumor)[5]. Tomita has pointed out that TES surgery is suitable for cases of Tomita Types 3, 4, or 5 and Tomita scores of 2, or 3,

while those of Tomita types 1, 2 and 6 were considered relative indications. Those of Tomita Type 7, as well as patients who cannot tolerate surgery, were considered to be contraindications for surgery[2, 6]. Combining these two surgical staging systems, we employed a multi-segmental vertebral sagittal resection approach to remove 1/3 of the vertebral body involved by a given rib tumor while retaining the remaining 2/3 of the vertebral body in order to maintain the stability of the anterior column of this vertebral body. In this study there were no instances of recurrence, with a median time to follow-up of 25.2 months. Local control in these 5 patients was therefore considered to be good after operation. These findings therefore provide evidence that this surgical approach may be appropriate and effective not only for primary rib tumors invading the spine, but also for metastatic rib tumors with spinal involvement. Sagittal surgical resection is not a formal contraindication for metastatic rib tumors invading the spine, as this approach can be conducted safely and effectively, allowing for effective local control of both locally advanced and metastatic rib tumors despite the high risk of operative mortality.

Generally speaking, the sagittal surgical resection procedure necessitates either multiple surgical approaches or a widely enlarged single posterior approach. Successful complete tumor resection necessitates extra-compartmental tumors resection according to the Enneking surgical staging system, and as a result this excision process inevitably involves important anatomical structures around the vertebral body, with a high probability of damage to important surrounding structures. Postoperative complications in patients can include chest wall paralysis, respiratory disorders, lower limb dysfunction, cerebrospinal fluid leakage, and long-term complications such as hardware fixation failure and vertebral disc degeneration. The incidence of complications has been reported to be as high as 40% following one-stage TES[7, 8]. Hence, a precise understanding of the morbidity associated with this operation is of great importance given this high complication rate. Limiting the range of resection as much as possible in a manner consistent the principles of oncology treatment will allow surgeons to reduce these complication rates in patients with rib tumors with thoracic spine involvement.

When treating rib tumors that violate the vertebral body but not the anterior large vessels, a single posterior approach-assisted lateral approach is advantageous as this makes it possible to observe the condition of the spinal cord and the large blood vessels throughout the course of the operation, thus avoiding injury to these structures. It is also important that all aspects of the surgical procedure including the length of spine which must undergo resection be fully evaluated. Studies have confirmed that bilateral segmental arterial ligation of 3 consecutive vertebral nodes can lead to a 25% reduction in blood supply to the spine, although spinal cord function is not affected[9]. The ligation of the bilateral segmental arteries of 4 consecutive vertebral nodes, however, can cause spinal cord ischemia syndrome[10]. The sagittal resection approach can effectively avoid the risk of spinal cord ischemia, as the vertebral blood supply is only ligated on one side of the a given segment. This surgical resection approach removes rib tumors, appropriate soft tissue, the thoracic rib joint, and the partially affected thoracic vertebrae, however 2/3 of the affected vertebral bodies remained following the operation, and the anterior column of vertebral body was not reconstructed after operation. In all cases in the present report, there were no instances of local recurrence, with a wide range of boundary resection for all patients such that all surrounding tissues with possible involvement including the pleura and nerve roots were removed.

The incidence of postoperative complications for this approach remains high, with primary complications including spinal cord nerve injury, cerebrospinal fluid leakage, and late hardware fixation failure. Through a combination of careful operative protocols aimed at minimizing the risk of these major complications and early postoperative positive symptomatic treatment, it is possible to obtain satisfactory results. For hemorrhages of the segmental blood vessels and vertebral vein plexus, segmental vascular ligation with bipolar coagulation hemostasis and gelatin sponge compression hemostasis can be employed, respectively. Injury of spinal cord and nerve root can be caused by exposing the tumor during operation, by cutting the disc, by shaking the vertebral body, or by ligating the segmental vessels. Therefore, it is necessary to avoid excessive pulling of the spinal cord and nerve root when the spinal nerve root is separated from the surrounding tissue in the course of operating[2]. Bandiera and Yokogawa have reported incidence rates of dural rupture of

71% and 8.3% after TES operation[7, 11]. Risk factors for such rupture reportedly include: age \geq 54 years old, preoperative radiotherapy, resection of more than 3 vertebral bodies, and intraoperative dural injury, all of which may increase the likelihood of cerebrospinal fluid leakage after operation. In all cases in the present study, less than 1/3 of each vertebral body was excised, and anterior column reconstruction of the spine was not implemented, with all being fixed by simple posterior segmental fixation. In one case, the patient experienced hardware fixation failure after operation – likely due to vertebral body instability, which increased the stress on the posterior fixation structure leading to hardware fixation failure. For the one patient in the present study that experienced cerebrospinal fluid leakage after surgery, symptoms were improved after symptomatic treatment.

This study has several limitations. For one, the sample size was very small and thus larger future studies with more patients will be essential to validate these findings. In addition, a longer follow-up period is needed to fully assess patient outcomes. Lastly, future studies should compare outcomes for sagittal resection and normal surgical procedures in a systematic manner.

Conclusion

Sagittal surgical resection has become a necessary surgical procedure for treating rib tumors involving the thoracic vertebral bodies. This surgical approach can help to reduce rates of local recurrence, but the high rates of postoperative complications cannot be overlooked. It is therefore important that physicians take a scientific and rational approach to fully considering the indications of this operation, and that the resected area be minimized as much as possible in order to maximize the chances of positive patient outcomes.

Abbreviations

TES: Total en bloc spondylectomy ;WBB :Weinstein-Boriani-Biagini;CT: [Computed tomography](#); MRI: Magnetic resonance imaging

Declarations

Author contributions

Bin Liu conceived the study and drafted the manuscript; Zhenchao Yuan participated in the study design and interpretation. All authors read and approved the final manuscript.

Conflict of interest

The authors declare no conflict of interest related to this study.

Availability of data and materials

The datasets used and/or analyzed during the current study are available from the corresponding author on reasonable request.

Acknowledgments

We would like to thank the patients for their willingness to share their cases for this study.

Ethics approval and consent to participate

This project was approved by the Medical Ethics Committee of Affiliated Tumor Hospital of Guangxi Medical University (2020115024)

Consent for publication

Not applicable.

Funding

This work was supported by the Guangxi Chinese medicine self-funded research project [grant numbers GZZC2020231].

References

1. A.D. Luzzati, S. Shah, F. Gagliano, G. Perrucchini, G. Scotto, M. Alloisio, Multilevel en bloc spondylectomy for tumors of the thoracic and lumbar spine is challenging but rewarding, *Clin Orthop Relat Res* 473(3) (2015) 858-867.
2. N. Kawahara, K. Tomita, H. Murakami, S. Demura, Total en bloc spondylectomy for spinal tumors: surgical techniques and related basic background, *Orthop Clin North Am* 40(1) (2009) 47-63.
3. S. Kato, N. Kawahara, H. Murakami, S. Demura, T. Shirai, H. Tsuchiya, K. Tomita, Multi-level total en bloc spondylectomy for solitary lumbar metastasis of myxoid liposarcoma, *Orthopedics* 33(6) (2010) 446.
4. J. Xiao, S. He, J. Jiao, W. Wan, W. Xu, D. Zhang, W. Liu, N. Zhong, T. Liu, H. Wei, Single-stage multi-level construct design incorporating ribs and chest wall reconstruction after en bloc resection of spinal tumour, *International Orthopaedics* 42(47-63) (2018) 1-7.
5. S. Boriani, J.N. Weinstein, R. Biagini, Primary bone tumors of the spine. Terminology and surgical staging, *Spine* 22(9) (1997) 1036.
6. K. Tomita, N. Kawahara, H. Baba, H. Tsuchiya, T. Fujita, Y. Toribatake, Total en bloc spondylectomy. A new surgical technique for primary malignant vertebral tumors, *Spine (Phila Pa 1976)* 22(3) (1997) 324-33.
7. S. Bandiera, S. Boriani, R. Donthineni, L. Amendola, M. Cappuccio, A. Gasbarrini, Complications of en bloc resections in the spine, *Orthop Clin North Am* 40(1) (2009) 125-31, vii.
8. S. Boriani, A. Gasbarrini, S. Bandiera, R. Ghermandi, R. Lador, Predictors for surgical complications of en bloc resections in the spine: review of 220 cases treated by the same team, *European spine journal : official publication of the European Spine Society, the European Spinal Deformity Society, and the European Section of the Cervical Spine Research Society* 25(12) (2016) 3932-3941.
9. K. Nambu, N. Kawahara, T. Kobayashi, H. Murakami, Y. Ueda, K. Tomita, Interruption of the bilateral segmental arteries at several levels: influence on vertebral blood flow, *Spine* 29(14) (2004) 1530.
10. S. Kato, N. Kawahara, K. Tomita, H. Murakami, S. Demura, Y. Fujimaki, Effects on spinal cord blood flow and neurologic function secondary to interruption of bilateral segmental arteries which supply the artery of Adamkiewicz: an experimental study using a dog model, *Spine Journal* 8(5) (2008) 103S-104S.
11. N. Yokogawa, H. Murakami, S. Demura, S. Kato, K. Yoshioka, H. Hayashi, T. Ishii, T. Igarashi, X. Fang, H. Tsuchiya, Postoperative Cerebrospinal Fluid Leakage Associated With Total En Bloc Spondylectomy, *Orthopedics* 38(7) (2015) e561.

Figures

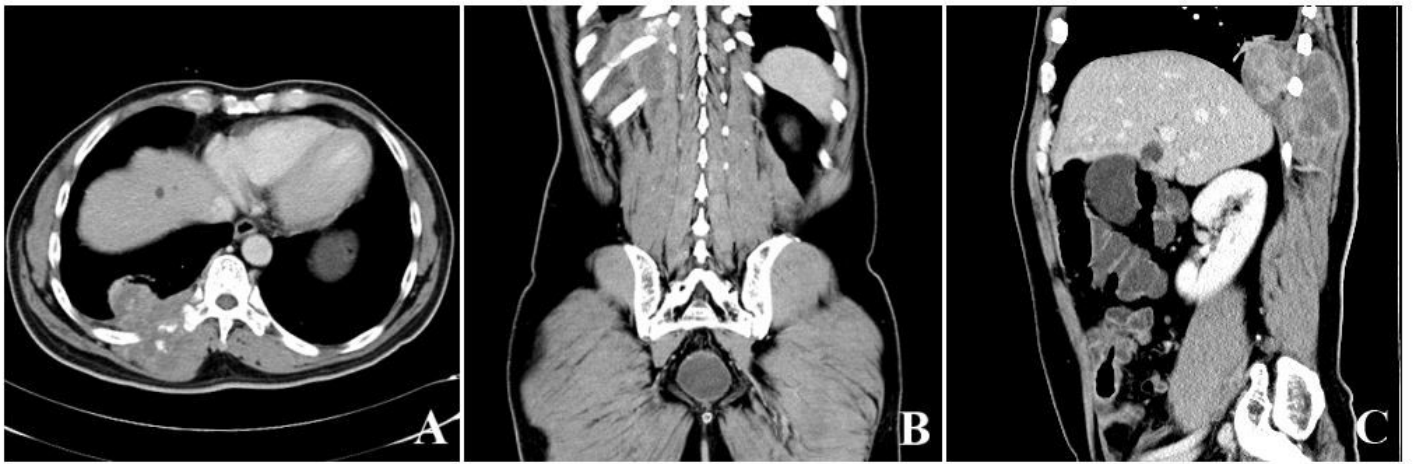

Figure 1

50-year-old male patient affected by right T11 primary rib tumor. Histological diagnosis reported chondrosarcoma. Tumor extension according to WBB staging was 8–11/A–D (A), The range of neoplasia is shown on the CT of the coronal position (B) Tumor boundary range on sagittal CT (C).

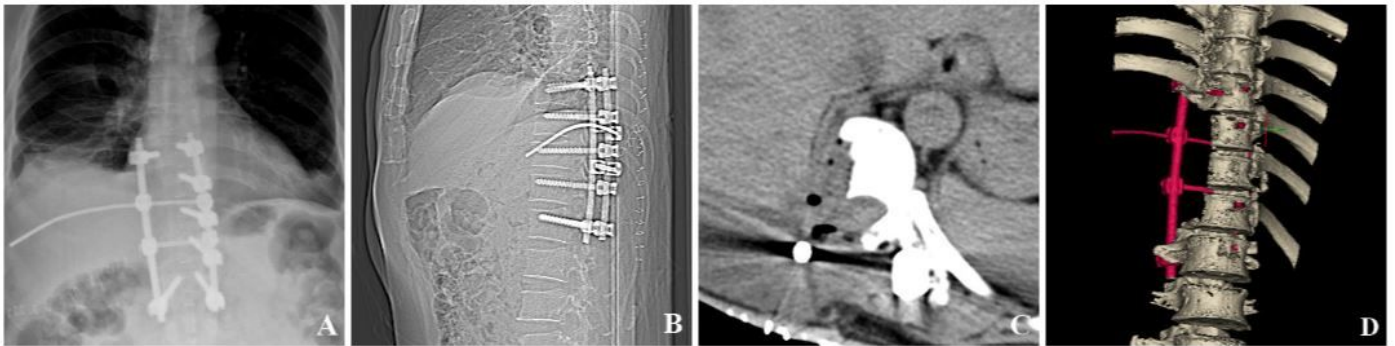


Figure 2

Surgery was performed as single posterior approach assisted lateral approach procedure (A). Post-operative reconstruction of sagittal CT (B). Cross-Sectional CT-scans showing remaining vertebral body using sagittal surgical resection (C). Sagittal surgical resection was performed at the level of disk spaces T9–T10 and T12–L1 (D).