

Assessment of choriocapillary blood flow changes in response to half-dose PDT in chronic central serous chorioretinopathy using OCTA

Juejun Liu

Wuhan University Renmin Hospital

Changzheng Chen (✉ whuchenchzh@163.com)

Lu Li

Wuhan University Renmin Hospital

Yishuang Xu

Wuhan University Renmin Hospital

Zuohuizi Yi

Wuhan University Renmin Hospital

Lu He

Wuhan University Renmin Hospital

Hongmei Zheng

Wuhan University Renmin Hospital

Research article

Keywords: Chronic; Central Serous Chorioretinopathy; Optical Coherence Tomography Angiography; Photodynamic Therapy

Posted Date: January 15th, 2020

DOI: <https://doi.org/10.21203/rs.2.18778/v2>

License: © ⓘ This work is licensed under a Creative Commons Attribution 4.0 International License.
[Read Full License](#)

Version of Record: A version of this preprint was published on October 7th, 2020. See the published version at <https://doi.org/10.1186/s12886-020-01674-9>.

Abstract

Background: To quantify flow changes in choriocapillaris (CC) in patients with chronic central serous chorioretinopathy (CCSC) in the treatment of half-dose photodynamic therapy (PDT) using optical coherence tomography angiography (OCTA). **Methods:** A total of 28 affected eyes and 24 unaffected eyes of 26 CCSC patients receiving half-dose PDT, and 40 eyes of 20 healthy gender- and age-matched subjects were retrospectively enrolled. Proportion of total areas of flow signal voids (FSV, %) in CC level of OCTA were mainly assessments in both eyes of the CCSC patients at baseline and repeated in multiple sections at 1-week, 1-month, 3-month and 6-month intervals after PDT. In addition, CC patterns in response to PDT at early stage and their subsequent morphologic changes were qualitatively documented using OCTA. **Results:** For affected eyes, significant decrease in FSV was found at 6-m follow-up than 1-m follow-up ($p=0.036$). Comparing to normal control eyes, FSV in affected eyes was significantly higher at 1-m, 3-m and 6-m follow-up ($p<0.05$ for all), while FSV in unaffected eyes was significantly higher at baseline, 1-w, 1-m and 3-m follow-up ($p<0.05$ for all). Three CC patterns of early response to PDT can be identified, including signs of recovery with more even flow signals, transient appearance of worsen ischemia and secondary neovascularization within CC level. **Conclusion:** Abnormal CC flow attenuation remained in completely resolved eyes of CCSC patients treated with half-dose PDT. **Key Words:** Chronic; Central Serous Chorioretinopathy; Optical Coherence Tomography Angiography; Photodynamic Therapy

Background

With advances in fundus imaging technology, the potential mechanism of choroidal hemodynamic changes in CSC has been gradually understood in studies applying ICGA and EDI-OCT¹. Choriocapillaris (CC) ischemia processes, along with increased hydrostatic pressure from choroidal pachyvessels, could result in focal or defused RPE barrier breakdown and subsequent SRD¹⁻³. It has been well documented that PDT, with modified parameters, has a long-term efficacy and safety profile in chronic CSC (CCSC), with less complications and more favorable vision improvement and anatomic resolution of subretinal fluid (SRF) and subfoveal choroidal thickness (SFCT)^{1,4}. As suggested by previous pathological researches and angiographic studies, PDT was presumed to cause short-term CC hypoperfusion and long-term choroidal vascular remodeling in the treatment of CSC⁵. Assessment of CC *in vivo* could be valuable in understanding the pathological mechanism of CSC and the therapeutic effects of PDT^{6,7}.

Optical coherence tomography angiography (OCTA) is a principally new imaging technique that provides new insights into CC perfusion and vasculature patterns over the selected layers free from dye injection, which hugely compensates for the deficiency of OCT and ICGA in the observation of CC^{7,8}. Several OCTA-related studies have reported irregular flow patterns of CC in patients with CSC, including CC dilatation with increased flow signal^{9,10}, and focal or defused dark areas with flow signal void (FSV)^{7,9}, which were associated with the changes in ICGA. Various binary quantifications of OCTA imaging with objective data on various parameters have further confirmed these conclusions of CC attenuation in CSC^{8,11,12}.

Previously, we have qualitatively documented that 97% (32/33) of eyes diagnosed with CCSC return to exhibiting relatively normal distribution of fine particles in CC layer of OCTA at 3-month follow-up after half-dose PDT¹³. And Nassisi M, et, al. has reported that CC vessel density at 1-month follow-up was even higher than baseline value using an alternative binary approach¹⁴, which however did not exclude the effect of SRF at enrollment. This study was designed to assess CC blood flow changes in the affected eyes of CCSC patients in response to half-dose PDT assessed at early and long-term follow-up using OCTA. These results were compared with those of the contralateral eyes and the healthy control eyes to determine if there is a difference in response to half-dose PDT in the affected eyes.

Methods

Patients with CCSC and healthy gender- and age-matched subjects, from November 2017 to November 2018, were retrospectively enrolled in this study. All patients provided written informed consent when being performed the examinations of FA and ICGA. CCSC was defined¹⁰ as exhibition of visual acuity symptoms for at least 6 months along with documented clinical features of CSC, including macular subretinal fluid (SRF), RPE changes of leakage and hyperfluorescent alterations detected by OCT and FFA/ICGA. All patients in this study were administered with half-dose PDT with verteporfin infusion (3 mg/m² of body surface area), the laser light (689 nm; 50 J/cm² for 83 seconds) was projected for 15 minutes after the start of the infusion and was targeted at the area of hyperpermeability in ICGA. Administration of PDT was performed by an experienced ophthalmologist. Patients with eyes subjected to any previous treatment and eyes that exhibited myopia more than 3.0 diopters, and those suffering from other diseases like PCV and neovascular maculopathy (eg, age-related macular degeneration, pathologic myopia, idiopathic CNV) were excluded from the study upon clinical examination.

All patients had received thorough ophthalmic examinations prior to PDT treatment, including best-corrected visual acuity (BCVA) assessment, FFA, ICGA (HRA2; Heidelberg Engineering, Heidelberg, Germany), fundus photography (Zeiss, Oberkochen, Germany), spectral-domain OCT (SD-OCT) and OCTA (RTVue XR AngioVue Version 2017.1; Optovue Inc., Fremont, CA, USA). Quantitative assessments were performed at baseline and repeated in multiple sections at 1-week, 1-month, and 3-month and 6-month intervals after PDT treatment. These assessments included central macular thickness (CMT) in the mode of Retina map and subfoveal choroidal thickness (SFCT) and Enhanced HD Line (Enhanced HD-OCT) of SD-OCT, and the proportion of total areas of flow signal voids (FSV, %) in OCTA using binary processing. Healthy gender- and age-matched subjects without ocular diseases were enrolled at a single visit and examinations of indirect ophthalmoscopy, BCVA, SD-OCT and OCTA were performed. Of those healthy subjects, those with systemic diseases like diabetes and hypertension, myopia more than 3.0 diopters and ocular media opacity that could affect the scan quality of OCTA were excluded from the study.

Enhanced HD-OCT was performed on the fovea by scanning many times with a horizontal single-line and with the preservation of the best one. SFCT was defined as the vertical distance between the outside boundary of RPE and the choroidal-scleral interface as measured by averaging the values obtained at three positions: the subfovea, the meridians 750 mm nasally and 750 mm temporally. In addition, 3×3

mm² OCTA scanning was acquired centering on the fovea with eye tracking option set to on. Multiple scans were performed and images with quality score greater than or equal to 7/10 were preserved. OCTA, using a light source centered on 840nm and an A-scan rate of 70,000 scans per second, was incorporated with split-spectrum amplitude-decorrelation angiography (SSADA) algorithm to extract angiographic information by quantifying the decorrelation of the OCT reflectance between the two consecutive B-scans, each containing 304 A-scans at each location on the retina¹⁵. CC level was defined as the distance between 10 mm of the upper-bruch's membrane and 10 mm of the lower-bruch's membrane. Layered modification was performed manually if inaccurate segmentation was found during image processing. Referring to the reproducible automatic binarization methods in the literature^{8,11}, we measured the percentage of black pixels representing absent or decreased flow signal within CC, known as flow signal voids (FSV, %)^{8,11}, using image J software (ImageJ 1.52a, <https://imagej.nih.gov/ij/docs/>) (Fig. 1).

All statistical tests were performed using SPSS version 23.0 (<https://www.ibm.com/analytics/spss-statistics-software>). Categorized data are described as frequency and percentage, and quantitative data are presented as mean and standard deviation. Shapiro-Wilk test was used to evaluate distribution. Student's t-test and one-way analysis of variance (ANOVA) were used in cases of normal distribution whereas nonparametric statistical analyses (independent samples Mann–Whitney U or related-samples Wilcoxon test and Kruskal-Wallis test) were otherwise used for comparing variables between groups. Differences in proportions of gender were tested by χ^2 test. Pearson or Spearman method was used to analyze the correlation between FSV and age, and between FSV and SFCT. A two-sided P-value = 0.05 was considered statistically significant.

Results

A total of 28 affected eyes and 24 unaffected eyes from 26 CCSC patients, and 40 eyes of 20 age- and gender-matched healthy individuals were enrolled in this study. The baseline characteristics of the CCSC patients are as follows: 19 (73.08%) males and 7 (26.92%) females, with a mean age of (45.14±7.05) years, and there was no statistical difference between healthy individuals and patients with CCSC in age and gender (p=0.084, p=0.899). OCTA imaging with subretinal fluid (SRF), PED, and RPE clumping shown on cross-sectional B-scan OCT were excluded from quantitative analysis of FSV (Fig. 2).

Measurements of FSV was performed in both eyes of CCSC with complete resolution of SRF during follow-ups (Table 1). At 6- month follow-up, 2 affected eyes showed signs of reoccurred SRF and patients complained of visual problems, while 7 affected eyes and 5 unaffected eyes were lost to follow-up. Significant improvement of BCVA was found at the last follow-up visit (0.045±0.074 LogMAR) compared to the initial (0.235±0.137 LogMAR) assessment (p<0.001).

Comparisons within the group of affected eyes showed a significant decrease of FSV at 6-m follow-up than 1-m follow-up (p=0.036). While Post-hoc multiple comparisons within the group of unaffected eyes showed that there were no significant changes of FSV values (p=0.674). Comparing with the normal control eyes, FSV in affected eyes were greater at 1-m, 3-m and 6-m follow-up (p<0.05 for all), while FSV

in unaffected eyes were significantly higher at baseline, 1-w, 1-m and 3-m follow-up ($p < 0.05$ for all) (Table 1). Besides, the values of FSV in affected eyes were greater than unaffected eyes at 1-m and 3-m post-treatment (Table 1).

Post-hoc multiple comparisons within the group of affected eyes showed a significant difference of SFCT between baseline and 3-m follow-up ($p = 0.015$), while no statistically significant change in average SFCT was observed in the unaffected eyes ($p = 0.674$). Relative to normal control eyes, SFCT in both eyes of CCSC patients were greater throughout the follow-up period in this cohort ($p < 0.05$ for all), while differences between the affected and the unaffected eyes of CCSC patients were only found at baseline ($p = 0.015$) (Table 1).

Due to the inevitable shadowing artifacts of SRF, the values of FSV at baseline and early stage after the treatment were not quantified. Qualitative observation of CC patterns, as a supplement, showed that all of the affected eyes demonstrated local or diffuse flow signal attenuation or dilation and tortuosity of CC at baseline. One week after PDT, three CC patterns of early response to PDT can be identified by OCTA: signs of recovery with increased blood flow signals and decreased dark areas were observed in 21 (75.0%) eyes (Fig. 3), while worsening local CC ischemia were observed in 6 (21.4%) eyes (Fig. 5), and an extraordinarily dilated choriocapillary network or emerging dense network of neovascularization surrounded by foci of reduced flow signals within CC slab was observed in 1 (3.6%) eye (Fig. 4).

Spearman correlation analysis showed that the mean value of FSV was positively correlated with age in the unaffected eyes of CCSC patients at onset ($r = 0.469$, $p = 0.021$), 1-m follow-up ($r = 0.470$, $p = 0.021$) and 3-m follow-up ($r = 0.414$, $p = 0.044$) intervals and in the eyes of healthy individuals ($r = 0.715$, $p = 0.000$). However, significant correlation between the values of FSV and SFCT has not been found.

Discussion

Using OCTA, quantitative analysis with automatic binarization methods has been increasingly employed to analyze CC flow changes in some chorioretinal disorders, such as dry age-related macular degeneration and CSC, providing reproducible and objective data^{7,8,11}. Excluding the masking artifacts of SRF and RPE clumping and PED could help increase the reliability of the quantitative assessment in resolved CSC^{2,11}. In previous studies, assessment of CC flow alterations in affected eyes showed a recovery of CC flow after the treatment of PDT^{7,13,14,16}, which was consistent with our results of the reduced value of FSV at 6-m follow-up compared to 1-m follow-up. However, in this study, the value of FSA in affected eyes retained higher at 6-m follow-up comparing with healthy controls, which indicated that CC attenuation might remain long after the treatment of half-dose PDT, contrary to previous OCTA studies suggesting that CC flow return to normal after half-dose/influence PDT treatment^{13,14,16}. A series of other follow-up investigations have also showed that reduced SFCT on EDI-OCT in affected eyes remain higher than healthy controls¹, and choroidal vascular hypermeability on ICGA persisted in some cases even after the SRF had resolved completely^{17,18}. While, these remaining choroidopathy observed

after half-dose PDT could potentially be attributed to the primary pathogenesis of CSC and/or the therapeutic effects of PDT.

It has been postulated that CSC may be an ocular condition caused by a systemic disease that involves choroidal circulation¹, which could be potentially supported by previous results of some systemic risk factors¹ and abnormalities of CC and SFCT in self-resolved CSC eyes and the unaffected eyes^{11,19-21}. Similarly, our study demonstrated that FSV in unaffected eyes of CCSC were higher than those in healthy individuals, and remained statistically unchanged over time. As proposed by Nicolo, M.¹⁹, these CC alterations in asymptomatic eyes might be in the early stage of the same condition of CSC^{2,11,19}. Previous studies have also detected punctated hyperfluorescent spots using ICGA in most contralateral eyes of CSC and PCV, which might be a subclinical manifestation of increased choroidal hypermeability and intrachoroidal hydrostatic pressure^{17,22}. And these zones of reduced choriocapillaris flow on OCTA have been found to be anatomically correlated with pathologically dilated Haller layer vessels on EDI-OCT². Compared to unaffected eyes, FSV in affected eyes, in this study, was significantly higher at 1-/3-m follow-up, but not at 6-m follow-up. We speculated that abnormal vascular situation in the CC layer in affected eyes of CCSC might recover to a subclinical condition similar to that of the contralateral eyes, which needs to be validated by longitudinal investigations with larger sample size.

In order to evaluate the early CC alterations in response to half-dose PDT in CCSC, qualitative observation was performed and three CC patterns at 1 week after PDT have been documented in the present study. Out of the affected eyes, 75.0% (21/28) showed favorable recovering signs of increased flow signals and decreased dark areas (Fig. 3), while 21.4% (6/28) exhibited worsen CC ischemia (Fig. 5), which we have previously documented as transient CC ischemia in another cohort¹³. Demircan, et al.¹⁶ showed that the transient CC ischemia may even occur at as early as 3 days after half-fluence PDT. Furthermore, 3.6% (1/28) of the eyes demonstrated transient appearance of exuberant neovascularization network within CC level (Fig. 4). Using OCTA, the direct action of PDT on the CC occlusion could be visualized *in vivo* during follow-up^{13,14,16}. Post-treatment choroidal hypoperfusion were largely reported, with evidence of hypoperfusion on traditional angiography²³, in the treatment of neovascular age-related macular degeneration with full PDT, which might be related to the preferential aggregation of verteporfin in the lesions²³.

The repairing mechanisms of surviving endothelial cells and the recanalization processes of novel channels within previously occluded capillaries after PDT treatment remains unclear¹. In addition to the possibility that CC flow recovered from the released pressure of decreased SFCT owing to the therapeutic effect of PDT^{2,11}, one could speculate that the damaged choroidal endothelial cells and RPE cells in PDT-treated areas may contribute to the release of VEGF^{24,25}, and an imbalanced stimulatory and inhibitory condition for neovascularization formation could be compromised by PDT-related hypoxia and ischemia^{25,26}. However, the process of recanalization could, to some extent, contribute to the formation of CNV²⁶. Particularly, 2 eyes with early CC ischemia, in this cohort, exhibited transient (Fig. 4) and persistent (Fig. 5) appearance of type I CNV, consisting with the morphologic characteristics of

neovascularization networks within CC level on previous OCTA-related studies^{20,27,28}. However, it is controversial that these suspected secondary CNV within CC level may contribute to the CC atrophy and the anterior displacement of medium-sized choroidal vessels with segmentation artifacts that masquerade as CNV²⁴. Besides, type I CNV has been well documented as the most common subtype of secondary CNV in the natural course of CSC^{1,6,29}, which should also be taken into account while studying PDT-related CNV³⁰. What makes it more controversial is that most of the previous studies of CSC related CNV were based on patients with heterogeneous treatment histories of PDT or laser photocoagulation^{20,28-30}. Longitudinal OCTA observation would thus help to comparatively follow these lesions over time to better understand how they behave.

There are certain limitations in our study including its retrospective nature, the small number of subjects, and the shortage of quantitative method for binarization that limit our ability to assess FSV in early stage and reflect CC alterations of exaggerated flow and dilated CC⁷. Our results may underestimate the occurrence of these transient alterations of ischemia and neovascularization occur within two intervals or outside the imaging area of OCTA. We believe that the actual value of FSV may be higher since patients with SRF were excluded in quantitative assessment, and CC in these patients is certainly abnormal. Although the value of FSV was positively correlated with age in healthy controls in consistence with aging physiological changes of CC^{8,11}, the dynamic nature of CC flow changes with time should also be taken into consideration when comparing results to those of the contralateral eyes. Besides, correlation between SFCT and FSV has not been established in this cohort, nor in other reports³¹. It might be related to the relatively small sample size, or that SFCT generally assesses choroidal thickness and both pathologically dilated vessels and increased stromal contribute to the increase of SFCT, future studies could further evaluate the correlation of FSV with other more specific indicators such as choroidal vascularity index (CVI)³.

Conclusions

In summary, we have quantitatively observed that abnormal CC flow attenuation remained in completely resolved eyes of CCSC patients treated with half-dose PDT. And it is noteworthy that half-dose PDT, as a safe therapeutic method for CCSC, could still potentially worsen choroidal ischemia as a pathophysiologic cause of neovascularization progressions in some cases, while OCTA is helpful in identifying these CC changes in the early stage after the treatment of PDT and following these lesions over time to better understand how they progress.

Abbreviations

OCTA: optical coherence tomography angiography

CC: choriocapillaris

CCSC: chronic central serous chorioretinopathy

SRF: subretinal fluid

RPE: retinal pigment epithelial

PED: pigment epithelial detachment

PDT: photodynamic therapy

FSV: flow signal voids

EDI-OCT: enhanced depth imaging optical coherence tomography

SFCT: subfoveal choroidal thickness

ICGA: indocyanine green angiography

CNV: choroidal neovascularization

Declarations

Ethics approval and consent to participate.

This retrospective study was approved by the Renmin Hospital of Wuhan University and was conducted in compliance with the Declaration of Helsinki.

Consent for publication.

Not applicable.

Availability of data and material.

The datasets used and/or analyzed during the current study are available from the corresponding author on reasonable request. All participants provided their written informed consent to participate in the study.

Competing interests.

Not applicable.

Funding.

Not applicable.

Authors' contributions.

JJ and L contributed to patient care. All authors, including JJ, CZ, L, ZHZ, L, and HM contributed to literature search, data collection, data analysis, and data interpretation. JJ, and CZ contributed to figures and writing the manuscript. All authors have read and approved the final manuscript.

Acknowledgements.

We want to especially express our gratitude to professor CZ and HM for their help on collecting data and support our work.

References

1. Daruich A, Matet A, Dirani A, et al. Central serous chorioretinopathy: Recent findings and new physiopathology hypothesis. *Prog Retin Eye Res.* 2015;48:82-118.
2. Gal-Or O, Dansingani KK, Sebro D, Dolz-Marco R, Freund KB. INNER CHOROIDAL FLOW SIGNAL ATTENUATION IN PACHYCHOROID DISEASE: Optical Coherence Tomography Angiography. *Retina.* 2018;38(10):1984-1992.
3. Wei X, Sonoda S, Mishra C, et al. Comparison of Choroidal Vascularity Markers on Optical Coherence Tomography Using Two-Image Binarization Techniques. *Invest Ophth Vis Sci.* 2018;59(3):1206-1211.
4. Lai FH, Ng DS, Bakthavatsalam M, et al. A Multicenter Study on the Long-term Outcomes of Half-dose Photodynamic Therapy in Chronic Central Serous Chorioretinopathy. *Am J Ophthalmol.* 2016;170:91-99.
5. Schmidt-Erfurth U, Laqua H, Schlotzer-Schrehard U, Viestenz A, Naumann GO. Histopathological changes following photodynamic therapy in human eyes. *Arch Ophthalmol.* 2002;120(6):835-844.
6. Borrelli E, Sarraf D, Freund KB, Sadda SR. OCT angiography and evaluation of the choroid and choroidal vascular disorders. *Prog Retin Eye Res.* 2018;67:30-55.
7. Lauermann JL, Eter N, Alten F. Optical Coherence Tomography Angiography Offers New Insights into Choriocapillaris Perfusion. *Ophthalmologica.* 2018;239(2-3):74-84.
8. Spaide RF. Choriocapillaris Flow Features Follow a Power Law Distribution: Implications for Characterization and Mechanisms of Disease Progression. *Am J Ophthalmol.* 2016;170:58-67.
9. Teussink MM, Breukink MB, Grinsven MJ, Hoyng CB, Klevering BJ. OCT angiography compared to fluorescein and indocyanine green angiography in chronic central serous chorioretinopathy. *Invest Ophthalmol Vis Sci.* 2015;56(9):5229-5237.
10. Quaranta-El Maftouhi M, El Maftouhi A, Eandi CM. Chronic central serous chorioretinopathy imaged by optical coherence tomographic angiography. *Am J Ophthalmol.* 2015;160(3):581-587 e581.
11. Rochepeau C, Kodjikian L, Garcia MA, et al. Optical Coherence Tomography Angiography Quantitative Assessment of Choriocapillaris Blood Flow in Central Serous Chorioretinopathy. *American Journal of Ophthalmology.* 2018;194:26-34.
12. Ogawa Y, Maruko I, Koizumi H, Iida T. Quantification of Choroidal Vasculature by High-Quality Structure En Face Swept-Source Optical Coherence Tomography Images in Eyes with Central Serous Chorioretinopathy. *Retina.* 2018.
13. Xu Y, Su Y, Li L, Qi H, Zheng H, Chen C. Effect of Photodynamic Therapy on Optical Coherence Tomography Angiography in Eyes with Chronic Central Serous Chorioretinopathy. *Ophthalmologica.*

2017;237(3):167-172.

14. Nassisi M, Lavia C, Alovisei C, Musso L, Eandi CM. Short-Term Choriocapillaris Changes in Patients with Central Serous Chorioretinopathy after Half-Dose Photodynamic Therapy. *Int J Mol Sci*. 2017;18(11).
15. Kraus MF, Liu JJ, Schottenhamml J, et al. Quantitative 3D-OCT motion correction with tilt and illumination correction, robust similarity measure and regularization. *Biomed Opt Express*. 2014;5(8):2591-2613.
16. Demircan A, Yesilkaya C, Alkin Z. Early choriocapillaris changes after half-fluence photodynamic therapy in chronic central serous chorioretinopathy evaluated by optical coherence tomography angiography: Preliminary results. *Photodiagnosis Photodyn Ther*. 2018;21:375-378.
17. Tsujikawa A, Ojima Y, Yamashiro K, et al. Punctate hyperfluorescent spots associated with central serous chorioretinopathy as seen on indocyanine green angiography. *Retina*. 2010;30(5):801-809.
18. Iida T, Kishi S, Hagimura N, Shimizu K. Persistent and bilateral choroidal vascular abnormalities in central serous chorioretinopathy. *Retina*. 1999;19(6):508-512.
19. Nicolo M, Rosa R, Musetti D, Musolino M, Saccheggiani M, Traverso CE. Choroidal Vascular Flow Area in Central Serous Chorioretinopathy Using Swept-Source Optical Coherence Tomography Angiography. *Invest Ophthalmol Vis Sci*. 2017;58(4):2002-2010.
20. Mandadi SKR, Singh SR, Sahoo NK, et al. Optical coherence tomography angiography findings in fellow eyes of choroidal neovascularisation associated with central serous chorioretinopathy. *Br J Ophthalmol*. 2019.
21. Kang NH, Kim YT. Change in subfoveal choroidal thickness in central serous chorioretinopathy following spontaneous resolution and low-fluence photodynamic therapy. *Eye (Lond)*. 2013;27(3):387-391.
22. Park S, Kim B, Park K, Woo S. Punctate hyperfluorescence spot as a common choroidopathy of central serous chorioretinopathy and polypoidal choroidal vasculopathy. *Am J Ophthalmol*. 2014;158(6):1155-1163.
23. Schmidt-Erfurth U, Kiss C, Sacu S. The role of choroidal hypoperfusion associated with photodynamic therapy in neovascular age-related macular degeneration and the consequences for combination strategies. *Prog Retin Eye Res*. 2009;28(2):145-154.
24. Chhablani J, Pichi F, Silva R, et al. Antiangiogenics in Choroidal Neovascularization Associated with Laser in Central Serous Chorioretinopathy. *Retina*. 2016;36(5):901-908.
25. Schmidt-Erfurth U, Schlotzer-Schrehard U, Cursiefen C, Michels S, Beckendorf A, Naumann GO. Influence of photodynamic therapy on expression of vascular endothelial growth factor (VEGF), VEGF receptor 3, and pigment epithelium-derived factor. *Invest Ophthalmol Vis Sci*. 2003;44(10):4473-4480.
26. Schlotzer-Schrehardt U, Viestenz A, Naumann GO, Laqua H, Michels S, Schmidt-Erfurth U. Dose-related structural effects of photodynamic therapy on choroidal and retinal structures of human eyes. *Graefes Arch Clin Exp Ophthalmol*. 2002;240(9):748-757.

27. Moussa M, Leila M, Khalid H, Lolah M. Detection of Silent Type I Choroidal Neovascular Membrane in Chronic Central Serous Chorioretinopathy Using En Face Swept-Source Optical Coherence Tomography Angiography. *Journal of Ophthalmology*. 2017.
28. Spaide RF. Optical Coherence Tomography Angiography Signs of Vascular Abnormalization With Antiangiogenic Therapy for Choroidal Neovascularization. *Am J Ophthalmol*. 2015;160(1):6-16.
29. Shiragami C, Takasago Y, Osaka R, et al. Clinical Features of Central Serous Chorioretinopathy With Type 1 Choroidal Neovascularization. *Am J Ophthalmol*. 2018;193:80-86.
30. Wu JS, Chen SN. Optical Coherence Tomography Angiography for Diagnosis of Choroidal Neovascularization in Chronic Central Serous Chorioretinopathy after Photodynamic Therapy. *Sci Rep*. 2019;9(1):9040.
31. Yun C, Huh J, Ahn SM, et al. Choriocapillaris flow features and choroidal vasculature in the fellow eyes of patients with acute central serous chorioretinopathy. *Graefes Arch Clin Exp Ophthalmol*. 2019;257(1):57-70.

Figures




Figure 1

The diagrammatic sketch of automatic quantitative binarization using ImageJ (B) of original image of en-face OCTA image of CC slab (A) in a healthy control eye.

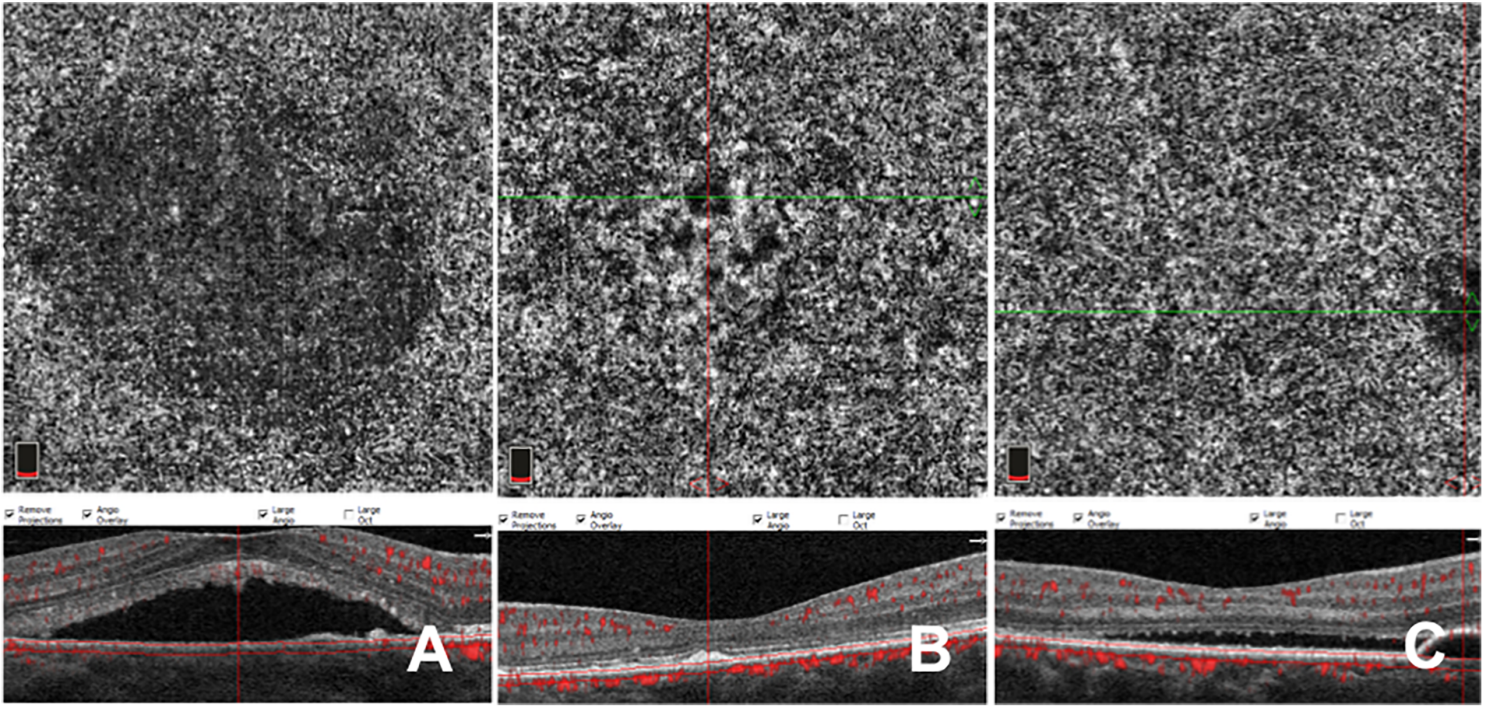


Figure 2

En-face OCTA image of CC slab in affected eyes showing false positive flow signal void (FSV) from subfoveal retinal detachment (A), retinal pigment epithelial (RPE) clumping (B) and pigment epithelial detachment (PED) (C) on the corresponding cross-sectional B-scan OCT.

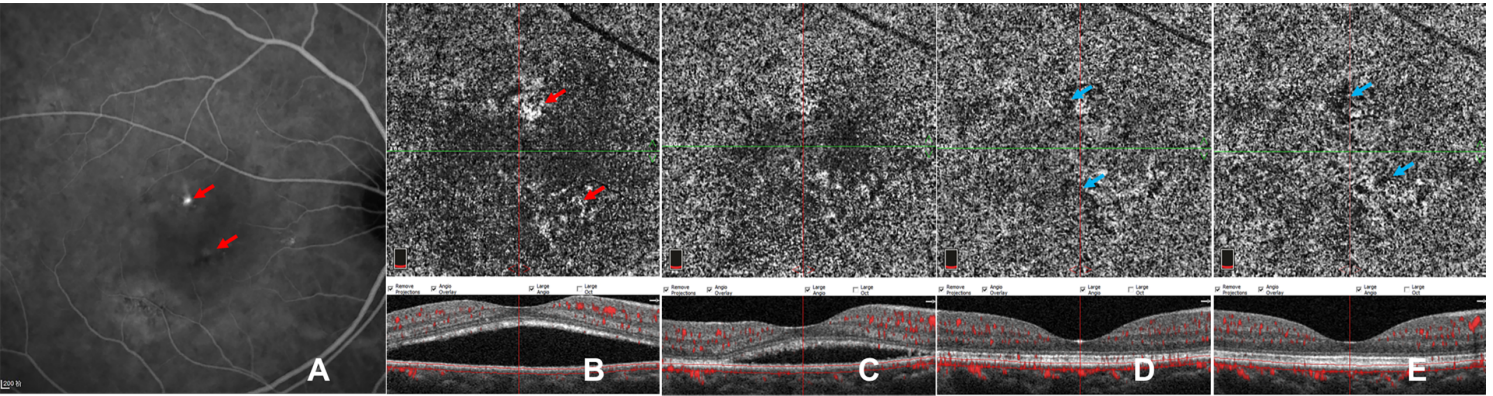


Figure 3

Paired of images of a case showing CC pattern of gradually increasing flow signals after PDT. Indocyanine green angiography (ICGA) (A) of baseline reveals partial choriocapillary hyperpermeability (red arrow) and focal hypo-fluorescent areas (blue arrow). En-face OCTA (B-F) of CC slab and the corresponding cross-sectional B-scan OCT (B-F) clearly demonstrates the CC flow changes with time. Dilatation of CC (red arrow) accompanied by dark areas (blue arrow) can be seen at baseline (B). Recovery sign of increasing flow signals and decreasing dark areas has been found at 1 week (C) after half-dose PDT (C) and at the following 1-m (D), 3-m (E) and 6-m (F) follow-ups, while foci of dark areas (blue arrows) remained.

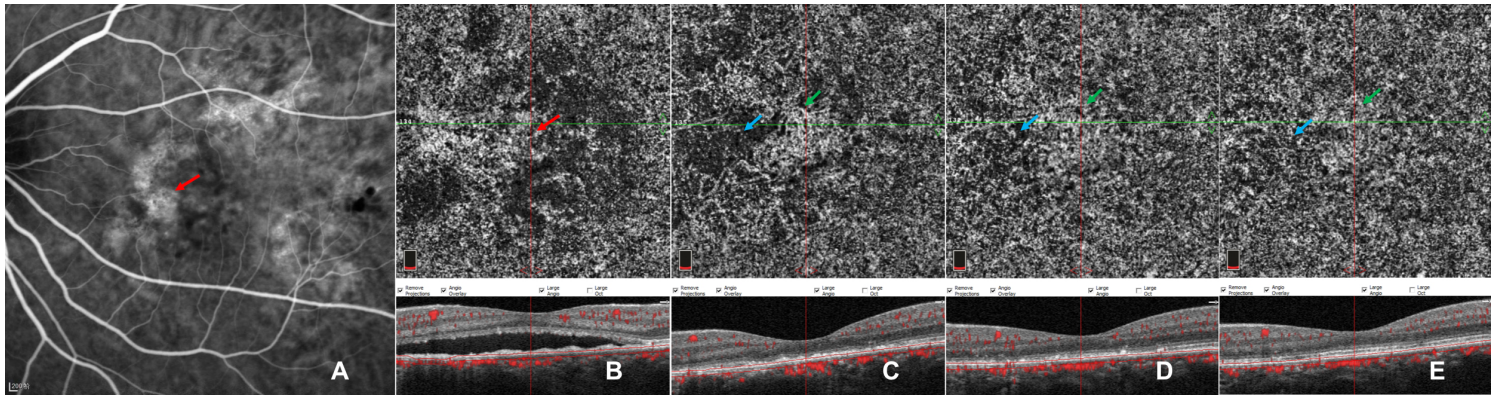


Figure 4

Paired of images of a case showing CC pattern of transient network of neovascularization. Indocyanine green angiography (ICGA) (A) of baseline reveals widespread lesions of choriocapillary hyperpermeability (red arrow) with hypo-fluorescent areas within them. En-face OCTA (B-F) of CC slab and the corresponding cross-sectional B-scan OCT (B-F) demonstrates the CC flow changes with time. Local dilated CC patterns in macular region surrounded by defused flow signal void are noticeable at baseline (B). An emerging dense network of neovascularization (green arrow) accompanying foci of reduced flow signals (blue arrow) was observed at 1 week after half-dose PDT (C), which gradually subsided (green arrows) during subsequent follow-ups of 1 month (D) , 3 month (E) and 6 months (F) while recovering with CC focal hypoperfusion.

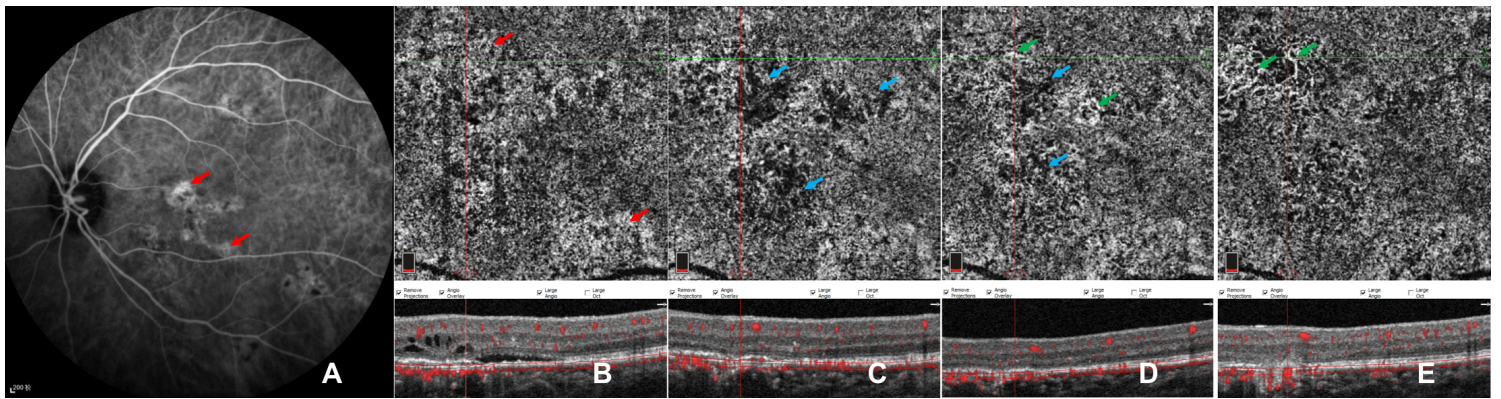


Figure 5

Paired of images of a case showing CC pattern of worse CC ischemia followed by persistent type I CNV. Indocyanine green angiography (ICGA) (A) of baseline reveals multifocal choriocapillary hyperpermeability (red arrows). En-face OCTA (B-F) of CC slab and the corresponding cross-sectional B-scan OCT (B-F) clearly demonstrates the CC flow changes with time. Defused dilatation of CC (red arrow) (B) can be detected at baseline, with punctate dark areas within the lesions. Local worsened CC ischemia (blue arrows) has been found at 1 week after half-dose PDT (C), which combined with dynamic changes of neovascularization of sprouts (D) at 1-m follow-up, and grew with loose network of CNV (green arrows) during follow-ups of 3 month (E) and 6 months (F) while recovering with CC focal hypoperfusion.