

Total Knee Arthroplasty to Treat Acute Knee Dislocation Associated With Osteoarthritis: a Case Report

Huazhang Xiong

Affiliated Hospital of Zunyi Medical College: Affiliated Hospital of Zunyi Medical University

<https://orcid.org/0000-0002-1017-5109>

Yuwan Li

Peking University Third Hospital

Hao Yu

Affiliated Hospital of Zunyi Medical University

Ying Jin

Affiliated Hospital of Zunyi Medical University

Wei Xiong

Affiliated Hospital of Zunyi Medical University

Jiachen Peng (✉ pengjiachen@139.com)

Affiliated Hospital of Zunyi Medical University

Yi Liu

Affiliated Hospital of Zunyi Medical University

Technical note

Keywords: Total knee arthroplasty, Treatment, Knee dislocation, Osteoarthritis

Posted Date: September 27th, 2021

DOI: <https://doi.org/10.21203/rs.3.rs-910434/v1>

License: © ⓘ This work is licensed under a Creative Commons Attribution 4.0 International License.

[Read Full License](#)

Abstract

Background: Knee dislocation (KD) is a common disease in the young people. It is rare to report treatment of the KD associated with osteoarthritis (OA) in the old population. In this case report, we present two cases in which total knee arthroplasty (TKA) was performed to treat acute KD associated with osteoarthritis (OA) in two female patients.

Methods: The two patients underwent knee injuries and limited range of motion (ROM). After diagnosing acute KD, including KD II and KD III-M, associated with OA with X-ray, computed tomography (CT) and magnetic resonance imaging (MRI) investigations, we considered TKA to be the best management.

Results: TKA was successfully used to treat acute KD associated with OA, and the patients achieved significant improvements in their clinical and functional outcomes.

Conclusion: Acute KD associated with OA could be an indication for TKA. However, early TKA procedures can lead to a risk of arthrofibrosis and joint stiffness.

Level of evidence V.

Background

Knee dislocation (KD) is a severe multiligament knee injury¹⁻³ that accounts for approximately 0.02–0.2% of orthopaedic injuries.³ Arthroscopic and open ligament reconstruction and repair procedures for acute KD are routine surgeries in young patients.^{1,3} To the best of our knowledge, total knee arthroplasty (TKA) is similarly considered to be a procedure that can successfully manage chronic KD.⁴⁻⁶ However, TKA for the management of acute KD associated with osteoarthritis (OA) has not been reported. Furthermore, TKA for acute KD associated with OA is challenging because the complicated natures of multiligament injuries could result in risks for an intraoperative gap imbalance and postoperative knee instability.⁷

In the current case report, two cases of TKA for the treatment of two elderly female patients with KD associated with OA are reported.

Surgical Technique And Case Presentation

Case 1

A 67-year-old woman suffered an injury to her left knee joint in a traffic accident while crossing a crosswalk, and no additional injuries or conditions were found. The patient requested ligament reconstruction and was transferred to our orthopaedic department from another hospital. Additionally, she presented with a history of bilateral knee pain before the accident. She had irreversible varus deformities of 8° and 10° in her left and right knees, respectively. The bilateral knee range of motion

(ROM) was 5° to 85°. The anterior drawer test (ADT) and posterior drawer test (PDT) were positive in the left knee. On both sides, the knee was severely degenerated with medial substantial bone loss on plain radiographs (►Fig. 1a, b), and anterior cruciate ligament (ACL) and posterior cruciate ligament (PCL) tears were found in the left knee on magnetic resonance imaging (MRI) (►Fig. 1c, d). KD II (ACL and PCL tears) associated with OA (Kellgren-Lawrence IV)⁸ was diagnosed in the left knee according to the Schenck classification system,⁹ and we decided to perform TKA on the eighth day after injury.

A cemented, posterior-stabilized (PS) prosthesis (Genesis II, Smith & Nephew, USA) was utilized during conventional surgery. After administering spinal anaesthesia, the patient was placed in the supine position with an upper-thigh tourniquet, a medial parapatellar approach was selected. In this case, a defect was present in the medial plateau of the tibia that was not completely removed by the proximal cut in the tibia. A cancellous screw was positioned into the tibial defect to improve the medial support for the tibial tray.

The PS prosthesis (femoral component-3; tibial component-2; polyethylene (PE) insert-9 mm) was chosen. At 18 months postoperatively, TKA (STAR, WEGO, China) was performed on her right knee because of end-stage OA (►Fig. 1g, h). The TKA procedure was the same as the left TKA procedure. The PS prosthesis (femoral component-3; tibial component-2; PE insert-9 mm) was chosen. On the second day after the procedure, physical therapy began. Isometric strength exercises of the quadriceps and ROM exercises of the knee joint were initiated. Full weight-bearing was allowed, and she could walk with assistive devices. The visual analogue scale/score (VAS), Oxford Knee Score (OKS), Western Ontario McMaster University Osteoarthritis Index (WOMAC), and ROM significantly improved in the latest follow-up compared with the preoperative values (►table. 1) (►Fig. 1k, l). The postoperative radiographs of the bilateral knee joints showed good alignment (►Fig. 1e, f, i, j), and the results were more satisfactory for the right knee than for the left knee .

Case 2

A 69-year-old female farmer was injured while standing up with a load, sustaining a lateral dislocation of the left knee. The patient requested ligament reconstruction and was transferred to our orthopaedic department from another hospital with the extended knee immobilized in plaster because of a KD. The ADT, PDT and valgus stress tests were positive, and the preoperative ROM of the left knee was 0° to 70°. Plain radiographs and MRI of the left knee showed KD III-M (ACL, PCL and MCL tears) according to the Schenck classification⁹ with end-stage knee OA (Kellgren-Lawrence III-IV)⁸ (► Fig. 2a, b, c, d, e, f). Left TKA (AK, Beijing, China) was performed on the fifteenth day after injury, and the MCL was repaired with sutures in the primary footprint to ensure complete stability and a full ROM. A constrained condylar knee (CCK) prosthesis (femoral component-3; tibial component-C; PE insert-8 mm) was chosen. Owing to the presence of medial instability (► Fig. 2g, h), the left knee was fixed to allow for full extension and flexion using an unlocked hinged brace for 6 weeks,¹⁰ and then the patient was allowed to start weight bearing. Manipulative release was performed under general anaesthesia at 10 weeks postoperatively because of

knee stiffness. No additional complications, such as infection or deep venous thrombosis, occurred. The VAS, OKS, WOMAC, and ROM significantly improved at the latest follow-up compared with the preoperative values (►Table 1) (►Fig. 2k). The postoperative radiographs of the left knee joint showed good alignment (►Fig. 2i, j).

Table 1
Scores of different knees preoperatively and at the latest follow-up

Outcome	Case 1		Case 2			
	Left knee	Right knee	Left knee		Right knee	
	Pre	Post	Pre	Post	Pre	Post
VAS	8	4	8	3	8	4
OKS	54	17	56	14	55	15
WOMAC	80	19	79	14	80	22
ROM	5°-85°	0°-90°	5°-90°	0°-90°	0°-70°	0°-90°
OT (min)	58		62		76	
BL (ml)	25		30		30	
Infusion	No		No		No	

NOTE. Pre, preoperative; Post, postoperative; VAS, visual analogue scale/score; OKS, Oxford Knee Score; WOMAC, Western Ontario McMaster University Osteoarthritis Index; OT, operative time; BL, blood loss.

Discussion

The important findings in these two cases were that acute KD associated with OA could be managed by TKA, with good functional outcomes. These cases showed that TKA could be indicated for acute KD associated with OA. However, early TKA procedures could lead to a risk of arthrofibrosis and joint stiffness.

KD is mainly caused by traumas, congenital anomalies,^{11,12} secondary lesions¹³ and so on. Both patients developed disabilities due to serious KD and severe OA. In the two cases, knee instability and pain with limited ROM were observed. Because of severe degenerative changes in the knee in both cases, the advantages and disadvantages of ligament reconstruction or repairs and joint arthroplasty were discussed and communicated with the patients who chose to undergo TKA over ligament reconstruction or single repair. TKA was chosen for these two patients because of severe knee OA, which is already an indication for TKA. The advantages of TKA include satisfactory outcomes, minimal complications, rapid postoperative rehabilitation, and early joint motion.^{4,14,15}

A few studies have reported TKA for the treatment of KD,³⁻⁶ although all of these studies only reported TKA as treatment for chronic multiligament knee injury. Jabalameli et al.⁵ reported TKA with a constrained hinged prosthesis for patients with CMKI, and recently, Goyal et al.³ reported that two patients with KD III injuries underwent TKA with PS prostheses because of progressive OA that developed after the ligament reconstruction procedures. These patients achieved improved functional ability and returned to their previous jobs. Our two patients also achieved significant improvements in their VAS, OKS, and WOMAC postoperatively, which is similar to the results obtained in the aforementioned studies. One-stage TKA can reduce complications and costs and allow for early mobility. Our procedure was finished within the tourniquet time, as ligament reconstruction and repair procedures, with no increased intraoperative bleeding or postoperative infusion. Therefore, we consider that TKA is a favourable treatment for KD associated with OA. However, there were better functional outcomes and higher satisfaction for the right knee than for the left knee in case 1, and the patient in case 2 sustained stiffness of the left knee. Acute TKA could be related to stiffness and arthrofibrosis.³ It may be more appropriate to perform TKA after soft tissue and bone marrow oedema has subsided.

There are some limitations in this case report. First, we initially considered the two cases to be ordinary cases, and few intraoperative images were collected. Second, this surgical procedure can only be performed by highly experienced and specialized surgeons using the knee arthroplasty technique. Third, TKA may only be indicated in some cases of KD with severe OA and for elderly patients.

In conclusion, TKA could be indicated for acute KD associated with OA. However, early TKA procedures could lead to a risk of arthrofibrosis and joint stiffness.

Abbreviations

KD: Knee dislocation; OA: Osteoarthritis; TKA: Total knee arthroplasty

Declarations

Acknowledgement

The authors would like to thank the patients who agreed to publish this article.

Authors' contributions

The following authors have designed the study (AU: Jiachen Peng), gathered and assessed the data (AU: Huazhang Xiong, Yuwan Li, Hao Yu, Wei Xiong), wrote the initial drafts (Huazhang Xiong), and ensure the accuracy of the data and evaluation (Jiachen Peng, Yi Liu, Ying Jin).

Funding

This article was supported by grants of the Science and Technology Program of Guizhou Province [2021] No. 434 and Doctoral Startup Foundation of Zunyi Medical University [2021]No. 4.

Availability of data and materials

Not applicable.

Ethics approval and consent to participate

The patients signed an informed consent. They agreed to allow the images and details of the case to be made public.

Consent for publication

The publication was done with the consent of the participants

Competing interests

The authors declare no conflict of interest.

References

1. Murakami R, Honda E, Fukai A, et al. Single-Stage Arthroscopic Anterior and Posterior Cruciate Ligament Repairs and Open Medial Collateral Ligament Repair for Acute Knee Dislocation. *Case Rep Orthop* 2020;20207348201
2. Ramirez-Bermejo E, Gelber PE, Pujol N. Management of acute knee dislocation with vascular injury: the use of the external fixator. A systematic review. *Arch Orthop Trauma Surg* 2020;9(4):122-130
3. Goyal T, Paul S, Banerjee S, Das L. Outcomes of one-stage reconstruction for chronic multiligament injuries of knee. *Knee Surg Relat Res* 2021;33(1):3
4. Ramanath SK, Shah RH, Rajan AV, Patil S. Hinged Total Knee Replacement for an Arthritic Knee Following a Neglected Knee Dislocation: A Case Report. *J Orthop Case Rep* 2020;10(6):68-71
5. Jabalameli M, Bagherifard A, Hadi H, Askari A, Ghaffari S. Total Knee Arthroplasty for Chronic Anterior Knee Dislocation. *Clin Med Insights Case Rep* 2018;111179547618782882
6. Ozturkmen Y, Akman YE, Unkar EA, Sukur E. Total joint replacement for neglected posterior knee dislocation following septic arthritis after arthroscopy. *Acta Orthop Traumatol Turc* 2017;51(4):347-351
7. Rodriguez-Merchan EC. Total knee arthroplasty using hinge joints: Indications and results. *EFORT Open Rev* 2019;4(4):121-132
8. Kohn MD, Sassoon AA, Fernando ND. Classifications in Brief: Kellgren-Lawrence Classification of Osteoarthritis. *Clin Orthop Relat Res* 2016;474(8):1886-1893

9. Schenck RC, Jr., Richter DL, Wascher DC. Knee Dislocations: Lessons Learned From 20-Year Follow-up. *Orthop J Sports Med* 2014;2(5):2325967114534387
10. Bohl DD, Wetters NG, Del Gaizo DJ, et al. Repair of Intraoperative Injury to the Medial Collateral Ligament During Primary Total Knee Arthroplasty. *J Bone Joint Surg Am* 2016;98(1):35-39
11. Malotin T, Matejka T, Matejka J. [Diagnosis, Treatment and Complications of Knee Dislocation: a Retrospective Study]. *Acta Chir Orthop Traumatol Cech* 2021;88(2):107-116
12. Yeoh M, Athalye-Jape G. Congenital knee dislocation: a rare and unexpected finding. *BMJ Case Rep* 2021;14(1):e234881
13. Citak M, Ansorge C, Klattke TO, et al. [Non-traumatic anterior knee dislocation in a patient with osteoarthritis of the knee]. *Z Orthop Unfall* 2013;151(2):138-141
14. Kooner S, Gibson E, Clark M. Periprosthetic total knee fracture after remote reconstruction of the anterior cruciate ligament: a case report. *J Med Case Rep* 2017;11(1):276
15. Putman S, Argenson JN, Bonneville P, et al. Ten-year survival and complications of total knee arthroplasty for osteoarthritis secondary to trauma or surgery: A French multicentre study of 263 patients. *Orthop Traumatol Surg Res* 2018;104(2):161-164

Figures

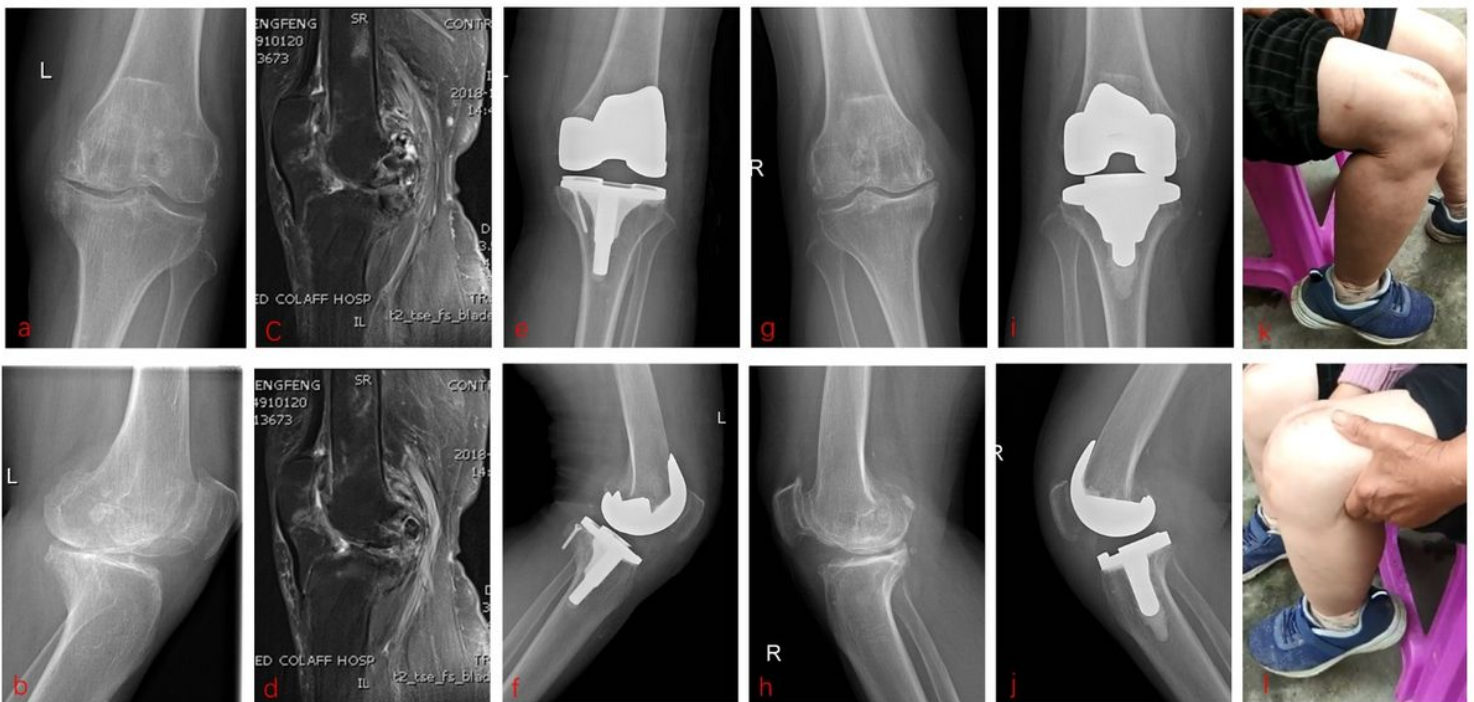

Figure 1

a-d The preoperative radiographs in case 1 show end-stage OA in the left knee joint, and MRI shows ACL and PCL tears. e-f Postoperative knee radiographs show good alignment. g-h The preoperative radiographs in case 1 show end-stage OA in the right knee joint. i-j Postoperative radiographs of the right

knee joint show good alignment. K Flexion of the right knee at the time of the latest follow-up. I Flexion of the left knee at the time of the latest follow-up.

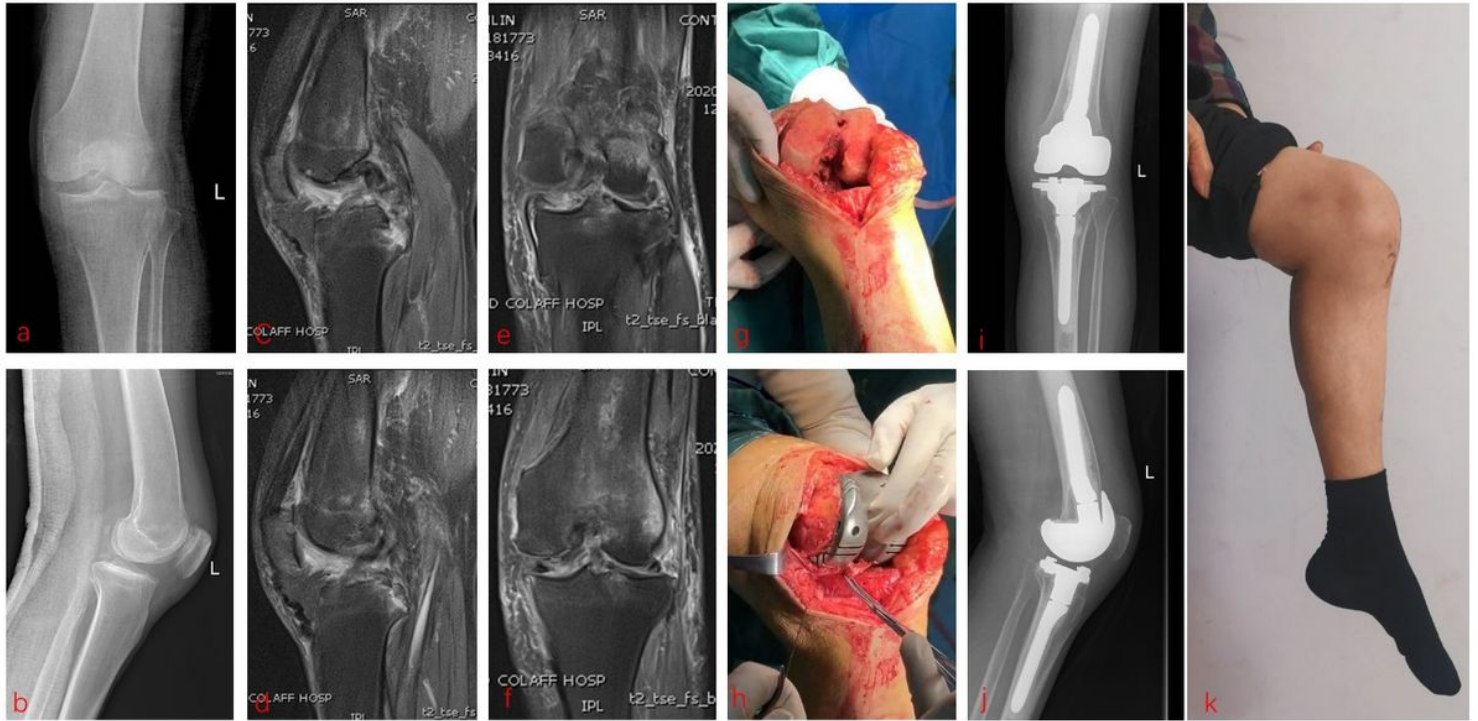


Figure 2

a-f The preoperative radiographs in case 2 show severe OA and subluxation of the left knee joint. MRI shows ACL, PCL, and MCL tears as well as peri-knee soft tissue and femoral marrow oedema. g-h Intraoperative images show an MCL tear, gap imbalance and knee instability. i-j Postoperative radiographs of the right knee joint show good alignment.