

Supplementary Materials

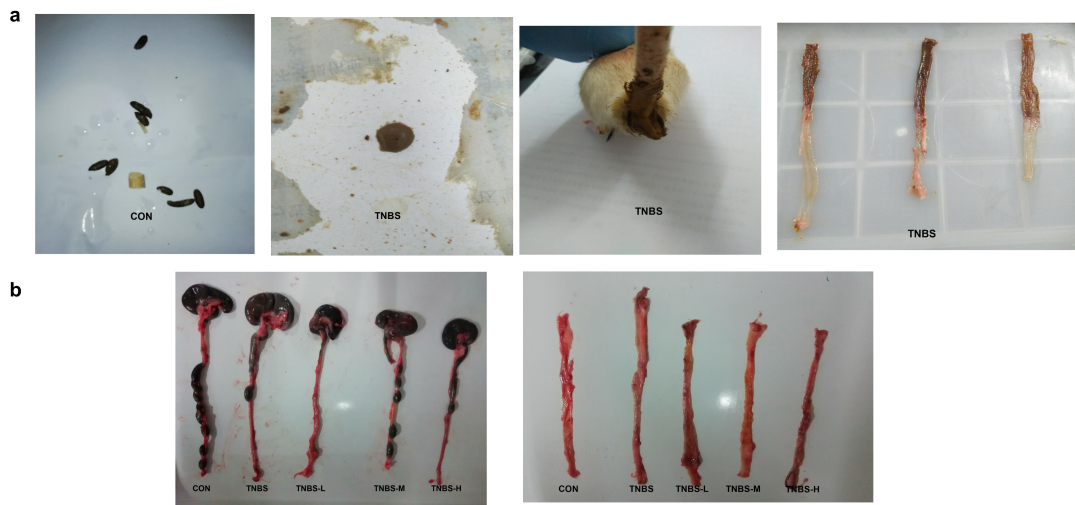


Fig. S1 Changes of colonic tissues and defecation. **a** defecation and lesions of colon in TNBS-induced rats. **b** changes of colonic tissues in each group after SLBZS treatment.