

Epidemiology and clinico-pathological characteristics of current goat pox outbreak in North Vietnam

Trang Pham Hong

Vietnam National University of Agriculture

Mohd Azmi Mohd Lila

Universiti Putra Malaysia

Nor Yasmin Abd. Rahaman

Universiti Putra Malaysia

Huong Lai Thi Lan

Vietnam National University of Agriculture

Lan Nguyen Thi

Vietnam National University of Agriculture

Khien Do Van

IVRD

Mohamed Mustapha Noordin (✉ noordinmm@upm.edu.my)

University Putra Malaysia <https://orcid.org/0000-0001-9288-797X>

Research article

Keywords: North Vietnam, goat pox, epidemiology, pathology, industry

Posted Date: December 9th, 2019

DOI: <https://doi.org/10.21203/rs.2.18170/v1>

License: © ⓘ This work is licensed under a Creative Commons Attribution 4.0 International License. [Read Full License](#)

Abstract

Background In view of the current swine fever outbreak and the government aspiration to increase the goat population, a need arises to control and prevent industry decimating outbreaks goat pox. Despite North Vietnam facing sporadic cases of goat pox, this most recent outbreak had the highest recorded morbidity, mortality and case fatality rate. Thus, owing to the fear that such outbreak may recur and become widespread, an analysis of that outbreak was done based on selected signalment, management and disease pattern (signs and pathology) parameters.

Results It was found that the susceptible age group were between 3-6 months old kids while higher infection rate occurred in those under the free-range rearing system. The clinical signs and lesions were not restricted to the skin but have extended into the lung and intestine. The pathogen had been confirmed in positive cases via PCR as goat pox with prevalence of almost 80%.

Conclusions The current outbreak of goat pox in North Vietnam denotes its significance to the industry and signals the importance of a prompt identification which will lead to an effective control of the disease.

Background

The re-emerging of Capripoxvirus and its affection has been well documented worldwide especially in Asia and Africa [1–2]. Undoubtedly, this virus bears pronounced economic impact not only to endemic regions especially to the livelihoods of small-scale farmers and poor rural communities [3] but also posed major constraint in international livestock trade. Much more worrying is its expansion to many countries including Vietnam in 2005 [4] which is in the midst of developing a competitive goat industry. The first reported North Vietnam occurrence of goat pox outbreak in 2005 has led to 789 deaths in four provinces i.e, Cao Bang, Bac Giang, Lang Son and Ha Tay. The agents confirmed via ELISA and PCR yielded that the isolate was host specific being severe in goats [4]. Following this incidence, the outbreak has been resolved leading to an annual increase of 38% in Vietnam goat population from 1.8 million heads in 2015 to 2.6 million heads in 2017 [5]. Owing to the Vietnamese government aspiration to produce 3.9 million heads of goats in 2020, a much more comprehensive study on devastating disease like the epidemio-economical impact of goat pox is warranted. Nevertheless, despite the increase in goat population, goat pox outbreak has recurred commencing from 2014 in Ninh Binh province. This recurrence has raised concern on the possible devastating impact of goat pox on Vietnam's goat industry which forms the basis of this study. A thorough analysis of current recurrence along with a complete set of epidemiological data will confer an effective root cause control and prevention of new outbreaks.

Results

Observation of the farms

None of the farms either intensive or extensive system practices vaccination against goat pox. The main goat rearing methods in North Vietnam includes backyard where the goats are freely grazing in midland and mountainous areas with minimal provision of commercial feed and intensive farming in whereby the goats are kept in stalls and supplemented with concentrates.

Morbidity rate

The morbidity and mortality rates due to goat pox is shown in Table 1. During this study, the first case of sick goats was reported in Ninh Binh province which then radiated to other parts of North Vietnam. Thus, the study commenced in Ninh Binh and radiated out to its five other surrounding provinces. The morbidity rate ranged between 11.8–17.5% without significant differences between all provinces except for Yen Bai which has the lowest rate ($p<0.000$). However, this lowest rate at Yen Bai was comparable to that of Hoa Binh.

Mortality and case fatality rate of goat pox outbreak

Table 2 shows the case fatality rate of goats due to the infection during the study period. The mortality and case fatality rate ranges between 5.1–7.4% and 35.3–63%, respectively without any significant differences between provinces.

Infection rate between farming system

It was found that goats under the extensive system has a higher ($p<0.05$) infection rate than those managed intensively (Table 3).

Age susceptibility

In order to examine the influence of age to infection rate, the goats were into categorized into three groups, viz; less than 3; 3–6 months and more than 6 months old. The analysis of age susceptibility to infection is shown in Table 4. It was found that at almost all instances, those between the ages of 3–6 months were most susceptible ($p<0.001$) except at Ninh Bin province. The other age groups of less than 3 and more than 6 months have comparable infection rate.

Clinical and pathology findings

Goats showed varying degrees of clinical signs severity, however, almost 85% of infected goats showed loss of appetite, anorexia to completely refusal of feed leading to emaciation. Fatigue and pyrexia were also among common manifestations observed in most cases. Additionally, blepharitis, rhinitis (Figure 1) and difficulty to move ensued in some cases.

Hardened swelling which developed into sores were found on the skin (mainly hairless regions) over any part of the body including the mouth, pinna (Figure 2) and udder (Figures 3–4). The size of the pock lesions varies between 0.5–1 cm in diameter.

The finding of lesions ante- and post mortem is presented in Table 5. In live animals, majority of lesions are confined to the eyes, nares and skin while that of post mortem revealed the lungs (Figure 5) as a primary site. Calcified greyish papules were found in the intestines (Figure 6), urinary bladder and uterus. However, other less frequently sites and tissues were also affected as shown in Table 5.

Histopathological lesions comprising of cellular degeneration and necrosis along with inflammation and haemorrhage were mostly found in skin (Figure 7), lung and liver. Despite exhaustive histopathology search, no evidence of eosinophilic inclusions were seen in any tissues.

PCR

The PCR primer specific test was performed on 128 scab biopsy samples. An almost 80% (102/128) of the samples were positive to capripox virus within the expected size band of 172 bp (Figure 8).

Discussion

Reported outbreaks of goat pox worldwide yields differing mortality rates with 7% in Sudan [2], 21% in Iraq [6] and 30% in India [7]. In this study, a much lower mortality rate was found despite a rather high morbidity rate high probably owing to the study population comprising less of the 3–6 months old goats. It has been shown that maternal antibody for goat pox is maintained for about 3 months and those older than 6 months that survived an infection will have life-long immunity [8–9]. This phenomenon explains the susceptibility of those in the 3–6 months old [9] which should yield higher morbidity rate. However, since the group of animals under this group is quite low, the mortality rate has failed to surpass those of other groups.

The number of death animal during the outbreak depends on the virus virulence, size of the population and their susceptibility and on the basic reproductive number [10]. However, these rates may vary depending additional factors including breed [11] and the most notably the herd immune status [12]. Recently published data showed that case fatality rate of goatpox disease ranged from 21.4 % to 60 % [13–15]. Likewise, the high fatality rate in the present study undermined the need for a much more effective control of goat pox along with the requirement to vaccinate at least susceptible herd or in endemic areas. However, the difficulty to implement such health programs in Vietnam is explained below.

Based on seroprevalence, [16] reported a morbidity rate in nomadic goat herds in Punjab to be about 23%. It is not surprising to see a higher infection rate in the extensive system as previously reported [11]. Unfortunately, this rearing method is popular to poor farmers in midland and mountainous areas in Vietnam who could not afford to spend on a standard health management. Goats under the extensive system forage freely in a wide area exposing them increase chances to be exposed to the virus. These goats might have also been exposed to lesser domestication, maintaining many of the behavioural traits of the wild types such as aggressiveness [17–18]. Furthermore, goats especially under the extensive system being naturally aggressive [17] predisposes the body to injuries making easier access of the virus when inoculated. This is an added problem since most of the goats were not dehorned (due to financial constraints) making injuries prone to infection during a fight. On the contrary, the low infection rate under the intensive system is due to a much proper disease control program that has minimized spread of the virus within the herd.

Undoubtedly, defining the vulnerable period of infection is one of the most important measurement to be known for an effective disease management [19]. In the study presented here, the most susceptible age were goats of 3–6 months old which conforms to findings of [16] and [20] who found that the chance of infection chance in the young was 2.2 times greater than that of an adult. However, contradictory results were seen if infection rate was based on seroprevalence. Fentie *et al.* [20] demonstrated a low infection rate in older animals although this appeared to refute earlier published findings [21]. Nevertheless, in the latter study [21], age groups were not clearly

defined which may have led to a less homogenous groupings. Additionally, the collected samples from slaughter house, tanneries and hide markets where the likelihood of the proportion of kids to be devoid [21]. The age grouping the study presented here was based on the main purpose of meat goat breeding in Vietnam. The indigenous and mixed breed of Vietnamese goat attained a market weight of 25 to 30 kilograms at 6 months old age, justifying a 3 month interval being chosen.

Recognising the key salient clinical signs is key factor for field diagnosis of goat pox [11]. The foremost marked as seen in this study too were depression and being much more severe in kids [22–23] accounting for systemic signs of pyrexia. About 85% of affected animals showed varying degrees of anorexia associated with the development of lesions on mucus membrane of the face. The lesion commences as red patches around the mouth, nose and eyes which later swelling into a papule. These papules trigger lacrimal, nasal and saliva discharges. Respiratory distress and secondary bacterial pneumonia are predominant in kids which could not survival malignant stage [6, 24–25]. In adult goats, the ulceration of papules renders difficulty for digestive and breathing activities which in turn worsen productive performance. There are goats with conjunctivitis, corneal opacity and blepharitis had been recorded which animals emulated the acute phase pox disease [4]. The development of pox lesions is observed over the animal body especially hairless areas (face, pinna of the ears, udder, genital, anus, under the tail). The red patches turn to hard rubbery papules and become vesicles after 3 to 4 days. Necrotic papules formed pustular as the result of thrombosis and localised ischaemia. Dark hard scabs are formed by the remnant of necrotic papules [6; 25–27].

In this study, for all positive cases, the clinical and post mortem lesions were 100% present in the skin and lungs of affected goats. It is likely that owing to the epitheliotropic nature of the virus lesions were predominantly seen in the skin, lung and discrete sites within mucosal surfaces of oro-nasal and gastrointestinal tissues [4]. As evidenced in this study and as reported earlier in similar studies, the role of skin and lung as a target organ [28] for the virus leads to much more deposition of the lesion in these tissues [29–30]. Beside darkened circumscribed pox lesions [29, 31], the entire lung are pale pink with loss of sponginess. Congested trachea contain blood or fluid-filled vesicles with involvement of the lymph nodes. As seen in the study presented here, calcified nodules are found the most abundant in large intestine (rectum) of goats that were mildly affected [21,32].

Histopathological findings in the study presented here were in accord to previous publications registering marked change in the epidermis. The degeneration of epithelial cells, hyperkeratosis, ballooning and degeneration of proliferating epithelial cells along with inflammation led to the desquamation of skin layers. Variable observation of lung microscopy include haemorrhage, congestion and thickening alveoli wall which resulted in narrowed alveoli. Secondary bacterial infection has invoked infiltration of inflammatory cells to affected regions of the lung [6, 33–34].

The PCR-based test is chosen regarding to its sensitivity and simplicity [35]. The sensitive and simple PCR assay has confirmed caprine pox virus in the biopsy samples [36]. Almost 80% of the samples were positive with amplicon size of 172 bp although no attempt was made to identify and differentiate of caprine pox virus [1, 22, 37–38]. However, the isolates from this study did not show much variation compared to those reported in China [39].

These findings boils down to the possibility of Vietnam's aspiration to transform the future potential of goat farming into an industry. The local consumer prefers fresh chevon than frozen products due to food safety issues

linked to the weakness of their cold chain system [40]. Furthermore, goats apart from being a form of meat for the family and community it serves as a cash reserve for the poor farmer [41].

The current study also revealed most of the goat husbandry system is mainly extensive which may hamper the possibility to initiate goat production outside the mountainous areas. Likewise, as unveiled here, goats reared under the intensive system offers a better farming milieu for disease control which the farmer or nation should adopt to improve productivity. Nevertheless, nation should make formidable reforms to the livestock industry since goats in Vietnam are still (as found in this study) and in future will be reared by the poorer farmers halting an increase in goat population and productivity. This is even much more worrying especially with respect to a lack of herd health program (disease control). Thus, in order to bring the industry to greater heights, offsetting devastating disease like goat pox is mandatory. It is believed that these findings on goat pox will facilitate the government to continue working on improving disease identification and control to avoid hindrance in goat production.

Conclusions: Goat pox infection in North Vietnam if left unattended may lead to devastating effect to the goat industry. Thus, needs arises not only to effectively control the disease but also to downregulate risks factors involved including that of current state of rearing.

Materials And Methods

Ethics, consent, questionnaire and study area

Since North Vietnam does not impose ethics on the use of local animals for research, all procedures involving in this study were conducted in compliance to the recommendations of the Guide for the Care and Use of Agricultural Animals in Research and Teaching (2010) [42]. A well-defined questionnaire composed of farm management information (total number of animals/age groups, breed, farming system and detailed health status) relevant to goat pox were noted during the visit and all participating farms consented the research via a written permission.

The sample size (n) was determined using the formula:

$$n = Z^2pq/L$$

where, Z = standard normal distribution at 95% confidence interval = 1.96

= prevalence of similar work (Babiuk 2008) = 33%

$$q = p - 1$$

L = allowable error taken at 5% = 0.05

Thus, the minimum required sample size obtained from the formula for this study was 477.

Disease investigation had been conducted in six provinces in North Vietnam where goat farming is most actively conducted. In general, goat farming in Vietnam is mainly divided into either extensive or intensive system as previously described [43]. During the visit, farms with clinically affected goats and those in close contact with the herd within outbreak provinces were further assessed. A thorough physical examination of clinical signs was done with emphasis on predilection site of goat pox lesions and animals with severe clinical signs were then post mortem.

Questionnaire and data collection

The questionnaire was structured to encompass information of the farm, management system practiced by the owner during an interview. It is compartmentalised to contain three main sections namely; ownership and farm information, herd information and physical plus pathology findings. The template of this questionnaire is attached separately as an additional file.

Tissue sampling

Based on the physical examination, a total of 11,688 goats that falls under the category of being affected or those in contact were chosen. Out of these, 1481 had clear cut signs suggestive of goat pox whereby fresh tissue samples totaling to 128 were collected for further pathology and virology diagnoses.

Approximately 2–3 grams of lesions were taken and placed in PBS (7.2 pH with 1% gentamycin) and stored under chilled conditions during delivery. Samples were then transferred to Key Veterinary Biotechnology Laboratory, Vietnam National University of Agriculture, Hanoi, Vietnam. Roughly a 1 cm³ lesion the of skin, lung, heart, liver, intestine, spleen, kidney and lymph node were fixed in 10% buffered formalin and later processed using routinely for histopathological examination.

Polymerase chain of reaction (PCR)

DNA extraction was performed using DNeasy Blood Tissue Kit (Qiagen, Gemany) following manufacturer instruction. Primers used for identifying Capripoxvirus in clinical specimens as previously designed [35].

The forward primer was P1: 5'-TTTCCTGATTTTCTTACTAT-3' and the reverse primer was P2: 5'-AAATTATATACGTAAATAAC-3'. 50 l of reaction mixture contained 5 l buffer, 3 l of MgCl₂, 2 l of dNTP mix (10mM), 2 l (10 pmol/l) of each primer, 0.4 l of Taq-DNA, 12 l biopsy supernatant and 23.6 l of RNase free water. PCR cycle started with initial denaturation at 94⁰C for 5 mins, followed with 35 cycles (1 min each) of denaturation at 94⁰C, annealing at 50⁰C, extension at 72⁰C and final extension at 72⁰C for 10 mins. The PCR products were examined by 1.5% agarose gel electrophoresis with ethidium bromide staining.

Data analysis

All data obtained was subjected to statistical analysis using the SAS 9.0 (2002), USA and only differences of p<0.005 were considered as significant.

Declarations

Abbreviations

bp: base pair; PBS: phosphate buffered saline; PCR: polymerase chain reaction; OD = odds ratio; CI = confidence interval; n = number of animals; Chisq: Chi Square test

Ethics approval and consent to participate

All procedures involving in this study were conducted in compliance to the recommendations of the Guide for the Care and Use of Agricultural Animals in Research and Teaching (2010) [42] since North Vietnam does have an official documentation on research ethics and such requirements are simultaneously done by grant provider during vetting of the proposal (Veterinary Ordinance 2004; <https://thuvienphapluat.vn/van-ban/the-thao-y-te/Phap-lenh-Thu-y-2004-18-2004-PL-UBTVQH11-52096.aspx>). The farms have also given their consent for the usage of their facilities and animals during the study.

Consent for publication

Not applicable

Availability of data and materials

The datasets generated and/or used during the current study are not available to public as it is owned by the Vietnam National University of Agriculture, Vietnam. However, these can be requested via email from the corresponding author Prof. Mustapha M Noordin (noordinmm@upm.edu.my).

Competing interests

The authors declare that they have no competing interests.

Funding

This study was funded by Ministry of Education and Training, Vietnam which the authors gratefully appreciate. The funding body fully supported this project commencing from the study design (including ethical requirement as stated above), collection, analysis and interpretation of the data.

Authors' contributions

PHT, HLTH, LNT and KDV conceived the research grant; PHT and NMM analysed and interpreted the results; PHT and NMM drafted the manuscript with contribution from all authors; NMM, MAML, NYAR revised the manuscript; NMM and MAML supervised running of the project. All authors read and approved the final manuscript.

Acknowledgements

The authors wish to extend their thanks to thank all staff of Faculty of Veterinary Medicine, Vietnam National University of Agriculture, Vietnam who have participated in the collection of epidemiology data and analysis of samples for the study. We would like to acknowledge deepest gratitude to the farm owners who have unselfishly cooperated in making the study a success.

Author details

¹Faculty of Veterinary Medicine, Universiti Putra Malaysia, Selangor, 43400 Serdang, Malaysia

²Faculty of Veterinary Medicine, Vietnam National University of Agriculture, Gia-Lam District, Hanoi 010000, Vietnam

³Institute of Veterinary Research and Development of Central Vietnam, Nha Trang, Khanh Hoa 650000, Vietnam

References

1. Santhamani R, Yogisharadhya R, Venkatesan G, Shivachadra SB, Pandey AB, Ramakrishnan MA. Detection and differentiation of sheeppox virus and goatpox virus from clinical sample using 30 kDa RNA polymerase subunit (RPO30) gene based PCR. Vet World, 2013; EISSN: 2231-0916
2. Ahmed ZEM, Abdelmalik IK and Muaz MA. An epidemiological study of sheep and goat pox outbreaks in the Sudan. Food Biology 2016; doi: 10.19071/fbiol.2016.v5.3007.
3. Tuppurainen ESM, Venter EH, Shisler JL, Gari G, Mekonnen GA, Juleff N, Lyons NA, Clercq KDe, Upton C, Bowden TR, Babiuk S, Babiuk Review: Capripoxvirus Diseases: current status and opportunities for control. Transbound Emerg Dis. 2017; doi: 10.1111/tbed.12444
4. Babiuk S, Bowden TR, Boyle DB, Wallace DB, Kitching RP. Capripoxviruses: An emerging worldwide threat to sheep, goats and cattle. Transbound Emerg Dis. 2008; 55: 263-272
5. Liang JB, Paengkoum Current status, challenges and the way forward for dairy goat production in Asia – conference summary of dairy goats in Asia. Asian-Australasian J Anim Sci. 2019; doi: <https://doi.org/10.5713/ajas.19.0272>
6. Zangana IK, Abdullah MA. Epidemiological, clinical and histopathological studies of lamb and kid pox in Duhok, Iraq. Bulg. J. Vet. Med. 2013; 16:133-138.
7. Roy A, Jaisree S, Balakrishnan S, Senthilkumar K, Mahaprabhu R, Mishra A, Maity B, Ghosh TK, Karmakar AP. Molecular epidemiology of goat pox viruses. Transbound Emerg Dis. 2018; doi: 10.1111/tbed.12763
8. Panchanathan V, Chaudhri G, Karupiah G. Correlates of protective immunity in poxvirus infection: Where does antibody stand? Immunol Cell Biol. 2008; 86: 80-86.

9. Bhanuprakash, V, Hosamani M, Venkatesan, G, Balamurugan V, Yogisharadhya R, Singh RK. Animal poxvirus vaccines: A comprehensive review. *Expert Rev. Vaccines* 2012; 11: 1355-1374
10. Bhanuprakash V, Hosamani M, Singh RK. Prospects of control and eradication of Capripox from the Indian subcontinent: A perspective. *Antiviral Res.* 2011; 91: 225-232.
11. Mizaie K, Barani SM, Bokaie S. A review of sheep pox and goat pox: perspective of their control and eradication in Iran. *J. Adv. Vet. Anim. Res.*, 2015; doi: 10.5455/javar.2015.b117.
12. Abutarbush, S.M. "Lumpy skin disease". *Emerging and re-emerging infectious diseases of livestock*. Ed. Jagadeesh Bayry. Springer, 2017; 321-322. doi: 10.1007/978-3-319-47426-7.
13. Venkatesan G, Balamurugan V, Singh RK, Bhanuprakash V. Goat pox virus isolated from an outbreak at Akola, Maharashtra (India) phylogenetically related to Chinese strain. *Trop Anim Health and Prod.* 2010; <https://doi.org/10.1007/s11250-010-9564-8>.
14. Youwen L, Haihong J, Jianjun H. Identification of four goatpox outbreaks in Xinjiang of China. *Human Health and Biomedical Engineering (HHBE) 2011 International Conference*. doi: 10.1109/HHBE.2011.6028993.
15. Jayalakshmi K, Yogeshpriya S, Veeraselvam M, Krishnakumar S, Selvaraj P. Univariable risk factors analysis of goat pox in Thanjavur Delta region. *Indian Vet. J.*, 2017; 94 (11): 19-20.
16. Masoud F, Mahmood MS, Hussain I. Seroepidemiology of goat pox disease in District Layyah, Punjab, Pakistan. *J Vet Med Res* 2016; 3:1043.
17. Côté SD. Dominance hierarchies in female mountain goats: stability, aggressiveness and determinants of rank. *Behaviour*; 2005; 137:1541–1566.
18. Mignon-Grasteau S, Boissy A, Bouix, J, Faure J-M, Fisher AD, Hinch GN, Jensen P, Neindre, P.Le., Mormede P, Prunet P, Vandeputte M, Beaumont C. Genetics of adaptation and domestication in livestock. *Livest Prod*

19. Darbon A, Colombi D, Valdano E, Savini L, Giovanni A, Colizza V. Disease persistence on temporal contact networks accounting for heterogeneous infectious periods. Soc. Open Sci. 2019; <https://doi.org/10.1098/rsos.181404>.
20. Fentie T, Fenta N, Leta S, Molla W, Ayele B, Teshome, Y, Nigatu S, Assefa A. Sero-prevalence, risk factors and distribution of sheep and goat pox in Amhara region, Ethiopia. BMC Veterinary Research, 2017; doi: 10.1186/s12917-017-1312-0.
21. Sajid A, Chaudhary I, Sadique U, Maqbol A, Anjum AA, Queshi MS, Hassan ZU, Idress M, Shaid M. Prevalence of goatpox disease in Punjab province of Pakistan. J Anim Plt Sci. 2012; 22 (2 Suppl.). Page: 28-32. ISSN: 1018-7081.
22. Rao TVS, Negi BS, Bansal MP. Identification and characterization of differentiating soluble antigens of sheep and goat poxviruses. Acta Virologica, 1996; 40:259-262.
23. Das, P.K. and Pradhan, K.C. 2006. Epidemiological studies on goatpox in Ganjam goats of Orissa. Indian J. Vet. Med., 26: 34-35.
24. Joshi RK, Ali SL, Shakya S, Rao VN. Clinico-Epidemiological studies on a natural outbreak of goat pox in Madhya Pradesh. Indian Vet J. 1999; 76: 279-281.
25. Pawaiya RVS, Bhagwan SK, Dubey SC. Histo-pathological study of goat pox in a natural outbreak. Indian J. Small Ruminants, 2008; 14: 266-270.
26. Babuik S, Bowden TR, Parkyn G, Dalman B, Hoa, DM, Long NT, Vu PP, Bieu DX, Copps J, Boyle DB. Yemen and Vietnam Capripoxviruses demonstrate a distinct host preference for goats compared with sheep. J Gen Virol, 2009; doi: 10.1099/vir.0.004507-0.
27. Manjunatha-Reddy GB, Sumana K, Babu S, Yadav J, Balamuragan V, Hemadri D, Patil SS, Suresh KP, Gajendragad MR, Rahman H. Pathological and molecular characterization of Capripox virus outbreak in sheep

and goats in Karnataka. Indian J Vet Path., 2015; 39:11-14.

28. Embury-Hyatt C, Babiuk S, Manning L, Ganske S, Bowden TR, Boyle Pathology and Viral Antigen Distribution following Experimental Infection of Sheep and Goats with Capripoxvirus J Comp. Path., 2012; 146: 106-115 <https://doi.org/10.1016/j.jcpa.2011.12.001>.
29. Jun WL, Zhang HT, Wang F, Cheng JJ, Hong-Ying SI. Clinical diagnosis technique of goat pox diseases. Agric Sci Technol., 2010; 11(7): 91-9.
30. Kumar A, Hirpurkar SD, Sannat C, Gilhare, VR. Adaptation of Capripox virus isolate from goats in heterologous cells. J Anim Res. 2015; doi: 10.5958/2277-940X.2015.00113.8.
31. Verma S, Verma LK, Gupta VK, Katoch VC, Dogra V, Pal B, Sharma M. Emerging Capripoxvirus disease outbreak in Himachal Pradesh, a Northern state of India. Transbound Emerg Dis., 2011; 58: 79-85.
32. Kumar J, Gupta VK. Pathological study of goat pox in a natural outbreak. Indian Vet J. 2015; 92(4):70-71.
33. Nyadolgor U, Usuhgerel S, Baatarjargal P, Altanchimeg A, Odbile R. Histopathological study for using of pox inactivated vaccine in goats. J Agric Sci. 2015; 15:51-55.
34. Manimaran K, Mahaprabhu R, Jaisree S, Hemalatha S, Ravimurugan T, Pazhanivel N, Roy P. An outbreak of sheep pox in an organized farm of Tamil Nadu, India. Indian J Anim Res. 2017; 51:162-164.
35. Ireland DC, Binepal YS. Improved detection of capripoxvirus in biopsy samples by PCR. Journal of Virological Methods, 1998; 74: 1-7.
36. Heine HG, Stevens MP, Foord AJ, Boyle DB. A capripoxvirus detection PCR and antibody ELISA based on the major antigen P32, the homolog of the vaccinia virus H3L gene. J. Immunol. Methods, 1999; 227: 187-196.

37. Mahmoud, MA, Khafagi MH. Detection, identification and differentiation of sheep pox virus and goat pox virus from clinical cases in Giza Governorate, Egypt. Vet World, 2016; EISSN: 2231-0916.
38. Zhao Z, Wu G, Yan X, Zhu X, Li J, Zhu H, Zhang Z, Zhang Development of duplex PCR for differential detection of goat pox and sheep pox viruses. BMC Vet Res. 2017;13: 278. DOI: 10.1186/s12917-017-1179-0.
39. Zeng XC, Chi XL, Wenbo WL, Li HM, Huang XH, Huang YF, Rock, Luo SH, Wang SH. Complete genome sequence analysis of goatpox virus isolated from China shows high variation. Vet Microbiol 2014; 173: 38-49 <https://doi.org/10.1016/j.vetmic.2014.07.013>.
40. Nguyen-Viet H, Tuyet-Hanh TT, Unger F, Dang-Xuan S, Grace, D. Food safety in Vietnam: where we are at and what we can learn from international experiences. Infect Dis Poverty; 2017; <https://doi.org/10.1186/s40249-017-0249-7>.
41. Anonymous (2013). Agricultural Transformation & Food Security 2040—Vietnam Country Report, Japan International Cooperation Agency, http://open_jicareport.jica.go.jp/pdf/12145546.pdf Accessed 20 June 2019.
42. Federation of Animal Science Societies (FASS), 3rd Edition: Guide for the Care and Use of Agricultural Animals in Research and Teaching. <http://www.fass.org> (2010). Accessed on 22 January 2019.
43. Devendra C. Dynamics of Goat Meat Production in Extensive Systems in Asia: Improvement of Productivity and Transformation of Livelihoods. Agrotechnol 2015; doi:10.4172/2168-9881.1000131.

Tables

Table 1 Morbidity rate of goatpox outbreak in North Vietnam

Province	n	Morbidity (%)	<i>p-value</i>	OR	95 % CI	
Bac Giang	2350	17.5 ^a	0.000	1	-	-
Ha Noi	1295	15.7 ^a		0.87	0.72	1.04
Hoa Binh	1954	13.9 ^{a,b}		0.76	0.64	0.90
Nghe An	1798	17.1 ^a		0.97	0.83	1.14
Ninh Binh	2435	16.5 ^a		0.92	0.79	1.07
Yen Bai	1856	11.8 ^b		0.63	0.53	0.75

OR: odds ratio; 95 % CI: confidence interval

Values within column bearing similar superscript do not differ at $p < 0.000$

Table 2 Mortality and case fatality rate of goat pox disease in North Vietnam

Province	No. of affected goat	No. of death	Mortality (%)	Case fatality rate (%)
Bac Giang	411	145	6.17	35.28
Ha Noi	203	74	5.17	36.45
Hoa Binh	227	125	6.40	45.95
Ninh Binh	401	151	6.20	37.66
Nghe An	308	131	7.28	42.53
Yen Bai	219	138	7.44	63.01
Grand Total	1814	764	6.54	42.12

Table 3 Comparison of goat pox incidence based on rearing method

Method	n	Unaffected (%)	Affected (%)	<i>p-value</i>	OR	95 % CI	
Extensive	4729	83.7	16.3	0.040	1	-	-
Intensive	6959	85.0	15.0		0.90	0.81	1.00

OR: odds ratio; 95 % CI: confidence interval

Table 4 The infection rate based on age groups

Province	Total	< 3 months			3 -6 months			> 6 months			Chisq	p-value
		n	Affected	Infection rate (%)	n	Affected	Infection rate (%)	N	Affected	Infection rate (%)		
Bac Giang	2350	545	86	15.8 ^a	608	167	27.5 ^b	1197	158	13.2 ^a	58.31	0.000
Ha Noi	1295	315	45	14.3 ^a	305	72	23.6 ^b	675	86	12.7 ^a	19.37	0.000
Hoa Binh	1954	528	64	12.1 ^a	352	91	25.8 ^b	1074	117	10.9 ^a	51.46	0.000
Ninh Binh	2435	587	93	15.8 ^a	623	173	27.8 ^b	1225	135	11.0 ^a	84.43	0.000
Nghe An	1798	404	63	15.6 ^a	441	119	27.0 ^b	953	126	13.2 ^a	41.09	0.000
Yen Bai	1856	419	41	9.8 ^a	492	98	19.9 ^a	945	80	8.5 ^a	42.89	0.000
Total	11688	2798	392		2821	720		6069	702			

Values between columns bearing similar superscript do not differ at $p < 0.000$

n = number of animals

Table 5 Lesions distribution in selected organs and their frequency of appearance (n = 128)

Organ	Lesions	n	%
Eyes	Hyperemia, corneal opacity, papules on the eyelids	128	100
Nose	Thickened and ulcerated papules on the nasum	128	100
Skin	Papules scattered over the body	128	100
Trachea	Blood/fluid-filled vesicles	85	66.4
Lung	Inflammation and necrosis	128	100
Heart	Pale and flabby	52	40.6
Intestine	Calcified papules	64	50
Bladder	Papules	28	21.9
Uterus	Papules	22	17.2
Mesenteric	Necrosis	88	68.8
Lymph Node			

Figures

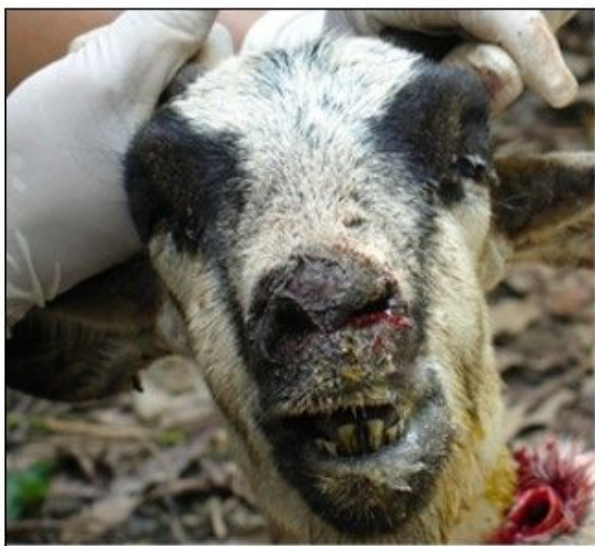

Fig.1 Photograph showing ulcers in nasal cavity and rhinitis.

Figure 1

Photograph showing ulcers in nasal cavity and rhinitis.

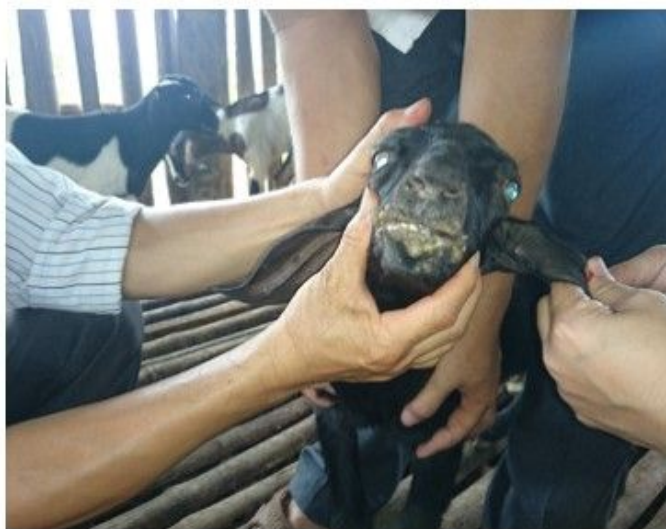

Fig. 2 Photograph exhibiting papules found on mouth, nares and ear.

Figure 2

Photograph exhibiting papules found on mouth, nares and ear.

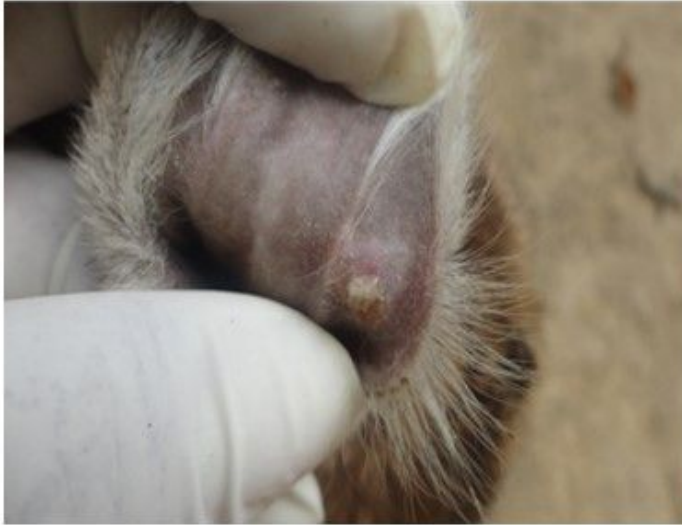

Fig. 3 Photograph showing a papule that has ulcerated on the ear pinna.

Figure 3

Photograph showing a papule that has ulcerated on the ear pinna.

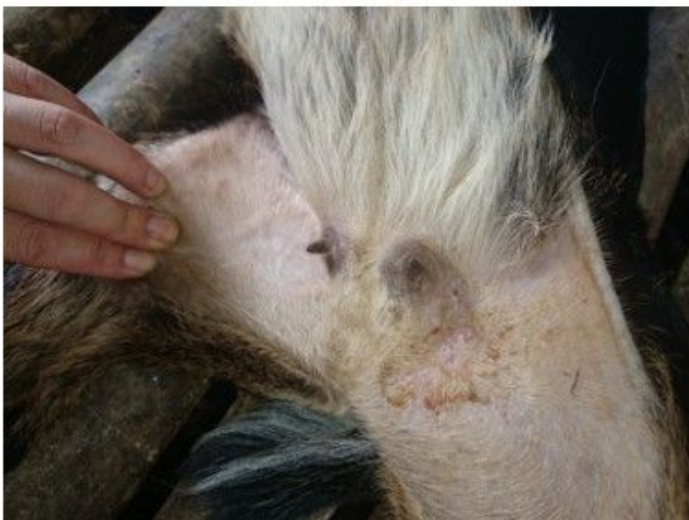

Fig. 4 Photograph of infected goat's udder denoting ulcers and inflammation.

Figure 4

Photograph of infected goat's udder denoting ulcers and inflammation.

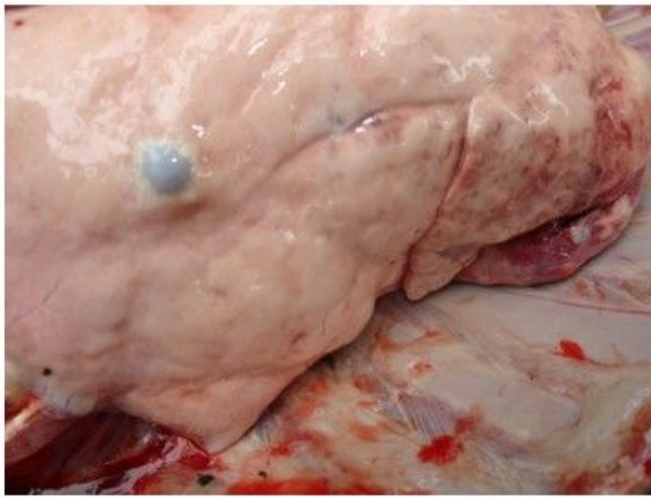

Fig. 5 Photograph of a well-circumscribed greyish pock lesion in the lung of an infected goat

Figure 5

Photograph of a well-circumscribed greyish pock lesion in the lung of an infected goat

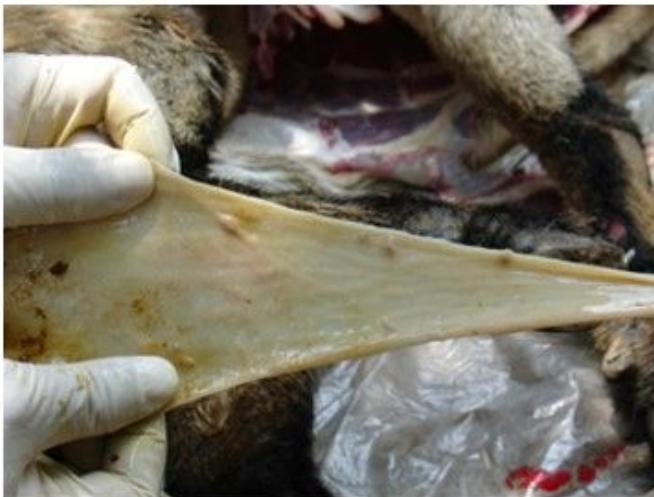

Fig. 6 Photograph of calcified papules on the intestinal mucosa of an affected goat.

Figure 6

Photograph of calcified papules on the intestinal mucosa of an affected goat.

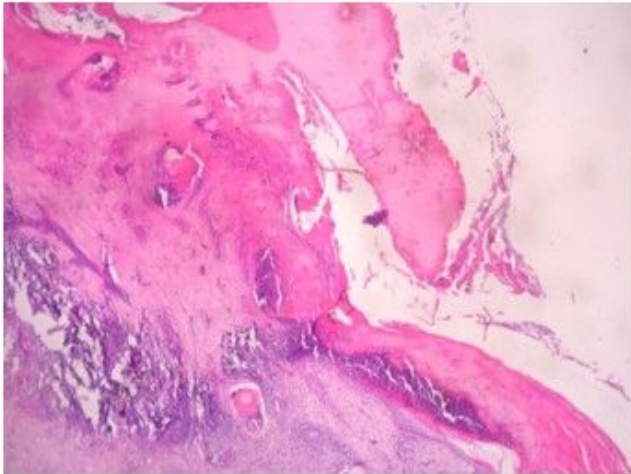


Fig. 7 Damaged epithelial layers of skin of an infected goat (H&E, X10)

Figure 7

Damaged epithelial layers of skin of an infected goat (H&E, X10)

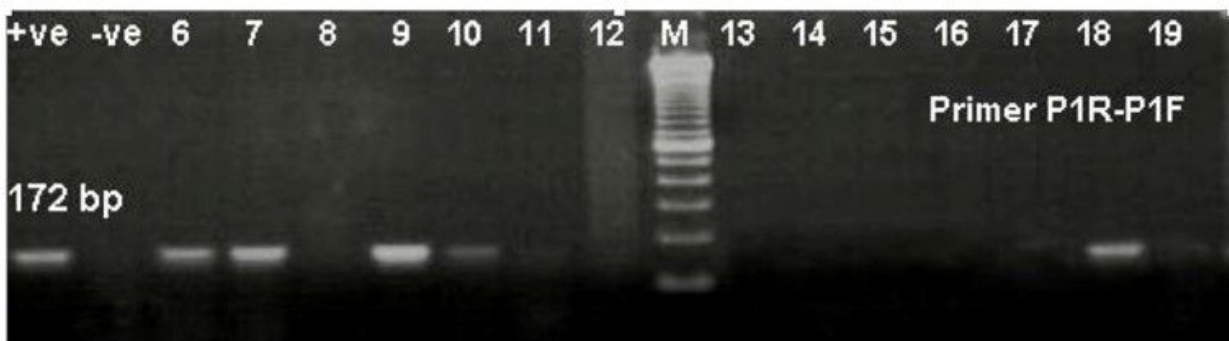


Fig. 8 PCRA gene based PCR result for detection of capripox virus. Lane M: 100 bp ladder

Figure 8

Supplementary Files

This is a list of supplementary files associated with this preprint. Click to download.

- [Questionnaire.docx](#)