

# Short-term changes in and preoperative factors affecting vaulting after posterior chamber phakic Implantable Collamer Lens implantation

Qiujian Zhu

Lixiang Eye Hospital of Soochow University <https://orcid.org/0000-0002-2794-2319>

Wen-Jing Chen

Lixiang Eye Hospital of Soochow University

Wei-Jian Zhu

Lixiang Eye Hospital of Soochow University

Hai-Xiang Xiao

Lixiang Eye Hospital of Soochow University

Man-Hui Zhu

Lixiang eye hospital of Soochow university

Lie Ma

Lixiang Eye Hospital of Soochow University

You Yuan (✉ [yuanyou@suda.edu.cn](mailto:yuanyou@suda.edu.cn))

Lixiang Eye Hospital of Soochow University <https://orcid.org/0000-0002-5701-904X>

E. Song

Lixiang Eye Hospital of Soochow University

---

## Research article

**Keywords:** ICL implantation, vault, sulcus to sulcus, crystalline lens thickness, prediction

**Posted Date:** October 8th, 2020

**DOI:** <https://doi.org/10.21203/rs.3.rs-86662/v1>

**License:** © ⓘ This work is licensed under a Creative Commons Attribution 4.0 International License.

[Read Full License](#)

---

**Version of Record:** A version of this preprint was published at BMC Ophthalmology on May 6th, 2021. See the published version at <https://doi.org/10.1186/s12886-021-01963-x>.

# Abstract

**Background:** To describe the very early changes in vault in the first month after Implantable Collamer Lens (ICL) implantation and to evaluate the effect of preoperative biometric factors on vault.

**Methods:** A total of 83 eyes from 83 subjects with complete data who met follow-up requirements were recruited in this retrospective study between May 2019 and March 2020. We quantitatively assessed postoperative vault at 2 hours, 1 day, 1 week, and 1 month following implantation. Associations between postoperative vault and age, ICL size, spherical equivalent (SE), axial length (AL), central corneal thickness (CCT), flat K, steep K, mean K, anterior chamber depth (ACD), crystalline lens thickness (LT), white-to-white (WTW) diameter obtained by three devices, horizontal and vertical sulcus-to-sulcus (STS) diameter, bright and dark pupil sizes (BPS and DPS) and DPS-BPS were investigated using Spearman's correlation analysis and stepwise multiple regression analysis.

**Results:** The mean vault values at 2 hours, 1 day, 1 week, and 1 month after ICL implantation were  $672.05 \pm 30.72$ ,  $389.15 \pm 28.33$ ,  $517.23 \pm 30.76$  and  $530.12 \pm 30.22$   $\mu\text{m}$ , respectively. There were significant differences in vault values between 2 hours, 1 day and 1 week after the operation. ICL size ( $\beta = 0.942$ ;  $p < 0.001$ ), followed by horizontal STS ( $\beta = -0.517$ ;  $p < 0.001$ ), crystalline LT ( $\beta = -0.376$ ;  $p < 0.001$ ) and vertical STS ( $\beta = -0.257$ ;  $p = 0.017$ ), significantly influenced vault at 1 month after the operation. The multiple regression equation was expressed as follows: central vault ( $\mu\text{m}$ ) =  $-1369.05 + 657.121 \times \text{ICL size} - 287.408 \times \text{horizontal STS} - 432.497 \times \text{crystalline LT} - 137.33 \times \text{vertical STS}$  (adjusted  $R^2 = 0.643$ ).

**Conclusions:** After ICL implantation, vault decreased and then increased, but it did not return to the vault value at 2 hours after surgery. ICL size, horizontal and vertical STS and crystalline LT were key factors for predicting postoperative vaulting.

## Background

The Implantable Collamer Lens (ICL; STAAR Surgical Co, Monrovia, California) is a safe and effective option for the correction of myopia [1–4]. With no corneal excision and few high-order aberrations, it is often the first choice for surgical correction of high myopia [5, 6]. Although ICL implantation offers outstanding benefits, postoperative complications have been reported, and most of these complications were associated with vault (distance between the posterior ICL surface and anterior crystalline lens surface) inappropriateness [7, 8]. Low vault may lead to mechanical contact with the lens or inadequate aqueous humour circulation, which accounts for the high incidence of anterior capsular opacity and cataract formation [9, 10]. Conversely, high vault can cause excessive mechanical contact between the ICL and iris, leading to inflammation and increased intraocular pressure [11, 12]. In addition, the occurrence of pigment dispersion syndrome, iris atrophy, and acute angle-closure glaucoma has also been associated with high vault [13–15].

Many factors can influence vault after ICL implantation. Lee et al. [16] found that horizontal compression of the ciliary sulcus is a key factor in the formation of vault, but it could not effectively predict vault.

Trancon et al. [17] and Zeng et al. [18] believed that the anatomy of the crystalline lens can affect vaulting after surgery. In addition, many studies have found that changes in pupil size are closely associated with changes in vaulting [19–21]. Unfortunately, there are not enough studies to integrate these factors to predict postoperative vaulting.

Very early changes in vaulting, which are often used in contralateral eye surgery strategies, are often ignored by researchers. Therefore, the present study reveals the early change process in vaulting through observations from 2 hours to 1 month after ICL implantation and establishes preoperative biometric factors that may contribute to vault formation and allow us to predict vaulting.

## Methods

### Study design and participants

This retrospective study was approved by the Lixiang Eye Hospital of Soochow University Institutional Review Board and adhered to the tenets of the Declaration of Helsinki. All patients were examined, treated and followed at the refractive surgery centre of Lixiang Eye Hospital between May 2019 and March 2020. A total of 83 eyes from 83 subjects with complete data were recruited for this study. Informed consent was obtained from each subject before surgery.

Inclusion criteria for this study included patients aged 18–45 years, patients with myopia between  $-0.50$  and  $-21.00$  DS, patients with astigmatism between  $0$  and  $-6.00$  DC, patients with an anterior chamber depth (ACD) equal to or greater than  $2.80$  mm, and patients with an endothelial cell density greater than  $2000$  cells/mm<sup>2</sup>. None of the patients had ciliary body cysts, obvious cataracts, glaucoma or retinal disease history, or systemic diseases. One eye was randomly selected for binocular surgery, and the eye of monocular surgery was the recruiting eye.

### Preoperative examination

All patients underwent complete ophthalmic examinations, including uncorrected and corrected distance visual acuity evaluation, slit-lamp microscopy, tonometry (noncontact tonometer; NT-530, Nidek Co., Ltd., Aichi, Japan), and fundus examination by a three-mirror lens. Refractive dioptre was measured with a standard phoropter and converted into spherical equivalent (SE), which was calculated as half of the original spherical dioptre plus astigmatism. Flat K, steep K, mean K, central corneal thickness (CCT) and ACD were obtained by a Scheimpflug camera (Pentacam, Oculus, Germany). The bright and dark pupil sizes (BPS and DPS) were measured by an OPD-Scan III device (Nidek Technologies, Gamagori, Japan). Axial length (AL) and crystalline lens thickness (LT) were obtained with an IOLMaster 700 (Carl Zeiss Meditec AG, Jena, Germany). Ultrasound biomicroscopy (UBM) equipped with a 50 MHz transducer was performed to measure the horizontal and vertical sulcus-to-sulcus (STS) diameter after instillation of proparacaine (Alcaine; Alcon, Fort Worth, TX, USA). Horizontal corneal diameter and white-to-white distance (WTW) measurements were conducted with a Pentacam, OPD-Scan III device and IOLMaster 700.

All examinations were performed in a room with constant temperature and humidity controlled by an air conditioning system. Phoropter, Pentacam and OPD-Scan III examinations were conducted in the darkroom, and all other examinations were conducted under standard room lighting conditions. Each test was performed by the same experienced physician or technician.

### **Surgical procedure**

ICL implantation followed a standard procedure and was performed by the same experienced surgeon (You Yuan, corresponding author). After topical anaesthesia (proxymetacaine hydrochloride, Nanjing, China) was applied and hyaluronic acid (Shanghai, China) was injected into the anterior chamber via a 3.0-mm temporal corneal incision using an injector cartridge, an ICL V4c model (VICMO or VTICMO) was implanted and then placed in the posterior chamber. Next, the hyaluronic acid was completely removed from the eye using a manual I/A instrument. All surgeries were uneventful, and no intraoperative complications were observed. Following surgery, tobramycin 0.3% dexamethasone 0.1% eye drops (Tobradex, Alcon, USA) were administered four times daily for the first 5 days; dosages were decreased every 5 days. The power calculations for the ICL were performed according to the manufacturer's guidelines using a modified vertex formula [22]. All ICLs were placed at 10° horizontally, and only four sizes (12.1, 12.6, 13.2, and 13.7 mm) were available.

### **Follow-up**

All subjects underwent vault measurements with a Pentacam at 2 hours, 1 day, 1 week and 1 month after ICL implantation. The patient placed their chin on the chin rest and their forehead against the forehead strap and was asked to open both eyes and fixate on the blue fixation target in the centre of the black background. Fifteen Scheimpflug image enhancement models were used to obtain anterior segment images. Image quality was checked using the quality factor value for each eye. Two experienced technicians who were blinded to the treatment groups independently measured the centre vault value in the Pentacam Scheimpflug image using the device's built-in image analyser. The vault measurement was centred on the optical axis and appeared as a white dashed line on the screen. Each technician obtained three measurements, which were averaged. If the difference between the two technicians was less than 30 µm, the average value of the six measurements was included in the analysis, and if the difference value was equal to or more than 30 µm, the measurements were repeated until the difference was less than 30 µm.

### **Statistical analysis**

Data analysis was performed using SPSS 18.0 (IBM Corp., New York, NY, USA). The Kolmogorov-Smirnov test was performed for all measurement data. Data with a normal distribution were expressed as means  $\pm$  standard deviations (SDs); otherwise, data were expressed as medians and quartiles. Repeated measures analysis of variance was used to calculate the change in vault, and post hoc comparisons among time points were performed using Bonferroni correction. A paired sample t test was used to assess the correlation between postoperative vault at 2 hours and 1 day and postoperative vault at 1 month. Spearman's correlation analysis and stepwise multiple regression analysis were used to examine associations between 1-month ICL vaulting and the other variables. The independent variables included

age, ICL size, SE, AL, CCT, flat K, steep K, mean K, ACD, LT, WTW obtained by three devices, horizontal and vertical STS, BPS, DPS, and DPS-BPS. A p-value of less than 0.05 was considered significant.

## Results

The average age of the subjects was  $27.21 \pm 5.07$  (range 18 to 38) years, and 32.53% (27/83) of the subjects were male. Table 1 summarizes the baseline clinical characteristics of the 83 eyes and descriptive data for preoperative variables.

Table 1  
Baseline clinical characteristics of the study eyes (83 eyes)

Characteristics	Mean $\pm$ SD	Range
Age, years	27.21 $\pm$ 5.07	18 to 38
Sex (male/female)	27/56	
Laterality (right/left)	43/40	
Refractive errors (D)		
Spherical	-7.48 $\pm$ 3.11	-1.25 to -15.75
Cylindrical	-1.80 $\pm$ 0.94	0 to -5.0
Spherical equivalent	-8.36 $\pm$ 3.18	-2 to -17
Keratometric value (D)		
Flat K	42.72 $\pm$ 1.59	38.5 to 46.5
Steep K	44.59 $\pm$ 1.93	39.9 to 49.2
Mean K	43.69 $\pm$ 1.72	39.5 to 47.8
STS diameter (mm)		
Vertical	11.93 $\pm$ 0.52	10.64 to 13.30
Horizontal	11.51 $\pm$ 0.49	10.25 to 12.96
IOP (mm Hg)	13.98 $\pm$ 3.06	7.30 to 21.00
AL (mm)	26.83 $\pm$ 1.30	23.93 to 29.73
ACD (mm)	3.38 $\pm$ 0.27	2.80 to 3.76
WTW diameter (mm)		
Pentacam	11.65 $\pm$ 0.38	10.8 to 12.9
OPD-Scan III	11.86 $\pm$ 0.44	10.77 to 13.26
IOLMaster 700	12.01 $\pm$ 0.38	11.2 to 13.3
Pupil size (mm)		
Bright	3.53 $\pm$ 0.59	2.39 to 5.11
Dark	6.37 $\pm$ 1.06	3.94 to 8.56
Dark-bright	2.84 $\pm$ 0.77	0.90 to 4.60

STS = sulcus-to-sulcus; WTW = white-to-white; IOP = intraocular pressure; ACD = anterior chamber depth.

Characteristics	Mean $\pm$ SD	Range
ICL size (12.1/12.6/13.2/13.7)	7/38/35/3	
Crystalline LT (mm)	3.70 $\pm$ 0.24	3.11 to 4.22
CCT (mm)	525.22 $\pm$ 32.62	458 to 589
STS = sulcus-to-sulcus; WTW = white-to-white; IOP = intraocular pressure; ACD = anterior chamber depth.		

Table 2 shows the repeated measures analysis of variance results of vault at each time point after ICL implantation. Vault was 672.05  $\pm$  30.72  $\mu$ m at 2 hours after surgery; decreased to 389.15  $\pm$  28.33  $\mu$ m at 1 day then increased to 517.23  $\pm$  30.76  $\mu$ m at 1 week after surgery. There was no significant difference in vault between 1 week and 1 month after surgery. Figure 1 and Fig. 2 shows vault changes within one month after ICL implantation.

Table 2  
Repeated measures analysis of variance of vault at each time point after ICL implantation

	2 hours	1 day	1 week	1 month	P value
Vault ( $\mu$ m)	672.05 $\pm$ 30.72	389.15 $\pm$ 28.33	517.23 $\pm$ 30.76	530.12 $\pm$ 30.22	$\leq$ 0.001
P value	Ref.	$\leq$ 0.001	$\leq$ 0.001	$\leq$ 0.001	
		Ref.	$\leq$ 0.001	$\leq$ 0.001	
			Ref.	0.448	

The paired sample correlation between vault values at 2 hours and 1 month after surgery was 0.879 ( $p < 0.001$ ) and that between vault values at 1 day and 1 month after surgery was 0.823 ( $p < 0.001$ ). The paired difference between vault values at 2 hours and 1 month after surgery was 141.93  $\pm$  136.66 (95% confidence interval [CI] 112.09, 171.77;  $p < 0.001$ ) and between 1 day and 1 month after surgery was -140.96  $\pm$  159.36 (95% CI -175.76, -106.17;  $p < 0.001$ ).

According to Spearman's correlation analysis, vault at 1 month after surgery was positively correlated with ACD, WTW and ICL size and negatively correlated with crystalline LT, as shown in Table 3 (all  $p < 0.05$ ). Table 3 also shows the results of the stepwise multivariate regression analysis. The explanatory variables relevant to vaulting were crystalline LT (standardized partial regression coefficient [ $\beta$ ] = -0.376;  $p < 0.001$ ), ICL size ( $\beta$  = 0.942;  $p < 0.001$ ), horizontal STS ( $\beta$  = -0.517;  $p < 0.001$ ) and vertical STS ( $\beta$  = -0.257;  $p = 0.017$ ). The multiple regression equation was expressed as follows: central vault ( $\mu$ m) = -1369.05 + 657.121  $\times$  ICL size - 287.408  $\times$  horizontal STS - 432.497  $\times$  crystalline LT - 137.33  $\times$  vertical STS. The R, R<sup>2</sup> and adjusted R<sup>2</sup> of the model were 0.814, 0.660 and 0.643, respectively. Figure 2 shows that the prediction formula has excellent prediction accuracy.





Table 3

Spearman's correlation analysis and stepwise multiple regression analysis between 1-month ICL vault and other variables

Variables	Spearman's correlation		Multivariable analysis (constant=-1369.05, R = 0.813, R <sup>2</sup> = 0.660, adjusted R <sup>2</sup> = 0.643)		
	r	P value	Partial regression coefficient (B)	Standardized partial regression coefficient (β)	P value
Age	-0.313	0.004			
SE	0.019	0.861			
Keratometric value					
Flat K	0.147	0.185			
Steep K	0.070	0.531			
Mean K	0.133	0.232			
STS					
Vertical	-0.140	0.206	-137.330	-0.257	0.017
Horizontal	0.060	0.592	-287.408	-0.517	0.001
IOP	-0.157	0.156			
AL	0.001	0.990			
ACD	0.261	0.017			
WTW diameter					
Pentacam	0.288	0.008			
OPD-Scan III	0.242	0.028			
IOLMaster 700	0.255	0.020			
Pupil size					
Bright	0.103	0.353			
Dark	0.140	0.207			
Dark-bright	0.129	0.246			
ICL size	0.450	0.001	657.121	0.942	0.001

STS = sulcus-to-sulcus; WTW = white-to-white; IOP = intraocular pressure; ACD = anterior chamber depth.

	Spearman's correlation		Multivariable analysis (constant=-1369.05, R = 0.813, R <sup>2</sup> = 0.660, adjusted R <sup>2</sup> = 0.643)		
Crystalline lens thickness	-0.603	0.001	-432.497	-0.376	0.001
Central corneal thickness	-0.201	0.068			
STS = sulcus-to-sulcus; WTW = white-to-white; IOP = intraocular pressure; ACD = anterior chamber depth.					

## Discussion

Over 120,000 ICL implantation surgeries are performed in over 60 countries annually, which makes vault, an indicator of postoperative safety, particularly important [23]. In the current study, we aimed to assess the early changes in ICL vault in the first month, starting at 2 hours after implantation of the ICL. We analysed preoperative variables, including patient age, ICL size, SE, AL, CCT, flat K, steep K, mean K, ACD, crystalline LT, WTW obtained by three devices, horizontal and vertical STS, BPS and DPS and their difference, to identify factors that influenced or may be used to predict postoperative ICL vault.

Our results demonstrated a significant decrease in vault postoperatively from 2 hours to 1 day after implantation, which then increased from 1 day to 1 week; at 1 month after surgery, vault was still lower than that 2 hours after surgery. Since most surgeons tend to perform ICL implantation at different times, early vault after surgery is the reference for the ICL size selection for the contralateral eye. However, few studies have described changes in vault within 24 hours after surgery. According to the paired sample t test, vault at both 2 hours and 1 day after surgery had a good correlation with vault at 1 month after surgery, but vault at 1 month after surgery was lower than that at 2 hours and higher than that at 1 day after surgery. We speculated that residual viscoelastic agent played a critical role in the relatively high vault value at 2 hours after surgery, as vault then decreased with the removal of the viscoelastic agent by aqueous humour circulation. Garcia-Feijoo et al. [24] demonstrated that ICL haptics were usually ultimately located in the ciliary sulcus or ciliary body, while Choi et al. [25] demonstrated that 64.7% of phakic IOL haptics were fixated in the ciliary sulcus. However, by analysing the full-scale UBM of 134 eyes, Zhang et al. [26] found that the ICL haptics in most cases were not in the ciliary sulcus and that different haptic positions had a significant influence on postoperative vaulting. For example, the eyes with haptics on the top of the ciliary sulcus were likely to have a high vault value, while those with one haptic on the ciliary process and another haptic in the ciliary body tended to have a low vault value. We speculated that the change in the position of haptics may also be a reason for the change in vault after surgery. In addition, previous studies have shown that changes in pupil size were associated with postoperative vaulting [27–30]. Lee et al. [19] believed that pupil constriction creates anteroposterior vectors through iris constriction, which exerts pressure on the ICL. Because the V4C ICL has a central hole,

pressure equilibrium is quickly achieved between the front and rear surfaces of the ICL, facilitating this process (the fountain effect of “aquaport”). In other words, a net effect of placing the ICL closer to the lens was created, followed by a reduction in central vault. Recently, Kato et al. [20] and Gonzalez-Lopez et al. [31] demonstrated that ICL vault can be significantly decreased by light-induced pupil constriction. Therefore, we speculated that pupil constriction due to the disappearance of the effect of the mydriatic agent played a very important role in vault reduction within 1 day after surgery. Finally, several studies have proven that the morphology of the crystalline lens also has an influence on vault after ICL implantation [32–34]. ICL vault was affected by changes in crystalline lens rise (CLR) caused by accommodation or light condition changes [20, 35, 36]. We hypothesized that the morphological changes in the crystalline lens caused by accommodation after surgery may also be a reason for decreased vault. Regarding the change from 1 day to 1 month after surgery, our results were highly consistent with those in the study by Chen and colleagues, who believed that changes in the pupil size and the position of haptics were the main reasons for the results [21].

According to our results, vault value at 1 month after surgery was positively correlated with ACD, WTW and ICL size and negatively correlated with crystalline LT. However, we believe that such results are of little clinical significance because ICL size was an important factor affecting postoperative vaulting. In our study, ICL size was not a continuous variable, so it had a significant impact on the results of Spearman’s correlation analysis. We are confident in the results of the multivariate analysis. We found that ICL size, followed by horizontal STS, crystalline LT and vertical STS, significantly influenced 1-month postoperative vaulting. Previous studies have shown that the ciliary sulcus is vertically oval [37–39]. Since the ICL has a flat plate design and a certain width, the supporting points of the lens are located between the horizontal and vertical ciliary sulcus but closer to the horizontal position. Therefore, the influence of horizontal STS distance on postoperative vaulting is greater than that of vertical STS (standardized partial regression coefficient – 0.517 vs. -0.257). As described previously, the morphology of the crystalline lens has a certain influence on vaulting after ICL implantation. Most recent studies have focused on the effect of CLR on vaulting after surgery [31, 34–36, 40]. However, the measurement of CLR is relatively complex. Qi et al. [41] demonstrated that the crystalline LT had an important influence on postoperative vault, which is highly consistent with our results, and crystalline LT can be easily obtained by an IOLMaster 700. There may be a correlation between CLR and crystalline LT, which needs to be further verified in subsequent studies. Our regression formula used crystalline LT as one of the independent variables, which had a very high degree of fitting (the  $R$ ,  $R^2$  and adjusted  $R^2$  of the model were 0.814, 0.660 and 0.643, respectively), indicating that crystalline LT is an excellent predictive variable. Our results also showed that pupil size can influence postoperative vault, but vault cannot be predicted by preoperative pupil size, including BPS, DPS or the difference between the two.

Conventionally, the manufacturer’s recommendation for ICL size refers to only two parameters: WTW and ACD (Visian ICL Product Information: Visian ICL For Myopia. Available at [http://www.accessdata.fda.gov/cdrh\\_docs/pdf3/p030016c.pdf](http://www.accessdata.fda.gov/cdrh_docs/pdf3/p030016c.pdf)). According to our results, neither WTW measured by any instrument nor ACD was a reliable predictor of postoperative vaulting, which was also

the consensus of many similar studies [34, 35, 42]. Lee et al. [19] obtained the following regression formula after multivariate linear regression analysis of 236 patients with 12.6-mm crystal implantation: central vault ( $\mu\text{m}$ ) =  $-0.784 + (0.171 \times \text{preoperative ACD}) + (0.038 \times \text{preoperative pupil size}) + (0.017 \times \text{preoperative AL})$ . Unfortunately, the fitting degree of this formula was very low ( $R^2 = 0.144$ ), only one size of ICL was included in this study, and the axial direction of ICL placement was not considered, which would affect the results. Chen et al. [21] developed the following regression formula in their study: ICL V4 central vault ( $\mu\text{m}$ ) =  $(386.51 \times \text{ACD}) - 718.77$ , ICL V4c central vault ( $\mu\text{m}$ ) =  $(503.43 \times \text{ACD}) - 1075.64$ . Similarly, the low fitting degree (adjusted  $R^2 = 0.320$  and  $0.297$ ) and the small sample size (38 eyes for the V4 group and 39 eyes for the V4c group) make the results unsatisfactory. Recently, Igarashi et al. [42] developed a relatively good prediction formula on the basis of the angle-to-angle (ATA) measurement: postoperative vault (mm) =  $660.9 \times (\text{ICL size [mm]} - \text{ATA [mm]}) + 86.6$ . However, the fitting degree of the adjusted  $R^2$  ( $0.41$ ) was still not completely satisfactory. The NK formula developed by Nakamura et al. [34, 43] is probably the most accurate prediction formula so far. The formula considers the distance between scleral spurs (ACW) and CLR as independent variables, and the  $R^2$  of the multiple regression was  $0.68$  and the adjusted  $R^2$  was  $0.666$ . In subsequent validation, moderate vault was achieved in  $92.1\%$  of cases by the application of the formula [43]. The regression formula in this study has some similarities with the NK formula. For example, they have similar fitting degrees (adjusted  $R^2$  of  $0.666$  vs.  $0.643$ ), CLR and crystalline LT both describe the morphology of the lens, and the distance between scleral spurs and horizontal and vertical STS describe the anatomical morphology of the posterior chamber. In addition, the sample size of our study was larger (83 eyes vs. 46 eyes) than theirs, and the crystalline LT was easier to measure. To identify the presence of ciliary body cysts, UBM is an important preoperative examination before ICL implantation [18, 44]. Therefore, our formula can be applied conveniently, without an additional anterior segment OCT examination.

There are certain limitations in this study. First, although the sample size was larger than those in some similar studies, it still needs to be supplemented in subsequent studies. Second, we only developed the prediction formula, and verification of the formula still needs to be carried out. We will release our verification work for the first time. Finally, our study was conducted among only Han Chinese, and further study is needed to determine whether ethnic differences will have an impact on the results.

## Conclusions

In summary, we described very early changes in ICL vault in the first month, starting at 2 hours after ICL implantation, and we found that ICL size, followed by horizontal STS, crystalline LT and vertical STS, significantly influenced vault 1 month after surgery. It is hoped that our findings and new formulas will be helpful for surgeons when choosing the appropriate ICL size.

## List Of Abbreviations

ICL: Implantable Collamer Lens; STS: sulcus to sulcus; WTW: white to white; IOP: intraocular pressure; ACD: anterior chamber depth; BPS: bright pupil size; DPS: Dark pupil size

## Declarations

### *Ethics approval and consent to participate*

The study was approved by the Lixiang Eye Hospital of Soochow University Institutional Review Board

### *Consent for publication*

Not applicable.

### *Availability of data and materials*

All data are fully available without restriction.

### *Competing interests*

The authors declare that they have no competing interests

### *Funding*

Jiangsu Provincial Natural Science Foundation Project [BK20191177]; Jiangsu Distinguished Medical Experts Program (No.2016)

### *Authors' contributions*

QJZ analyzed and interpreted the patient data and wrote the paper; WJC, WJZ and HXX collected data and conducted the examinations; MHZ and LM checked and revise the paper; YY and ES designed the study and performed the surgery.

### *Acknowledgements*

We thank Dr. Chen qing and Dr. Yu peng for their help in patient management

## References

1. Niu L, Miao H, Han T, Ding L, Wang X, Zhou X. Visual outcomes of Visian ICL implantation for high myopia in patients with shallow anterior chamber depth. BMC Ophthalmol. 2019;19:121.
2. Nakamura T, Isogai N, Kojima T, Yoshida Y, Sugiyama Y. Posterior Chamber Phakic Intraocular Lens implantation for the correction of myopia and myopic astigmatism: a retrospective 10-year follow-up study. Am J Ophthalmol. 2019;206:1-10.

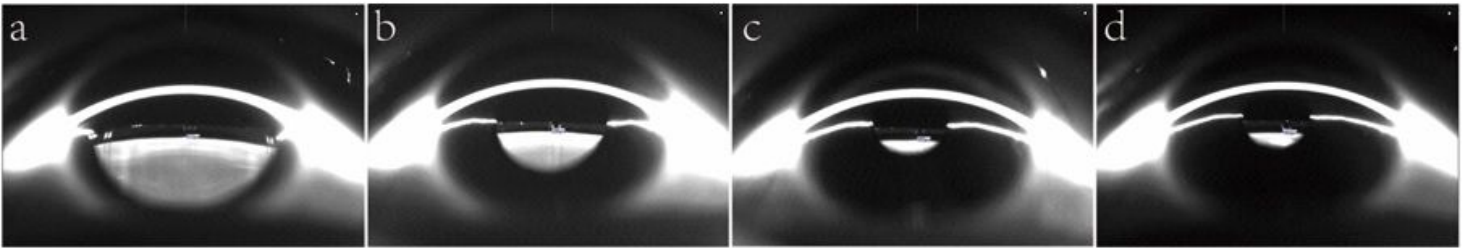
3. Alfonso JF, Fernandez-Vega-Cueto L, Alfonso-Bartolozzi B, Montes-Mico R, Fernandez-Vega L. Five-year follow-up of correction of myopia: posterior chamber phakic intraocular lens with a central port design. *J Refract Surg.* 2019;35:169-76.
4. Vasavada V, Srivastava S, Vasavada SA, Sudhalkar A, Vasavada AR, Vasavada VA. Safety and efficacy of a new phakic posterior chamber IOL for Correction of myopia: 3 years of follow-up. *J Refract Surg.* 2018;34:817-23.
5. Eissa S, Badr Eldin N. ICL versus SMILE in management of anisometropic myopic amblyopia in children. *Can J Ophthalmol.* 2018;53:560-7.
6. Niu L, Miao H, Tian M, Fu D, Wang X, Zhou X. One-year visual outcomes and optical quality of femtosecond laser small incision lenticule extraction and Visian Implantable Collamer Lens (ICL V4c) implantation for high myopia. *Acta Ophthalmol.* 2020; doi:10.1111/aos.14344.
7. Fernandes P, Gonzalez-Mejome JM, Madrid-Costa D, Ferrer-Blasco T, Jorge J, Montes-Mico R. Implantable Collamer Posterior Chamber Intraocular Lenses: a review of potential complications. *J Refract Surg.* 2011;27:765-76.
8. Matarazzo F, Day AC, Fernandez-Vega Cueto L, Maurino V. Vertical implantable collamer lens (ICL) rotation for the management of high vault due to lens oversizing. *Int Ophthalmol.* 2018;38:2689-92.
9. Gimbel HV, LeClair BM, Jabo B, Marzouk H. Incidence of implantable Collamer lens-induced cataract. *Can J Ophthalmol.* 2018;53:518-22.
10. Guber I, Mouvet V, Bergin C, Perritaz S, Othenin-Girard P, Majo F. Clinical outcomes and cataract formation rates in eyes 10 years after posterior phakic lens implantation for myopia. *JAMA Ophthalmol.* 2016;134:487-94.
11. Alfonso JF, Lisa C, Abdelhamid A, Fernandes P, Jorge J, Montes-Mico R. Three-year follow-up of subjective vault following myopic implantable collamer lens implantation. *Graefes Arch Clin Exp Ophthalmol.* 2010;248:1827-35.
12. Repplinger B, Kohnen T. Intraocular pressure after implantation of an ICL with aquaport. Development of intraocular pressure after implantation of an ICL (model V4c) with aquaport without iridotomy. *Ophthalmologe.* 2018;115:29-33.
13. Chun YS, Park IK, Lee HI, Lee JH, Kim JC. Iris and trabecular meshwork pigment changes after posterior chamber phakic intraocular lens implantation. *J Cataract Refract Surg.* 2006;32:1452-8.
14. Ye C, Patel CK, Momont AC, Liu Y. Advanced pigment dispersion glaucoma secondary to phakic intraocular collamer lens implant. *Am J Ophthalmol.* 2018;10:65-7.
15. Shipper I. Surgical management of acute angle-closure glaucoma after implantation of a toric ICL. *J Cataract Refract Surg.* 2007;33:563-4.
16. Lee DH, Choi SH, Chung ES, Chung TY. Correlation between preoperative biometry and posterior chamber phakic Visian Implantable Collamer Lens vaulting. *Ophthalmology.* 2012;119:272-7.
17. Trancon AS, Manito SC, Sierra OT, Baptista AM, Serra PM. Determining vault size in Implantable Collamer Lenses (ICL): preoperative anatomy and lens parameters. *J Cataract Refract Surg.* 2020;46:728-36.

18. Zeng Q-Y, Xie X-L, Chen Q. Prevention and management of collagen copolymer phakic intraocular lens exchange: causes and surgical techniques. *J Cataract Refract Surg.* 2015;41:576-84.
19. Lee H, Kang DSY, Choi JY, Ha BJ, Kim EK, Seo KY, et al. Analysis of pre-operative factors affecting range of optimal vaulting after implantation of 12.6-mm V4c implantable collamer lens in myopic eyes. *BMC Ophthalmol.* 2018;18:163.
20. Kato S, Shimizu K, Igarashi A. Vault changes caused by light-induced pupil constriction and accommodation in eyes with an implantable collamer lens. *Cornea.* 2019;38:217-20.
21. Chen X, Miao H, Naidu RK, Wang X, Zhou X. Comparison of early changes in and factors affecting vault following posterior chamber phakic Implantable Collamer Lens implantation without and with a central hole (ICL V4 and ICL V4c). *BMC Ophthalmol.* 2016;16:161.
22. Vukich JA, Sanders DR, Barnett R, Dulaney D, Perkins S, Rowen SL, et al. US food and drug administration clinical trial of the implantable contact lens for moderate to high myopia. *Ophthalmology.* 2003;110:255-66.
23. Pan A-P, Wen L-J, Shao X, Zhou K-J, Wang Q-M, Qu J, et al. A novel ophthalmic viscosurgical device-free phakic intraocular lens implantation makes myopic surgery safer. *Eye Vis.* 2020;7:18.
24. Garcia-Feijoo J, Alfaro IJ, Cuina-Sardina R, Mendez-Hernandez C, Del Castillo JMB, Garcia-Sanchez J. Ultrasound biomicroscopy examination of posterior chamber phakic intraocular lens position. *Ophthalmology.* 2003;110:163-72.
25. Choi KH, Chung SE, Chung TY, Chung ES. Ultrasound biomicroscopy for determining Visian Implantable Contact Lens length in phakic IOL implantation. *J Refract Surg.* 2007;23:362-7.
26. Zhang X, Chen X, Wang X, Yuan F, Zhou X. Analysis of intraocular positions of posterior implantable collamer lens by full-scale ultrasound biomicroscopy. *BMC Ophthalmol.* 2018;18:114.
27. Du C, Wang J, Wang X, Dong Y, Gu Y, Shen Y. Ultrasound biomicroscopy of anterior segment accommodative changes with Posterior Chamber Phakic Intraocular Lens in high myopia. *Ophthalmology.* 2012;119:99-105.
28. Lindland A, Heger H, Kugelberg M, Zetterstrom C. Changes in vaulting of myopic and toric implantable collamer lenses in different lighting conditions. *Acta Ophthalmol.* 2012;90:788-91.
29. Totsuka K, Ishikawa H, Kamiya K, Shoji N, Shimizu K. Pupil dynamics induced by light reflex after posterior Chamber Phakic Intraocular Lens Implantation. *J Refract Surg.* 2017;33:704-7.
30. Kamiya K, Shimizu K, Igarashi A, Ishikawa H. Evaluation of pupil diameter after posterior chamber phakic intraocular lens implantation. *Eye.* 2010;24:588-94.
31. Gonzalez-Lopez F, Mompean B, Bilbao-Calabuig R, Vila-Arteaga J, Beltran J, Baviera J. Dynamic assessment of light-induced vaulting changes of Implantable Collamer Lens with central port by swept-source OCT: pilot study. *Transl Vis Sci Technol.* 2018;7:4.
32. Kojima T, Yokoyama S, Ito M, Horai R, Hara S, Nakamura T, et al. Optimization of an Implantable Collamer Lens sizing method using high-frequency ultrasound biomicroscopy. *Am J Ophthalmol.* 2012;153:632-7.

33. Zheng QY, Xu W, Liang GL, Wu J, Shi JT. Preoperative biometric parameters predict the vault after ICL implantation: a retrospective clinical study. *Ophthalmic Res.* 2016;56:215-21.
34. Nakamura T, Isogai N, Kojima T, Yoshida Y, Sugiyama Y. Implantable Collamer Lens sizing method based on swept-source anterior segment optical coherence tomography. *Am J Ophthalmol.* 2018;187:99-107.
35. Gonzalez-Lopez F, Bilbao-Calabuig R, Mompean B, Luezas J, Ortega-Usobiaga J, Druchkiv V. Determining the Potential Role of Crystalline Lens rise in vaulting in posterior chamber phakic collamer lens surgery for correction of myopia. *J Refract Surg.* 2019;35:177-83.
36. Lee H, Kang DSY, Ha BJ, Choi M, Kim EK, Seo KY, et al. Effect of accommodation on vaulting and movement of Posterior Chamber Phakic Lenses in eyes with Implantable COL Lamer Lenses. *Am J Ophthalmol.* 2015;160:710-6.
37. Chen X, Shen Y, Xu H, Wang X, Zhou X. One-year natural course of corneal densitometry in high myopic patients after implantation of an implantable collamer lens (model V4c). *BMC Ophthalmol.* 2020;20:50.
38. Biermann J, Bredow L, Boehringer D, Reinhard T. Evaluation of ciliary sulcus diameter using ultrasound biomicroscopy in emmetropic eyes and myopic eyes. *J Cataract Refract Surg.* 2011;37:1686-93.
39. Oh J, Shin HH, Kim JH, Kim HM, Song JS. Direct measurement of the ciliary sulcus diameter by 35-megahertz ultrasound biomicroscopy. *Ophthalmology.* 2007;114:1685-8.
40. Torbey J, Mehanna C-J, Abdul Fattah M, Awwad ST. Comparison of intraoperative vs postoperative optical coherence tomography measurement of implantable collamer lens vaulting. *J Cataract Refract Surg.* 2020;46:737-41.
41. Qi MY, Chen Q, Zeng QY. The effect of the Crystalline Lens on central vault after Implantable Collamer Lens Implantation. *J Refract Surg.* 2017;33:519-23.
42. Igarashi A, Shimizu K, Kato S, Kamiya K. Predictability of the vault after posterior chamber phakic intraocular lens implantation using anterior segment optical coherence tomography. *J Cataract Refract Surg.* 2019;45:1099-104.
43. Nakamura T, Isogai N, Kojima T, Yoshida Y, Sugiyama Y. Optimization of implantable collamer lens sizing based on swept-source anterior segment optical coherence tomography. *J Cataract Refract Surg.* 2020;46:742-8.
44. Li Z, Xu Z, Wang Y, Liu Q, Chen B. Implantable collamer lens surgery in patients with primary iris and/or ciliary body cysts. *BMC Ophthalmol.* 2018;18:287.

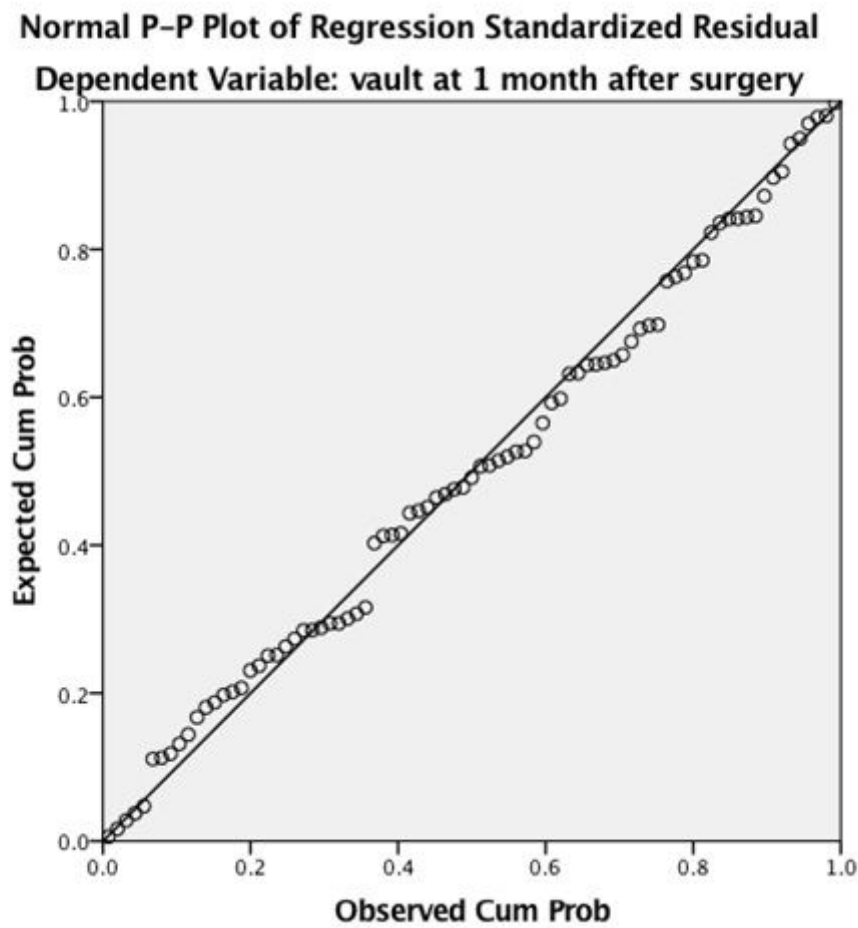
## Figures





**Figure 1**

Vault changes within one month after ICL implantation. a, b, c, and d represent 2 hours, 1 day, 1 week, and 1 month after surgery. Vault values were 510, 290, 450 and 460  $\mu\text{m}$ , respectively.



**Figure 2**

Normal P-P plot of the regression standardized residual, which shows excellent prediction accuracy.