

The Epidemiology, Cause, and Prognosis of Painful Tic Convulsif Syndrome: An Individual Patient Data Analysis of 192 Cases

Zixiao Yin

Beijing Tiantan Hospital

Yuye Liu

Beijing Tiantan Hospital

Yutong Bai

Beijing Tiantan Hospital

Hua Zhang

Beijing Tiantan Hospital

Huangang Liu

Beijing Tiantan Hospital

Feng Yu

Beijing Tiantan Hospital

Jianguo Zhang

Beijing Tiantan Hospital

Ruen Liu

Beijing Tiantan Hospital

Anchao Yang (✉ yang.anchao@163.com)

Beijing Tiantan Hospital <https://orcid.org/0000-0001-9179-5571>

Research article

Keywords: hemifacial spasm, IPD meta-analysis, microvascular decompression, painful tic convulsif, trigeminal neuralgia

Posted Date: October 8th, 2020

DOI: <https://doi.org/10.21203/rs.3.rs-86398/v1>

License: © ⓘ This work is licensed under a Creative Commons Attribution 4.0 International License. [Read Full License](#)

Version of Record: A version of this preprint was published at World Neurosurgery on March 1st, 2021. See the published version at <https://doi.org/10.1016/j.wneu.2020.11.161>.

Abstract

Background Characterized by the coexistence of trigeminal neuralgia and ipsilateral hemifacial spasm (HFS), painful tic convulsif (PTC) is a rare entity not yet been systematically studied.

Objective To systematically explore the epidemiology, cause, prognosis, and prognosis predictors of PTC.

Method We searched PubMed, Web of Science, and the Cochrane Library for relevant studies published between the library establishment time and July 1st, 2020. Information on demographics, causes, specific interventions, and intervention outcomes was extracted. We first made descriptive analyses for demographics, causes, and surgical outcomes of PTC. Univariate and multivariate regression methods were utilized to explore potential prognosis predictors. Further, a two-step meta-analysis method was employed to validate the identified factors.

Results Overall, 57 reports including 192 cases with PTC were included in the analysis. The median age of PTC patient is 54 (44-62), with more patients being female ($p < 0.001$), initiated as HFS ($p = 0.005$), and affected left side ($p = 0.045$). Vertebrobasilar artery (VBA) contributes to over-65% of the causes of single vascular compression for PTC. Anterior inferior cerebellar artery (AICA)/posterior inferior cerebellar artery (PICA) involvement (OR = 4.050, 95% CI = 1.091-15.031) and older age ($p = 0.008$) predicts symptom-free and recurrence after microvascular decompression (MVD), respectively.

Conclusions PTC more occurs in middle-age women between 40 to 60, initiates as HFS, and affects left side. VBA compression is the most common single cause for PTC. MVD could effectively treat PTC with an over-80% cure rate. AICA/PICA involvement predicts successful surgery and older age predicts recurrence.

Registration: the protocol of this study is registered in the Open Science Framework (DOI 10.17605/OSF.IO/X9G3R) on July 10th, 2020.

Background

Painful tic convulsif (PTC) is a rare entity characterized by the coexistence of trigeminal neuralgia (TN) and ipsilateral hemifacial spasm (HFS) [1]. It is mostly caused by vascular compression of the posterior fossa [2], and mainly treated by microvascular decompression (MVD) surgery [3].

PTC has only been reported in case reports or small case series. So far, the largest report of PTC is a retrospective study published in 2019 including 40 cases [4], which can be insufficient to systematically answer what the epidemiology, cause, and prognosis of PTC is. Although we know TN and HFS relatively well [5, 6], PTC as a combined dysfunction syndrome of the cranial nerves (CNs) can be very different from TN and HFS in terms of the offending vessel and surgical complication [7]. A fully understanding of these differences will help transfer experience on familiar diseases (e.g. TN and HFS) to unfamiliar diseases (e.g. PTC), contributing to a better treatment procedure.

Due to the rarity of the syndrome, it is scarcely possible to research PTC in large-scale prospective studies. In this situation, the method of individual patient data (IPD) meta-analysis possesses unique advantages in exploring the epidemiology of rare diseases [8, 9]. This study was conducted to systematically analyze the demographics, causes, prognosis, and prognosis predictors of PTC. These outcomes were compared to that of TN and HFS, to help establish an overall understanding of PTC.

Methods

This study was conducted following PRISMA-IPD report criteria [10], and under the guidance of the Cochrane Handbook for Systematic Reviews of Interventions [11]. We registered the protocol of this study in the Open Science Framework on July 10th, 2020.

Literature search

We searched PubMed, Web of Science, and the Cochrane Library for relevant publications. The literature search was last updated on July 1st, 2020. We employed the following keywords for standard search: "hemifacial spasm," "facial spasm," "trigeminal neuralgia," and "painful tic convulsif." The specific search algorithm employed in each library was detailed in the Supplementary File. Two independent experienced reviewers screened the title and abstract of identified studies. Studies deemed relevant by either of the 2 reviewers were eligible for next-stage screening.

Inclusion/exclusion criteria

Inclusion criteria: PTC (the coexistence of TN and ipsilateral HFS) was reported.

Exclusion criteria: I) reporting patients with TN or HFS alone without combination; II) reporting patients with combinations of CN dysfunction, such as TN plus glossopharyngeal neuralgia (GN), but without PTC. Patients with PTC plus GN were included; III) reporting patients with TN combined with contralateral HFS; IV) patient data were redundant with another report.

We set no limitations on publication language. Non-English literature was translated through Google Translate (<https://translate.google.com>). For abstract-only articles, we included them only when sufficient descriptions of the case are available.

Data extraction

We extracted the following information: (I) descriptive statistics including age at onset, age at surgery, disease duration, gender, laterality for both HFS and TN, and concomitant hypertension; (II) causes for PTC including neural-vascular conflict, tumor, and vascular malformation, etc.; (III) interventions including medication, botulinum toxin therapy, and MVD surgery, etc.; and (IV) prognosis including the intervention outcome, complication after surgery, and information on recurrence.

For studies lacking information on the individual patient level, we tried to contact corresponding authors for original data. Four authors [4, 7, 12, 13] replied to us and 2 of them [4, 7] shared raw data. In this way, we acquired IPD of 46 patients with PTC. For IPD acquired through E-mail, we first repeated the statistical process reported in the original publication and then included them in the analysis. Any difference found between the repetition and the original report was queried by contacting the corresponding author. For studies reporting only group-level outcomes and whose corresponding author did not reply to us, we only included the enumeration data (e.g. sex) into the analysis.

Definition

Surgical outcomes

Separately, we categorized TN and HFS outcomes after intervention into 3 degrees [14]: 1) excellent, defined as complete relief of TN or HFS; 2) good, defined as reduced degree or frequency of TN or HFS, with symptoms still existing; and 3) poor, defined as no improvement or symptom worsening in the TN or HFS. Given that delayed relief is commonly seen in HFS, we regarded the treatment outcome as symptom-free so long as HFS is completely relieved in the last follow-up [15]. The treatment outcome of PTC was judged according to the separate outcomes of TN and HFS. If both TN and HFS reached excellent relief after interventions, the outcome was regarded as symptom-free. If both TN and HFS showed no alleviation, the outcome was regarded as no alleviation. All other situations lied between were regarded as alleviation [13].

Complications

We recorded all reported complications. Transient complications were defined as complications that occurred shortly after surgery and recovered in later follow-ups. Persistent complications were defined as complications that remained unrecovered in the last follow-up.

Recurrence

Recurrence was defined as relapse after initial response to MVD. Only the recurrence after surgical interventions was analyzed.

Statistical analysis

We first made a descriptive analysis of patient's demographics. Continuous data were presented as mean \pm SD or median and quartile when under normal distribution or skewed distribution, respectively. Enumeration data were presented as count number or proportion. For gender (male/female), initiate symptom (HFS first/TN first), and laterality (left/right), a further one sample z-test was conducted to test the difference between the 2 categories. Then, we used the chi-square test and Student t-test to explore potential predictors on prognosis after MVD surgery. Multivariate logistic regression was further conducted to validate the predictor identified in the univariate analysis. Up to here, we employed only the one-step method for IPD analyzing, while the method cannot well address the clustering of patients within studies [10, 16]. We thus conducted a two-step analysis for further validation. Specifically, we included 6 case-series studies with a sample size over 5 and calculated statistics (odds ratio (OR) or mean and SD) for each study. Then, we employed a random-effects model to pool these statistics and got a pooled result. In the case of zero event in calculating OR, a continuity correction of 0.5 was employed [11, 17]. All procedures were conducted using SPSS 24 (IBM, Chicago, IL, USA) and Comprehensive Meta-Analysis 3 (Biostat, Englewood, NJ, USA).

Results

Search results

A total of 57 reports including 192 patients with PTC were included in the final analysis. The specific screening process is shown in Figure 1. Detailed information of the 57 included studies is shown in Supplementary Table 1. Demographics of the 192 included patients are shown in

Table 1. Notably, PTC was more often diagnosed in women than men ($p < 0.001$), initiated as HFS than TN ($p = 0.005$), and occurred on the left side than the right side ($p = 0.045$).

Cause and offending vessel for PTC

We analyzed causes for TN and HFS in PTC separately, including vascular compression, tumor, vascular disease, and malformation (Figure 2). Vascular compression is the most common cause for both the TN and HFS in PTC. In TN, the most offending vessels are the superior cerebellar artery (SCA), anterior inferior cerebellar artery (AICA), and basilar artery (BA). In HFS, the most offending vessels are AICA, posterior inferior cerebellar artery (PICA), and vertebral artery (VA). In situations when PTC was caused by single vessel compression, vertebrobasilar artery (VBA) system compression was the most common cause.

Surgical result and decomposition material

Overall, 149 out of the 192 patients with PTC received MVD surgery. Teflon felt was used in 85% (127/149) of the surgery for nerve decomposition. Other decomposition materials included Gelfoam, Ivalon, polyvinyl sponge, Silicone, cotton gauze, and muscle.

Surgical results were reported in 132 cases. After surgery, 111 (84%) patients reached symptom-free, 18 (14%) patients were obviously alleviated, and 2 (2%) patients' symptoms were not alleviated. One (1%) patient died during the perioperative period.

Recurrence after surgery

Information on recurrence was reported in 127 cases. In an average of 48 months follow-up period, 14 (11%) patients showed symptom recurrence. Among them, TN recurred in 10 patients and HFS recurred in 3 patients. One patient had both the TN and HFS recurred.

Complications

Out of the 116 patients whose postoperative causes were reported, 30 (26%) patients had transient and/or permanent complications. Transient complications were observed in 27 patients, with the most common ones being facial weakness, hearing and sensation loss, and aseptic meningitis. Permanent complications were observed in 5 patients, including hypoaesthesia and permanent hearing loss.

Prognosis predictors

In the preliminary analysis of potential predictors of MVD surgery outcome (Table 2), significant predictor on symptom free, postoperative complication and recurrence was "AICA/PICA involved" over "noninvolvement" (OR = 2.719, 95% CI = 1.025-7.210, $\chi^2 = 4.247$), "left side symptom" over "right side symptom" (OR = 2.563, 95% CI = 1.027-6.393, $\chi^2 = 4.218$), and "older age" (58.5 ± 9.7 vs 65.8 ± 7.9 , $p = 0.008$), respectively.

In the multivariate logistic regression employing Forward Wald method, "AICA/PICA involved" ($B = 1.399$, OR = 4.050, 95% CI = 1.091-15.031) and "older age" ($B = 0.081$, OR = 1.084, 95% CI = 1.018-1.155) remained to be significant predictors for symptom free and recurrence, respectively. However, we did not identify any factor associated with postoperative complication.

Further, to account for potential bias introduced due to the clustering of patients, we validated the above results using a two-step IPD meta-analysis method including 6 case-series studies. Results showed that "AICA/PICA involved" still predicted symptoms free (OR = 4.477, 95%CI = 1.157 to 17.323, $p = 0.030$), while "left side symptom" did not predict postoperative complication (OR = 1.718, 95%CI = 0.607 to 4.866, $p = 0.308$). Patients in the recurrence group had an older age than patients in the non-recurrence group (65.9 ± 9.4 vs 57.2 ± 4.0 , Q-value = 2.086, $p = 0.037$).

A summary of PTC, TN, and HFS

Table 3 summarized comparison between PTC, TN, and HFS in aspects of epidemiology, surgical outcome, and prognosis predictor [6, 18–51].

Discussion

This study analyzed IPD from 192 patients with PTC, showing that PTC shared many similarities with TN and HFS in terms of epidemiology, but may differ in conflicting vessel and prognosis predictor.

Epidemiology and conflicting vessel

Our results suggest that PTC is more likely to afflict middle-aged women between 40 to 60. The gender ratio and onset age of PTC is similar to that of TN and HFS [20, 22, 23, 26–28]. Left side symptom is more common than the right side in PTC, the same as HFS but differing from TN,

which are more right-side dominant [24, 25]. We found that PTC initiated more as HFS than as TN, a finding also observed by Liu et al. [4] This can possibly be explained by the compression of the VBA, as the stem of the VBA is more adjacent to the root entry zone (REZ) of the facial nerve than that of the trigeminal nerve. So, when VBA gets enlarged and stiffened due to arteriosclerosis, it is more likely to induce HFS firstly.

Identical to previous reports [2, 52], the most common cause for PTC was vascular compression, observed in 85% of the cases. Interestingly, our results showed that, when analyzed separately, the offending vessel for TN and HFS in PTC is very similar to that for TN and HFS alone. In PTC, the facial nerve was commonly compressed by AICA, PICA, and VA. These 3 vessels are also the most common causes of HFS [30]. Similarly, the trigeminal nerve was most compressed by SCA, AICA, and BA in PTC, identical to the SCA, vein, and AICA compression observed in TN [26]. Given that the cause and conflicting vessel of PTC are so alike to that of TN and HFS alone, we speculated that in most cases, PTC should be regarded as a simple coexistence of the 2 CNs dysfunction, rather than an independent syndrome. This is also supported by that the prevalence of hypertension in patients with PTC (approximately 30%) is similar to that in TN and HFS [23, 29]. After the first CN is compressed, whether the second CN will be affected depends on the degree of dolichoectasia, the position of the nerve, and the volume of the posterior fossa [4]. Importantly, in 46 PTC cases whose symptoms were caused by a single vessel compression, a tortuous dolichoectatic vertebral artery was the major offender, consisting of over 65% of the cases, a finding different to that when TN and HFS exist alone. This is relevant to the anatomy as VBA has the largest vessel diameter among arteries in the posterior fossa [53]. For patients with arteriosclerosis, the ectatic VBA shifted to the affected side could compress multiple CNs along its running area, resulting in combined CN dysfunction.

Surgical outcome and prognosis predictor

In our included patients, the cure-rate after MVD surgery was 84%. It reflects a satisfactory surgical outcome although the rate is slightly lower than that in TN (82% to 91%) and HFS (89% to 91%) [31–34, 51]. Previous literature suggested that the course of PICA is the most variable and complex in all the cerebellar vessels [44], while we observed that the involvement of AICA/PICA is the only predictor of excellent surgical outcome. The reason could be that the AICA/PICA are generally slimmer than the VBA. Once the course and neural-vascular conflicting relationship is established, surgeons can decompress the CN though placing Teflon sponge with relative ease. While in VBA compression, Teflon sponge alone may not be sufficient for adequate decompression [54]. Montava et al.[37] have similar findings that PICA compression is predictive of better surgical outcomes. Other correlative factors have also been indicated in the previous report, e.g. single vascular compression and artery compression are predictive of good surgical outcome [31], while venous compression foresees a suboptimal outcome [26].

Our results showed that postoperative complication was not rare after MVD surgery, occurred in 26% of patients, with facial weakness being the most common transient complication. As reported, the complication rate of TN is slightly higher than that of HFS, occurring in approximately 30% of patients [38, 39]. Alford [40] and Liu [4] suggested that physical conditions such as preoperative anemia, and life habits such as excessive drinking and smoking are predictors for postoperative complication [40, 43]. Amagasaki et al.[44] indicated that PICA offending is the only independent risk factor of postoperative lower CN palsy, possibly because PICA and lower CN belong to the same vascular nerve complex [55]. We did not identify any significant predictor on postoperative complication in the multivariate regression analysis, but observed a weak relationship between postoperative complication and left side surgery in the univariate analysis. We assumed that VBA compression may play a role here, as left-side VBA is often larger and more likely to have sclerosis than right-side VBA [56, 57], causing difficulty for decomposition surgery [54].

In our study, PTC recurred in 14 patients after MVD surgery, with a recurrence rate of 11%. Among the 14 patients, 11 patients had TN recurred and 3 patients had HFS recurred. Previous findings agreed that TN may have a higher rate of recurrence than HFS [34, 46], possibly because venous compression is more seen as a cause for TN [26]. For TN, previous literature also reported that female gender, long disease duration, and atypical pain are associated with a higher risk of recurrence [26, 47, 48]. Notably, several previous studies indicated that older age is not only a predictive factor for successful decomposition [36, 48], but also a protective factor for postoperative recurrence in patients with TN [47]. The authors hold that older patients are oftentimes concomitant with cerebellar atrophy. The reduced cerebellar volume contributes to better posterior fossa exposure, which not only helps better identify neural-vessel conflict but also shortens operation time. On the contrary, in our study, older age is a risk factor for PTC recurrence. Three possible reasons may explain this. First, for patients with PTC, the conflicting vessel in the REZ is oftentimes already obvious. This makes identification of the offending vessel less difficult for younger patients without significant cerebellar atrophy. Second, PTC is a rare syndrome that neurosurgeons may pay extra attention to. This may offset the bonus brought by cerebellar atrophy because careful exposure and decomposition of the CNs is already needed. Third, older patients are at a higher risk of developing arteriosclerosis and diabetes. These factors could result in the dolichoectatic vertebral artery, increasing the difficulty of decomposition [58]. Besides, recurrence could result from newly developed responsible vessels, which can be more commonly seen when concomitant arteriosclerosis and diabetes exist.

Limitations

Several limitations of the study should be noted. First, we did not choose the two-step method, which better considers the clustering of patients within studies [10, 16], for main analyses. The reason for doing so is that most of the included studies are case reports, making it impossible to calculate a pooled statistic for each study. Besides, the effect of patient clustering would not significantly bias our result, since most of our outcomes are calculated from count data. But undeniably, the effect of patient clustering could influence regression outcomes. Thus, an additional two-step meta-regression was conducted to validate outcomes obtained in the one-step regression.

Another flaw is that the included studies inconsistently report outcomes. Not each of the 57 studies clearly reported all the demographics and surgical outcomes. And not every study judged surgical outcomes on the same basis. Therefore, we can only estimate surgical outcomes according to descriptions in the report. Future studies should employ standard scales (e.g. barrow neurological institute score) in the evaluation of surgical results.

Conclusion

This IPD meta-analysis systematically analyzed 192 patients with PTC and found that PTC is more likely to initiate as HFS and afflict middle-aged women between 40 to 60, with left side symptoms more commonly seen than the right side. Neural-vascular conflict with an ectatic VBA system is the most common single cause for PTC. MVD could effectively treat PTC, with an over-80% cure rate after surgery. AICA/PICA involvement is predictive of a successful surgery, while older age is associated with a higher risk of recurrence. The results will help neurosurgeons better understand, diagnose, treat, and manage patients with PTC.

Abbreviations

PTC: Painful tic convulsif; TN: trigeminal neuralgia; HFS: hemifacial spasm; MVD: microvascular decompression; CN: cranial nerves; IPD: individual patient data; GN: glossopharyngeal neuralgia; OR: odds ratio; SCA: superior cerebellar artery; AICA: anterior inferior cerebellar artery; BA: basilar artery; PICA: posterior inferior cerebellar artery; VA: vertebral artery; VBA: vertebrobasilar artery; REZ: root entry zone.

Declarations

Ethics approval and consent to participate

Not applicable.

Consent for publication

Not applicable

Availability of data and materials

The datasets used and/or analyzed during the current study are available from the corresponding author on reasonable request.

Competing interests

The authors declare that they have no competing interests

Funding

this work was funded by National Natural Science Foundation of China (81870888), Capital Medical Development Research Fund (2018-ZZ-1076), and Beijing Municipal Administration of Hospitals' Ascent Plan (DFL20150503).

Authors' contributions

Z.J.G. and Y.A.C contributed to the conception and design of the work. Y.Z.X., L.Y.Y. and B.Y.T. contributed to the data acquisition. Y.Z.X., L.Y.Y. and B.Y.T. analyzed and interpreted the data. Y.Z.X. and L.Y.Y drafted the work. Z.H., L.H.G, Y.F., L.R.E., Z.J.G. and Y.A.C. substantively revised the paper.

Acknowledgements

We thank all the participants for their support of this research.

References

1. Cushing H (1920) The major trigeminal neuralgias and their surgical treatment based on experiences with 332 gasserian operations: the varieties of facial neuralgia. *The American Journal of the Medical Sciences* 160:157–183. <https://doi.org/10.1097/00000441-192008000-00001>
2. Zhong J, Zhu J, Li S-T, Guan H-X (2011) Microvascular decompressions in patients with coexistent hemifacial spasm and trigeminal neuralgia. *Neurosurgery* 68:916–920; discussion 920. <https://doi.org/10.1227/NEU.0b013e318208f5ac>
3. Crevier-Sorbo G, Brock A, Rolston JD (2019) Trigeminal neuralgia plus hemifacial spasm caused by a dilated artery: a case of painful tic convulsif syndrome. *Lancet* 394:e36. [https://doi.org/10.1016/S0140-6736\(19\)32598-X](https://doi.org/10.1016/S0140-6736(19)32598-X)
4. Liu J, Zhu C, Liu R, et al (2020) Clinical Analysis of Patients with Ipsilateral Coexistence of Hemifacial Spasm and Trigeminal Neuralgia. *World Neurosurgery* 138:e652–e658. <https://doi.org/10.1016/j.wneu.2020.03.040>
5. Holste K, Chan AY, Rolston JD, Englot DJ (2020) Pain Outcomes Following Microvascular Decompression for Drug-Resistant Trigeminal Neuralgia: A Systematic Review and Meta-Analysis. *Neurosurgery* 86:182–190. <https://doi.org/10.1093/neuros/nyz075>
6. Holste K, Sahyouni R, Teton Z, et al (2020) Spasm Freedom Following Microvascular Decompression for Hemifacial Spasm: Systematic Review and Meta-Analysis. *World Neurosurg* 139:e383–e390. <https://doi.org/10.1016/j.wneu.2020.04.001>
7. Zhang Y-Q, Yu F, Zhao Z-Y, Men X-Z (2019) Combined Hyperactive Dysfunction Syndrome of the Cranial Nerves: Analysis of 37 Cases and Literature Review. *World Neurosurg* 129:e650–e656. <https://doi.org/10.1016/j.wneu.2019.05.237>
8. De Vloo P, Lee DJ, Dallapiazza RF, et al (2019) Deep brain stimulation for pantothenate kinase-associated neurodegeneration: A meta-analysis. *Mov Disord* 34:264–273. <https://doi.org/10.1002/mds.27563>
9. Wang X, Zhang Z, Mao Z, Yu X (2019) Deep brain stimulation for Meige syndrome: a meta-analysis with individual patient data. *J Neurol* 266:2646–2656. <https://doi.org/10.1007/s00415-019-09462-2>
10. Stewart LA, Clarke M, Rovers M, et al (2015) Preferred Reporting Items for a Systematic Review and Meta-analysis of Individual Participant Data: The PRISMA-IPD Statement. *JAMA* 313:1657. <https://doi.org/10.1001/jama.2015.3656>
11. Higgins J, Thomas J, Chandler J, et al (2019) *Cochrane Handbook for Systematic Reviews of Interventions* version 6.0 (updated July 2019). Cochrane
12. Li HY, Xing YZ, Lai SL, et al (2019) Clinical study of microvascular decompression in patients with coexistent hemifacial spasm and ipsilateral trigeminal neuralgia. *Zhonghua Yi Xue Za Zhi* 99:1805–1808. <https://doi.org/10.3760/cma.j.issn.0376-2491.2019.23.011>
13. Cao J, Jiao J, Du Z, et al (2017) Combined Hyperactive Dysfunction Syndrome of the Cranial Nerves: A Retrospective Systematic Study of Clinical Characteristics in 44 Patients. *World Neurosurg* 104:390–397. <https://doi.org/10.1016/j.wneu.2017.05.020>
14. El-Ghandour NMF (2010) Microvascular decompression in the treatment of trigeminal neuralgia caused by vertebrobasilar ectasia. *Neurosurgery* 67:330–337. <https://doi.org/10.1227/01.NEU.0000371978.86528.60>
15. Ishikawa M, Nakanishi T, Takamiya Y, Namiki J (2001) Delayed Resolution of Residual Hemifacial Spasm after Microvascular Decompression Operations. *Neurosurgery* 49:847–856. <https://doi.org/10.1097/00006123-200110000-00013>
16. Abo-Zaid G, Guo B, Deeks JJ, et al (2013) Individual participant data meta-analyses should not ignore clustering. *Journal of Clinical Epidemiology* 66:865-873.e4. <https://doi.org/10.1016/j.jclinepi.2012.12.017>
17. Cochrane Collaboration (2006) RevMan 4.2 user guide. 2004[2007-09] <http://www.cc-ims.net/download/revman/Documentation/User%20guide.pdf>
18. Pan S-L, Yen M-F, Chiu Y-H, et al (2011) Increased risk of trigeminal neuralgia after hypertension: A population-based study. *Neurology* 77:1605–1610. <https://doi.org/10.1212/WNL.0b013e3182343354>
19. van Hecke O, Austin SK, Khan RA, et al (2014) Neuropathic pain in the general population: a systematic review of epidemiological studies. *Pain* 155:654–662. <https://doi.org/10.1016/j.pain.2013.11.013>
20. Nilsen B, Le K-D, Dietrichs E (2004) Prevalence of hemifacial spasm in Oslo, Norway. *Neurology* 63:1532–1533. <https://doi.org/10.1212/01.wnl.0000142080.85228.e8>
21. Wu Y, Davidson AL, Pan T, Jankovic J (2010) Asian over-representation among patients with hemifacial spasm compared to patients with cranial–cervical dystonia. *Journal of the Neurological Sciences* 298:61–63. <https://doi.org/10.1016/j.jns.2010.08.017>
22. Katusic S, Beard CM, Bergstralh E, Kurland LT (1990) Incidence and clinical features of trigeminal neuralgia, Rochester, Minnesota, 1945–1984. *Ann Neurol* 27:89–95. <https://doi.org/10.1002/ana.410270114>
23. Teruel A, Ram S, Kumar SKS, et al (2009) Prevalence of hypertension in patients with trigeminal neuralgia. *J Headache Pain* 10:199–201. <https://doi.org/10.1007/s10194-009-0107-5>
24. Toda K (2009) Side-to-side Asymmetry in Trigeminal Neuralgia. *Oral Science International* 6:95–99. [https://doi.org/10.1016/S1348-8643\(09\)80004-9](https://doi.org/10.1016/S1348-8643(09)80004-9)

25. Au WL, Tan LCS, Tan AKY (2004) Hemifacial spasm in Singapore: clinical characteristics and patients' perceptions. *Ann Acad Med Singap* 33:324–328
26. Barker FG, Jannetta PJ, Bissonette DJ, et al (1996) The Long-Term Outcome of Microvascular Decompression for Trigeminal Neuralgia. *N Engl J Med* 334:1077–1084. <https://doi.org/10.1056/NEJM199604253341701>
27. Sindou M, Leston J, Howeidly T, et al (2006) Micro-vascular decompression for primary Trigeminal Neuralgia (typical or atypical). Long-term effectiveness on pain; prospective study with survival analysis in a consecutive series of 362 patients. *Acta Neurochir (Wien)* 148:1235–1245. <https://doi.org/10.1007/s00701-006-0809-2>
28. Tan EK, Chan LL (2006) Young onset hemifacial spasm. *Acta Neurol Scand* 114:59–62. <https://doi.org/10.1111/j.1600-0404.2006.00650.x>
29. Leong J-L, Li H, Chan L-L, Tan E-K (2016) Revisiting the link between hypertension and hemifacial spasm. *Sci Rep* 6:21082. <https://doi.org/10.1038/srep21082>
30. Mercier P, Sindou M (2018) The conflicting vessels in hemifacial spasm: Literature review and anatomical-surgical implications. *Neurochirurgie* 64:94–100. <https://doi.org/10.1016/j.neuchi.2018.01.004>
31. Jo KW, Kong D-S, Hong K-S, et al (2013) Long-term prognostic factors for microvascular decompression for trigeminal neuralgia. *Journal of Clinical Neuroscience* 20:440–445. <https://doi.org/10.1016/j.jocn.2012.03.037>
32. Tai AX, Nayar VV (2019) Update on Trigeminal Neuralgia. *Curr Treat Options Neurol* 21:42. <https://doi.org/10.1007/s11940-019-0583-0>
33. Lee MH, Lee J-A, Park K (2019) Different Roles of Microvascular Decompression in Hemifacial Spasm and Trigeminal Neuralgia. *J Neurol Surg B* 80:511–517. <https://doi.org/10.1055/s-0038-1676377>
34. Miller LE, Miller VM (2012) Safety and effectiveness of microvascular decompression for treatment of hemifacial spasm: a systematic review. *British Journal of Neurosurgery* 26:438–444. <https://doi.org/10.3109/02688697.2011.641613>
35. Szapiro J, Sindou M, Szapiro J (1985) Prognostic Factors in Microvascular Decompression for Trigeminal Neuralgia. *Neurosurgery* 17:920–929. <https://doi.org/10.1227/00006123-198512000-00009>
36. Bakker NA, Van Dijk JMC, Immenga S, et al (2014) Repeat microvascular decompression for recurrent idiopathic trigeminal neuralgia. *J Neurosurg* 121:936–939. <https://doi.org/10.3171/2014.7.JNS132667>
37. Montava M, Rossi V, CurtoFais CL, et al (2016) Long-term surgical results in microvascular decompression for hemifacial spasm: efficacy, morbidity and quality of life. *Acta Otorhinolaryngol Ital* 36:220–227. <https://doi.org/10.14639/0392-100X-899>
38. Koopman JSHA, de Vries LM, Dieleman JP, et al (2011) A nationwide study of three invasive treatments for trigeminal neuralgia: Pain 152:507–513. <https://doi.org/10.1016/j.pain.2010.10.049>
39. Olson S, Atkinson L, Weidmann M (2005) Microvascular decompression for trigeminal neuralgia: recurrences and complications. *Journal of Clinical Neuroscience* 12:787–789. <https://doi.org/10.1016/j.jocn.2005.08.001>
40. Alford EN, Chagoya G, Elsayed GA, et al (2020) Risk factors for wound-related complications after microvascular decompression. *Neurosurg Rev*. <https://doi.org/10.1007/s10143-020-01296-1>
41. Zhang W-B, Sun Q-Y, Min L-Z, et al (2019) The Risk Factors for Facial Numbness After Microvascular Decompression in Patients With Trigeminal Neuralgia: *Journal of Craniofacial Surgery* 30:e710–e713. <https://doi.org/10.1097/SCS.0000000000005711>
42. Helbig GM, Callahan JD, Cohen-Gadol AA (2009) Variant intraneural vein-trigeminal nerve relationships: an observation during microvascular decompression surgery for trigeminal neuralgia. *Neurosurgery* 65:958–961. <https://doi.org/10.1227/01.NEU.0000351757.29658.C0>
43. Liu L-X, Ren Y-M, Ren P-W, et al (2018) Prognosis of Symptoms and Complications After Microvascular Decompression for Hemifacial Spasm: A Single-Center Experience. *World Neurosurg* 118:e557–e561. <https://doi.org/10.1016/j.wneu.2018.06.238>
44. Amagasaki K, Kurita N, Watanabe S, et al (2017) Lower cranial nerve palsy after the infrafloccular approach in microvascular decompression for hemifacial spasm. *Surg Neurol Int* 8:67. https://doi.org/10.4103/sni.sni_8_17
45. Na BS, Cho JW, Park K, et al (2018) Severe Hemifacial Spasm is a Predictor of Severe Indentation and Facial Palsy after Microdecompression Surgery. *J Clin Neurol* 14:303–309. <https://doi.org/10.3988/jcn.2018.14.3.303>
46. Cho D-Y, Chang CG-S, Wang Y-C, et al (1994) Repeat Operations in Failed Microvascular Decompression for Trigeminal Neuralgia. *Neurosurgery* 35:665–670. <https://doi.org/10.1227/00006123-199410000-00012>
47. Zhang W-B, Zeng Y-Y, Chang B-W, et al (2020) Prognostic nomogram for microvascular decompression–treated trigeminal neuralgia. *Neurosurg Rev*. <https://doi.org/10.1007/s10143-020-01251-0>
48. Bick SK, Huie D, Sneh G, Eskandar EN (2019) Older Patients Have Better Pain Outcomes Following Microvascular Decompression for Trigeminal Neuralgia. *Neurosurgery* 84:116–122. <https://doi.org/10.1093/neuros/nyy011>

49. Kureshi SA, Wilkins RH (1998) Posterior fossa reexploration for persistent or recurrent trigeminal neuralgia or hemifacial spasm: surgical findings and therapeutic implications. *Neurosurgery* 43:1111–1117. <https://doi.org/10.1097/00006123-199811000-00061>
50. Bigder MG, Kaufmann AM (2016) Failed microvascular decompression surgery for hemifacial spasm due to persistent neurovascular compression: an analysis of reoperations. *JNS* 124:90–95. <https://doi.org/10.3171/2015.1.JNS142714>
51. Sharma R, Garg K, Agarwal S, et al (2017) Microvascular decompression for hemifacial spasm: A systematic review of vascular pathology, long term treatment efficacy and safety. *Neurol India* 65:493. https://doi.org/10.4103/neuroindia.NI_1166_16
52. Cook BR, Jannetta PJ (1984) Tic convulsif: results in 11 cases treated with microvascular decompression of the fifth and seventh cranial nerves. *J Neurosurg* 61:949–951. <https://doi.org/10.3171/jns.1984.61.5.0949>
53. Shroutz C, Dujovny M, Ausman JI, et al (1986) Surgical anatomy of the arteries of the posterior fossa. *J Neurosurg* 65:540–544. <https://doi.org/10.3171/jns.1986.65.4.0540>
54. Perez-Roman RJ, Chen SH, Sur S, et al (2020) A Unique Case of Microvascular Triple Decompression for Combined Simultaneous Trigeminal Neuralgia, Hemifacial Spasm, and Glossopharyngeal Neuralgia Because of the Dolichoectatic Vertebrobasilar System. *Oper Neurosurg (Hagerstown)* 18:692–697. <https://doi.org/10.1093/ons/onz205>
55. Rhoton AL (2000) The Cerebellar Arteries. *Neurosurgery* 47:S29–S68. <https://doi.org/10.1097/00006123-200009001-00010>
56. Cloud GC (2003) Diagnosis and management of vertebral artery stenosis. *QJM* 96:27–54. <https://doi.org/10.1093/qjmed/hcg003>
57. Jeng J-S, Yip P-K (2004) Evaluation of vertebral artery hypoplasia and asymmetry by color-coded duplex ultrasonography. *Ultrasound Med Biol* 30:605–609. <https://doi.org/10.1016/j.ultrasmedbio.2004.03.004>
58. Arnone G, Esfahani D, Papastefan S, et al (2017) Diabetes and morbid obesity are associated with higher reoperation rates following microvascular decompression surgery: An ACS-NSQIP analysis. *Surg Neurol Int* 8:268. https://doi.org/10.4103/sni.sni_325_17

Tables

Table.1
Demographics of included patients*

	Value	n
Age of onset, yr	52.3 ± 12.4 54 (44–62)	129
Age of surgery, yr	58.8 ± 11.4 59 (51–66)	173
Duration for TN, mo	36 (1-300)	130
Duration for HFS, mo	36 (1-372)	130
Hypertension (n/N, %)	40/140, 28.6%	140
Gender ratio (male/female)	65/125	190
Z-test for male/female	$z = 4.35, p < 0.001$	
Initial symptom (TN first/HFS first/simultaneous)	51/84/26	161
Z-test for TN first/HFS first	$z = 2.84, p = 0.005$	
Side (left/right/both)	104/77/1	182
Z-test for left/right	$z = 2.01, p = 0.045$	
TN, trigeminal neuralgia; HFS, hemifacial spasm		
* Data are presented as mean ± SD and/or median (quartile) for continuous variables, N for categorical variables. Bolded numbers indicate statistically significance.		

Table.2

Exploratory analysis of relevant factors of the MVD surgery outcome, postoperative complications, and recurrence

		Symptom-free	Symptom persist	p value	No complication	Have complication	p value	No recurrence	Recurrence	p value
Age at surgery, yr		58.9 ± 9.7 (n = 110)	63.4 ± 9.6 (n = 21)	0.053	59.6 ± 9.7 (n = 85)	59.9 ± 9.7 (n = 30)	0.876	58.5 ± 9.7 (n = 113)	65.8 ± 7.9 (n = 14)	0.008
Gender	Male	34	6	0.831	26	12	0.346	33	5	0.616
	Female	76	15		59	18		80	9	
Disease duration	≤ 5 yr	40	12	0.060	37	15	0.344	46	6	0.986
	> 5 yr	41	4		35	9		39	4	
Side	Left	62	13	0.670	44	22	0.040	64	7	0.611
	Right	47	8		41	8		48	7	
Initiate symptoms	TN	30	2	0.120	14	10	0.075	28	3	0.930
	HFS	46	12		44	9		51	7	
	Both	19	2		14	5		18	2	
Hypertension	Yes	60	5	0.246	41	16	0.699	57	8	0.999
	No	28	6		19	9		28	4	
Single vessel compression	Yes	82	13	0.263	61	19	0.439	82	10	0.928
	No	29	8		25	11		31	4	
Vein compression	Yes	88	18	0.497	68	25	0.812	89	12	0.797
	No	23	3		18	5		24	2	
VBA involved	Yes	66	11	0.546	48	18	0.690	68	8	0.827
	No	45	10		38	12		45	6	
SCA involved	Yes	69	15	0.418	54	20	0.704	70	10	0.689
	No	42	6		32	10		43	4	
AICA/PICA involved	Yes	24	9	0.039	20	11	0.153	26	3	0.999
	No	87	12		66	19		87	11	
MVD, microvascular decompression; VBA, vertebrobasilar artery; SCA, superior cerebellar artery; AICA, anterior inferior cerebellar artery; PICA, posterior inferior cerebellar artery										
When the expected frequency lied between 1 and 5, the Chi-square test with continuity correction was employed.										

Table.3

A comparison between PTC, TN, and HFS in demographics, surgical outcomes, and prognostic predictors

	PTC	TN	HFS
Prevalence	No data	4 to 28.9 per 100,000 [1, 2]	9.8 to 12.6 per 100,000 [3, 4]
Gender ratio (men to women)	1: 1.9	1:1.5 to 1:1.7 [5, 6]	1:2 [3]
Side (left/right)	More prominent on the left side	Slightly more prominent on the right side [7]	Slightly more prominent on the left side [8]
Age at onset, yr	On average 52	Approximately 57 to 61 [9, 10]	Mostly in between 50 to 60 [11]
Prevalence of hypertension	28.6%	25–37% [5, 6]	31–61% [12]
Conflicting vessels (the 3 most common)	VA, BA, AICA	SCA, vein, AICA [9]	AICA, PICA, VBA [13]
Symptom-free rate after MVD	84%	82–91% [9, 14, 15]	89–92% [16–18]
Predictors for symptom-free	AICA/PICA involved	Presence of arterial compression; classic trigeminal neuralgia symptoms, good response to medical therapy [15]. Paroxysmal pain [19]. Single arterial offender [14]. Immediate postoperative relieve, older age [20].	Single conflicts, atypical conflicts involving vessels other than PICA, and compression sites other than REZ are predictive factors for surgical failure [21]. The initial surgery is more predictive to surgical success than a redo MVD [22].
Complication rate after MVD	26%	Approximately 30% [9, 23, 24]	5–15% [17, 18, 22]
Predictors for complication	Not identified	Preoperative anemia and current tobacco use [25], longer duration of surgery [26], intraneural vessels [27]	Age, HBV infection and alcohol [28], offending PICA [29], spasm severity [30].
Recurrence rate after MVD	11%	3–30% [9, 31]	1–10% [16, 17]
Predictors for recurrence	Older age	Younger age, atypical pain [32], female sex [33], a sensory deficit involving two or three branches [19], long duration of symptom before surgery, venous compression [9].	Inappropriate implant material and position [34], elongated vertebral artery [35].
PTC, painful tic convulsif; TN, trigeminal neuralgia; HFS, hemifacial spasm; MVD, microvascular decompression; VA, vertebral artery; BA, basilar artery; AICA, anterior inferior cerebellar artery; SCA, superior cerebellar artery; VBA, vertebrobasilar artery; REZ, root entry zone.			

References

1. Pan S-L, Yen M-F, Chiu Y-H, et al (2011) Increased risk of trigeminal neuralgia after hypertension: A population-based study. *Neurology* 77:1605–1610. <https://doi.org/10.1212/WNL.0b013e3182343354>
2. van Hecke O, Austin SK, Khan RA, et al (2014) Neuropathic pain in the general population: a systematic review of epidemiological studies. *Pain* 155:654–662. <https://doi.org/10.1016/j.pain.2013.11.013>
3. Nilsen B, Le K-D, Dietrichs E (2004) Prevalence of hemifacial spasm in Oslo, Norway. *Neurology* 63:1532–1533. <https://doi.org/10.1212/01.wnl.0000142080.85228.e8>
4. Wu Y, Davidson AL, Pan T, Jankovic J (2010) Asian over-representation among patients with hemifacial spasm compared to patients with cranial–cervical dystonia. *Journal of the Neurological Sciences* 298:61–63. <https://doi.org/10.1016/j.jns.2010.08.017>
5. Katusic S, Beard CM, Bergstralh E, Kurland LT (1990) Incidence and clinical features of trigeminal neuralgia, Rochester, Minnesota, 1945–1984. *Ann Neurol* 27:89–95. <https://doi.org/10.1002/ana.410270114>
6. Teruel A, Ram S, Kumar SKS, et al (2009) Prevalence of hypertension in patients with trigeminal neuralgia. *J Headache Pain* 10:199–201. <https://doi.org/10.1007/s10194-009-0107-5>

7. Toda K (2009) Side-to-side Asymmetry in Trigeminal Neuralgia. *Oral Science International* 6:95–99. [https://doi.org/10.1016/S1348-8643\(09\)80004-9](https://doi.org/10.1016/S1348-8643(09)80004-9)
8. Au WL, Tan LCS, Tan AKY (2004) Hemifacial spasm in Singapore: clinical characteristics and patients' perceptions. *Ann Acad Med Singap* 33:324–328
9. Barker FG, Jannetta PJ, Bissonette DJ, et al (1996) The Long-Term Outcome of Microvascular Decompression for Trigeminal Neuralgia. *N Engl J Med* 334:1077–1084. <https://doi.org/10.1056/NEJM199604253341701>
10. Sindou M, Leston J, Howeidly T, et al (2006) Micro-vascular decompression for primary Trigeminal Neuralgia (typical or atypical). Long-term effectiveness on pain; prospective study with survival analysis in a consecutive series of 362 patients. *Acta Neurochir (Wien)* 148:1235–1245. <https://doi.org/10.1007/s00701-006-0809-2>
11. Tan EK, Chan LL (2006) Young onset hemifacial spasm. *Acta Neurol Scand* 114:59–62. <https://doi.org/10.1111/j.1600-0404.2006.00650.x>
12. Leong J-L, Li H, Chan L-L, Tan E-K (2016) Revisiting the link between hypertension and hemifacial spasm. *Sci Rep* 6:21082. <https://doi.org/10.1038/srep21082>
13. Mercier P, Sindou M (2018) The conflicting vessels in hemifacial spasm: Literature review and anatomical-surgical implications. *Neurochirurgie* 64:94–100. <https://doi.org/10.1016/j.neuchi.2018.01.004>
14. Jo KW, Kong D-S, Hong K-S, et al (2013) Long-term prognostic factors for microvascular decompression for trigeminal neuralgia. *Journal of Clinical Neuroscience* 20:440–445. <https://doi.org/10.1016/j.jocn.2012.03.037>
15. Tai AX, Nayar VV (2019) Update on Trigeminal Neuralgia. *Curr Treat Options Neurol* 21:42. <https://doi.org/10.1007/s11940-019-0583-0>
16. Lee MH, Lee J-A, Park K (2019) Different Roles of Microvascular Decompression in Hemifacial Spasm and Trigeminal Neuralgia. *J Neurol Surg B* 80:511–517. <https://doi.org/10.1055/s-0038-1676377>
17. Miller LE, Miller VM (2012) Safety and effectiveness of microvascular decompression for treatment of hemifacial spasm: a systematic review. *British Journal of Neurosurgery* 26:438–444. <https://doi.org/10.3109/02688697.2011.641613>
18. Sharma R, Garg K, Agarwal S, et al (2017) Microvascular decompression for hemifacial spasm: A systematic review of vascular pathology, long term treatment efficacy and safety. *Neurol India* 65:493. https://doi.org/10.4103/neuroindia.NI_1166_16
19. Szapiro J, Sindou M, Szapiro J (1985) Prognostic Factors in Microvascular Decompression for Trigeminal Neuralgia. *Neurosurgery* 17:920–929. <https://doi.org/10.1227/00006123-198512000-00009>
20. Bakker NA, Van Dijk JMC, Immenga S, et al (2014) Repeat microvascular decompression for recurrent idiopathic trigeminal neuralgia. *J Neurosurg* 121:936–939. <https://doi.org/10.3171/2014.7.JNS132667>
21. Montava M, Rossi V, CurtoFais CL, et al (2016) Long-term surgical results in microvascular decompression for hemifacial spasm: efficacy, morbidity and quality of life. *Acta Otorhinolaryngol Ital* 36:220–227. <https://doi.org/10.14639/0392-100X-899>
22. Holste K, Sahyouni R, Teton Z, et al (2020) Spasm Freedom Following Microvascular Decompression for Hemifacial Spasm: Systematic Review and Meta-Analysis. *World Neurosurg* 139:e383–e390. <https://doi.org/10.1016/j.wneu.2020.04.001>
23. Koopman JSHA, de Vries LM, Dieleman JP, et al (2011) A nationwide study of three invasive treatments for trigeminal neuralgia: Pain 152:507–513. <https://doi.org/10.1016/j.pain.2010.10.049>
24. Olson S, Atkinson L, Weidmann M (2005) Microvascular decompression for trigeminal neuralgia: recurrences and complications. *Journal of Clinical Neuroscience* 12:787–789. <https://doi.org/10.1016/j.jocn.2005.08.001>
25. Alford EN, Chagoya G, Elsayed GA, et al (2020) Risk factors for wound-related complications after microvascular decompression. *Neurosurg Rev*. <https://doi.org/10.1007/s10143-020-01296-1>
26. Zhang W-B, Sun Q-Y, Min L-Z, et al (2019) The Risk Factors for Facial Numbness After Microvascular Decompression in Patients With Trigeminal Neuralgia: *Journal of Craniofacial Surgery* 30:e710–e713. <https://doi.org/10.1097/SCS.00000000000005711>
27. Helbig GM, Callahan JD, Cohen-Gadol AA (2009) Variant intraneural vein-trigeminal nerve relationships: an observation during microvascular decompression surgery for trigeminal neuralgia. *Neurosurgery* 65:958–961. <https://doi.org/10.1227/01.NEU.0000351757.29658.C0>
28. Liu L-X, Ren Y-M, Ren P-W, et al (2018) Prognosis of Symptoms and Complications After Microvascular Decompression for Hemifacial Spasm: A Single-Center Experience. *World Neurosurg* 118:e557–e561. <https://doi.org/10.1016/j.wneu.2018.06.238>
29. Amagasaki K, Kurita N, Watanabe S, et al (2017) Lower cranial nerve palsy after the infratemporal approach in microvascular decompression for hemifacial spasm. *Surg Neurol Int* 8:67. https://doi.org/10.4103/sni.sni_8_17
30. Na BS, Cho JW, Park K, et al (2018) Severe Hemifacial Spasm is a Predictor of Severe Indentation and Facial Palsy after Microdecompression Surgery. *J Clin Neurol* 14:303–309. <https://doi.org/10.3988/jcn.2018.14.3.303>

31. Cho D-Y, Chang CG-S, Wang Y-C, et al (1994) Repeat Operations in Failed Microvascular Decompression for Trigeminal Neuralgia. *Neurosurgery* 35:665–670. <https://doi.org/10.1227/00006123-199410000-00012>
32. Zhang W-B, Zeng Y-Y, Chang B-W, et al (2020) Prognostic nomogram for microvascular decompression–treated trigeminal neuralgia. *Neurosurg Rev.* <https://doi.org/10.1007/s10143-020-01251-0>
33. Bick SK, Huie D, Sneh G, Eskandar EN (2019) Older Patients Have Better Pain Outcomes Following Microvascular Decompression for Trigeminal Neuralgia. *Neurosurgery* 84:116–122. <https://doi.org/10.1093/neuros/nyy011>
34. Kureshi SA, Wilkins RH (1998) Posterior fossa reexploration for persistent or recurrent trigeminal neuralgia or hemifacial spasm: surgical findings and therapeutic implications. *Neurosurgery* 43:1111–1117. <https://doi.org/10.1097/00006123-199811000-00061>
35. Bigder MG, Kaufmann AM (2016) Failed microvascular decompression surgery for hemifacial spasm due to persistent neurovascular compression: an analysis of reoperations. *JNS* 124:90–95. <https://doi.org/10.3171/2015.1.JNS142714>

Figures

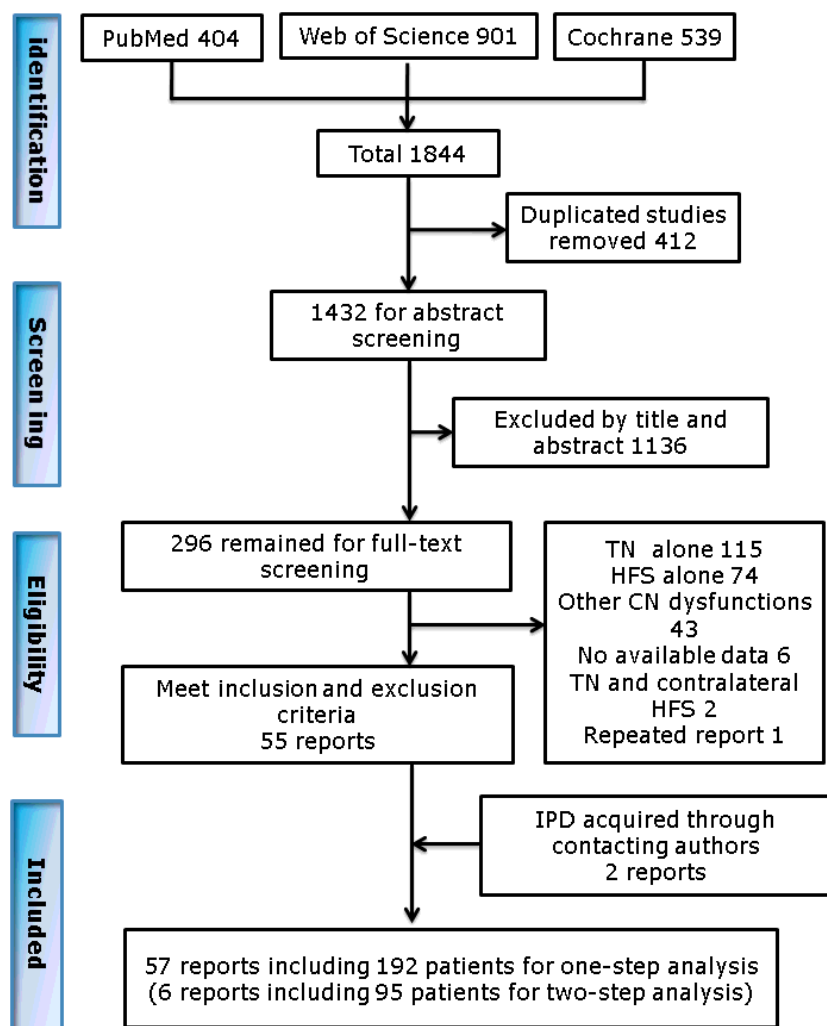


Figure 1

PRISMA-IPD flow chart of the included studies.

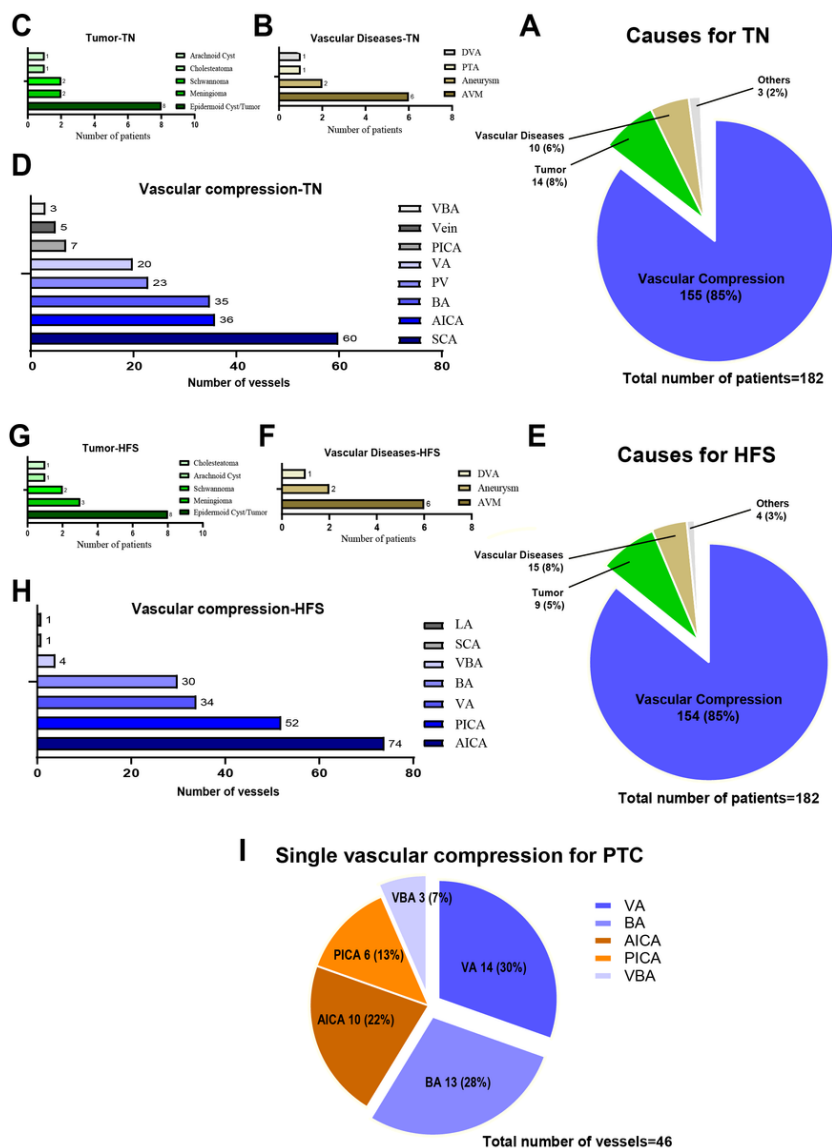


Figure 2

Causes for PTC. A, Pie chart showing causes for TN in the PTC. B-D, Bar charts showing specific causes for TN in the PTC in the categories of vascular disease (B), tumor (C), and vascular compression (D). E, Pie chart showing causes for HFS in the PTC. F-H, Bar charts showing specific causes for HFS in the PTC in the categories of vascular disease (F), tumor (G), and vascular compression (H). I, Pie chart showing single vascular compression for PTC. Abbreviations: TN, trigeminal neuralgia; HFS, hemifacial spasm; PTC, painful tic convulsif; DVA, developmental venous malformation; PTA, persistent trigeminal artery variant; AVM, arteriovenous malformation; VBA, vertebrobasilar artery; PICA, posterior inferior cerebellar artery; VA, vertebral artery; PV, petrosal vein; BA, basilar artery; AICA, anterior inferior cerebellar artery; SCA, superior cerebellar artery; LA, labyrinthine artery.

Supplementary Files

This is a list of supplementary files associated with this preprint. Click to download.

- [SupplementaryFile.docx](#)
- [SupplementaryTable1.docx](#)