

Role of Ultrasound in the Diagnosis of Lymph Node Status in Axillary Lymph Node Metastases in Breast Cancer undergoing Neoadjuvant Chemotherapy

Yizhen Zhou

the Fifth Hospital of Xiamen

Lei Zhang

the First Hospital of China Medical University

Zining Jin

the First Hospital of China Medical University

Hailan Yu

the First Hospital of China Medical University

Siyu Ren

the First Hospital of China Medical University

Danyu Wang

the First Hospital of China Medical University

Chunyan Liang

the First Hospital of China Medical University

Guogang Wu

the First Hospital of China Medical University

Bo Chen (✉ chbyxl@163.com)

China Medical University Hospital <https://orcid.org/0000-0002-2216-2794>

Research article

Keywords: Breast cancer, Neoadjuvant chemotherapy, Axillary lymph node metastasis, Axillary ultrasound

Posted Date: July 7th, 2020

DOI: <https://doi.org/10.21203/rs.2.17922/v2>

License: © ⓘ This work is licensed under a Creative Commons Attribution 4.0 International License.

[Read Full License](#)

Abstract

Background: Axillary ultrasound (AUS) is one of the important bases for evaluating the axillary status of breast cancer patients. And it would be helpful for the reassessment of axillary lymph node status in these patients after neoadjuvant chemotherapy (NAC) and guide the selection of their axillary surgical options. The purpose of this study was to evaluate the diagnostic performance of ultrasound, and to find out the factors related to the outcome of ultrasound.

Methods: In this retrospective analysis, 172 patients (one bilateral breast cancer) with breast cancer and clinical positive axillary nodes, were enrolled. After NAC, all patients received mastectomy and axillary lymph node dissection (ALND). AUS was used before and after NAC to assess the axilla status.

Results: Of the 173 axillae, 137 (79.19%) had pathological metastasis after NAC. The accuracy, sensitivity, specificity, positive predictive value and negative predictive value of axillary ultrasound in this cohort were 68.21%, 69.34%, 63.89%, 87.96% and 35.38% respectively. Univariate analysis showed that primary axillary lymph node (ALN) short axis, progesterone receptors, hormone receptors, the tumor status after NAC, tumor reduction rate, ALN short axis after NAC, physical examination of axilla after NAC and pN impacted the results of AUS ($P = 0.000 \sim 0.040$). Multivariate analysis of the above indicators showed that ALN short axis after NAC and pN associated with AUS results independently.

Conclusion: AUS can accurately assess axilla status after NAC in most breast cancer patients. If the short axis of ALN ≥ 10 mm and AUS negative, SLNB could be chosen. However, AUS cannot detect residual lymph node disease after NAC in a short axis of the ALN < 10 mm.

Background

The status of axillary lymph node (ALN) is one of the most important prognostic factors in patients with breast cancer. Sentinel lymph node biopsy (SLNB) instead of axillary lymph node dissection (ALND) is widely used to evaluate ALN status in clinically node-negative patients with breast cancer, with less morbidity of surgical complications compared with ALND [1]. And its security had been tested by many trials in early-stage breast cancer [2,3]. However, whether it is applicable to the clinical evaluation of patients with negative ALNs after neoadjuvant chemotherapy (NAC) from locally advanced breast cancer with positive initial axillary lymph nodes remains controversial [4]. In ACOSOG Z1071 trial, in patients with breast cancer with clinical N1 stage receiving NAC, the false-negative rate (FNR) of SLN biopsy (SLNB) was 12.6% [5]. And the secondary endpoint of this trial was to evaluate the ALN status of patients after NAC by ultrasound. SLNB was performed in patients with negative axillary lymph nodes by ultrasound, and FNR was 9.8% [6]. Ultrasound is one of the important basic methods to evaluate the axillary condition of breast cancer patients [7], it is an important means for evaluating the efficacy of chemotherapy [8]. And it would be helpful for the reassessment of axillary lymph node status in these patients after NAC and guide the selection of their axillary surgical options.

The purpose of this study is to evaluate the diagnostic performance of ultrasound, and to find out the factors related to the outcome of ultrasound.

Methods

Patients

From August 2011 to December 2015, a retrospective analysis was performed, 172 patients with breast cancer who underwent ultrasound for assessment of

tumour response during NAC were included. One of the 172 patients had bilateral breast cancer, so we got 173 results of axillae. All 172 patients received a 21-day cycle NAC based on anthracycline and paclitaxel, followed by mastectomy and ALND.

The inclusion criteria included: (1) primary unilateral or bilateral breast cancer in women, histologically confirmed as breast cancer; (2) patients with positive axillary lymph nodes diagnosed by ultrasonography in our hospital before neoadjuvant chemotherapy and with clinical stages of cT0~4, cN1~3 and M0; (3) complete NAC and ALND, and review breast and axillary ultrasound before surgery.

The exclusion criteria included: (1) breast cancer during pregnancy and lactation; (2) occult breast cancer and cancer of accessory mamma; (3) patients with distant metastatic breast cancer during the same period; (4) patients with the second primary malignant tumor; (5) ultrasound evaluation of lymph node negative patients before neoadjuvant chemotherapy.

Ultrasound technique and interpretation

Ultrasound examinations were performed in all patients by a group of radiologists with rich experience in breast imaging. Lymph nodes were classified as normal if the radiologist was unable to visualize any lymph nodes on AUS or indicated that the lymph nodes were normal in morphologic appearance. Lymph nodes with abnormal morphology on AUS were classified as suspicious. ALN metastasis was suspected if the LN had any of the following morphologic characteristics: eccentric or concentric cortical thickening >3 mm, absent fatty hilum, a transverse axis-to-the[1]longitudinal axis ratio more than two or increased blood flow in the thickened cortex on Doppler image. Referring to the above conditions, the grading system was divided into five categories: (1) Normal without abnormal findings; (2) Benign abnormal findings; (3) Indeterminate or uncertain; (4) Suspicious of malignancy; (5) Highly suspicious of malignancy. In this study, ultrasound-diagnosed lymph nodes categories 1-3 were classified as negative, and categories 4-5 were classified as positive. The clinical efficacy evaluation refers to the evaluation criteria of the solid tumor efficacy evaluation standard (RECIST 1.1) guidelines.

Histopathological evaluation

The specimens of tumour and ALNs were evaluated according to the following histopathological features: tumour size, histological type of carcinoma, ALN metastasis, immunohistochemistry (IHC) and

so on. We defined $\geq 1\%$ positive cells as the positive boundary value, according to the ER/PR immunohistochemical detection guidelines issued by the American society of clinical oncology (ASCO)/ American college of pathologists (CAP) in 2010[6]. The intensity of HER2 staining was scored as 0, 1+, 2+ or 3+. Tumours with a 3+ score were classified as HER2 positive, and tumours with a 0 or 1+ score were classified as negative. In tumours with a 2+ score, gene amplification by using fluorescence in situ hybridization (FISH) was used to determine HER2 status. And the HER2 gene copy number ≥ 6.0 or HER-2/CEP17 ≥ 2.0 was defined as HER2 positive.

Statistical analysis

We used SPSS 20.0 software for statistical analysis. Single-factor analysis was performed using chi-square test (χ^2 test), and multiple-factor analysis was performed using logistical regression of the variables. The diagnostic performance of ultrasound for the evaluation of ALN after NAC was evaluated with receiver operating characteristic (ROC) curve analysis. The diagnostic accuracy was estimated by calculating the area under the ROC curve (Az value). $P < 0.05$ was considered statistically significant.

Results

Patient Characteristics

In this study 172 patients with T0-4, cN1-3, M0 breast cancer were enrolled, including one bilateral breast cancer, a total of 173 axillae. The median age of the patients was 51 years old, ranged from 25 to 76. Of these, 163 (94.2%) patients were invasive breast cancer. Eleven (6.4%) of the 173 had T1 tumors and 162 (93.6%) had T2-4 tumors. Tumors were hormone receptor-positive in 68.2% of cases, HER2-positive in 30.1%, and 90.2% showed a Ki-67 index $> 14\%$ (Table 1).

The number of NAC cycles less than or equal to 2 was 31 cases (17.9%), meanwhile, 142 cases (82.1%) received more than 2 NAC cycles. During the postoperative evaluation, the number of pathological complete response (PCR) was 8 cases (4.6%), the number of partial response (Pr) was 89 cases (51.4%), the number of progressive disease (PD) was 7 cases (4.0%), and the number of stable disease (SD) was 67 cases (38.7%). PCR and PR were regarded as effective for chemotherapy, and the effective rate of NAC was 56.0%. All of the patients' characteristics are listed in Table 1.

Table 1. Baseline characteristics

Parameter	N	N(%)
Age		
≤50	86	49.7
>50	87	50.3
Tumor histology		
Invasive breast cancer	163	94.2
DCIS	2	1.2
Not available	8	4.6
Clinical T category at diagnosis		
Tis(carcinoma in situ)	2	1.2
T1	9	5.2
T2	107	61.8
T3	49	27.8
T4	6	4.0
cN(Clinical staging of lymph nodes)		
cN1	97	56.1
cN2	1	0.6
cN3	75	43.4
TNM stage		
I A	5	2.9
I B	61	35.3
II A	29	16.9
II B	2	1.2
II C	75	43.4
Not available	1	0.6
Hormone receptor(HR) status		
Negative	50	28.9
Positive	118	68.2
Not available	5	2.9
HER2 status		
Negative	69	39.9
Positive	52	30.1
Not available	52	30.0
Ki-67 index		
<14%	10	5.8
≥14%	156	90.2
Not available	7	4.0
IHC classification		
Luminal	112	64.7
Her-2(+)	24	13.9
TNBC	21	12.1
Not available	16	9.3
Physical examination of axilla after NAC		
Palpable	37	21.4
No palpable adenopathy	136	78.6

No. of chemotherapy cycles		
<4	78	45.1
≥4	95	54.9

Association of Postchemotherapy AUS Findings With Pathologic Findings

After completion of neoadjuvant chemotherapy and within 4 weeks before surgery, all patients underwent an AUS to assess the morphologic appearance of the axillary lymph nodes. Lymph nodes were classified as normal if the radiologist was unable to visualize any lymph nodes on AUS or indicated that the lymph nodes were normal in morphologic appearance. Of 173 patients with postchemotherapy AUS results, 65(37.6%) had lymph nodes classified as normal on AUS, and 108(62.4%) had suspicious lymph nodes. Postchemotherapy AUS status was associated with nodal pathologic findings. Of the 65 patients with normal nodes as assessed by AUS, 42 patients (64.6%) were node positive on final pathology. In comparison, 95 (90.0%) of 108 patients who had suspicious nodes identified by AUS were found to have the residual node-positive disease. The sensitivity, specificity, positive predictive value, negative predictive value, and accuracy of postchemotherapy AUS for assessing axillary metastases were 69.3%, 63.9%, 88.0%, 35.4%, and 68.2%, respectively (Table 2). The ROC curve was plotted. The ROC showed that the area under the curve(AUC) was 0.703(P=0.000[95%CI[0.605–0.800]]), with a high statistical significance.

Table 2. Comparison of AUS and pathology after NAC

AUS	Pathological metastasis	
	Positive	Negative
Positive	95	13
Negative	42	23
Sensitivity		69.3%
Specificity		63.9%
Positive predictive value		88.0%
Negative predictive value		35.4%
Accuracy		68.2%

Table 3 lists tumor, patient and treatment characteristics for patients with normal lymph nodes as assessed by post chemotherapy AUS and for patients with suspicious lymph nodes. Physical examination of the axilla after NAC, number of chemotherapy cycles, primary tumor reduction rate, tumor status after NAC, ALN short axis after NAC and number of positive nodes differed significantly between

patients with normal lymph nodes and those with suspicious nodes as assessed by AUS. Patients with suspicious nodal status based on AUS were also more likely to have a greater number of positive ALN than patients with normal AUS findings (56.5% v 20.0%, respectively, with four or more positive ALN; $P<0.001$). Patients with suspicious lymph nodes by AUS were also more likely to have residual invasive disease in the breast (pathologic T2 or greater) than T1/T0 disease compared with patients with normal AUS findings (75.9% v 23.1%, respectively; $P=0.001$).

Table 3. AUS after NAC was compared in each group

Characteristic	AUS after NAC—		AUS after NAC (+)		P
	N	%	N	%	
Nodal category before NAC					0.010
cN1-2	45	69.2	53	49.1	
cN3	20	30.8	55	50.9	
Physical examination of axilla after NAC					0.000
Negative	62	95.4	74	68.5	
Positive	3	4.6	34	31.5	
No. of Chemotherapy cycles					0.047
<4	23	35.4	55	50.9	
≥4	42	64.6	53	49.1	
Primary tumor reduction rate					0.004
<30%	19	29.2	56	51.9	
≥30%	45	69.2	51	47.2	
Tumor status after NAC					0.001
T<2.0cm	30	46.2	25	23.1	
T≥2.0cm	34	52.3	82	75.9	
ALN short axis after NAC					0.000
<10mm	63	96.9	69	63.9	
≥10mm	2	3.1	39	36.1	
No. of positive nodes					0.000
0-3	52	80.0	47	43.5	
≥4	13	20.0	61	56.5	

Single-factor and multiple-factor analysis of AUS after NAC

In the single-factor analysis, we found that short axis of primary ALN, PR, HR, tumor size after NAC, tumor reduction rate, short axis of ALN after NAC, physical examination of the axilla after NAC made a difference in FNR of AUS after NAC which had statistically significant. And the results of the other subgroups were not statistically significant. All P values were greater than 0.05.

FNR of AUS was 17.6% in the subgroup with ≥4 ALNs metastasis (pN2-3), while FNR of AUS in the subgroup with no metastasis or < 4 ALNs metastasis (pN0-1) was 46.0%. The difference was significant ($P=0.000$). After NAC, 37 cases were clinically touched by enlarged lymph nodes, 34 cases of which were pathologically confirmed by lymph node metastasis, 3 cases of which was diagnosed as negative by

AUS. FNR of AUS in this part of cases was 8.8%, which was far lower than 37.9% ($P=0.001$) of the non-touched lymph nodes.

FNR diagnosed by AUS in the tumor $T \geq 2.0\text{cm}$ subgroup after NAC was 25%, far lower than 47.2% in the primary focus group $T < 2.0\text{cm}$. In the subgroup of primary focus reduction rate $< 30\%$, FNR was 19.7%, far lower than 41.4% in the PD group (the primary focus reduction rate $\geq 30\%$), and the difference was significant ($P=0.006$).

Further multiple-factor analysis was performed for the above results, the independent factors related to the FNR of AUS after NAC were: after NAC ALN short diameter and pN in installment, the NAC ALN after short diameter on the judgement of the state of AUS after NAC significance was bigger ($OR = 7.021$), the FNR AUS after NAC ALN short diameter $\geq 10\text{ mm}$ OR the group of less than 10% (5.4%), short diameter $< 10\text{ mm}$ in the two groups were greater than 10%. All the above data is listed in Table4 and Table5.

Table 4. FNR of AUS after NAC in 137 cases of ALNs positive in different subgroups

Characteristics	P(+)	US(+) n	US(-)		χ^2	<i>P</i>	Logistic <i>P</i>
			n	FNR(%)			
Age					3.12	0.077	
≤50	66	41	25	37.9			
>50	71	54	17	23.9			
Clinical T category at diagnosis					1.293	0.256	
Tis-T1-2	91	66	25	27.5			
T3-4	46	29	17	37.0			
Nodal category(axillary ultrasound)					2.945	0.086	
cN1-2	73	46	27	37.0			
cN3	64	49	15	23.4			
Primary ALN short axis					11.408	0.001	0.183
<1cm	44	22	22	50.0			
≥1cm	93	73	20	21.5			
Primary TNM stage					1.293	0.256	
I	46	29	17	37.0			
II	91	66	25	27.5			
ER(estrogen receptor)					0.610	0.435	
Negative	43	32	11	25.6			
Positive	90	61	29	32.2			
PR(progesterone receptor)					5.057	0.025	0.540
Negative	49	40	9	18.4			
Positive	84	53	31	36.9			
HR					4.220	0.040	0.931
Negative	36	30	6	16.7			
Positive	97	63	34	35.1			
Her-2(Human epidermal growth factor receptor-2)					1.058	0.589	
Negative	59	43	16	27.1			
Positive	34	24	10	29.4			
Ki-67					0.195	0.659	
≤14%	8	5	3	37.5			
>14%	123	86	37	30.1			
Immunohistochemistry classification					3.21	0.201	
Luminal	93	61	32	34.4			
Her-2(+)	15	11	4	26.7			
TNBC	16	14	2	12.5			
Physical examination of axilla after NAC					10.141	0.001	0.427
Negative	103	64	39	37.9			
Positive	34	31	3	8.8			
Chemotherapy cycles					1.366	0.243	
<4	69	51	18	26.1			
≥4	68	44	24	35.3			
Tumor reduction rate					7.516	0.006	0.559
<30%	66	53	13	19.7			

≥30%	70	41	29	41.4			
Tumor status after NAC					6.124	0.013	0.113
T0-1	36	19	17	47.2			
T2-4	100	75	25	25.0			
ALN short axis after NAC					28.453	0.000	0.019
<5mm	19	5	14	73.7			
≥5mm,<10mm	79	53	26	32.9			
≥10mm	37	35	2	5.4			
ALN long-to-short axis ratio after NAC					1.872	0.171	
<2	76	59	17	22.4			
≥2	51	34	17	33.3			
pN(Pathological stage of lymph node)					12.969	0.000	0.004
pN0-1	63	34	29	46.0			
pN2-3	74	61	13	17.6			

Table 5. Logistic results of AUS after NAC in 137 cases of ALNs positive in different subgroups

	Regression coefficient	Standard error	Wald	P	OR	95%CI of OR
short axis of ALN after NAC	1.949	0.831	5.502	0.019	7.021	1.378~35.776
pN	1.392	0.485	8.239	0.004	4.024	1.555~10.411
constant	-0.737	0.928	0.630			

Discussion

NAC has become the standard treatment not only in patients with locally advanced breast cancer but also in early invasive breast cancer in an attempt to downstage the primary cancer, to reduce micrometastasis, and to evaluate the susceptibility of chemotherapy drugs. Today ALND is still the preferred treatment for breast cancer patients with ALN positive after NAC. However, only 50% ~ 60% of the patients who received NAC have residual metastatic lesion of ALNs. And about 40% of patients after NAC have reached ALNs PCR, and this part of the patients should be avoided with excessive treatment to reduce a series of complications from ALND.

We need a method that can accurately evaluate the axillary status to guide the treatment after NAC. Herrada, J et al believed that ultrasound was the most accurate imaging examination method for the assessment of axillary status at present [7], while Klauber-Demore, N et al believed that ultrasound was not accurate enough for the assessment of axillary status after neoadjuvant chemotherapy for locally advanced breast cancer [8]. Whether SLNB can replace ALND to evaluate the axillary status of patients with clinically negative ALNs is controversial [4, 9-12]. ACOSOG Z1071 test and a number of studies have shown [5, 13-16] that AUS combined with SLNB after NAC can reduce the FNR of axillary diagnosis and

replace ALND to achieve the purpose of accurate assessment of axillary status. It has also been reported that [17] ultrasound and magnetic resonance imaging (MRI) have the same or more important value in accurately measuring the size of residual lesions of breast cancer after NAC.

In the Z1071 test [5,18], the evaluation criteria of AUS for ALN were: a maximum cortical thickness > 3 mm, absence of the fatty hilum significantly. The evaluation criteria in our institution were based on the shape is round, cortical thickness, the structure of the lymph node hilum of anomaly or disappear, blood flow is unusually rich, whether lymph node capsule indicators, combined with the above indicators, we simplified the grading system, the categories 4 ~ 5 was used as the criterion for suspicious lymph nodes. This system effectively improved the ultrasonic diagnosis value and helped clinicians to quickly locate ALN. This study found that AUS was used to assess the axillary status, its accuracy was 68.21%, higher than that in the ACOSOG Z1071 trials; the sensitivity and the FNR of our study were 69.34% and 30.6% respectively, while Z1071 test results were 65.15% and 34.85%. The performance of ultrasonography on diagnosis of this study was good. On the premise that SLNB technology was mature, ultrasound could attempt to evaluate the post-NAC axillary status combined with it.

This study suggests that ALN after NAC diagnosed as abnormal by AUS are more likely to have residual metastatic lesions and the load of lymph node metastatic lesions is greater. Among the 108 patients diagnosed with AUS abnormality after NAC, 95 (87.96%) patients had residual axillary lymph node metastasis (ALM) confirmed by final pathology. 42 (64.6%) of the 65 patients diagnosed with normal AUS results had ALM confirmed by final pathology, and only 13 (30.9%) had more than 4 ALM pieces, while 64.2% of the patients diagnosed with AUS abnormality had more than 4 ALM pieces. FNR of AUS in subgroup with more than 4 ALM pieces (pN2-3) was 17.6%, while FNR of AUS in subgroup with less than 4 ALM pieces (pN0-1) was 46.0%, with statistically significant difference ($P=0.000$). The results were the same as that of ACOSOG Z1071 test [5]. After NAC, 37 cases were clinically touched by enlarged lymph nodes, and 34 of which were pathologically confirmed to lymph node metastasis. AUS was diagnosed as negative in 3 cases of 34, and FNR was 8.8%, which was far lower than that (37.9%, $P=0.001$) of those who were negative by clinical palpation.

In this study, FNR of AUS decreased successively, 73.7%, 32.9% and 5.4%, respectively, in the three subgroups with the short diameter < 5 mm, $d < 10$ mm, and 10 mm after NAC, $P=0.000$. AUS, therefore, is not easy to find residual lymph node metastases with the short diameter < 5 mm. The accuracy of these patients with lymph nodes between 5 mm and 10 mm needs to be improved by improving the definition of ultrasound examination equipment and the technical level of ultrasound examination physicians, which is consistent with Feu et al.'s opinion [19] that AUS is more accurate in evaluating lymph nodes with diameters greater than 10 mm than those with diameters less than 10 mm. In this study, 37 cases with short diameter of lymph nodes greater than or equal to 10 mm after NAC were confirmed as lymph node metastasis, 2 of which showed no abnormalities in AUS and FNR was less than 10% (5.4%). Multi-factor analysis showed that the short diameter of lymph nodes after NAC was an independent factor affecting AUS diagnosis.

From the study, we found that patients diagnosed by AUS as normal after NAC had lower tumor load. 46.9% patients with normal AUS results had $T < 2.0\text{cm}$ after NAC, while 23.4% patients with abnormal AUS results had it. And, 86.2% patients with $T \geq 2.0\text{cm}$ after NAC were pathologically confirmed to have residual lymph node metastasis, while only 65.5% patients with $T < 2.0\text{cm}$ did it. Chua, B et al. [20] found that the pathological size of primary breast tumor T1 was less than or equal to 2.0cm, which was significantly lower than that of axillary lymph node metastasis at stage T2, consistent with the results of this study. The size of tumor after NAC affects the accuracy of AUS. The FNR diagnosed by AUS after NAC in the tumor $T > 2.0\text{cm}$ subgroup was 25%, far lower than the 47.2% of the original focus $T < 2.0\text{cm}$ group, and the difference was statistically significant. At the same time, it could be detected that for patients with a high response rate to NAC, the reduction rate of primary focus was more than 30% compared with $< 30\%$, the probability of lymph node transformation from positive to negative was higher (27.1% vs. 12.0%, $P=0.015$), and the burden of lymph node metastasis was smaller. FNR of the group with the reduction rate of primary focus $< 30\%$ was 19.7%, far lower than that of the group with PD (with the reduction rate of primary focus $> 30\%$), which was 41.4%, with a significant difference ($P=0.006$).

From the results of this study, it is not difficult to see that AUS is more likely to find residual lymph node lesions in patients with heavy lymph node metastasis, high tumor load and poor response rate to NAC. ALND should be further performed in patients diagnosed as abnormal by AUS. On the contrary, for patients with low lymph node metastasis load, low tumor load and good chemotherapy effect, AUS is difficult to find residual lymph node metastasis focus. It is insufficient to evaluate the axillary status of these patients only by AUS, and further combination with SLNB is needed to reduce the false negative rate, so as to accurately evaluate the axillary status. In the Z1071 test [5], 63% of patients diagnosed by AUS with normal SLNB and positive SLNB results did not find more metastatic lymph nodes in subsequent ALND. Therefore, patients diagnosed as normal by AUS after NAC combined with SLNB may be sufficient to assess whether axillary lymph node metastasis, avoid complications caused by ALND and improve the quality of life of patients.

The defect of this study is that not all the enrolled patients diagnosed as lymph node positive by ultrasound were pathologically confirmed before NAC. Compared with the pathological results, the results of ultrasound evaluation are subjective, and inaccurate evaluation may occur under certain conditions. Some inflammatory lymph nodes could not be excluded, it may influence the results of this study. Secondly, not all patients have completed the established NAC cycle number, compared with other studies that have completed all NAC treatment [5] the PCR rate was likely reduced. The population in this study has a higher tumor load and lymph node load, which might overestimate the diagnostic value of AUS after initial lymph node positive breast cancer before NAC. Finally, the proportion of patients with positive HR in this study was 68.2%. It is also worth reflecting on whether the efficacy of neoadjuvant therapy in these patients will affect the results of the study.

Conclusion

AUS has certain diagnostic value in evaluating ALNs status after NAC in breast cancer. Axillary status can be accurately evaluated in patients with lymph node metastasis, with high tumor burden and poor NAC reactivity. SLNB could be selected for the negative evaluation of AUS in patients with short ALN axis \geq 10mm after NAC. For patients with short ALN axis <10mm after NAC, AUS is unable to accurately detect residual lymph node lesions, and it is necessary to further evaluate the axillary status after NAC by combining other examination methods.

Abbreviations

AUS: axillary ultrasound; NAC: neoadjuvant chemotherapy; ALN: axillary lymph node; ALND: axillary lymph node dissection; SLNB: sentinel lymph node biopsy; FNR: false-negative rate; IHC: immunohistochemistry; ASCO: American society of clinical oncology; CAP: American college of pathologists; FISH: fluorescence in situ hybridization; ROC: receiver operating characteristic; PCR: pathological complete response; Pr: partial response; PD: progressive disease; SD: stable disease; HR: hormone receptor; AUC: area under the curve; ALM: axillary lymph node metastasis; ER: estrogen receptor; PR: progesterone receptor; Her-2: human epidermal growth factor receptor-2.

Declarations

The authors declare that they have no conflicts of interest.

Ethics approval and consent to participate

Not applicable.

Consent for publication

Not applicable.

Availability of data and material

The datasets used and/or analysed during the current study are available from the corresponding author on reasonable request.

Competing interests

The authors declare no competing financial interests.

Authors' contributions

This study was designed by BC. YZ and LZ performed the tests and data analyses. ZJ also contributed in data analysis. DW helped polish the language. HY and SR collected and collated the data. CL and GW helped with interpretation of data. YZ and LZ wrote the paper. All authors read and approved the final version of the manuscript.

Acknowledgement

Not applicable.

Fundings

This study was supported by Subject Development Project of China Medical University(No. 3110117053) and National Natural Science Foundation Project (No. 81372811).The funder in this study is Dr Chen, who is the corresponding author of this article.

References

1. Berveiller P, Mir O, Veyrie N, et al. The sentinel-node concept: a dramatic improvement in breast-cancer surgery [J]. *Lancet Oncol*, 2010, 11(9): 906.
2. Lyman GH, Giuliano AE, Somerfield MR, et al. American Society of Clinical Oncology guidelines recommendations for sentinel lymph node biopsy in early-stage breast cancer. *J Clin Oncol*. 2005;23(30):7703–20.
3. Veronesi U, Viale G, Paganelli G, et al. Sentinel lymph node biopsy in breast cancer: ten-year results of a randomized controlled study. *Ann Surg*. 2010;251(4):595–600.
4. Mocellin S, Goldin E, Marchet A, et al. Sentinel node biopsy performance after neoadjuvant chemotherapy in locally advanced breast cancer: A systematic review and meta-analysis. *Int J Cancer*, 2016, 138(2): 472-480.
5. Boughey J C, Ballman K V, Hunt K K, et al. Axillary Ultrasound After Neoadjuvant Chemotherapy and Its Impact on Sentinel Lymph Node Surgery: Results From the American College of Surgeons Oncology Group Z1071 Trial (Alliance). *J Clin Oncol*, 2015, 33(30): 3386-3393.
6. Hammond M E, Hayes D F, Dowsett M, et al. American Society of Clinical Oncology/College Of American Pathologists guideline recommendations for immunohistochemical testing of estrogen and progesterone receptors in breast cancer. *J Clin Oncol*, 2010, 28(16): 2784-2795.
7. Herrada J, Iyer R B, Atkinson E N, et al. Relative value of physical examination, mammography, and breast sonography in evaluating the size of the primary tumor and regional lymph node metastases in women receiving neoadjuvant chemotherapy for locally advanced breast carcinoma. *Clin Cancer Res*, 1997, 3(9): 1565-1569.
8. Klauber-Demore N, Kuzmiak C, Rager E L, et al. High-resolution axillary ultrasound is a poor prognostic test for determining pathologic lymph node status in patients undergoing neoadjuvant chemotherapy for locally advanced breast cancer. *Am J Surg*, 2004, 188(4): 386-389.
9. Fu J F, Chen H L, Yang J, et al. Feasibility and accuracy of sentinel lymph node biopsy in clinically node-positive breast cancer after neoadjuvant chemotherapy: a meta-analysis. *PloS one*, 2014, 9(9): e105316.
10. Lee H D, Ahn S G, Lee S A, et al. Prospective evaluation of the feasibility of sentinel lymph node biopsy in breast cancer patients with negative axillary conversion after neoadjuvant chemotherapy.

Cancer Res Treat, 2015, 47(1): 26-33.

11. Mittendorf E A, Caudle A S, Yang W, et al. Implementation of the American College of Surgeons Oncology Group Z1071 Trial Data in Clinical Practice: Is There a Way Forward for Sentinel Lymph Node Dissection in Clinically Node-Positive Breast Cancer Patients Treated with Neoadjuvant Chemotherapy?. Ann Surg Oncol, 2014, 21(8): 2468-2473.
12. Rebollo-Aguirre Á C, Gallego-Peinado M, Sánchez-Sánchez R, et al. Sentinel lymph node biopsy after neoadjuvant chemotherapy in patients with operable breast cancer and positive axillary nodes at initial diagnosis. Revista Española de Medicina Nuclear e Imagen Molecular (English Edition), 2013, 32(4): 240-245.
13. Shigekawa T, Sugitani I, Takeuchi H, et al. Axillary ultrasound examination is useful for selecting patients optimally suited for sentinel lymph node biopsy after primary systemic chemotherapy. Am J Surg, 2012, 204(4): 487-493.
14. Farrell T P, Adams N C, Stenson M, et al. The Z0011 Trial: Is this the end of axillary ultrasound in the pre-operative assessment of breast cancer patients?. Eur Radiol, 2015, 25(9): 2682-2687.
15. Harvey S C, Wolff A C. Does a Picture Make a Difference? Ultrasound Guidance in the Management of the Axilla After Neoadjuvant Chemotherapy. J Clin Oncol, 2015, 33(30): 3367-3369.
16. Maxwell F, De Margerie Mellon C, Bricout M, et al. Diagnostic strategy for the assessment of axillary lymph node status in breast cancer. Diagn Interv Imaging, 2015, 96(10): 1089-1101.
17. Vriens B E, De Vries B, Lobbes M B, et al. Ultrasound is at least as good as magnetic resonance imaging in predicting tumour size post-neoadjuvant chemotherapy in breast cancer. Eur J Cancer, 2016, 52: 67-76.
18. Le-Petross HT, McCall LM, Hunt KK, et al. Axillary Ultrasound Identifies Residual Nodal Disease After Chemotherapy: Results From the American College of Surgeons Oncology Group Z1071 Trial (Alliance). AJR Am J Roentgenol. 2018 Mar;210(3):669-676.
19. Feu J, Tresserra F, Fabregas R, et al. Metastatic breast carcinoma in axillary lymph nodes: in vitro US detection. Radiology, 1997, 205(3): 831-835.
20. Chua B, Ung O, Taylor R, et al. Frequency and predictors of axillary lymph node metastases in invasive breast cancer. ANZ J Surg, 2001, 71(12): 723-728.

Figures

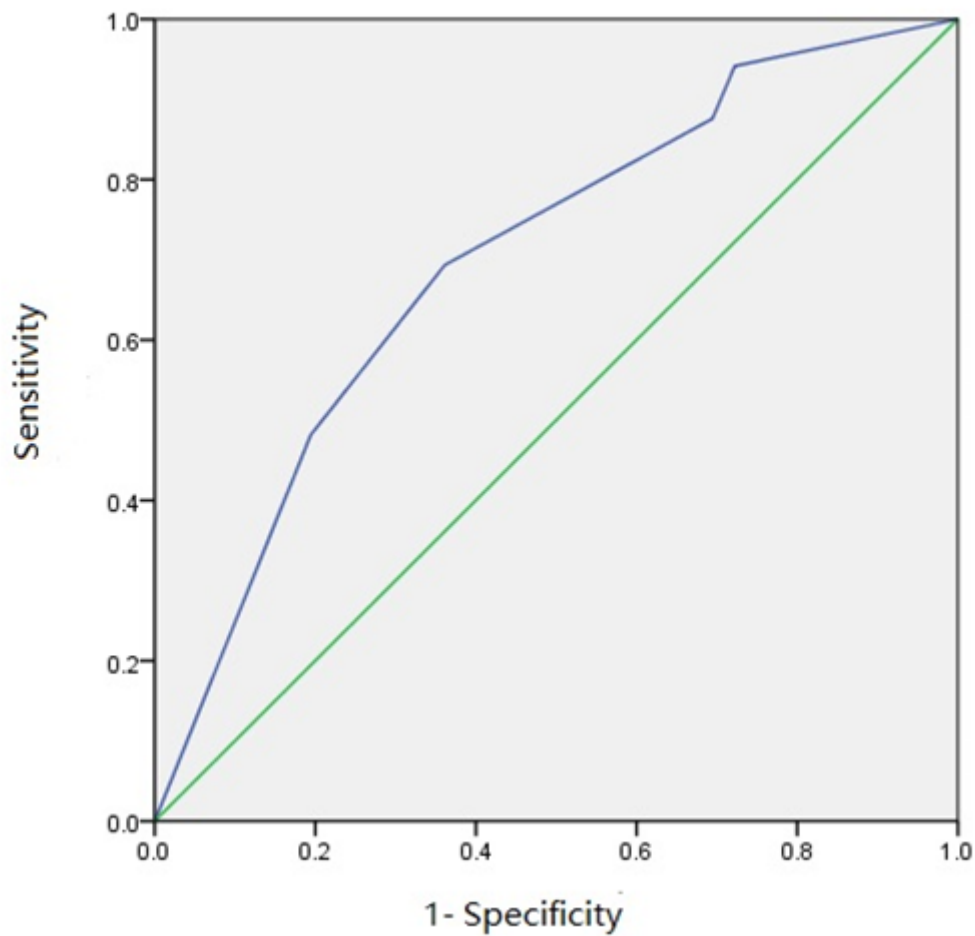


Figure 1

The ROC showed that the area under the curve(AUC) was 0.703($P=0.000$ 95%CI[0.6050.800]), with a high statistical significance.