

Predictors of Heart Failure Symptoms in Hereditary Hemorrhagic Telangiectasia Patients With Hepatic Arteriovenous Malformations

Lucas Russell Cusumano

University of California Los Angeles David Geffen School of Medicine <https://orcid.org/0000-0001-9710-8488>

Joseph A Tesoriero

David Geffen School of Medicine: University of California Los Angeles David Geffen School of Medicine

Craig B Wilsen

David Geffen School of Medicine: University of California Los Angeles David Geffen School of Medicine

James Sayre

David Geffen School of Medicine: University of California Los Angeles David Geffen School of Medicine

Matthew Quirk

David Geffen School of Medicine: University of California Los Angeles David Geffen School of Medicine

Justin P McWilliams (✉ JuMcWilliams@mednet.ucla.edu)

David Geffen School of Medicine: University of California Los Angeles David Geffen School of Medicine

Research

Keywords: Hereditary Hemorrhagic Telangiectasia, Arteriovenous malformations, High-output heart failure, Common hepatic artery, Computed tomography

Posted Date: August 23rd, 2021

DOI: <https://doi.org/10.21203/rs.3.rs-824554/v1>

License:   This work is licensed under a Creative Commons Attribution 4.0 International License.

[Read Full License](#)

Abstract

Background

Hepatic arteriovenous malformations (AVMs) in hereditary hemorrhagic telangiectasia (HHT) patients are most commonly hepatic artery to hepatic venous shunts which can result in high-output heart failure. This condition can be debilitating and is a leading cause of liver transplantation in HHT patients. However, it is not known what characteristics can discriminate between asymptomatic patients and those who will develop heart failure symptoms.

Results

176 patients with HHT were evaluated with computed tomography angiography (CTA) between April 2004 and February 2019 at our HHT Center of Excellence. 63/176 (35.8%) patients were found to have hepatic AVMs on CTA. 18 of these patients were excluded because of the presence of another condition which could confound evaluation of heart failure symptoms. In the remaining 45 patients included in our cohort, 25/45 (55.6%) patients were classified as asymptomatic and 20/45 (44.4%) were classified as symptomatic, and these groups were compared.

In symptomatic patients, mean common hepatic artery (CHA) diameter was significantly higher (11.1 versus 8.4 mm) and mean hemoglobin levels were significantly lower (10.7 vs 12.6 g/dL). A stepwise multiple logistic regression analysis demonstrated that both CHA diameter and hemoglobin level were independent predictors of heart failure symptoms with ORs of 2.554 (95% CI 1.372-4.754) and 0.489 (95% CI 0.299-0.799), respectively. The receiver operator characteristic (ROC) curve of our analysis demonstrated an AUC of 0.906 (95% CI 0.816–0.996), sensitivity 80.0% (95% CI 55.7-93.4%), and specificity 75.0% (95% CI 52.9-89.4%).

Conclusions

CTA is an effective and easily reproducible method to evaluate hepatic involvement of HHT. Utilizing CTA, clinical, and laboratory data we determined CHA diameter and hemoglobin level were independent predictors of heart failure symptoms.

Background

Hereditary hemorrhagic telangiectasia (HHT) is an autosomal dominant disorder characterized by the development of arteriovenous malformations (AVMs) in the skin, mucous membranes, brain and visceral organs (1). Hepatic manifestations of HHT are characterized by abnormal shunts that connect the hepatic arterial, hepatic venous or portal venous systems (2–5). Hepatic artery to hepatic vein shunts are the most common type, and may result in high-output cardiac failure secondary to low resistance and high flow (6, 7). High-output heart failure can become debilitating and is a leading cause of liver

transplantation in HHT patients (8–10). However, symptoms are nonspecific, often beginning with exertional dyspnea which may then progress to worsening dyspnea at rest (6).

Most patients with liver AVMs are asymptomatic (8). However, it is not known what characteristics can discriminate between the minority who will develop heart failure and the majority who will not. Furthermore, it is not known if prophylactic treatment of patients with liver AVMs can prevent development of symptoms. Current guidelines recommend treatment for liver AVMs only in symptomatic patients (11).

Computed tomography angiography (CTA) has been proposed as the most effective non-invasive modality for diagnosing hepatic involvement and evaluating different intrahepatic vascular shunts in HHT patients (12). CTA characteristics associated with the development of symptomatic heart failure have not previously been identified. The aim of this study is to describe the clinical and CTA characteristics of HHT patients with hepatic AVMs and their association with symptomatic heart failure.

Methods & Materials

Patients

The protocol for this retrospective study has been approved by the institutional review board and waived informed consent for participation. Our database comprised patients with a clinical or genetic diagnosis of HHT and a CTA including the hepatic vasculature performed at our HHT Center of Excellence between April 2004 and February 2019. Patients with a definite clinical diagnosis of HHT had at least three of the following criteria present: epistaxis, telangiectasia, visceral lesions, or a first degree relative with HHT (4).

Clinical characteristics

The presence of heart failure symptoms, defined as exercise-induced fatigue and dyspnea, were determined by review of the electronic medical record (EMR). Patients were classified as “asymptomatic” if there was no limit to physical activity and ordinary activity did not induce symptoms. Patients who exhibited exercise induced fatigue and dyspnea were considered “symptomatic,” and were classified using the New York Heart Association (NYHA) functional classification (13). We excluded patients with other conditions which may produce symptoms that overlap with heart failure, such as untreated pulmonary arteriovenous malformations (PAVMs), symptomatic anemia or asthma (14–19). Patients were deemed to have symptomatic anemia and excluded from the study if the heart failure symptoms correlated with hemoglobin levels or clinically significant bleeding events. We did not impose a hemoglobin level threshold to exclude patients. The presence of atrial fibrillation was determined from review of the EMR. Evidence of portal hypertension was assessed by the presence of splenomegaly, ascites, variceal bleeding, or encephalopathy (20).

Computed tomography angiography

CTA of the chest or abdomen was performed on a Siemens 64-detector scanner (Siemens, Erlangen, Germany). Chest CTA was performed from one centimeter superior to the lung apices to the mid kidney level using a single breath hold and with the patient supine and their arms above the head. Abdominal CTA was performed from one centimeter superior to the diaphragm to the iliac crest. Iodine-based contrast material was administered through a peripheral vein at a flow rate of 4.0 mL/s for a total of 100 mL followed by 100 mL saline bolus administered at the same rate. Image acquisition was triggered for chest CTA when the main pulmonary artery reached 100 Hounsfield unit (HU) attenuation and for abdominal CTA when the abdominal aorta just above the diaphragm reached 150 HU attenuation. Timing of image acquisition allowed for sufficient opacification of hepatic vasculature.

CTAs were evaluated for the presence of hepatic AVMs, diameter of the common hepatic artery (CHA), diameter of the right and left hepatic arteries, portal vein diameter and main pulmonary artery diameter.

Laboratory values

Laboratory values collected were the most recent with respect to CTA examination. Laboratory values included in this study were total bilirubin, albumin, platelet count, and hemoglobin.

Echocardiograms

For patients with echocardiograms available, the cardiac chamber size, ejection fraction, degree of valvular regurgitation and right ventricular systolic pressure were determined from the echocardiogram performed closest to date of the CTA. Chamber size of the right ventricle, left atrium, and left ventricle was graded on a scale from non-dilated to severely dilated by the interpreting cardiologist. Degree of valvular regurgitation of the tricuspid, mitral and aortic valves were graded on a scale from no regurgitation to severe regurgitation by the interpreting cardiologist.

Statistical analysis

Continuous data are expressed as mean +/- standard deviation. Comparisons between groups were made using the Fisher's exact test for categorical variables and Mann-Whitney analysis for continuous variables. *P* values < 0.05 were considered significant. Stepwise multiple logistic regression analysis was performed to determine factors impacting patients experiencing heart failure symptomatology. ORs were reported with 95% CIs. Factors used included age, CHA diameter, evidence of portal hypertension, portal vein diameter, pulmonary artery diameter, platelet count, and hemoglobin. Parameters with the highest performance in the stepwise logistic regression analysis were evaluated using receiver operator characteristics (ROC). AUC, sensitivity, and specificity were calculated to determine the diagnostic value of these parameters in determining the presence of heart failure symptoms. Statistical analyses were performed with SPSS software, version 24.0 (IBM Corp, Armonk, New York) and GraphPad Prism, version 8.0 (GraphPad Software, La Jolla, California).

Results

Patient characteristics

At our HHT Center of Excellence, 176 patients with definite HHT were evaluated with CTA between April 2004 and February 2019. Patient age ranged between 18 and 81 years old with a mean age of 49.5 (+/- 15.9) years. 107/176 (60.8%) were female. 63/176 (35.8%) patients were found to have hepatic AVMs on CTA. 18 of these patients were excluded because of the presence of another condition which could confound heart failure symptoms. As a result, our cohort included 45 patients (Fig. 1).

HHT was genetically confirmed in 30/45 (66.7%) patients; the remaining 15/45 (33.3%) patients met criteria for a clinical diagnosis of HHT (4). 25/45 (55.6%) patients were classified as asymptomatic and 20/45 (44.4%) were classified as symptomatic. There was no significant difference in age, sex or presence of portal hypertension between groups. Symptomatic patients were more likely to have a history of atrial fibrillation ($P = 0.0337$) (Table 1).

Table 1
Clinical characteristics

Characteristic	All (N = 45)	Asymptomatic (N = 25)	Symptomatic (N = 20)	P value
Age (years)	57.2 (+/- 15.8)	53.7 (+/- 16.6)	61.5 (+/- 13.9)	0.1195
Sex (female)	33 (73.3%)	18 (72.0%)	15 (75.0%)	> 0.9999
Atrial fibrillation	7 (15.6%)	1 (4.0%)	6 (30.0%)	0.0337
Portal hypertension	2 (4.4%)	0 (0%)	2 (10.0%)	0.1058

Computed tomography angiography

CHA diameter and right hepatic artery diameter were significantly larger in symptomatic patients. Left hepatic artery diameter was also larger in symptomatic patients but this difference did not reach statistical significance. Mean portal vein diameter was enlarged in both groups (> 13 mm), however there was no significant difference between groups. Pulmonary artery diameter was also not significantly different between groups (Table 2).

Table 2
Computed tomography angiography characteristics

Characteristic	All (N = 45)	Asymptomatic (N = 25)	Symptomatic (N = 20)	P value
Common hepatic artery diameter (mm)	9.6 (+/- 2.5)	8.4 (+/- 2.1)	11.1 (+/- 2.2)	0.0003
Left hepatic artery diameter (mm)	6.2 (+/- 2.2)	5.6 (+/- 2.1)	6.9 (+/- 2.1)	0.0882
Right hepatic artery diameter (mm)	7.5 (+/- 2.4)	6.4 (+/- 1.8)	8.8 (+/- 2.0)	0.0006
Portal vein diameter (mm)	14.6 (+/- 3.0)	14.2 (+/- 3.0)	15.1 (+/- 3.2)	0.5507
Pulmonary artery diameter (mm)	27.1 (+/- 4.9)	26.0 (+/- 4.7)	28.6 (+/- 4.7)	0.1014

Laboratory values

Laboratory values were available for 42/45 (93.3%) patients. Albumin was significantly higher in asymptomatic patients (4.2 g/dL vs 3.9 g/dL, $P = 0.0344$). Hemoglobin was also significantly higher in asymptomatic patients (12.6 g/dL vs 10.7 g/dL, $P = 0.0097$). Total bilirubin and platelet count showed no significant difference between groups (Table 3).

Table 3
Laboratory values characteristics

Characteristic	All	Asymptomatic	Symptomatic	P value
Albumin (g/dL)	4.1 (+/- 0.5)	4.2 (+/- 0.4)	3.9 (+/- 0.4)	0.0344
Total bilirubin (g/dL)	0.6 (+/- 0.3)	0.5 (+/- 0.2)	0.6 (+/- 0.4)	0.6863
Platelets ($10^3/\mu\text{L}$)	242.3 (+/- 89.1)	244.9 (+/- 69.8)	239.1 (+/- 109.7)	0.9535
Hemoglobin (g/dL)	11.7 (+/- 2.3)	12.6 (+/- 2.0)	10.7 (+/- 2.3)	0.0097

Echocardiogram characteristics

Echocardiogram studies were available in for 32/45 (71.1%) patients. Two of these patients had incomplete examinations with evaluation of one chamber size or valve unavailable. Although chamber enlargement and valvular regurgitation were more frequent in the symptomatic group, there was no significant difference between groups in echocardiogram characteristics (Table 4).

Table 4
Echocardiogram characteristics

Characteristic	All	Asymptomatic (N = 17)	Symptomatic (N = 18)	P value
Right ventricle dilation	6 (19.4%)	1 (5.9%)	5 (27.8%)	0.1774
Left atrial dilation	21 (65.6%)	8 (47.1%)	13 (72.2%)	0.1756
Left ventricle dilation	7 (21.9%)	3 (17.6%)	4 (22.2%)	> 0.9999
Tricuspid regurgitation	15 (48.4%)	5 (29.4%)	10 (58.8%) ¹	0.1663
Mitral regurgitation	10 (31.3%)	3 (17.6%)	7 (38.9%)	0.2642
Aortic regurgitation	8 (25.0%)	3 (17.6%)	5 (27.8%)	0.6906
Ejection fraction	63.6 (+/- 4.7)	63.5 (+/- 3.9)	63.3 (+/- 5.3)	0.8907
Right ventricular systolic pressure	34.1 (+/- 18.1)	33.9 (+/- 15.0)	38.8 (+/- 17.9)	0.4854

¹Echocardiogram of characteristic unavailable for one patient

Predictors of heart failure symptoms

In the stepwise logistic regression analysis, CHA diameter and hemoglobin were determined to be independent predictors of heart failure symptoms (Table 5). To assess the utility of these quantitative parameters as diagnostic tools, we performed ROC curve analysis. The ROC curve shows an AUC of 0.906 (95% CI 0.816–0.996), sensitivity 80.0% (95% CI 55.7–93.4%), and specificity 75.0% (95% CI 52.9–89.4%) (Fig. 2).

Table 5
Significant predictors of heart failure symptoms as determined by stepwise logistic regression analysis

Characteristic	OR	95% CI
Common hepatic artery diameter (mm)	2.554	1.372–4.754
Hemoglobin (g/dL)	0.489	0.299–0.799

Discussion

Hepatic involvement of HHT is a complex process involving shunts between hepatic arterial, hepatic venous or portal venous systems (9, 12). Hepatic AVMs may be present in up to 74% of HHT patients and several modalities have been utilized in their detection and monitoring (5). Hepatic angiography is

considered the gold standard to detect subtle abnormalities indicative of hepatic AVMs, however it is limited by the invasive nature of the procedure and has largely been replaced by non-invasive modalities such as ultrasonography and CTA (21). While it is known that CTA can readily distinguish between different hepatic shunts and is often performed to characterize hepatic AVMs, no previous studies have quantified the association between CTA findings and the presence of heart failure symptoms in HHT patients (1, 5, 22).

CTA may be superior to ultrasonography in detecting and characterizing hepatic AVMs (11, 12). Although hepatic AVM screening is not typically performed in HHT patients (10, 21), CTA including the hepatic vasculature is often available in these patients because of the frequent use of chest CTA to screen or diagnose pulmonary AVMs. A routine chest CTA protocol often includes much or all of the hepatic parenchyma and vasculature, and thus CTA chest can serve a dual purpose of screening for both lung and liver AVMs. Identifying these hepatic AVMs and subsequently assessing their risk may lead to better outcomes even in initially asymptomatic HHT patients due to the early detection of hepatic AVM related complications (10, 21).

The results of our multivariate analysis suggest that the degree of CHA dilation is an independent predictor of heart failure symptoms. Mean CHA diameter was significantly higher in symptomatic patients (11.1 versus 8.4 mm), and our data showed 2.6 times greater odds of having heart failure symptoms with each 1 mm increase in CHA diameter. These results are compatible with an ultrasonography study which demonstrated that high output heart failure only occurred in higher grade hepatic vascular malformations (10). This ultrasound grading system is reproducible by trained ultrasonographers and incorporates factors such as dilation of the hepatic vasculature and vascular flow abnormalities (23). Ultrasonography benefits by being low cost with a high sensitivity and specificity for liver AVM detection (10, 23–25). However, it requires capable and experienced ultrasonographers, and the subjectivity of the grading system may lead to discrepancies between operators. On the other hand, measurement of the CHA diameter using CTA is unambiguous and is not technologist dependent.

Symptomatic anemia overlaps with heart failure symptoms, and hemoglobin less than 7 g/dL may directly lead to heart failure in a mechanism that expands extracellular plasma volumes from increased sympathetic and renin-angiotensin activity (26, 27). Symptoms are temporary as correction of anemia demonstrates rapid and complete regression of anemia-related high output heart failure (26). We excluded patients who experienced symptoms correlating to their anemia because of the possible overlap with heart failure symptoms. None of the patients in our cohort had hemoglobin levels less than 7 g/dL at the time of testing. Nevertheless, mean hemoglobin levels were significantly lower in symptomatic patients (10.7 vs 12.6 g/dL). Our multiple logistic regression analysis determined hemoglobin to be an independent predictor of heart failure symptoms with an OR 0.489 for each 1 g/dL increase of hemoglobin.

In our stepwise logistic regression analysis the combination of these two independent variables, CHA diameter and hemoglobin level, allows for excellent discrimination between patients who do and do not

have heart failure symptoms with an AUC of 0.906. Employing the ORs respective to both CHA diameter and hemoglobin may help clinicians quantify risks to their patients.

Most patients in our cohort exhibited normal ejection fractions and a non-dilated left ventricle. In the remaining cardiac chambers, dilation was more frequently seen in the symptomatic group, though these differences were not statistically significant. Left atrial enlargement, for example, occurred in 72.2% of symptomatic patients, versus 47.1% of asymptomatic patients. The relatively small sample size likely contributed to this difference not reaching statistical significance and left atrial enlargement may be prognostic in a larger sample size. Additionally, the degree of regurgitation was higher in symptomatic patients but this also did not reach statistical significance. Although further research is needed, echocardiograms should continue to be utilized to monitor cardiac manifestations of HHT (28, 29).

Initial treatment of high-output heart failure secondary to liver AVMs is supportive and includes diuretics, salt and fluid restriction, beta-blockers and maintaining adequate hemoglobin levels (1, 20). Bevacizumab, an anti-angiogenic agent, has been successfully used to reduce shunting and mitigate symptoms of high-output heart failure, but may expose patients to adverse events including hypertension and arterial thromboembolism (30). Endovascular embolization is infrequently performed because of high complication risk from ischemic cholangitis, ischemic cholecystitis or hepatic necrosis (21). Orthotopic liver transplant has been proposed as the only definitive curative treatment, but is typically reserved for patients with severe complications related to hepatic AVMs (8, 21, 31). The current study shows only association, not causation, but measurement of CHA diameter and hemoglobin may help identify patients who are at higher risk of development of heart failure symptoms. This group may benefit from more aggressive correction of anemia, more frequent monitoring of symptoms and regular echocardiography. Further research is needed to explore if early or prophylactic treatment of this higher-risk group could improve outcomes associated with hepatic AVMs.

Our study had limitations inherent to studies with a small sample size performed at a single academic center and a retrospective design. Patients at our institution are not universally screened for hepatic AVMs and abdominal CTAs were often performed in patients with suspected hepatic AVMs due to symptoms. This likely led to the high proportion of symptomatic patients in our cohort. In our study, 44.4% of patients with hepatic AVMs were classified as having symptoms attributed to hepatic AVMs compared to the 8%-15% of patients reported in the literature (5, 21, 23). Although chest CTAs were typically performed to screen for or evaluate PAVMs, they were included in this study because our chest CTA protocol includes the liver parenchyma and the hepatic vasculature. It is possible that hepatic AVMs in the inferior liver could have been excluded from the scan plane in some patients, causing misclassification. These two factors could have led to exclusion of some patients with small, asymptomatic hepatic AVMs which would have only been detected by more extensive screening.

Conclusion

CTA is an effective and easily reproducible method to evaluate hepatic involvement of HHT. Combining CTA, clinical and laboratory data we found that common hepatic artery diameter and hemoglobin level were significantly associated with heart failure symptoms.

Abbreviations

AVM- arteriovenous malformation

CHA- common hepatic artery

CTA- computed tomography angiography

EMR- electronic medical record

HHT- hereditary hemorrhagic telangiectasia

HU- Hounsfield unit

NYHA- New York Heart Association

PAVM- pulmonary arteriovenous malformations

ROC- receiver operator characteristic

AUC- area under curve

Declarations

Ethics approval and consent to participate

The protocol for this retrospective study has been approved by the institutional review board and waived informed consent for participation.

Consent for publication

Not applicable

Availability of data and materials

The datasets generated and/or analysed during the current study are not publicly available due concerns for patient privacy but are available from the corresponding author on reasonable request.

Competing interests

Dr. Justin P. McWilliams, wishes to disclose consultancy fees from Penumbra and Johnson & Johnson. We have no commercial affiliation or consultancy that could be construed as a conflict of interest with

respect to the submitted data.

Funding

Not applicable

Authors' contributions

LC, JT, CW, and MQ and performed data collection to form data set. All authors analyzed and interpreted patient data. All authors read and approved the final manuscript.

Acknowledgements

Not applicable

References

1. Garg N, Khunger M, Gupta A, Kumar N. Optimal management of hereditary hemorrhagic telangiectasia. *J Blood Med.* 52014. p. 191-206.
2. Reilly PJ, Nostrant TT. Clinical manifestations of hereditary hemorrhagic telangiectasia. *Am J Gastroenterol.* 1984;79(5):363-7.
3. McDonald JE, Miller FJ, Hallam SE, Nelson L, Marchuk DA, Ward KJ. Clinical manifestations in a large hereditary hemorrhagic telangiectasia (HHT) type 2 kindred. *American journal of medical genetics.* 2000;93(4):320-7.
4. Shovlin CL, Guttmacher AE, Buscarini E, Faughnan ME, Hyland RH, Westermann CJ, et al. Diagnostic criteria for hereditary hemorrhagic telangiectasia (Rendu-Osler-Weber syndrome). *American journal of medical genetics.* 2000;91(1):66-7.
5. Ianora AA, Memeo M, Sabba C, Cirulli A, Rotondo A, Angelelli G. Hereditary hemorrhagic telangiectasia: multi-detector row helical CT assessment of hepatic involvement. *Radiology.* 2004;230(1):250-9.
6. Bernard G, Mion F, Henry L, Plauchu H, Paliard P. Hepatic involvement in hereditary hemorrhagic telangiectasia: clinical, radiological, and hemodynamic studies of 11 cases. *Gastroenterology.* 1993;105(2):482-7.
7. Trotter JF, Suhocki PV, Lina JR, Martin LW, Parrish JL, Swankowski T. Hereditary hemorrhagic telangiectasia causing high output cardiac failure: treatment with transcatheter embolization. *Am J Gastroenterol.* 1998;93(9):1569-71.
8. Lerut J, Orlando G, Adam R, Sabbà C, Pfitzmann R, Klempnauer J, et al. Liver transplantation for hereditary hemorrhagic telangiectasia: Report of the European liver transplant registry. *Ann Surg.* 2006;244(6):854-62; discussion 62-4.
9. Garcia-Tsao G. Liver involvement in hereditary hemorrhagic telangiectasia (HHT). *J Hepatol.* 2007;46(3):499-507.

10. Buscarini E, Leandro G, Conte D, Danesino C, Daina E, Manfredi G, et al. Natural History and Outcome of Hepatic Vascular Malformations in a Large Cohort of Patients with Hereditary Hemorrhagic Telangiectasia. *Digestive Diseases and Sciences*. 2011;56(7):2166-78.
11. Buscarini E, Plauchu H, Garcia Tsao G, White Jr. RI, Sabbà C, Miller F, et al. Liver involvement in hereditary hemorrhagic telangiectasia: consensus recommendations. *Liver International*. 2006;26(9):1040-6.
12. Wu JS, Saluja S, Garcia-Tsao G, Chong A, Henderson KJ, White RI. Liver Involvement in Hereditary Hemorrhagic Telangiectasia: CT and Clinical Findings Do Not Correlate in Symptomatic Patients. *American Journal of Roentgenology*. 2006;187(4):W399-W405.
13. Dolgin M, New York Heart A, Criteria C. Nomenclature and criteria for diagnosis of diseases of the heart and great vessels. Boston: Little, Brown; 1994.
14. Cartin-Ceba R, Swanson KL, Krowka MJ. Pulmonary arteriovenous malformations. *Chest*. 2013;144(3):1033-44.
15. Cusumano LR, Duckwiler GR, Roberts DG, McWilliams JP. Treatment of Recurrent Pulmonary Arteriovenous Malformations: Comparison of Proximal Versus Distal Embolization Technique. *Cardiovasc Intervent Radiol*. 2020;43(1):29-36.
16. Gossage JR, Kanj G. Pulmonary arteriovenous malformations. A state of the art review. *Am J Respir Crit Care Med*. 1998;158(2):643-61.
17. Berliner D, Schneider N, Welte T, Bauersachs J. The Differential Diagnosis of Dyspnea. *Deutsches Ärzteblatt International*. 2016;113(49):834-45.
18. Porter WB, James GW. The heart in anemia. *Circulation*. 1953;8(1):111-6.
19. Storms WW. Review of Exercise-Induced Asthma. *Medicine & Science in Sports & Exercise*. 2003;35(9):1464-70.
20. Al-Busafi SA, McNabb-Baltar J, Farag A, Hilzenrat N. Clinical manifestations of portal hypertension. *Int J Hepatol*. 2012;2012:203794.
21. Faughnan ME, Palda VA, Garcia-Tsao G, Geisthoff UW, McDonald J, Proctor DD, et al. International guidelines for the diagnosis and management of hereditary haemorrhagic telangiectasia. *Journal of medical genetics*. 2011;48(2):73-87.
22. Carette M-F, Nedelcu C, Tassart M, Grange J-D, Wislez M, Khalil A. Imaging of hereditary hemorrhagic telangiectasia. *Cardiovascular and interventional radiology*. 2009;32(4):745-57.
23. Buscarini E, Danesino C, Olivieri C, Lupinacci G, De Grazia F, Reduzzi L, et al. Doppler ultrasonographic grading of hepatic vascular malformations in hereditary hemorrhagic telangiectasia – results of extensive screening. *Ultraschall Med*. 2004;25(5):348-55.
24. Caselitz M, Bahr MJ, Bleck JS, Chavan A, Manns MP, Wagner S, et al. Sonographic criteria for the diagnosis of hepatic involvement in hereditary hemorrhagic telangiectasia (HHT). *Hepatology*. 2003;37(5):1139-46.

25. Bodner G, Peer S, Karner M, Perkmann R, Neuhauser B, Vogel W, et al. Nontumorous Vascular Malformations in the Liver. *Journal of Ultrasound in Medicine*. 2002;21(2):187-97.
26. Anand IS, Gupta P. Anemia and Iron Deficiency in Heart Failure: Current Concepts and Emerging Therapies. *Circulation*. 2018;138(1):80-98.
27. Brannon ES, Merrill AJ, Warren JV, Stead EA. The Cardiac Output in Patients with Chronic Anemia as Measured by the Technique of Right Atrial Catherization. *J Clin Invest*. 1945;24(3):332-6.
28. Cavel A, Bleuzen A, Bertrand P, Patat F, Cottier JP. Comparison between Doppler ultrasonography and multiphase multidetector-row computed tomography in the detection of liver involvement in Rendu-Osler disease: An analysis of 62 patients. *Diagnostic and interventional imaging*. 2016;97(4):451-9.
29. Gincul R, Lesca G, Gelas-Dore B, Rollin N, Barthelet M, Dupuis-Girod S, et al. Evaluation of previously nonscreened hereditary hemorrhagic telangiectasia patients shows frequent liver involvement and early cardiac consequences. *Hepatology*. 2008;48(5):1570-6.
30. Buscarini E, Botella LM, Geithoff U, Kjeldsen AD, Mager HJ, Pagella F, et al. Safety of thalidomide and bevacizumab in patients with hereditary hemorrhagic telangiectasia. *Orphanet Journal of Rare Diseases*. 2019;14(1):28.
31. Dupuis-Girod S, Chesnais AL, Ginon I, Dumortier J, Saurin JC, Finet G, et al. Long-term outcome of patients with hereditary hemorrhagic telangiectasia and severe hepatic involvement after orthotopic liver transplantation: a single-center study. *Liver Transpl*. 2010;16(3):340-7.

Figures

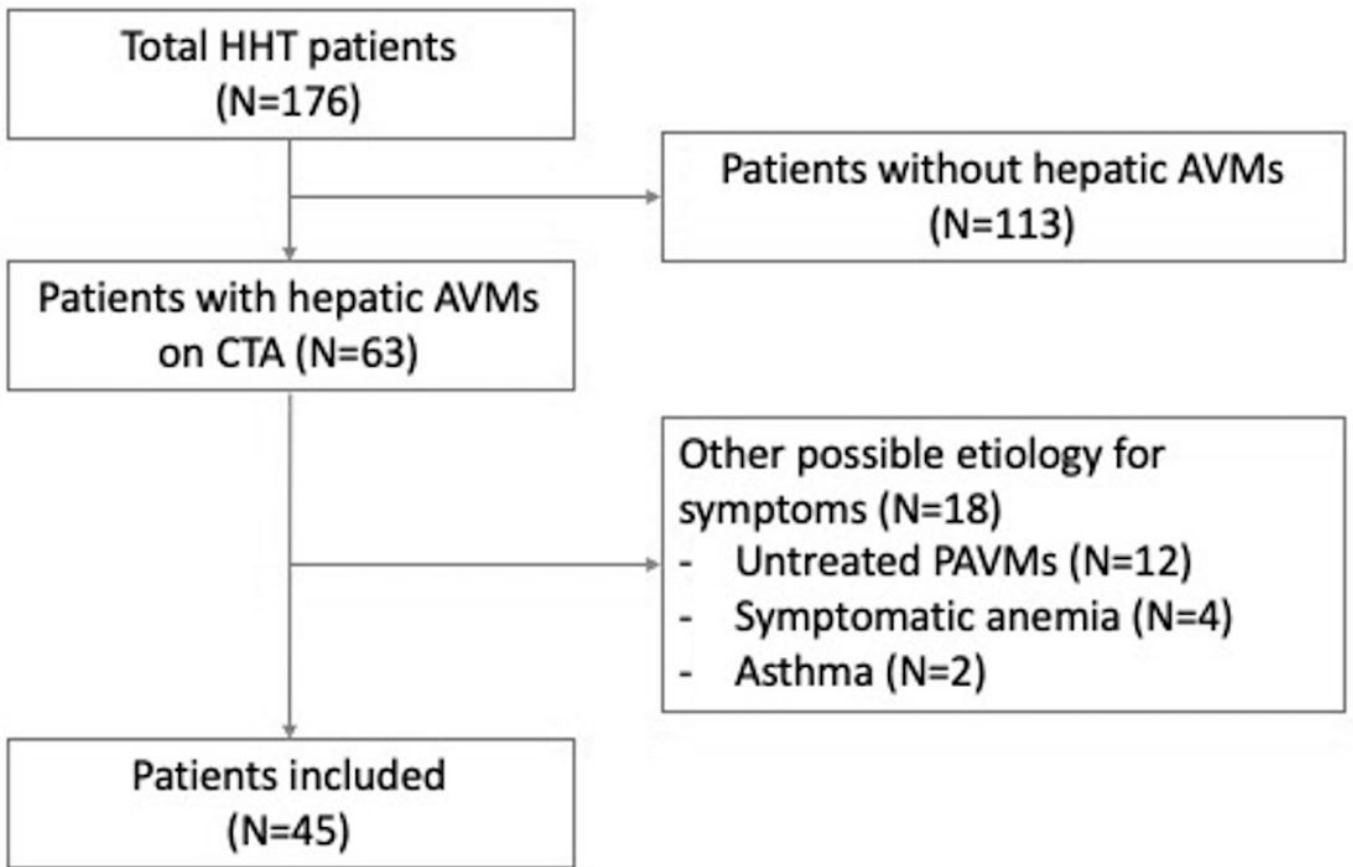


Figure 1

Flow chart of patient inclusion

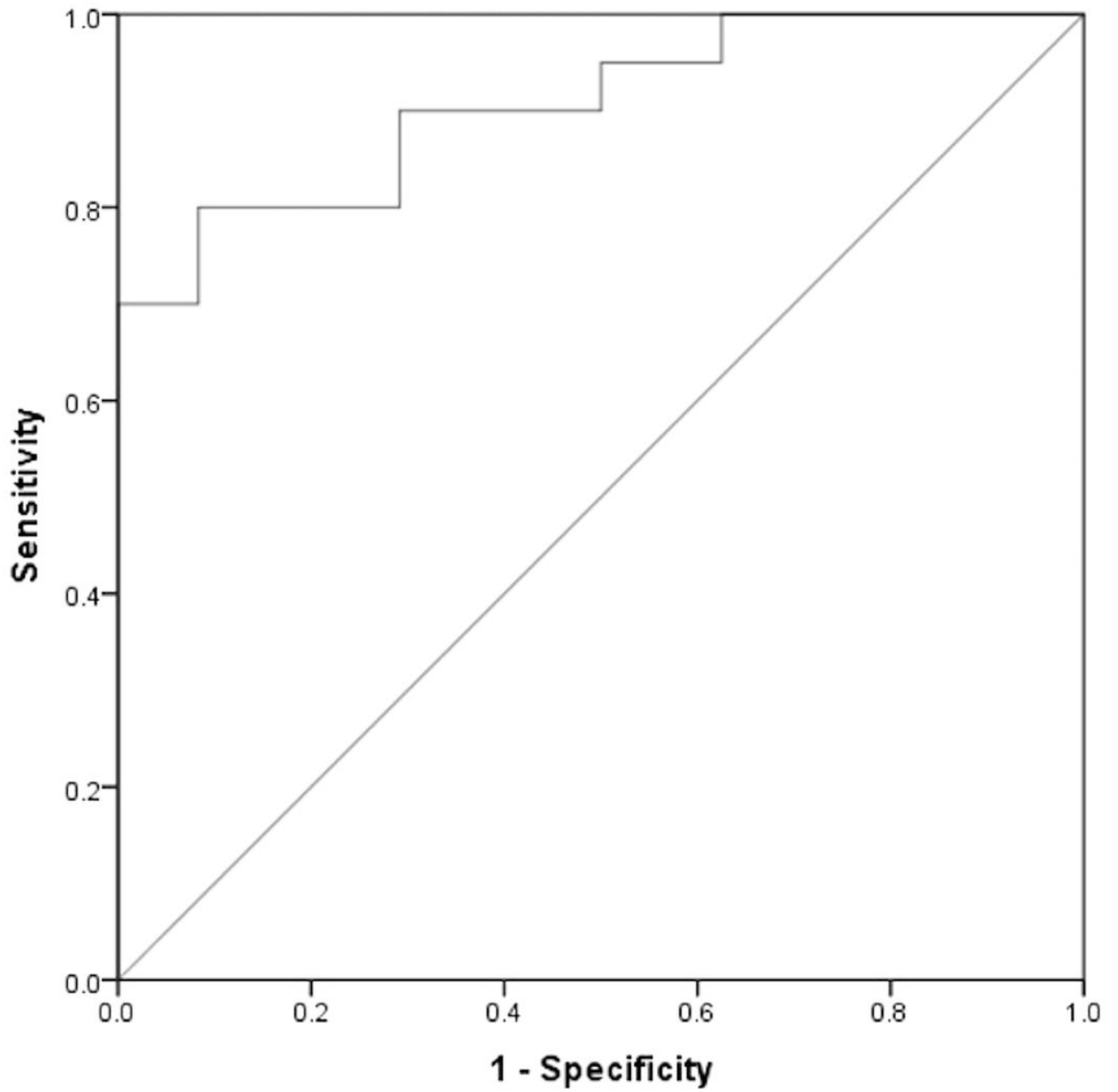


Figure 2

ROC curve of variables with the highest performance in the stepwise multivariate logistic regression analysis