

# Respiratory Rehabilitation After Blood Transfusion in a COVID-19 Patient: A Case Report

**Mohammad Javad Mousavi**

Tehran University of Medical Sciences

**Narges Obeidi**

Bushehr University of Medical Sciences

**Saeed keshmiri**

Bushehr University of Medical Sciences

**Farzan Azodi**

Bushehr University of Medical Sciences

**Jamile Kiyani**

Bushehr University of Medical Sciences

**Farhad Abbasi** (✉ [jj\\_immuno@yahoo.com](mailto:jj_immuno@yahoo.com))

Bushehr University of Medical Sciences

---

## Case Report

**Keywords:** COVID-19, SARS-CoV-2, hypoxemia, PRBC transfusion, case report

**DOI:** <https://doi.org/10.21203/rs.3.rs-78131/v1>

**License:**   This work is licensed under a Creative Commons Attribution 4.0 International License.

[Read Full License](#)

---

# Abstract

**Background:** The coronavirus disease 2019 (COVID-19), caused by severe acute respiratory syndrome coronavirus 2 (SARS-CoV-2), has been identified as the most crucial threat of the century. Due to severe pneumonia and acute respiratory distress syndrome (ARDS), the SARS-CoV-2 can cause shortness of breath, hypoxemia, and the need to mechanical ventilation, intensive care unit (ICU) management, and eventual death. We have tried to use a non-invasive approach to prevent patient from needing respiratory support with invasive ventilation (IV). Here, for the first time, improvement of oxygen delivery and oxygen saturation levels were observed in a COVID-19 patient using packed red blood cells (PRBCs) transfusion.

**Case presentation:** A 63-year-old man with a history of smoking and addiction who came to our hospital facility with fever, shortness of breath and decreased blood oxygen saturation. High-resolution chest CT revealed bilateral and multifocal ground-glass opacities consistent with COVID-19. Subsequently, the COVID-19 infection was confirmed by real-time polymerase chain reaction (qRT-PCR) assay of the upper respiratory tract.

**Conclusions:** Oxygen delivery and oxygen saturation improvement were observed in the COVID-19 patient, after PRBCs transfusions.

## 1. Background

The coronavirus disease 2019 (COVID-19) is an infection caused by the severe acute respiratory syndrome coronavirus 2 (SARS-CoV-2) [1, 2]. The first report of this disease, which was first introduced as the novel coronavirus (2019-nCoV) [3], was in late 2019 in Wuhan, China's Hubei province. It quickly spread as an epidemic in China throughout and then a worldwide pandemic [4, 5]. SARS-CoV-2 is the third most important coronavirus after severe acute respiratory syndrome coronavirus (SARS-CoV, 2002) and Middle East respiratory syndrome coronavirus (MERS-CoV, 2012), in the last two decades. Increased pro-inflammatory mediators play a critical role in acute lung injury (ALI), acute respiratory distress syndrome (ARDS), and lethal pneumonia caused by pathogenic human coronaviruses (hCoVs) such as SARS and MERS [6, 7].

Based on previous experience with SARS, aerosol-generating procedures such as tracheal intubation or tracheostomy, are considered as high-risk methods for transmitting the SARS-CoV-2 infection to health care workers [8, 9]. Here, we have tried to use a non-invasive approach to prevent patients from needing respiratory support with invasive ventilation (IV) and the use of endotracheal tubes. In this study, for the first time, improvement of oxygen delivery and oxygen saturation levels were observed in a patient with COVID-19 using packed red blood cells (PRBCs) transfusion.

## 2. Case Presentation

A 63-year-old single man came to our institute (Bushehr medical university hospital, Bushehr, Iran, a designated COVID-19 referral center), with the manifestations of fever and shortness of breath on March

22, 2020. The patient had a history of smoking and addiction, but no history of respiratory or cardiovascular diseases, or chemotherapy and transplantation. Upon arrival, the patient was febrile (38.9 °C). His heart rate (HR) was 100, with high blood pressure (BP) (160/80 mmHg). Besides, his oxygen saturation was 89% in room air.

Laboratory investigations of the blood parameters showed that the complete blood count (CBC) was normal, except for hemoglobin (Hgb) levels. His white blood cell (WBC) count was  $8.5 \times 10^9/L$  (normal range:  $4-11 \times 10^9/L$ ), the lymphocyte count was  $1.24 \times 10^9/L$  (normal range:  $1-4.8 \times 10^9/L$ ), blood platelet (Plt) count was  $286 \times 10^9/L$  (normal range:  $140-400 \times 10^9/L$ ), and hemoglobin levels were 6.8 g/dL (normal range: 11.5–15.5 g/dL). Other lab measurements were within normal ranges, including renal and liver function tests.

According to the patient's history, the interval between the first symptoms and severe shortness of breath was one week. A high-resolution computed tomography (HRCT) scan of the chest was performed (Fig. 1) several days after the onset of shortness of breath, which led to a high suspicion of SARS-CoV-2 infection, due to the presence of the bilateral multifocal ground-glass opacity (GGO) pattern. Subsequently, the COVID-19 infection diagnosis was confirmed by an upper respiratory tract swab (nasopharyngeal and oropharyngeal) for molecular evaluation, using the real-time reverse polymerase-transcriptase chain reaction (rRT-PCR method).

As soon the patient was admitted to the ward, he received a hydroxychloroquine 400 mg stat and 200 mg bid, azithromycin 250 mg daily, and ceftriaxone 1gr bid. The fever continued until the 3rd. day of admission. Ceftriaxone was discontinued and meropenem and vancomycin were substituted on the 4rd. day of admission. Also, for control of fever intravenous acetaminophen (Apotel) was used. The patient's oxygen saturation was 89% in room air, after receiving supplemental oxygen by mask it improved but after its removal, it declined again. Dyspnea and shortness of breath continued. We decided to transfused packed RBC (PRBC) to increase hemoglobin, in accordance to improve oxygen saturation. After transfusion of the first unit of PRBCs, the patient's hemoglobin levels and oxygen saturation were evaluated. Blood hemoglobin levels and oxygen saturation after transfusion of the first PRBC unit increased to 8.7 g/dL and 91% in the room air, respectively. Improving of general condition, dyspnea, shortness of breath, and oxygen saturation, after the first PRBC unit, we decided to transfuse the second PRBC unit. These values were raised to 9.9 g/dL and 96%, respectively, after the transfusion of the second PRBC unit. After receiving two PRBC units, the patient's general condition improved greatly and dyspnea disappeared. At this stage, a CT scan was taken again from the patient, which indicated an improvement in the condition of the lung (Fig. 2).

The patient was discharged from the hospital on March 29, 2020, one week after the initial visit to the hospital, in good general condition, without fever and shortness of breath. In outpatient follow up two weeks after hospital discharge his general condition was good, there was no fever, dyspnea and shortness of breath, and oxygen saturation in room air was 97%.

### 3. Discussion And Conclusions

COVID-19 is a global pandemic that affects many people with reduced oxygen saturation levels and requires long-term invasive ventilation supports [10, 11]. Acute respiratory failure along with acute hypoxemia is the major leading cause of death in COVID-19 patients [12]. According to recent guidelines, tracheostomy is not recommended because of the high risk of virus aerosolization to healthcare workers, and transmission through health care facilities [13]. There is the same potential risk for the endotracheal intubation, as a hazardous and high-risk aerosol-generating procedure [14]. A meta-analysis and systematic review reported the risk of this transmission to the medical staff for SARS-CoV-1 infection, with a significantly increased the odds ratio (OD) of 6.6 [8].

Due to the high viral load in upper respiratory tract secretions of COVID-19 patients, these methods have been identified as high-risk procedures for exposure and transmission of SARS-CoV-2 [15]. Furthermore, mechanical ventilation of patients with COVID-19 who have had prolonged airway intubation has been reported with a high mortality rate (at least 50–67%) [13, 16]. In general, at the time of this writing, no approved treatment or medication has been prescribed by the US Food and Drug Administration (FDA) for the definitive treatment of COVID-19 or their hypoxia.

In this study, we tried to achieve a non-invasive method to help patients and prevent needing invasive and tracheal intubation. We found that hemoglobin levels and the oxygen saturation percentage in the patient's blood increased appropriately, after receiving two PRBC units. This supportive transfusion was associated with a lack of need to invasive respiratory support and improved patient status.

As a conclusion remark, oxygen delivery and oxygen saturation improvement were observed in the COVID-19 patient, after PRBCs transfusions.

### 4. Abbreviations

ALI: acute lung injury

ARDS: acute respiratory distress syndrome

BP: blood pressure

CBC: complete blood count

COVID-19: coronavirus disease 2019

FDA: Food and Drug Administration

GGO: ground-glass opacity

Hbg: hemoglobin

hCoVs: human coronaviruses

HR: heart rate

HR: heart rate

HRCT: high-resolution computed tomography

ICU: intensive care unit

IV: invasive ventilation

MERS-CoV: Middle East respiratory syndrome coronavirus

OD: odds ratio

Plt: platelet

PRBCs: packed red blood cells

rRT-PCR: real-time reverse polymerase-transcriptase chain reaction

SARS-CoV: severe acute respiratory syndrome coronavirus

SARS-CoV-2: severe acute respiratory syndrome coronavirus 2

WBC: white blood cell

## 5. Declarations

The authors declare no conflict of interest.

### **Ethics approval and consent to participate**

The participant gave written informed consent to participate in the study.

### **Consent for publication**

The participant gave written informed consent to publication of the study.

### **Availability of data and material**

The raw data of this research includes the personal and clinical information of the participant. Any request for data should be directed to the corresponding author.

### **Competing interests**

The authors declare that they have no competing interests.

## Funding

This research received no external funding.

## Authors' contributions

NO stated the initial idea of the research. FA2 and SK were specialist physicians of the patient. The FA1 and JK have collaborated in extracting information of the patient. MJM prepared the first manuscript and FA2 commented on successive drafts. All authors read and approved the final manuscript.

## Acknowledgments

The authors would like to thank the staff in the Hospital for their help, boarding time, in controlling the recent outbreak.

## 6. References

1. **Naming the coronavirus disease (COVID-19) and the virus that causes it** [[www.who.int/emergencies/diseases/novel-coronavirus-2019/technical-guidance/naming-the-coronavirus-disease-\(covid-2019\)-and-the-virus-that-causes-it](http://www.who.int/emergencies/diseases/novel-coronavirus-2019/technical-guidance/naming-the-coronavirus-disease-(covid-2019)-and-the-virus-that-causes-it)]
2. Coronaviridae Study Group of the International Committee on Taxonomy of V: **The species Severe acute respiratory syndrome-related coronavirus: classifying 2019-nCoV and naming it SARS-CoV-2.** *Nat Microbiol* 2020, **5**(4):536-544.
3. Gralinski LE, Menachery VD: **Return of the Coronavirus: 2019-nCoV.** *Viruses* 2020, **12**(2).
4. Zhu N, Zhang D, Wang W, Li X, Yang B, Song J, Zhao X, Huang B, Shi W, Lu R *et al*: **A Novel Coronavirus from Patients with Pneumonia in China, 2019.** *N Engl J Med* 2020, **382**(8):727-733.
5. Gates B: **Responding to Covid-19 – A Once-in-a-Century Pandemic?** *New England Journal of Medicine* 2020, **382**(18):1677-1679.
6. Anderson LJ, Baric RS: **Emerging human coronaviruses—disease potential and preparedness.** *N Engl J Med* 2012, **367**(19):1850-1852.
7. Cui J, Li F, Shi ZL: **Origin and evolution of pathogenic coronaviruses.** *Nature reviews Microbiology* 2019, **17**(3):181-192.
8. Tran K, Cimon K, Severn M, Pessoa-Silva CL, Conly J: **Aerosol generating procedures and risk of transmission of acute respiratory infections to healthcare workers: a systematic review.** *PloS one* 2012, **7**(4):e35797.
9. van Doremalen N, Bushmaker T, Morris DH, Holbrook MG, Gamble A, Williamson BN, Tamin A, Harcourt JL, Thornburg NJ, Gerber SI *et al*: **Aerosol and Surface Stability of SARS-CoV-2 as Compared with SARS-CoV-1.** *New England Journal of Medicine* 2020, **382**(16):1564-1567.

10. Petrilli CM, Jones SA, Yang J, Rajagopalan H, Donnell LF, Chernyak Y, Tobin K, Cerfolio RJ, Francois F, Horwitz LI: **Factors associated with hospitalization and critical illness among 4,103 patients with COVID-19 disease in New York City.** *medRxiv* 2020:2020.2004.2008.20057794.
11. Wu Z, McGoogan JM: **Characteristics of and Important Lessons From the Coronavirus Disease 2019 (COVID-19) Outbreak in China: Summary of a Report of 72 314 Cases From the Chinese Center for Disease Control and Prevention.** *JAMA* 2020, **323**(13):1239-1242.
12. Huang C, Wang Y, Li X, Ren L, Zhao J, Hu Y, Zhang L, Fan G, Xu J, Gu X *et al*: **Clinical features of patients infected with 2019 novel coronavirus in Wuhan, China.** *Lancet (London, England)* 2020, **395**(10223):497-506.
13. Angel L, Kon ZN, Chang SH, Rafeq S, Shekar SP, Mitzman B, Amoroso N, Goldenberg R, Sureau K, Smith D *et al*: **Novel Percutaneous Tracheostomy for Critically Ill Patients with COVID-19.** *The Annals of thoracic surgery* 2020, **In Press**.
14. Weissman DN, de Perio MA, Radonovich LJ, Jr: **COVID-19 and Risks Posed to Personnel During Endotracheal Intubation.** *JAMA* 2020, **323**(20):2027-2028.
15. Cook TM, El-Boghdady K, McGuire B, McNarry AF, Patel A, Higgs A: **Consensus guidelines for managing the airway in patients with COVID-19: Guidelines from the Difficult Airway Society, the Association of Anaesthetists the Intensive Care Society, the Faculty of Intensive Care Medicine and the Royal College of Anaesthetists.** *Anaesthesia* 2020, **75**(6):785-799.
16. Yang X, Yu Y, Xu J, Shu H, Xia J, Liu H, Wu Y, Zhang L, Yu Z, Fang M *et al*: **Clinical course and outcomes of critically ill patients with SARS-CoV-2 pneumonia in Wuhan, China: a single-centered, retrospective, observational study.** *The Lancet Respiratory medicine* 2020, **8**(5):475-481.

## Figures

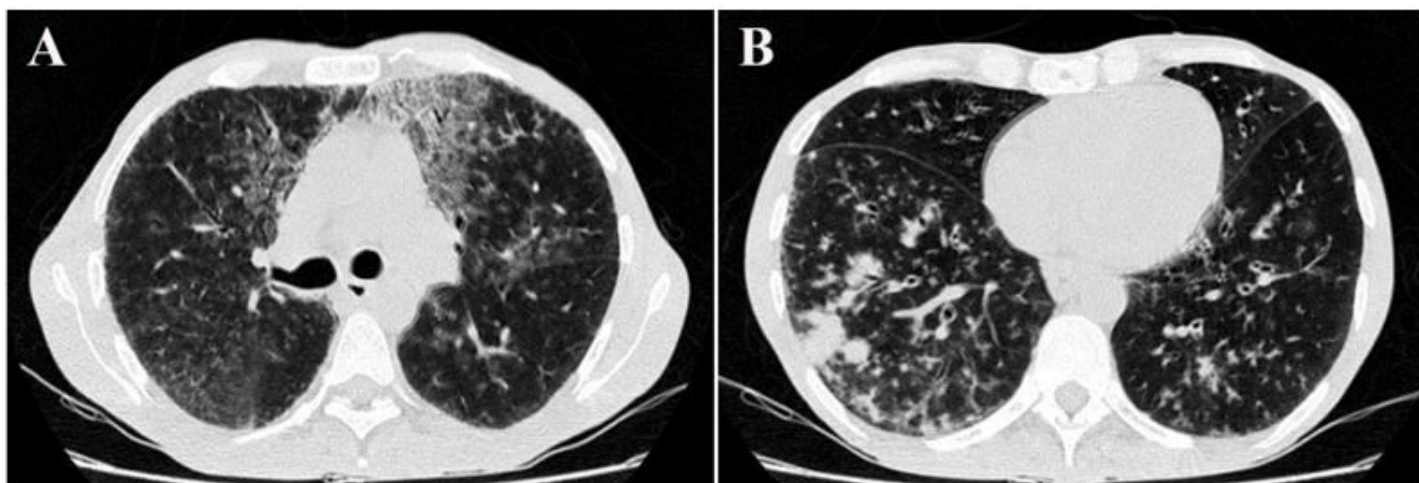
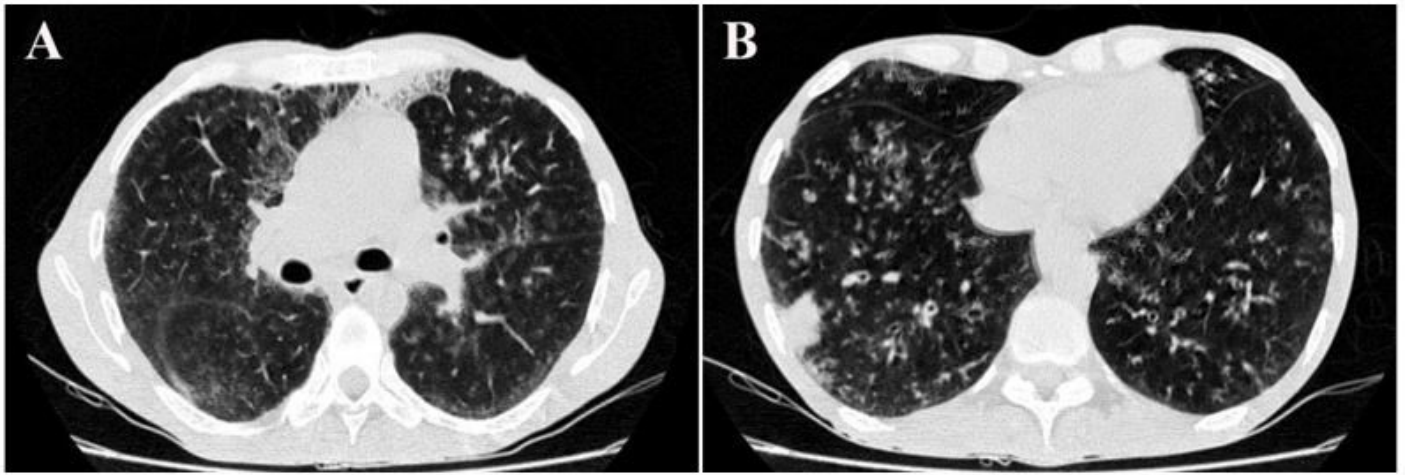


Figure 1

High-resolution CT (HRCT) scan of Chest before transfusion of PRBC units: Peripheral patchy ground-glass opacity in the bilateral and multifocal lung involvement, due to viral pneumonia. A. Bilateral multifocal ground-glass opacities (GGO). B. GGO and infiltration more prominent in right side.



**Figure 2**

High-resolution CT scan (HRCT) of Chest after transfusion of PRBC units: Peripheral patchy ground-glass opacity in the bilateral and multifocal lung involvement, due to viral pneumonia. A. GGO has been decreased. B. GGO and infiltration of right side has been decreased.