

# New onset of Myasthenia Gravis in a patient with COVID-19: A novel case report and literature review

Shitiz Sriwastava (✉ [sks00002@hsc.wvu.edu](mailto:sks00002@hsc.wvu.edu))

West Virginia University <https://orcid.org/0000-0001-6844-3286>

Medha Tandon

Safdarjung Hospital

Saurabh Kataria

University of Missouri

Maha Daimee

MedStar Georgetown University

Shumaila Sultan

West Virginia University

---

## Case Report

**Keywords:** SARS-CoV-2, COVID-19, Myasthenia Gravis, Ocular Myasthenia, Neuromuscular disorder

**DOI:** <https://doi.org/10.21203/rs.3.rs-77694/v1>

**License:**  This work is licensed under a Creative Commons Attribution 4.0 International License.

[Read Full License](#)

---

# Abstract

The novel coronavirus outbreak of SARS-CoV-2 first began in Wuhan, China in December, 2019. The most striking manifestation is atypical pneumonia and respiratory complications, however various neurological manifestations are now well recognized. Currently, there have been a very few case reports in regards to COVID-19 in patients with known history of myasthenia gravis. Myasthenia gravis (MG) causes muscle weakness, especially respiratory muscles in high-risk COVID-19 patients that can lead to severe respiratory compromise. There are few reported cases of severe myasthenia crisis following COVID-19, likely due to the involvement of the respiratory apparatus and from use of immunosuppressive medication.

We report a first case MG developing secondary to COVID-19 infection in a 65-year-old woman. Two weeks prior to hospitalization, the patient suffered from cough, fever, diarrhea and was found to be positive for COVID-19 via nasopharyngeal RT-PCR swab test. The electrodiagnostic test showed decremental response over more than 10% on repetitive nerve stimulation test of orbicularis oculi. She tested positive for antibodies against Acetylcholine receptor (AChR).

COVID-19 is known to cause release of inflammatory cytokines leading to immune-mediated damage. MG is an immune-mediated disorder caused due to molecular mimicry and autoantibodies against the neuromuscular junction.

## Introduction

Myasthenia gravis is a common autoimmune disorder caused due to the production of autoantibodies against the nicotinic acetylcholine receptors at the neuromuscular junction [1, 2]. The disruption of the neuromuscular pathway causes reduced stimulation of the muscles manifesting as fatigable muscle weakness, which may be generalized or focal, specifically involving ocular and bulbar regions, and in severe cases, leading to respiratory compromise [1, 3].

In general, 80% of generalized myasthenia gravis (gMG) patients and 55% of ocular myasthenia gravis (oMG) have autoantibodies against acetylcholine receptor blocking, binding and modulating receptors (AChR-Ab) (1). Anti-MuSK antibodies tend to be positive in about one-third of patients that are seronegative in generalized myasthenia gravis [1].

Viral and bacterial infections are established triggers for a myasthenic crisis in patients with pre-existing myasthenia gravis. However, there is yet to be a clear consensus regarding infections causing myasthenia gravis in otherwise healthy patients.

With the outbreak of the novel coronavirus, SARS-CoV-2, scientists and researchers around the world are trying to gain information regarding its effects and complications with regards to various pre-existing comorbidities on different subgroups of people. While atypical pneumonia and respiratory compromise are the primary features of COVID-19, various neurological manifestations are now well recognized and many other are being extensively studied. There is a concern that neuromuscular disorders affecting the swallowing and respiratory apparatus will predispose patients to a more severe infection[4].

Additionally, coronavirus other than SARS-CoV-2, such as MERS and SARS are well recognized to cause myopathies and neuropathies in addition to other neuromuscular disorders [5, 6]. A case series by Kim et al reported critical illness neuropathy and acute sensory neuropathy in a group of patients with MERS [5]. Another case series by Tsai L. et al of 4 cases of SARS-CoV infection was reported with coexistent neuropathy and myopathy[6].

Recently, these complications are also being recognized among patients of COVID-19.

A few case reports have been described of Covid-19 infection in patients with pre-existing myasthenia gravis [2, 7-13]. However, to the best of our knowledge, there have been no reported cases of myasthenia gravis being triggered by COVID-19 infection. Here, we describe the first such case and attempt to describe the clinical course, possible pathophysiological manifestations behind this presentation and briefly review the present literature on COVID-19 in Myasthenia patients.

## Case Report

A 65-year-old woman with significant history of left renal cell carcinoma status-post partial nephrectomy in 2018, pituitary adenoma with acromegaly status post partial resection in 1993 (on chronic prednisone replacement therapy), lung carcinoid, meningioma and history of pulmonary embolism on apixaban. She presented from an outside facility with 2 weeks of diarrhea, myalgia, and extreme fatigue now with 1 day of left eyelid ptosis. Of note she had exposure to a family member with COVID – 19 and tested positive for COVID – 19 by nasopharyngeal swab.

She had left ptosis at baseline and inducible ptosis with diplopia with vertical up gaze after 20 seconds. She had normal strength and normal reflexes. She denied any dyspnea, dysphagia, chewing fatigue or proximal weakness.

Extensive lab work revealed elevated inflammatory markers including Interleukin-6 at 3 pg/mL (normal <=1.8), serum CRP 88.4 mg/l (normal <0.8), serum ferritin 966 ng/ml (normal 10-200 ng/ml), serum fibrinogen 546 mg/dl (normal 200-400 mg/dl), and D-dimer 521 ng/ml (normal <232 ng/ml).

Acetylcholine receptor (AChR) binding antibody (Ab) was positive with high titer 7.39 nmol/L (normal <0.02 nmol/L), striational Ab with high titer positive 1:960 (normal <1:120), and AChR modulating Ab 78% (0-20% reported as normal percentage loss of AChR) along with negative anti-MuSK Ab.

EMG was performed on day 2 of hospitalization and was consistent with a neuromuscular transmission deficit with a decremental response on repetitive nerve stimulation test of left orbicularis oculi (refer to figure 1). Icepack test was positive. CT chest showed no pulmonary infiltrates and was negative for thymoma. Normal MRI of orbits ruled out infiltrative etiologies and brain MRI was unremarkable. Paraneoplastic panel was negative including antibodies against P/Q-type calcium channel and N-type calcium channel.

Patient was started on pyridostigmine 60 mg every 4 hours with noticeable improvement with the medication. Based on the combination of findings from history, blood work, and electrodiagnostic testing, she was diagnosed with seropositive ocular myasthenia gravis.

Two days after discharge patient developed loss of taste and smell. Six days later she was transferred from an outside hospital for septic shock and had received ceftriaxone and azithromycin. She was consistently requiring 4L of oxygen due to respiratory compromise and received 1-unit convalescent plasma on day 4 after second admission. She was placed on prone position for 1 hour at a time for 4 days, started on IV dexamethasone 6mg and ultimately received 4 doses of IV dexamethasone. She continued to have mild ptosis but no diplopia or any fatigable weakness.

She was eventually weaned to room air on day 10 of admission and no longer had any shortness of breath or cough. She was having some episodes of asymptomatic sinus bradycardia with heart rate approaching to the low 40's, which was likely due to dysautonomia which can be seen with COVID-19 [14].

## Discussion

There have been no reported cases of patient's developing post-infectious myasthenia gravis from COVID-19, but cases of co-existing COVID-19 with pre-existing MG have been published[7, 9].

In our brief literature review, we reviewed 17 patients with known MG that were infected with COVID-19. All patients except one [10] were sero-positive myasthenic patients on varying immunosuppressive therapies (majority on at least 2 agents, including pyridostigmine), and with varying disease status at the time of

infection[7-9, 11-13]. The patients were either continued on the same medication regimen during their COVID-19 infection or given an extra pulse dose of steroids or IVIG, depending on whether or not they were suffering from acute worsening of bulbar respiratory symptoms warranting further aggressive therapy. Majority of patients were able to be discharged to home or rehab facility, with two patients however remained on mechanical ventilation[2, 7] (refer table 1).

The patient suffered from ocular symptoms, and showed with improvement with pyridostigmine trial, which further indicates that these findings are secondary to myasthenia, with an indirect perpetuation from COVID-19. During the COVID-19 pandemic, it has been established that neurological complications in form of autoimmune reactions such as GBS and MG may be provoked. Along with the patient's underlying predilection for the disease due to genetic factors, environmental factors may also play a role, which was further instigated by the viral infection.

While the underlying mechanism of disease pathology has not been clearly established, and would need further investigation. However, it is well known that there is a decrease in the availability of AchRs at the post-synaptic neuromuscular junction due to destruction by the antibodies and the inflammatory response, plays a key role in the pathogenesis [3]. Antibodies produced by an inflammatory reaction to an external agent such as a virus, can result in a triggered immune response that cross reacts with the AchRs due to molecular resemblance leading to damage. COVID-19 has affinity to ACE-2 receptors directly causing formation of autoantibodies leading to a significant inflammatory cascade [15]. The ACE-2 receptor is expressed in multiple different organs such as the lungs, kidneys, and liver. This produces proinflammatory cytokines and chemokines along with B and T-cell depletion with increased levels of interleukins and TNF- $\alpha$  which correlates with disease severity, and increased risk of cross-reactive autoimmune attack against our own body's receptors [15]. Myasthenia gravis antibody production is a B cell dependent process and plays an important role in loss of self-tolerance and dysregulation [3]. IL-6 is an inflammatory marker that is found in COVID-19 and MG, and can be associated with higher mortality rate in COVID-19 [16]. In our case, patient had mild to moderate COVID-19 symptoms based off of ATS/IDSA guidelines [17]. The ongoing inflammatory response along with production of destructive reactive oxygen species can lead to ARDS and long-term pulmonary fibrosis.

There have also been reported cases of post-infectious myasthenia gravis that developed weeks after initial infection, associated with Varicella zoster, West Nile Virus, Zika virus[18-20]. In the literature review, post-COVID-19 infection, neuromuscular manifestations have been found after a 1 to 3 weeks [6, 21]. Our case had neuromuscular manifestation after 2 weeks of viral prodromal symptoms.

Treatment is targeted at symptomatic improvement with pyridostigmine and with immunosuppressive therapies (corticosteroids and long-term steroid-sparing agents) to control the production of antibodies and decrease the severity of disease [2, 4, 9]. Current guidelines from a panel of MG experts recommend tailoring treatment according to each individual patient with underlying comorbidities with the primary care provider and specialists, however, it is encouraged to continue standard MG protocol during hospitalizations and continue immunosuppressive therapy [2, 4].

## Conclusion

In summary, to our knowledge, this is the first reported case of MG in a patient infected with COVID-19. Although Coronavirus disease 2019 (COVID-19) typically presents with upper or lower respiratory symptoms, there have been reports of significant neurological complications.

Likely mechanisms for the development of MG are the molecular resemblance. An immune response triggered by prior infection, cross-reacts with the Autoantibody against neuromuscular junction, and causes its damage. Some infectious agents are known to be associated mg such as VZV, WNV, Zika virus. MG should be considered as neurological complications of infection with COVID-19 who can present with ptosis, fatigability.

It is unclear whether COVID-19 could induce the production of antibodies against neuromuscular junction triggering myasthenia gravis in COVID-19 patients. Further investigations should be conducted about the mechanism of MG in patients with COVID-19, in the future.

## Abbreviations

Coronavirus infectious disease-2019, COVID-19; Generalized Myasthenia Gravis, gMG; Myasthenia Gravis, MG; Ocular Myasthenia Gravis, oMG; Anti Muscle specific tyrosine kinase, Anti-MuSK; Acetylcholine Receptor, AchRs; Middle East Respiratory Syndrome, MERS; Severe Acute Respiratory Distress Syndrome coronavirus 2, SARS-CoV-2; Infectious Disease Society of America/American Thoracic Society, IDSA/ATS; Intravenous immunoglobulin, IVIG; Interleukin, IL; Electromyography, EMG; Magnetic Resonance Imaging, MRI; Reverse transcriptase polymerase chain reaction, RT-PCR; C-reactive protein, CRP

## Declarations

### Funding:

None

### Availability of data and material:

None

### Conflict of interest:

All authors declared no potential conflicts of interest.

**Ethics approval and consent to participate:**

Not applicable.

**Consent for publication:**

available and also IRB approved.

**Disclosures:**

Shitiz Sriwastava      Reports no disclosure

Saurabh Kataria      Reports no disclosure

Medha Tandon.      Reports no disclosure

Maha Daimee      Reports no disclosure

Shumaila Sultan      Reports no disclosure

All authors have equally contributed for the paper.

**Author Contributions:**

Drafting the manuscript: Saurabh Kataria, Medha Tandon, Maha Daimee, Shitiz Sriwastava

Editing and Final Draft: Shitiz Sriwastava, Shumaila Sultan

**Acknowledgments:**

None

**References**

1. Meriggioli, M.N. and D.B. Sanders, *Autoimmune myasthenia gravis: emerging clinical and biological heterogeneity*. Lancet Neurol, 2009. **8**(5): p. 475-90.
2. Hübers, A., A.M. Lascano, and P.H. Lalive, *Management of patients with generalised myasthenia gravis and COVID-19: four case reports*. Journal of Neurology, Neurosurgery & Psychiatry, 2020.
3. Koneczny, I. and R. Herbst, *Myasthenia gravis: pathogenic effects of autoantibodies on neuromuscular architecture*. Cells, 2019. **8**(7): p. 671.
4. Guidon, A.C. and A.A. Amato, *COVID-19 and neuromuscular disorders*. Neurology, 2020. **94**(22): p. 959-969.

5. Kim, J.-E., et al., *Neurological complications during treatment of middle east respiratory syndrome*. Journal of Clinical Neurology, 2017. **13**(3): p. 227-233.
6. Tsai, L.-K., et al., *Neuromuscular disorders in severe acute respiratory syndrome*. Archives of neurology, 2004. **61**(11): p. 1669-1673.
7. Anand, P., et al., *COVID-19 in patients with myasthenia gravis*. Muscle & Nerve, 2020.
8. Delly, F., et al., *Myasthenic crisis in COVID-19*. Journal of the Neurological Sciences, 2020. **414**: p. 116888.
9. Rein, N., et al., *Description of 3 patients with myasthenia gravis and COVID-19*. Journal of the Neurological Sciences, 2020: p. 117053.
10. Kushlaf, H., *COVID-19 in muscle-specific kinase myasthenia gravis: A case report*. Muscle & Nerve, 2020.
11. Aksoy, E. and T. Oztutgan, *COVID-19 Presentation in Association with Myasthenia Gravis: A Case Report and Review of the Literature*. Case Reports in Infectious Diseases, 2020. **2020**.
12. Ramaswamy, S.B. and R. Govindarajan, *COVID-19 in Refractory Myasthenia Gravis-A Case Report of Successful Outcome*. Journal of Neuromuscular Diseases, 2020(Preprint): p. 1-4.
13. Singh, S. and R. Govindarajan, *COVID-19 and generalized Myasthenia Gravis exacerbation: A case report*. Clinical Neurology and Neurosurgery, 2020.
14. Eshak, N., et al., *Dysautonomia: an overlooked neurological manifestation in a critically ill COVID-19 patient*. The American Journal of the Medical Sciences, 2020.
15. Baig, A.M., et al., *Evidence of the COVID-19 virus targeting the CNS: tissue distribution, host–virus interaction, and proposed neurotropic mechanisms*. ACS chemical neuroscience, 2020. **11**(7): p. 995-998.
16. Herold, T., et al., *Elevated levels of IL-6 and CRP predict the need for mechanical ventilation in COVID-19*. J Allergy Clin Immunol, 2020. **146**(1): p. 128-136.e4.
17. Metlay, J.P., et al., *Diagnosis and treatment of adults with community-acquired pneumonia. An official clinical practice guideline of the American Thoracic Society and Infectious Diseases Society of America*. American journal of respiratory and critical care medicine, 2019. **200**(7): p. e45-e67.
18. Felice, K.J., F.J. DiMario, and S.R. Conway, *Postinfectious myasthenia gravis: report of two children*. Journal of child neurology, 2005. **20**(5): p. 441-444.
19. Hawkes, M.A., S.E. Hocker, and A.A. Leis, *West Nile virus induces a post-infectious pro-inflammatory state that explains transformation of stable ocular myasthenia gravis to myasthenic crises*. Journal of the neurological sciences, 2018. **395**: p. 1-3.
20. Molko, N., et al., *Zika virus infection and myasthenia gravis: report of 2 cases*. Neurology, 2017. **88**(11): p. 1097-1098.
21. Ellul, M.A., et al., *Neurological associations of COVID-19*. Lancet Neurol, 2020. **19**(9): p. 767-783.

## Table

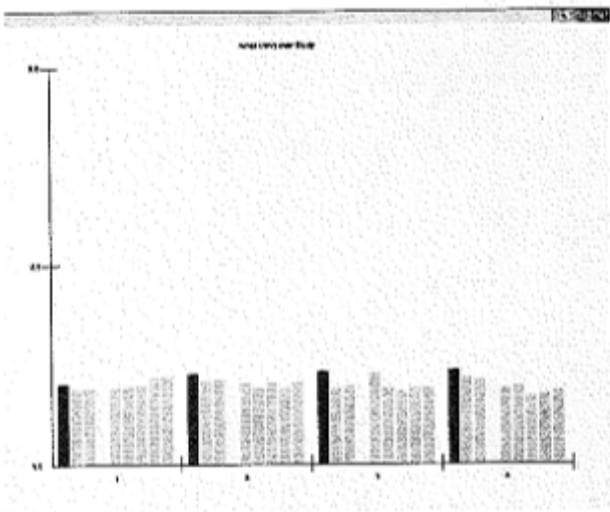


## Table 1

Author	Article type	No. of pt	Lab tests	Management	Outcomes
<b>Aksoy et al</b>	Case report	1	AchR +ve, CRP/WBC elevation	Pyridostigmine (increased to 60mg QID), favipiravir, meropenem, oseltamivir, HCQ (400 mg BID first day, afterwards 200 BID)–D/c then worsening symptoms added linezolid and IV methylprednisone 40mg daily and plasma therapy	Complete recovery
<b>Kushlaf et al.</b>	Case report	1	MuSK Ab +ve	HCQ x 5 days, tocilizumab, and IVIG 1 g/kg daily x 2 consecutive days	Intermittent hemodialysis for renal failure. No symptoms suggestive of worsening of MG
<b>Ramaswamy et al.</b>	Case report	1	AchR +ve, elevated WBC	prednisone 30 mg daily and mycophenolate 1000 mg BID (no changes in meds during COVID)	Complete recovery
<b>Rein et al.</b>	Case report	3	Not reported	PT 1: HCQ, lopinavir, ritonavir, increased prednisone dose and IVIG PT 2: PLEX switched for IVIG PT 3: No change in treatment	PT 1: Non-invasive respiratory support. Discharged home.  PT 2: Complete recovery  PT 3: Recovered at home
<b>Hubers et al.</b>	Case report	4	PT 1: AchR +ve PT 2: AchR +ve PT 3: negative PT 4: AchR +ve	PT 1: AZA stopped; IVIG x 5 days PT 2: No change in treatment PT 3: No change in treatment PT 4: Increase in pyridostigmine	PT 1: Discharged home; anosmia, ageusia at 4 weeks  PT 2: Fluctuating headaches and respi symptoms over 6 weeks  PT 3: Resolved after 3 weeks

					PT 4: Mechanical ventilation >14 days, tracheostoma x 9 weeks.
<b>Singh et al.</b>	Case report	1	Elevated WBC, AST, ALT, LDH, ferritin, D-dimer	PLEX + stress steroids	Discharged after 1 month, persistent anosmia
<b>Delly et al.</b>	Case report	1	AchR +ve	HCQ, steroids, IVIG	Discharged to SAR
<b>Anand et al.</b>	Case report	5	PT 1: AchR +ve PT 2: AchR +ve PT 3: AchR +ve PT 4: MuSK Ab +ve PT 5: AchR +ve	PT 1: HCQ 400 mg BID x 1 day, 200 mg OD x 2 days; AZM 500 mg OD x 1 day, 250 mg OD x 2 days; TOZ 300 mg x 1 dose + AZA PT 2: HCQ 400 mg BID x 1 day, 400 mg OD x 4 days; AZM 500 mg OD x 1 day, 250 mg OD x 4 days; CTX 2 g OD x 2 days, 1 g OD x 3 days+ prednisone 10mg OD to 5mg PT 3: HCQ 400 mg BID x 1 day, 200 mg BID x 4 days; AZM 500 mg OD x 5 days, CTX 1 g OD x 5 days; continued IVIG and reduced prednisone PT 4: Prednisone increased, IVIG added PT 5: No change	PT 1: Discharged home on day 9 PT 2: Continued mechanical ventilation PT 3: Discharged to skilled nursing facility on day 19 PT 4: Discharged home on day 5 PT 5: Discharged home on day 9

## Figures



**L Orbicularis oculi**

Train	Amp mV	4-1 %	Time
Baseline	1.0	-5.8	0:00:00
@0:05	1.1	-12.2	0:01:37
@0:30	1.2	-15.2	0:02:11
@1:00	1.2	-16.4	0:03:16

**Figure 1**

EMG repetitive nerve stimulation test of the left orbicularis oculi (facial nerve) The fourth run of the repetitive nerve stimulation of the left orbicularis oculi (facial nerve) demonstrated reproducible decrement of 16.4% (>10%) consistent with neuromuscular junction transmission defect. EMG: Electromyography test