

Inter-vertebral Height, Inter-vertebral Foramen Height and Range of Motion are Associated with Redundant Nerve Roots in Lumbar Spinal Stenosis

Deng Bo

Taizhou Hospital of Zhejiang Province

Fan Shao Hua

Taizhou Hospital of Zhejiang Province

Feng Xin Bing

Taizhou Hospital of Zhejiang Province

Zhenghua Hong (✉ hongzhenghua001@126.com)

Taizhou Hospital of Zhejiang Province

Research article

Keywords: Redundant nerve roots, Inter-vertebral height, Inter-vertebral foramen height, lumbar spinal stenosis

Posted Date: September 28th, 2020

DOI: <https://doi.org/10.21203/rs.3.rs-76701/v1>

License: © ⓘ This work is licensed under a Creative Commons Attribution 4.0 International License.

[Read Full License](#)

Abstract

Background: To analyze the relational factors influencing the formation of cauda equina redundant nerve roots (RNRs) of the lumbar spinal stenosis.

Methods: A retrospective study of 116 patients with lumbar spinal stenosis were treated in our department from January 2016 to June 2019. Magnetic resonance imaging (MRI) was performed to observe the shape and morphology of the redundant nerve roots of the cauda equina. We divided patient into (RNRs) group and non-RNRs (NRNRs) group based on the presence or absence of RNRs on sagittal T2-weighted MR. We analyzed the demographic characteristics, preoperative back pain visual analogue scale (VAS) scores, preoperative leg pain VAS scores, and preoperative Oswestry disability index (ODI) scores, and also analyzed the rate of spondylolisthesis and ligamentum flavum hypertrophy. Simultaneously, the inter-vertebral height, intervertebral foramen height, inter-vertebral height + vertebral height, median sagittal diameter at the inter-vertebral space level (DIW-MSD), median sagittal diameter at the pedicle level (DV-MSD), ROM of the stenotic segment, were statistically analyzed for clinical and radiological significance.

Results : Of a total 116 total patients, there were no statistically significant differences in either gender [RNRs group (n = 42, 18/24 female) and NRNR group (n = 74, 38/36 female)], age, BMI index, preoperative back pain VAS score, preoperative leg pain VAS score and preoperative ODI score ($p > 0.05$); however, there were statistically significant differences regard to the duration of symptoms and the rate of spondylolisthesis and ligamentum flavum hypertrophy ($p < 0.05$); the inter-vertebral height, intervertebral foramen height, inter-vertebral height + vertebral height, DIW-MSD, ROM of the stenotic segment were also significantly different between the group ($p < 0.05$).

Conclusions: The inter-vertebral height, inter-vertebral foramen height, inter-vertebral height + vertebral height, DIW-MSD and ROM of the stenotic segment were the crucial factors related to RNRs in lumbar spinal stenosis.

1. Introduction

Redundant nerve roots (RNRs) manifest clinically as persistent low back and leg pain, which characterized by a tortuous, serpentine, enlarged and longated nerve root of the cauda equina in patients with lumbar spinal stenosis [1–4]. This phenomenon first discovered and described by Verbiest in 1954, when he performed X-ray myelography to patients with lumbar spinal stenosis [5], and subsequently named RNRs by Cressmen and Pawl in 1968 [6]. The mechanism associated with RNRs is still unclear. The pathological mechanism is likely associated with the compression of the cauda equina nerve by lumbar spinal stenosis. With movement of the lumbar spine, the cauda equina nerve gradually becomes thicker and longer [7]. Other studies have demonstrated that RNRs are closely related to the severity of symptoms in patients with lumbar spinal stenosis [8].

The previous study focused on the clinical significance and mechanism associated with RNRs [9–12]. Studies have demonstrated that RNRs are closely related to the age and the clinical symptoms of patients. The older and more severe the symptoms, the higher the incidence of RNRs [9–10]. Savarese et al [13] conducted a retrospective study of 171 patients, in which the lumbar spinal stenosis was measured by using the lumbar spinal canal cross-sectional area (CSA). The degree of stenosis and lumbar spondylolisthesis are known to be closely related to the occurrence of RNRs, spinal stenosis and spondylolisthesis are independent risk factors for RNRs, in particular, when the lumbar spinal dural sac cross-sectional area (CSA) is less than 50mm². Hur et al [14] compared the lumbar disc herniation area, the ligamentum flavum hypertrophy area, and the lumbar dynamic segment angle by measuring and comparing the spinal canal, and considered that the increase in lumbar dynamic position mobility and ligamentum flavum hypertrophy were crucial factors for the occurrence of RNRs. Kubosch et al [15] believed that it is still uncertain whether the degree of spine degeneration and range of motion were influencing factors in RNRs and recommended that more research was needed in the area.

To date, there have been no studies on RNRs and their relation with inter-vertebral height, intervertebral foramen height, inter-vertebral height + vertebral height, DIW-MSD, and ROM of the stenotic segment. This study was conducted to explore the correlation the clinical and radiologic evidence in the development of RNRs of cauda equine.

2. Materials And Methods

2.1. General study design

This study was conducted with approval from the Ethics Committee of our Hospital. Specifically, the study was a retrospective analysis of clinical and radiological data obtained from 116 lumbar spinal stenosis patients treated in our hospital from January 2016 to June 2019. All patients underwent lumbar X-ray, CT, and MRI (sagittal-section T1-weighted images and cross-section T1-weighted images), RNRs were judged based on MRI T2 weighted images, RNRs were identified in the lumbar spine based on apparent tortuosity of elongated and coiled nerve roots in the subarachnoid space. Three radiologists were responsible diagnosing RNRs. The radiologists disagreed on classification in the event, a consensus decision was reached by discussion among the radiologists. According to the results, patients were divided into an RNRs group and a non-RNRs (NRNRs) group.

The inclusion criteria included: (1) The diagnostic criteria of lumbar spinal stenosis, patient with intermittent claudication symptoms was met; (2) over 18 years of age; (3) X-ray, CT and MRI are complete and clear, and (4) spinal stenosis is evident in a single segment. The exclusion criteria included: (1) patients with a history of spine surgery; (2) infectious disease of the lumbar; (3) Patients that did have an MRI in our hospital; (4) patients with spinal intervention, such as epidural injection or myelography; (5) the patient with a history of congenital lumbar spinal stenosis; and (6) patients with a previous fracture of the lumbar spine.

2.2 Clinical and Radiological data

Clinical data included demographic parameters, including gender, age, BMI index, duration of symptoms, severity of symptoms (preoperative VAS scores for back pain and leg pain), and preoperative ODI scores. Radiological parameter measurements included: lumbar stenosis, inter-vertebral height, intervertebral foramen height, vertebral body height, DIW-MSD, DV-MSD, ROM of the stenotic segment, and whether spondylolisthesis and ligamentum flavum hypertrophy appeared on the MRI can Surgimap Spine (Nemaris Inc, New York, NY, USA) to measure radiological data.

2.3 Statistical analysis methods

All data were statistically analyzed with SPSS for Windows, Version 20.0 (SPSS Inc., Chicago, IL, USA), and continuous variables were presented as mean \pm standard deviation. Continuous variables included age, BMI index, duration of symptoms, severity of symptoms (VAS scores for back pain and leg pain), and preoperative ODI score, inter-vertebral height, intervertebral foramen height, vertebral body height, DIW-MSD, DV-MSD, and ROM of the stenotic segment. Counted data were expressed as a percentage (%), and included gender, and the rate lumbar spondylolisthesis and ligamentum flavum hypertrophy, as assessed by MRI. An unpaired Student's *t* test analysis of variance, and χ^2 test were used to analyze the counted data. A *p*-value of less than 0.05 was considered statistically significant ($p < 0.05$).

3. Results

A total of 116 patients were included in our study. According to the radiologist' diagnoses, 42 (36.2%) patients were placed in the RNRs group and 74 (63.8%) in the NRNRs group. There were no significant differences between the RNRs group and NRNRs group in either, mean age (63.36 \pm 8.73 vs 62.00 \pm 10.41 years, respectively; $p = 0.292$), gender (18/24 vs 38/36, respectively; $p = 0.379$), BMI index (22.63 \pm 2.60 vs 23.09 \pm 2.22, respectively; $p = 0.541$), preoperative back pain VAS score (6.57 \pm 1.15 vs 6.45 \pm 0.83, respectively; $p = 0.546$), preoperative leg pain VAS score (7.19 \pm 1.11 vs 6.89 \pm 1.09, respectively; $p = 0.162$), or preoperative ODI score (40.14 \pm 3.62 vs 40.57 \pm 3.25, respectively; $p = 0.518$), Maximum stenosis level of L2/3, L3/4, L4/5, or L5/S1, regions were found in three, nine, 27, and three patients in the RNRs group, and in 12, 38, 21, and four patients in the NRNRs group, respectively. Lumbar spondylolisthesis (26/42 vs 16/74, respectively; $p < 0.0001$) and ligamentum flavum hypertrophy (21/42 vs 7/74, respectively; $p < 0.0001$) were both significantly higher in the RNRs group than in the NRNRs group (Table 1). MRI and X-ray images respectively indicated that inter-vertebral height (7.25 \pm 1.65 vs 9.12 \pm 1.67, respectively; $p < 0.0001$) (Fig. 1A), and intervertebral foramen height (16.76 \pm 2.77 vs 20.50 \pm 3.73, respectively; $p < 0.0001$) (Fig. 1B), Using a combination MRI and X-ray, inter-vertebral height + vertebral body height was found to be significantly less in the RNRs group (35.40 \pm 3.39 vs 38.57 \pm 3.27, respectively; $p < 0.0001$) (Fig. 1C), while CT images, indicated that DIW-MSD was also significantly less in this group (9.22 \pm 2.08 vs 15.25 \pm 2.71, respectively; $p < 0.0001$) (Fig. 1D), X-ray images indicated ROM of the stenotic segment was significantly larger in the RNRs group (7.15 \pm 2.46 vs 5.46 \pm 3.08, respectively; $p = 0.0029$) (Fig. 1E) CT images indicated that DV-MSD was not significantly different between the groups (12.87 \pm 2.16 vs 13.56 \pm 1.78, respectively; $p = 0.06$) (Fig. 1F). The radiological data of patients are summarized in Table 2.

Table 1
Demographic characteristics and clinical manifestation of both groups

parameters	RNRs(+)	NRNRs(-)	p value
No. of patients	42	74	
Mean age (years)	(63.36 ± 8.73)	(62.00 ± 10.41)	0.292
Sex (M/F)	18/24	38/36	0.379
BMI index(kg/cm ²)	(22.63 ± 2.60)	(23.09 ± 2.22)	0.541
Pre-op VAS			
Mean preoperative back pain(point)	(6.57 ± 1.15)	(6.45 ± 0.83)	0.546
Mean preoperative leg pain(point)	(7.19 ± 1.11)	(6.89 ± 1.09)	0.162
Mean preoperative ODI score(point)	(40.14 ± 3.62)	(40.57 ± 3.25)	0.518
Mean Symptom duration (months)	(28.00 ± 4.41)	(22.36 ± 5.49)	<0.0001
Maximal stenotic level (cases)			
L2-3	3	12	
L3-4	9	38	
L4-5	27	21	
L5-S1	3	4	
Spondylolisthesis(%)	26(61.90%)	16(21.62%)	<0.0001
ligamentum flavum(%)	21(50.00%)	7(9.46%)	<0.0001

Table 2
The difference of radiologic parameters in RNRs and NRNRs group

Parameters	RNRs	NRNRs	p value
Inter-vertebral height(mm)	(7.25 ± 1.65)	(9.12 ± 1.67)	<0.0001
Inter-vertebral foramen height(mm)	(16.76 ± 2.77)	(20.50 ± 3.73)	<0.0001
Inter-vertebral height + vertebral height(mm)	(35.40 ± 3.39)	(38.57 ± 3.27)	<0.0001
Inter-vertebral height compare to vertebral body height(mm/mm)	(0.26 ± 0.07)	(0.31 ± 0.06)	<0.0001
DIW-MSD(mm)	(9.22 ± 2.08)	(15.25 ± 2.71)	<0.0001
DV-MSD(mm)	(12.87 ± 2.16)	(13.56 ± 1.78)	0.06
ROM (°)	(7.15 ± 2.46)	(5.46 ± 3.08)	0.0029

4. Discussion

The current study demonstrated that the occurrence of lumbar stenosis complicated with RNRs as assessed by MR, affected approximately 36.2% (42/116)of patients, This result is consistent with prior literature, which indicated that the incidence of lumbar stenosis complicated with RNRs was ~33.8%–42.3% [9, 14]. Mechanical compression of patients with lumbar spinal stenosis is considered to be the basic mechanism involved in RNRs formation[16]. Suzuki et al[12] performed autopsies on patients with severe lumbar spinal stenosis, and the results demonstrated that cauda equina RNRs formed strands in the stenosis. In the spinal canal, these compressed nerve roots are significantly elongated as they stretch with the legs and trunk, eventually leading to their over-elongation . In addition, other scholars believe that RNRs may be related to an abnormality of the cauda equina microvascular function, and that ischemia of the cauda equina could lead to tortuous never root deformation [17].

Formerly, the diagnosis of RNRs was mainly assessed by myelography. At present, MRI has provided an important basis for the diagnosis of RNRs, although a deeper understanding and research of RNRs needed. T2-weighted MRI scans usually indicate RNRs as tortuous and entangled, with an overall narrowing of the spinal canal ,The MRI imaging characteristics of RNRs are characterized by high-signal images of spinal canal relaxation, tortuosity, and entanglement on T2-weighted images[18]. In the current study, we found that RNRs were more likely to occur in stenotic segments of L4- 5 and above. We consider that there are more cauda equina nerves in the spinal canal at higher segments, which are more likely to form RNRs after compression. Hur et al[5] demonstrated that during the development of lumbar spinal stenosis the level of L4-5,which is the area most associated with spondylolisthesis,multi-segment stenosis and spondylolisthesis may be important factors for the formation of RNRs in central lumbar

spinal stenosis. Yukawa et al [19] found that patients with two-segment or multiple-segment stenosis walked much shorter distances than patients with perioperative single-segment stenosis. In the current study, there was no statistically significant difference between the RNRs group and the NRNRs group regard to preoperative back pain and leg pain VAS scores, and preoperative ODI scores . These results are consistent with the research by Min and Hur [4, 14]. However, our study indicated that there was a significant difference in the duration of back pain symptoms between the two groups. In previous studies, it has also been demonstrated that the older patient and longer the duration of symptoms, the greater was the possibility of developing RNRs [9-10, 14]. However,

However, the results of this study indicate that age is not associated with RNRs. Savarese et al. [13] showed that the probability of RNRs in patients with lumbar spondylolisthesis is 55.56%, whereas the probability of RNRs in patients without lumbar spondylolisthesis is 23.61%, demonstrating that patients with lumbar spondylolisthesis are more prone to RNRs. Our study is consistent with the findings of Savarese et al. Many studies have shown that ligamentum flavum hypertrophy is the main cause of lumbar spinal stenosis. At the same time, hypertrophy of the ligamentum flavum is closely related to the mechanical stress of the cauda equina [20-24]. In the current study, the probability of hypertrophy of the ligamentum flavum was significantly higher in the RNRs group than in the NRNRs group. This result is in agreement with previous literature [13-14]. Hur et al. [14] indicated that patients with hypertrophy of the ligamentum flavum in the spinal canal had a stronger relationship with the occurrence of RNRs than with other structures in the spinal canal.

The appearance of RNRs is closely related to lumbar spinal stenosis [25]. In the current study, we used DIW-MSD and DV-MSD were used to evaluate the degree of lumbar spinal stenosis. There are many methods of CT to evaluate lumbar spinal stenosis. The simplest and most commonly used method is to measure the median sagittal diameter. There are many methods of CT measurement to evaluate lumbar spinal stenosis. The simplest and most commonly used method is MSD [26]. In previous studies, the MSD of the spinal canal was mostly taken at the vertebral level as it was inconsistent at the intervertebral space level and the vertebral level. We measured DIW-MSD and DV-MSD and found statistically significant differences between the two groups when DIW-MSD was used; whereas none were found when DV-MSD was used. These results indicate that the formation of RNRs in patients with lumbar spinal stenosis is caused by spinal stenosis at the intervertebral space level. We believe that the occurrence of disc herniation, hypertrophy of the ligamentum flavum, and fat behind the dural sac results in spinal stenosis of the MSD at the intervertebral space level; a hypothesis that is consistent with the conclusions of Savarese et al. [13] and Hur et al. [14].

Intervertebral height is measured by either taking the height of the anterior, middle, or posterior edges. Here, we measured the height of the posterior edge, as the posterior edge and the height of the vertebral body composed the length of the spinal canal. To date, there have been no reports that the intervertebral height, intervertebral foramen height, and the intervertebral height + vertebral height are associated with formation of RNRs in patients with lumbar spinal stenosis. In addition, in order to avoid individual differences, we used the ratio of intervertebral height and vertebral body height. Because the ratio is

relatively constant, we used three values to evaluate the spinal canal length index. Results demonstrated that length indices, including intervertebral height, intervertebral foramen height, and intervertebral height + vertebral height in the RNRs group were less than those in the NRNRs group. We conclude that the length of the spinal canal is shortened due to the decrease in intervertebral and intervertebral foramen height, which eventually the spinal canal length shortens. However, The length of the cauda equina actually not changed, RNRs are more likely to occur.

The curvature is an important feature in the structure of the spine and maintenance of spine curvature is closely related to the prevention of spinal diseases [27]. Ono et al. [3] found that the incidence of RNRs was higher in the neutral position of the lumbar spine than in the flexed position, when performing myelography. Mendelsohn et al. [28] observed that RNRs are aggravated during back extension and reduced during flexion. These results indicate that lumbar lordosis and lumbar spine mobility may be related to the occurrence of RNRs. In the current study, we demonstrated that, although not significant, ROM of the stenotic segment of patients in the RNRs group was larger than that in the NRNRs group.

5. Conclusion

The current study demonstrated that lumbar spinal stenosis accompanied by RNRs is common. Our data are consistent with previous studies that demonstrated the severity of symptoms and spondylolisthesis, and ligamentum flavum ligament hypertrophy are associated with formation of RNRs. In addition, we have demonstrated that length indices, including intervertebral height, intervertebral foramen height, and inter-vertebral height + vertebral height, are key factors leading to the formation of RNRs.

6. Abbreviations

RNRs:redundant nerve roots,

MRI:Magnetic resonance imaging ,

VAS:visual analogue scale ,

ODI:Oswestry disability index,

DIW-MSD:median sagittal diameter at the inter-vertebral space level,

DV-MSD:median sagittal diameter at the pedicel level,

CSA:canal cross-sectional area,

7. Declarations

Ethics approval and consent to participate

There is no relevant problems exist.

Consent for publication

Not applicable.

Competing interests

The authors declare that they have no conflict of interest.

Funding

Not applicable.

Authors' contributions

DB designed the study and developed the retrieval strategy. DB and HZH searched and screened the summaries and titles. DB drafted the article. All authors read and approved the final draft.

Acknowledgements

This study was supported by Medical Science and Technology Plan Project of Zhejiang Province(Grant No.2012KYA188).

8. References

1. Sorensen BF,Wirthlin AJ,Redundant nerve roots of the canna equina [J]Surgical neurology ,1975 , 3(4) ;177-181.
2. Suzuki K,Ishida Y,Ohmori K,et al. Redundant nerve roots of the cauda equina:clinical aspects and consideration of pathogenesis[J].Neurosurgery ,1989 , 24(4) : 521-528.
3. Ono A,Suctsuna F,Irie T,et al. Clinical significance of the redundant nerve roots of the cauda equina documented magnetic resonance imaging[J]J Neurosurg Spine,2007,7(1):27-32.
4. Min JH,Jang JS,Lee SH. Clinical significance of redundant nerve roots of the cauda equina in lumbar spinal stenosis [J]. Clin Neurol Neurosurg , 2008 ,110(1) :14-18.
5. Verbiest H. A radicular syndrome from developmental narrowing of the lumbar vertebral canal[J].J Bone Joint Surg Br,1954, 36-B(2): 230-237.
6. Cressman MR, Pawl RP. Serpentine myelographic defect caused by a redundant nerve root—a case report[J]. J Neurosurg,1968, 28(4):391-393.

7. Tsuji H, Tamaki T, Itoh T, et al. Redundant nerve roots in patients with degenerative lumbar spinal stenosis [J]. *Spine (Phila patients 1976)* 1985;10(1) ; 72-82.
8. Ozturk AK, Gokaslan ZL. Clinical significance of redundant nerve roots of the cauda equina [J]. *World Neurosurg*, 2014, 82(6): e717-718.
9. Min JH, Jang JS, Lee SH: Clinical significance of redundant nerve roots of the cauda equina in lumbar spinal stenosis. *Clin Neurol Neurosurg* 110:14-18, 2008.
10. Ono A, Suetsuna F, Irie T, Yokoyama T, Numasawa T, Wada K, et al. Clinical significance of the redundant nerve roots of the cauda equina documented on magnetic resonance imaging. *J Neurosurg Spine* 7:27-32, 2007.
11. Suzuki K, Ishida Y, Ohmori K, Sakai H, Hashizume Y: Redundant nerve roots of the cauda equina: clinical aspects and consideration of pathogenesis. *Neurosurgery* 24 : 521-528, 1989.
12. Suzuki K, Takatsu T, Inoue H, Teramoto T, Ishida Y, Ohmori K : Redundant nerve roots of the cauda equina caused by lumbar spinal canal stenosis. *Spine (Phila Pa 1976)* 17:1337-1342, 1992.
13. Savarese LG, Ferreira-Neto GD, Herrero CF, et al. Cauda equina redundant nerve roots are associated to the degree of spinal stenosis and to spondylolisthesis [J]. *Arq Neuropsiquiatr*, 2014, 72(10): 782-787.
14. Hur JW, Hur JK, Kwon TH, et al. Radiological significance of ligamentum flavum hypertrophy in the occurrence of redundant nerve roots of central lumbar spinal stenosis [J]. *J Korean Neurosurg Soc*, 2012, 52(3): 215-220.
15. Kubosch D, Vicari M, Siller A, et al. The Lumbar spine as a Dynamic structure depicted in upright MRI [J]. *Medicine (Baltimore)*, 2015, 94(32): e1299.
16. Kobayashi S, Uchida K, Takeno K, et al. Imaging of cauda equina edema in lumbar canal stenosis by using gadolinium-enhanced MR imaging: experimental constriction injury [J]. *AJNR Am J Neuroradiol*, 2006, 27(2): 346-353.
17. Olmarker K, Rydevik B, Holm S. Edema formation in spinal nerve roots induced by experimental, graded compression: an experimental study on the pig cauda equina with special reference to differences in effects between rapid and slow onset of compression [J]. *Spine (Phila Pa 1976)*, 1989, 14(6): 569-573.
18. Poureisa M, Daghighi MH, Eftekhari P, et al. Redundant nerve roots of the cauda equina in lumbar spinal canal stenosis, an MR study on 500 cases [J]. *Eur Spine J*, 2015, 24(10): 2315-2320.
19. Yukawa Y, Lenke LG, Tenhula J, et al. A comprehensive study of patients with surgically treated lumbar spinal stenosis with neurogenic claudication [J]. *J Bone Joint Am*, 2002, 84-A(11): 1954-1959.
20. Zhong ZM, Zha DS, Xiao WD, Wu SH, Wu Q, Zhang Y, et al. Hypertrophy of ligamentum flavum in lumbar spine stenosis associated with the increased expression of connective tissue growth factor. *J Orthop Res* 29 : 1592-1597, 2011.
21. Okuda T, Baba I, Fujimoto Y, Tanaka N, Sumida T, Manabe H, et al. The pathology of ligamentum flavum in degenerative lumbar disease. *Spine (Phila Pa 1976)* 29:1689-1697, 2004.

22. Kosaka H, Sairyo K, Biyani A, Leaman D, Yeasting R, Higashino K, et al. Pathomechanism of loss of elasticity and hypertrophy of lumbar ligamentum flavum in elderly patients with lumbar spinal canal stenosis. *Spine (Phila Pa 1976)* 32:2805-2811, 2007.
23. Sairyo K, Biyani A, Goel V, Leaman D, Booth R Jr, Thomas J, et al. Pathomechanism of ligamentum flavum hypertrophy: a multidisciplinary investigation based on clinical, biomechanical, histologic, and biologic assessments. *Spine (Phila Pa 1976)* 30:2649-2656, 2005.
24. Nakatani T, Marui T, Hitora T, Doita M, Nishida K, Kurosaka M: Mechanical stretching force promotes collagen synthesis by cultured cells from human ligamentum flavum via transforming growth factor-beta. *J Orthop Res* 20:1380-1386, 2002.
25. Yang SM, Park HK, Cho SJ, et al. Redundant nerve roots of cauda equina mimicking intradural disc herniation: a case report [J]. *Korean J Spine*, 2013, 10(1):41-43.
26. Bolender NF, Schonstrom NS, Spengler D. Role of computed tomography and myelography in the diagnosis of central spinal stenosis [J]. *Bone Jt Surg (Am)*, 1985, 67 (3) :240-246.
27. Chernukha KV, Daffner RH, Reigel DH. Lumbar lordosis measurement. A new method versus Cobb technique [J]. *Spine (Phila Pa 1976)*, 1998, 23(1) : 74-79.
28. Mendelsohn DB, Hertzanu Y. Migratory redundant lumbar nerve roots. A case report [J]. *S Afr Med J*, 1984, 66(12):461-462.

Figures

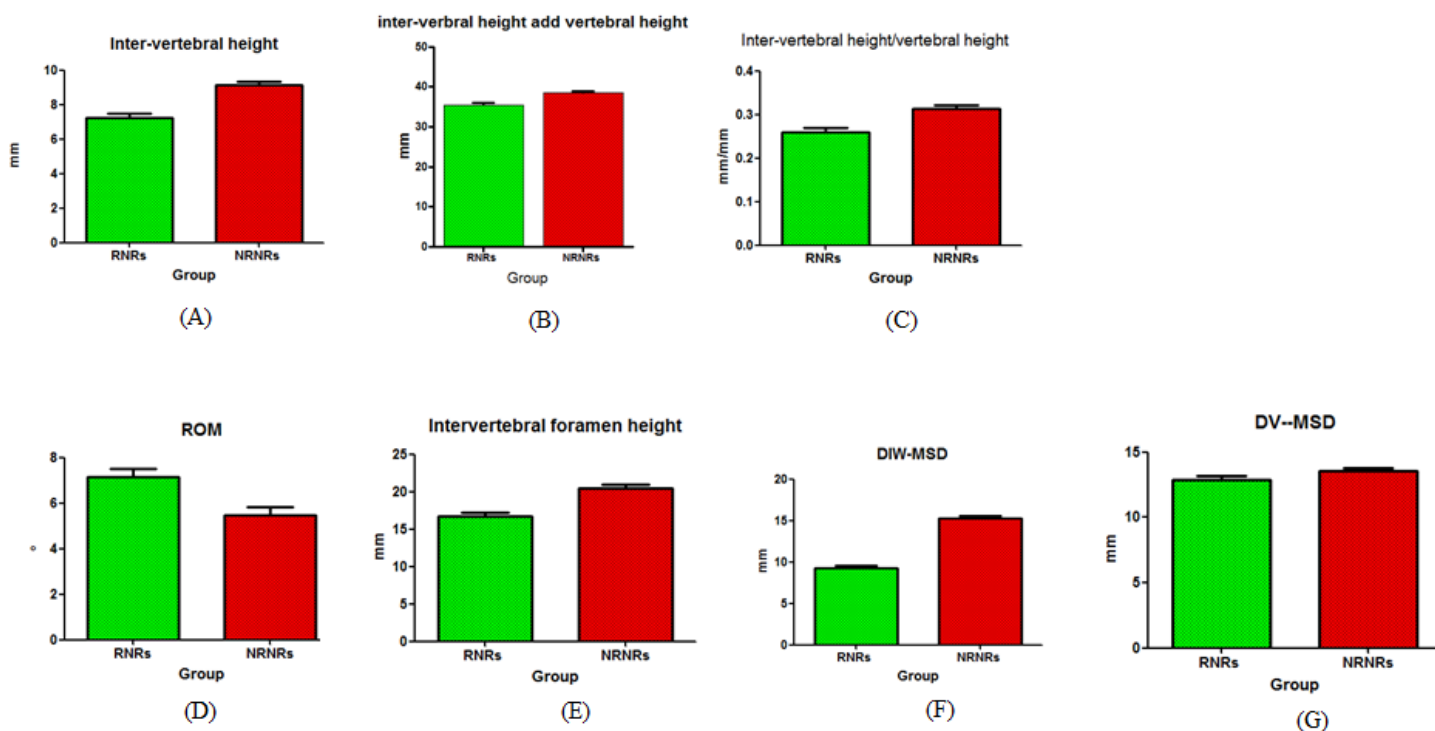


Figure 1

Inter-vertebral height((A), intervertebral foramen height(B), inter-vertebral height+vertebral body height(C),DIW-MSD (D),ROM of the stenotic segment (E)shows statistically significant differences between the two groups,however,CT images indicated that DV-MSD was not significantly different between the groups(F).

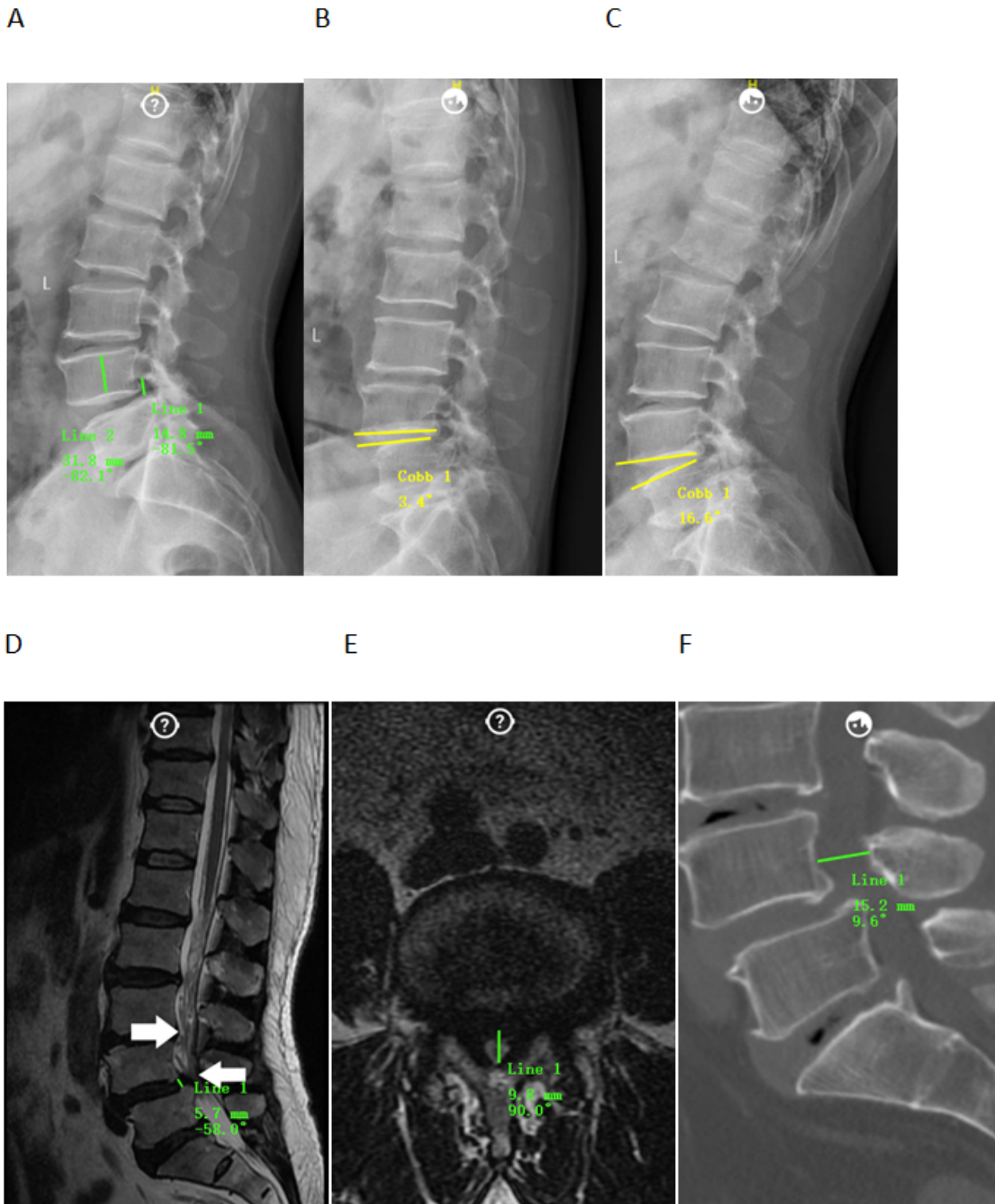


Figure 2

Method of measurement of intervertebral foramen height(A), vertebral body height(A),ROM of the stenotic segment(B and C),Inter-vertebral height(D),DIV-MSD(E),DV-MSD(F) by using Surgimap Spine software.This is a 54-year-old patient with spondylolisthesis.The result of the measurement is 14.8mm,31.8mm,(16.6-3.4)°,5.7mm,9.8mm and 15.2mm.