

Cup-to-Disc Ratio Based Efficient Glaucoma Prediction on Fundus Images Using Tripartite Tier Convolutional Neural Network

Prabakaran G

B V Raju Institute of Technology

Pitchai R (✉ pitchrks1984@gmail.com)

B V Raju Institute of Technology

Madhu Babu Ch

B V Raju Institute of Technology

Kalaiyarasi M

VSB Engineering College

Research Article

Keywords: Cup-to-Disc Ratio, Tripartite Tier-Convolutional Neural Network, Deep learning, Optic Disc, Optic Cup.

Posted Date: August 10th, 2021

DOI: <https://doi.org/10.21203/rs.3.rs-746252/v1>

License:  This work is licensed under a Creative Commons Attribution 4.0 International License.

[Read Full License](#)

Cup-to-Disc Ratio based Efficient Glaucoma Prediction on Fundus Images using Tripartite Tier Convolutional Neural Network

Prabakaran G¹, Pitchai R^{2*}, Madhu Babu Ch³, Kalaiyarasi M⁴

^{1,2,3}Department of Computer Science and Engineering, B V Raju Institute of Technology, Narsapur, Telangana, India

⁴Associate Professor, Department of Electronics and Communication Engineering, VSB Engineering College, Karur, Tamilnadu, India

Email: prabaharang@gmail.com, pitchrks1984@gmail.com, madhubabu.ch@bvrit.ac.in, mukalaiyarasi@gmail.com

Abstract

Glaucoma is a condition that causes permanent damage to the optic nerves, resulting in partial or total vision loss. In this paper, a deep learning model using Tripartite Tier Convolutional Neural Network (TTCNN) structure is proposed to detect the glaucomatous images from the normal images. The proposed system includes different steps such as preprocessing, attribute extraction, and glaucoma evaluation. Preprocessing discusses how to convert RGB fundus images to grayscale and how to improve fundus feature contrast. Then, the optic cup (OC) and optic disc (OD) boundaries are fragmented during the attribute extraction using TTCNN. Finally, the Cup-to-Disc Ratio (CDR) has been determined to diagnose glaucoma in the image. This system has been verified on two different publicly available datasets DRIVE and RIM-ONE, yielding an average sensitivity, specificity, accuracy, and precision in glaucoma diagnosis of 84.50%, 98.01%, 99%, and 84% respectively. The obtained results show that the proposed recognition system is suitable for detecting glaucoma with higher precision.

Keywords: Cup-to-Disc Ratio, Tripartite Tier-Convolutional Neural Network, Deep learning, Optic Disc, Optic Cup.

1. Introduction

Glaucoma is a serious retinal illness that can result in blindness if not recognized and cured properly. It occurs when the intraocular pressure rises above the baseline level. It affects the retinal nerve fiber layer and the optic disc, causing vision loss if not treated early [1-2]. The investigation of the optic nerve, the Optic cup to Disc Ratio (CDR), and the neural rim specifications are critical for recognizing glaucoma at the beginning stages. Due to the broadest

range of CDR, identifying early changes in the optic nerve head is difficult. As a result, there is a need to develop glaucoma recognition methods to help clinicians in diagnosing glaucoma at the preliminary stage. As previously stated, the most widely used parameter CDR is presently measured using a manual process [3-5]. This paper describes a deep learning-based glaucoma detection method for identifying glaucoma from the affected images.

Blindness is caused primarily by Glaucoma [6], which begins with high intraocular pressure (>21 mmHg) and progresses to optic nerve damage [7]. The existence of glaucoma is indicated by a CDR value higher than 0.3. Retinal fundus images are commonly used to measure the characteristics of the normal retina which includes blood vessels, Optic Disc (OD), Optic Cup (OC), and macula. The physical diameter of the OC in a healthy eye is 1.5 mm and is located 3 to 4 mm to the nasopharyngeal side of the cornea. Figure 1 shows the normal and glaucomatous eyes.

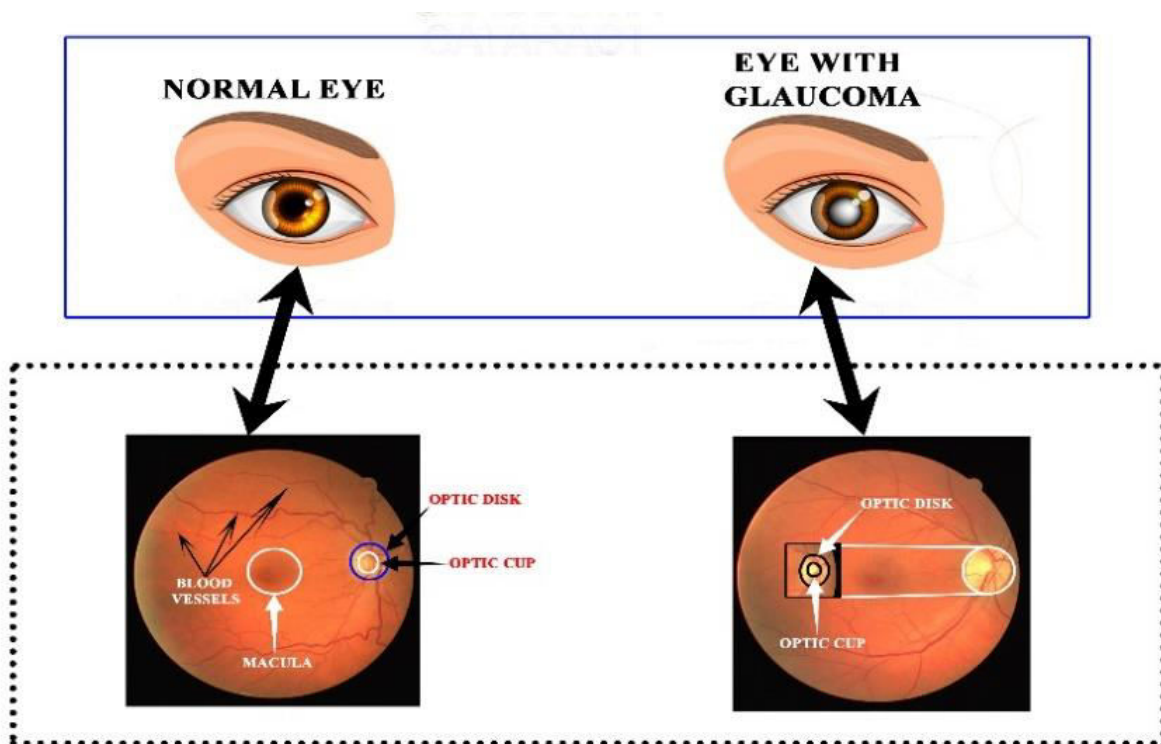


Figure 1: (a) Healthy eye (b) Glaucoma-suspicious eye

The proposed method's significant contribution has been given as follows.

- To fragment the OC from OD using deep learning based neural network.

- To increase the segmentation accuracy using TTCNN structure.
- Detection of glaucoma using SVM Classifier using CDR values.

This paper has been structured as follows. The background of this proposed glaucoma recognition method has been given in Section 2. Section 3 briefly explains the proposed recognition model. Section 4 gives the experimental outcomes and the performance metrics evaluation. The conclusion of this paper has been given in Section 5.

2. Related work

A lot of researchers have experimented on OD and OC-based glaucoma detection using fundus images. Among them, some of the works are analyzed here. Super-pixel classification-based OC segmentation for glaucoma detection has been presented in [8]. Histograms and center-surround statistical analysis were utilized in OD segmentation to categorize each superpixel as disc or non-disc. To assess the efficiency of the automated OD fragmentation, a self-assessment reliability score was calculated. Even though this method improves the performance, it yields poor segmentation results. In [9], OD and OC feature extraction from monocular fundus images for glaucoma analysis was demonstrated. They developed an OD classification model that incorporates local spatial information between each point of interest in multi-dentinal feature space. They used anatomical evidence such as vessel bends at the cup boundary to segment the cup. The method was tested on 138 images, 33 normal and 105 glaucomatous, against three glaucoma experts. Even though, in some cases, the method was produced irregular OD shapes. In [10], researchers have experimented with glaucoma detection based on deep learning, namely, modification of U-Net Convolutional Neural Network (CNN). A hierarchical technique for fast and accurate Optic Disc localization and segmentation is described in [11]. During the preprocessing stage, morphological operations were used to delineate and remove retinal vasculature and pathologies, which were then followed by the circular Hough transform for OD localization. The accurate OD and OC segmented value has been achieved by using this method. Similarly, in [12], a method for segmenting digital images utilizing an ensemble learning-based CNN structure is presented. To select informative points, an entropy sampling technique was used, which reduced computational complexity while outperforming uniform sampling. To obtain the resultant fragmentation, the classifier output was subjected to an unsupervised graph

cut technique has been followed by a convex hull transformation. In [13], a machine learning model was used to recognize OD and OC boundary lines. In this technique, at first, the superpixel data acquired by the entropy sampling method. This data was being used to train their proposed CNN structure. Finally, the classification has been done by using a softmax classifier.

There are some drawbacks to using feature extraction methods to detect glaucoma. Poor image artifact quality, such as distortion, lesser brightness, communication error, blurring effects, and non-uniform illumination, has been identified as a major impediment to accurate localization and detection of disc and cup contours [14]. Also, these methods are computationally expensive when used to fragment the OD and OC boundaries in images. Another issue is blood vessel interweaving in the cup region, which causes invisibility between the OD and cup borders [15]. As a result, accurate OC detection remains a difficult task for current automatic algorithms. Furthermore, it is difficult to obtain a precise CDR. The above-mentioned drawbacks are rectified in the proposed recognition method.

3. Materials and Methods

The block diagram of the proposed glaucoma recognition method has been given in Figure 2. This method includes different image processing steps such as image enhancement, image dilation, adaptive median filtering, OD, and OC segmentation using TTCNN and SVM Classification. Initially, the collected fundus imageries are enhanced through the image enhancement method. Here, the histogram equalization method has been utilized for image enhancement. The enhanced images are diluted and the diluted images are passed through the bilateral filter to remove the unwanted distortions. Then the images are segmented using the TTCNN method. From the segmented images, CDR has been evaluated, and then it is given to the SVM Classifier to classify the normal images from glaucoma-affected images. The different image processing steps used in the proposed method have been discussed in the following.

To evaluate the effectiveness of the TTCNN recognition method with existing methodologies, 209 fundus images are acquired from two standard fundus datasets, namely DRIVE and RIM-ONE. The image-level parameters for the selected material are shown in Table 1. These public datasets are most widely utilized to screening for glaucoma and diabetic retinopathy. At each image level, the identified datasets contain clinical experts' sarcoid ground

truth illustrations. These quantitative measurements attributes are now being used as a benchmark to evaluate the effectiveness of automated screening tools.

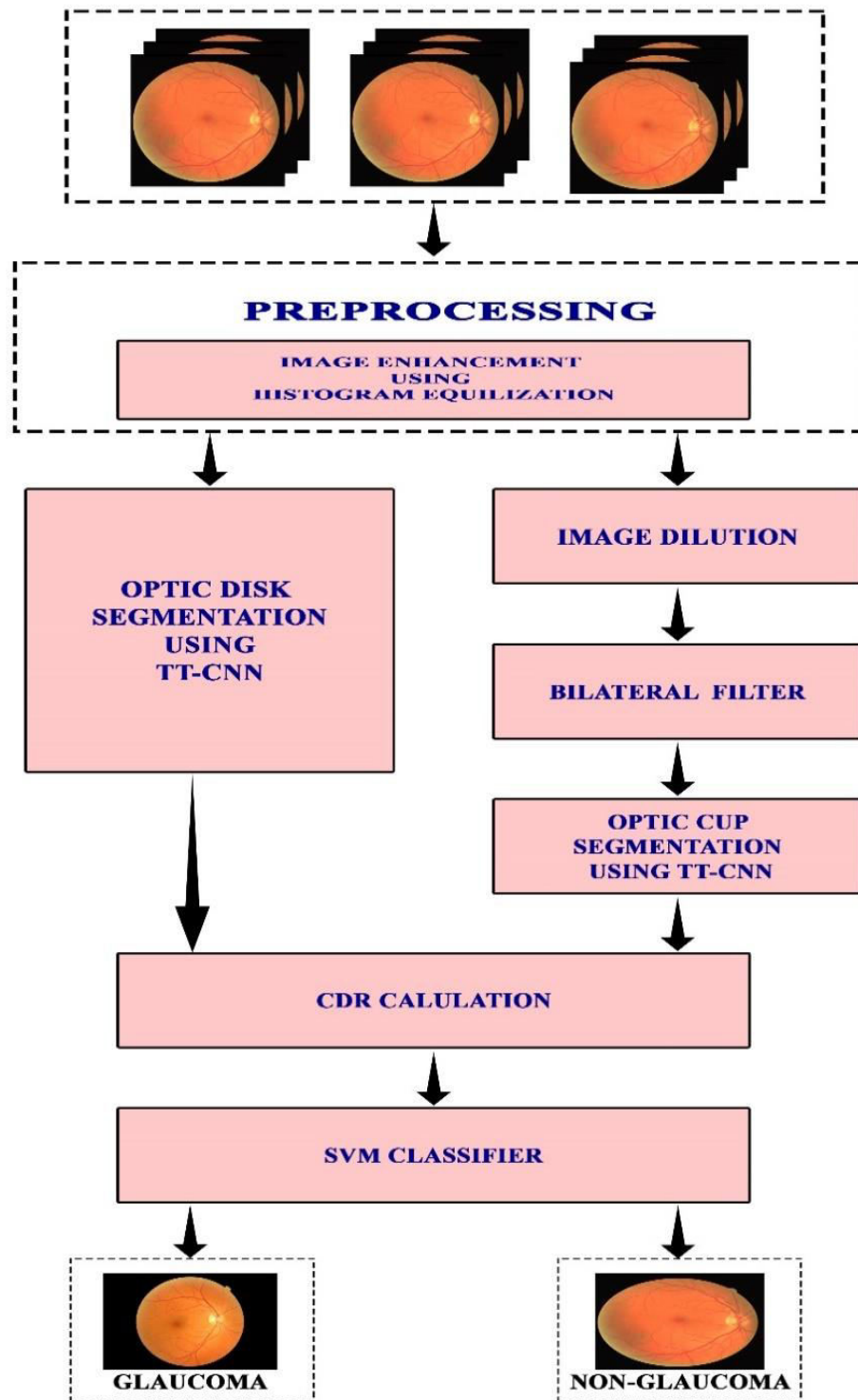


Fig. 2. Proposed Architecture

Table 1: Diagnosis of glaucoma on DRIVE and RIM-ONE Dataset

No	Name of the dataset	Images	Healthy	Glaucoma
1	DRIVE	40	34	6
2	RIM-ONE	169	118	51
	Total	209	152	57

3.1 Image preprocessing

Image preprocessing is used to enhance the input image quality of the original image by removing the unwanted distortion and improving the low contrast region. In this paper, histogram equalization has been employed to increase the image quality and make the OD and OC boundaries brighter. It modifies the intensity distribution to improve visual quality. This method improves the global contrast of many images, particularly when the image's usable data is represented by close contrast values. The intensities on the histogram can be better distributed with this adjustment. This improves the lower contrast region into the higher contrast region. An example of a greyscale image and its histogram has been given in Figure 3.

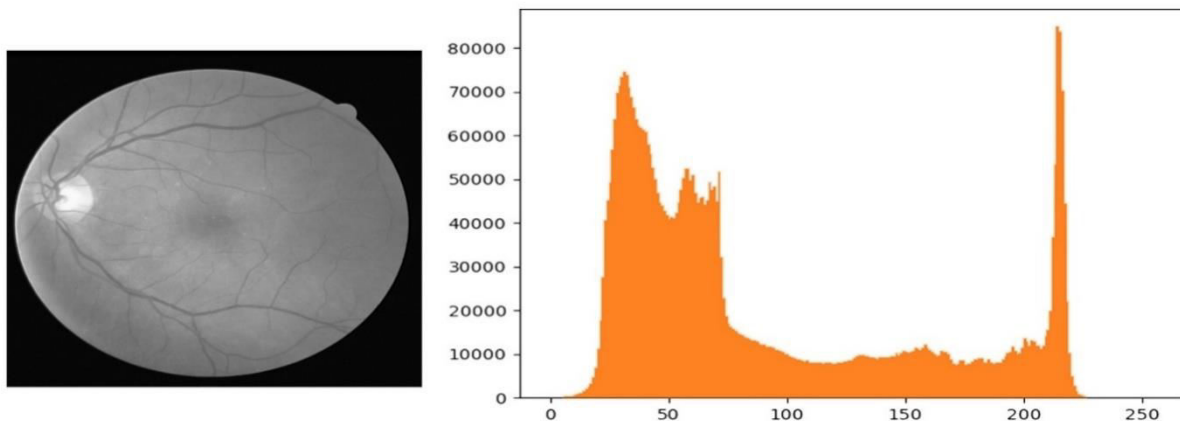


Figure 3: Greyscale image and its histogram output

3.1.3 OD segmentation using Tripartite Tier CNN (TTCNN)

The OD and OC segmentation has been performed by using the TTCNN network. The structure of TTCNN has been illustrated in Figure 4. This network contains three tiers namely Top, Middle, and Bottom tiers. Each tier performs various operations such as Convolution, Relu,

max pooling, drop. All the layers are fully connected in each tier. The convolutional layer conducts element-wise multiplication on the segment of the input, then adds the results in a single output cell. To achieve the best results using TTCNN, three types of filters with varied sizes are used: 3x3, 5x5, and 7x7. After that, the data has been sent to the pooling layer, which reduces the number of attributes obtained using the dataset. The TTCNN performs segmentation based on the findings of object detection.

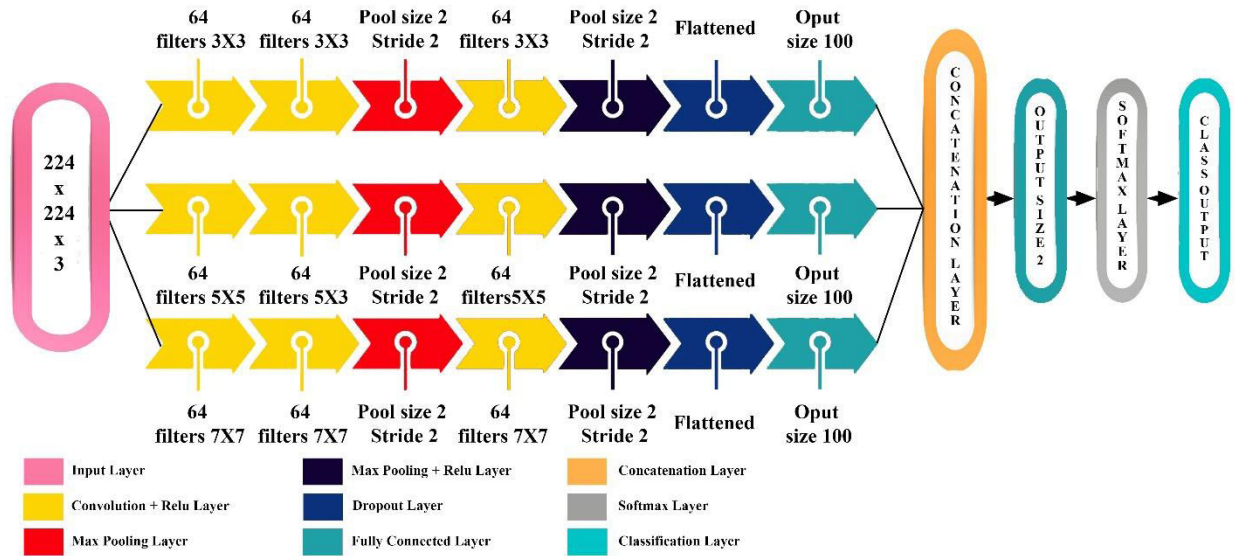


Figure 4: TTCNN network Structure

3.1.4 Image dilation

Both the OD and OC have been identified as the most prominent bright components of the fundus image. Due to the retinal vascular system in the cup region, OC segmentation is critical when compared with OD segmentation. As a result, dilation, a morphological operation, is used to suppress pectoral muscle and focus on improving the light intensity of the OD and OC [16]. It acts as a structural element in the image, enlarging the disc and cup. Consider X and Y to be two subgroups of a two-dimensional space. The testing image is denoted by X , and the structuring kernel is denoted by Y . The below equation depicts the dilation implementation on the RGB enhanced image.

$$X \oplus Y = \bigcup_{p \in X} Y_p \quad (1)$$

In a greyscale image, a morphometric gradient is used to fragment and diagnose the contours of a disc and a cup. It is a greyscale morphometric application that can be used for watershed

transformation techniques, particularly OC segmentation using image datasets. In equation (2), X represents an image received after the dilation procedure, and Y represents structure attributes. The resulting image by the morphometric gradient is denoted by G .

$$G = (X \oplus Y) - (X \oslash Y) \quad (2)$$

3.1.5 Adaptive Median filtering

The adaptive median filtering has been performed to remove the unwanted distortion that occurred during dilation [17]. Due to this operation, we can able to achieve more accurate segmentation results of OC. In this filtering, the central value of the window has been replaced with the median of the value of the kernel's window [18]. In addition to adaptive median filtering, the order statistics filter has also been utilized to increase the quality of the retinal fundus images. The mathematical expression of the OS filter has been given as follows:

$$K(i, j) = \{K(1)(i, j), K(2)(i, j), \dots, K(2m + 1)(i, j)\} \quad (3)$$

The intensity of the image K has been represented as (i, j) and $(2m + 1)$ represents the window L . The expression for the output of median filter can be represented as follows,

$$G(i, j) = K(m + 1)(i, j)$$

3.1.7 CDR measurement

After detecting OD and OC boundaries, the most widely used parameter CDR has been evaluated using retinal fundus images. Equation (10) gives the generally used mathematical expression for calculating CDR [19],

$$CDR = \frac{\text{total number of cup pixels}}{\text{total number of disc pixels}} \quad (4)$$

IV Experiment outcomes

The proposed system has been verified on a PC equipped with an Intel i7 7700 (LGA1151) 3.60GHz processor running at 3.48 GHz and 8 GB of RAM. The proposed glaucoma recognition algorithm is simulated using MATLAB 2019a, and the results are analyzed using different evaluation parameters which include Sensitivity, Specificity, Accuracy, and Precision. A total of 209 fundus images are collected from various public datasets (DRIVE and RIM-ONE) and assessed analyzed fundus images using the TTCNN method, finally, the results are tabulated in Table I. After the analysis, we found that 209 imageries include 150 normal fundus images and

260 glaucoma-affected images. The different evaluation metrics are theoretically described as follows [20],

$$Sensitivity = \frac{TP}{TP+FN} \quad (5)$$

$$Specificity = \frac{TN}{TN+TP} \quad (6)$$

$$Accuracy = \frac{TP+TN}{TP+TN+FP+FN} \quad (7)$$

$$Precision = \frac{TP}{TP+FP} \quad (8)$$

- Glaucoma images are detected accurately called True positives (TP).
- Non-glaucomatous images that have been accurately identified called True negatives (TN).
- A false positive occurs when an image that is not related to glaucoma is misinterpreted for glaucoma (FP).
- When a glaucomatous image is incorrectly categorized as a non-glaucoma image, a false negative arises (FN).

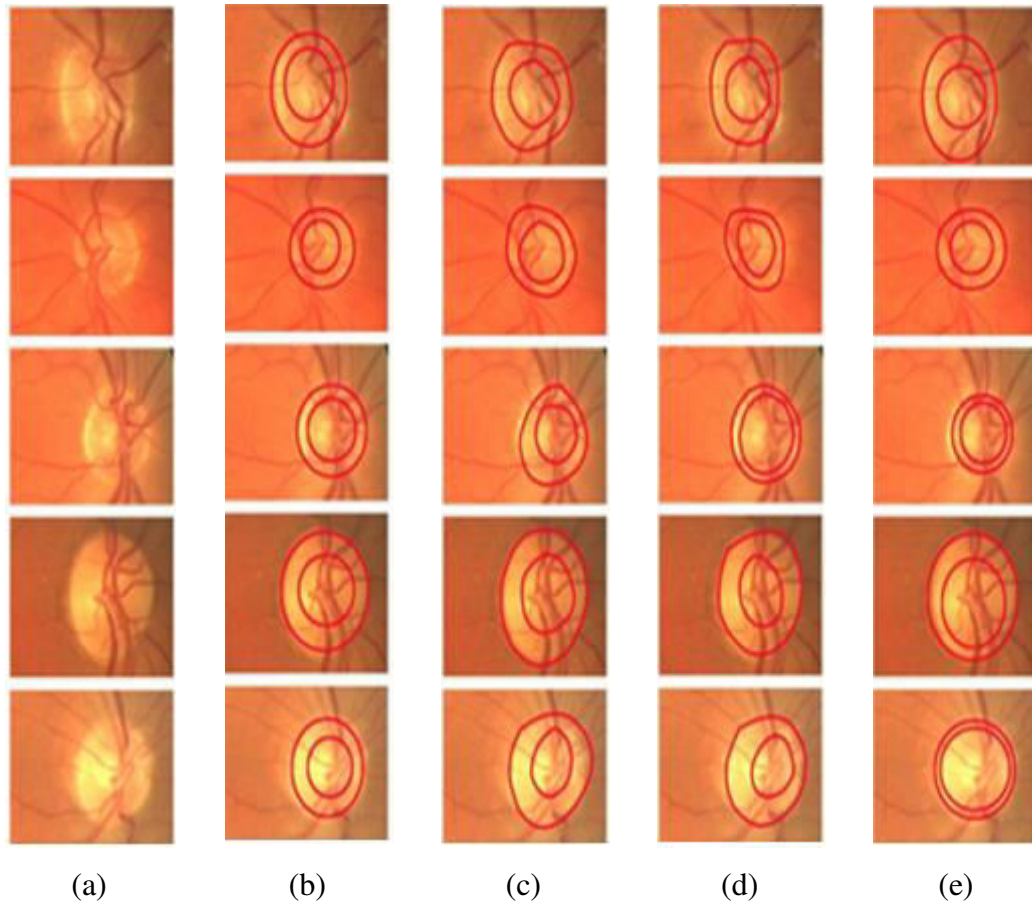


Figure 5: Results of OD and cup segmentation. a) Original image b) TTCNN c) U-Net CNN d) Deep Learning CNN e) CNN

The simulation outcomes of OD and OC segmentation using the proposed method has been given in Figure 5. This figure indicates that the proposed methodology can discern the OD and cup regions menta geometry of the areas.

Table 2: Different Evaluation metrics for Healthy and Glaucomatous images

No.	Glaucoma eye disease detection				
	Type	SE	SP	ACC	PRC
1	Healthy	85.17	98.45	99.00	82.01
2	Glaucoma	83.50	99.25	99.01	87.05
Average		84.50%	98.01%	99%	84%

Table 2 gives the different evaluation metrics of glaucoma and non-glaucomatous images. The average value of performance metrics is determined. The average SE of 84.50%,

SP of 98.01%, an ACC of 99%, and a PRC of 84% have been determined for the proposed method. Meanwhile, 83.50% of SE, 99.25% of SP, 99.01% of ACC, and 87.05% of PRC have been obtained for Glaucomatous images. As a result, the TTCNN can promptly identify glaucoma eye disease in a large-scale setting, removing the concern about clinical competency during the eye-screening procedure. **Table 3: The healthy and pathological images' MSE and SD**

Type	Feature	Database	MSE \pm SD
Normal Eye	CDR	150	0.292 \pm 0.123
Glaucomatous Eye	CDR	260	0.582 \pm 0.368

The Mean square error (MSE) and standard deviation (SD) for the healthy and glaucomatous images along with the CDR values are given in Table 3. The obtained SD is ± 0.123 for healthy images and ± 0.368 for glaucomatous images. The CDR value has been found that it is lower for healthy images and higher for glaucomatous images. Additionally, the proposed methodology has been compared with the existing glaucoma recognition methodologies, and the values are tabulated in Table 4. This table clearly shows that the proposed methodology outperformed in the diagnosis of glaucoma when compared with other existing methodologies such as CNN, Deep Learning CNN, and U-Net CNN.

Table 4: Performance Comparison results with TTCNN

Cited	Glaucoma was discovered using the techniques	
	Methodologies	Accuracy
[21]	CNN	96%
[22]	Deep learning CNN	98%
[23]	U-Net CNN	98%
	TTCNN	99.0%

5. CONCLUSIONS

In this paper, an early-stage CDR-based glaucoma detection system has been proposed. The proposed scheme included three major steps: preprocessing, feature extraction, and glaucoma assessment. post-processing. The histogram equalization method has been used to enhance the

contrast of fundus imageries. In the feature extraction stage, OD and cup are extracted using the TTCNN method. Then CDR value has been calculated after detecting disc and cup pixels. At last, based on the CDR values, the fundus imageries are categorized as glaucoma and non-glaucoma. This proposed method has been simulated on different publicly available datasets and the efficiency of the TTCNN structure has been determined using sensitivity, specificity, accuracy, and precision. The efficiency of this system is correlated with various existing recognition techniques which included CNN, Deep learning CNN, and U-Net CNN. From the analysis of the proposed system, we can conclude that the TTCNN recognition method has the potential to provide a precise solution for early-stage glaucoma detection. Further, this TTCNN method could be extended to assess glaucoma through OCT imageries and hybrid attributes such as neuroretinal rim shape, color, size, and vertical CDR.

Declarations

Funding: Not Applicable

Conflicts of interest/Competing interests : There is no Conflict interest

Availability of data and material (data transparency): Available

Code availability (software application or custom code): Available

Ethics approval : No human or animals used in our research

Consent to participate: Not Applicable

Consent for publication : We give our consent for the publication of identifiable details, which can include figures, graphs within the text to be published in the Artificial Intelligence Review Journal.

References

1. Juneja, M., Singh, S., Agarwal, N., Bali, S., Gupta, S., Thakur, N., & Jindal, P. (2019). Automated detection of Glaucoma using deep learning convolution network (G-net). *Multimedia Tools and Applications*, 1-23.
2. Abbas, Q. (2017). Glaucoma-deep: detection of glaucoma eye disease on retinal fundus images using deep learning. *Int J Adv Comput Sci Appl*, 8(6), 41-5.

3. Praveena, R., & Ganeshbabu, T. R. (2021). Determination of Cup to Disc Ratio Using Unsupervised Machine Learning Techniques for Glaucoma Detection. *Molecular & Cellular Biomechanics*, 18(2), 69-86.
4. Diaz-Pinto, A., Morales, S., Naranjo, V., Köhler, T., Mossi, J. M., & Navea, A. (2019). CNNs for automatic glaucoma assessment using fundus images: an extensive validation. *Biomedical engineering online*, 18(1), 1-19.
5. X. Chen, Y. Xu, D. Wing Kee Wong, T. Yin Wong, J. Liu, "Glaucoma detection based on deep convolutional neural network," *IEEE Eng Med Biol Soc*, pp. 715–718, Annual Conf., August 2015.
6. Akbar, S., Akram, M.U., Sharif, M., Tariq, A. and Yasin, U.U. (2017) 'Decision support system for detection of papilledema through fundus retinal images', *Journal of Medical Systems*, Vol. 41, No. 4, p.66.
7. Qaisar Abbas, " Glaucoma-Deep: Detection of Glaucoma Eye Disease on Retinal Fundus Images using Deep Learning", *International Journal of Advanced Computer Science and Applications*, Vol. 8, No. 6, 2017.
8. Jun Cheng, Jiang Liu, Yanwu Xu, Fengshou Yin, Damon Wing Kee Wong, NganMeng Tan, Dacheng Tao, Ching-Yu Cheng, Tin Aung, and Tien Yin Wong. "Superpixel classification based optic disc and optic cup segmentation for glaucoma screening", *IEEE transactions on Medical Imaging* 32, no. 6 (2013): 1019-1032.
9. Gopal Datt Joshi, Jayanthi Sivaswamy, and S. R. Krishnadas, "Optic disk and cup segmentation from monocular color retinal images for glaucoma assessment", *IEEE transactions on medical imaging* 30, no. 6 (2011): 1192-1205.
10. Artem Sevastopolsky, "Optic disc and cup segmentation methods for glaucoma detection with modification of U-Net convolutional neural network", *Pattern Recognition and Image Analysis* 27, no. 3 (2017): 618-624.
11. Muhammad Nauman Zahoor and Muhammad Moazam Fraz. "Fast optic disc segmentation in retina using polar transform." *IEEE Access* 5 (2017): 12293-12300.
12. Julian Zilly, Joachim M. Buhmann, and Dwarikanath Mahapatra, "Glaucoma detection using entropy sampling and ensemble learning for automatic optic cup and disc segmentation", *Computerized Medical Imaging and Graphics* 55 (2017): 28-41.

13. Shuang Yu , Di Xiao , Yogesan Kanagasingam, “Machine Learning Based Automatic Neovascularization Detection on Optic Disc Region”, *IEEE Journal of Biomedical and Health Informatics* , Volume: 22 , Issue: 3 , May 2018.
14. Akara Sopharak, Matthew N. Dailey , Bunyarit Uyyanonvara , Sarah Barman , Tom Williamson , Khine Thet Nwe and Yin Aye Moe, “Machine learning approach to automatic exudate detection in retinal images from diabetic patients “,*Journal of Modern Optics*, 57(2), 2010.
15. Juneja, M., Singh, S., Agarwal, N. *et al.* Automated detection of Glaucoma using deep learning convolution network (G-net). *Multimed Tools Appl* , <https://doi.org/10.1007/s11042-019-7460-4> , 2019.
16. Xiangyu Chen , Yanwu Xu , Damon Wing Kee Wong , Tien Yin Wong , Jiang Liu, “Glaucoma detection based on deep convolutional neural network”, *IEEE, 37th Annual International Conference of the IEEE Engineering in Medicine and Biology Society (EMBC)*, 2015.
17. Marcos Vinícius dos Santos Ferreira, Antonio Oseas de Carvalho Filho,, Alcilene Dalívia de Sousa, Aristófanés Corrêa Silva, Marcelo Gattass, “Convolutional neural network and texture descriptor-based automatic detection and diagnosis of glaucoma”, *Expert Systems with Applications*, Volume 110, Pages 250-263, 15 November 2018.
18. A. Diaz-Pinto, A. Colomer, V. Naranjo, S. Morales, Y. Xu and A. F. Frangi, "Retinal Image Synthesis and Semi-Supervised Learning for Glaucoma Assessment," *in IEEE Transactions on Medical Imaging*, vol. 38, no. 9, pp. 2211-2218, Sept. 2019.
19. Yunshu Qin, Ammar Hawbani, “A Novel Segmentation Method for Optic Disc and Optic Cup Based on Deformable U-net”, *Conference: IEEE-2018 International Conference on Artificial Intelligence and Big Data*, February 2019
20. Kalaiyarasi Murugesan et al., Color-based SAR image Segmentation using HSV+FKM clustering for estimating the deforestation rate of LBA-ECO LC-14 modeled deforestation scenarios, Amazon basin 2002-2005, *Arabian Journal of Geosciences*, 14, 777(2021).
21. Raja, C., & Vinodhkumar, D. N. (2020). An Efficient Segmentation Of Optic Disc Using Convolution Neural Network For Glaucoma Detection In Retinal Images. *European Journal of Molecular & Clinical Medicine*, 7(3), 2609-2627.

22. Veena, H. N., Muruganandham, A., & Kumaran, T. S. (2021). A novel optic disc and optic cup segmentation technique to diagnose glaucoma using deep learning convolutional neural network over retinal fundus images. *Journal of King Saud University-Computer and Information Sciences*.
23. Sevastopolsky. "A Optic disc and cup segmentation methods for glaucoma detection with modification of U-Net convolutional neural network", *Pattern Recognition and Image Analysis*, volume 27, pages 618–624, 2017.