

Comparative Effect of Dietary Supplements On Performance And Severity of Experimental Eimeria Tenella Infection In Broiler Chickens

Matthew Ogwiji (✉ ogwiji.matthew@gmail.com)

Ahmadu Bello University Faculty of Veterinary Medicine <https://orcid.org/0000-0002-1159-0902>

Jatau Isa Danladi

Ahmadu Bello University Faculty of Veterinary Medicine

Natala Audu Joseph

Ahmadu Bello University Faculty of Veterinary Medicine

Sani Dahiru

Ahmadu Bello University Faculty of Veterinary Medicine

Habibu Buhari

Ahmadu Bello University Faculty of Veterinary Medicine

Andamin Danlami Aliyu

Ahmadu Bello University Faculty of Veterinary Medicine

Kyari Stephen

Ahmadu Bello University

Gasaliyu Abidemi Khadijat

Ahmadu Bello University Faculty of Veterinary Medicine

Research Article

Keywords: prebiotic, probiotic, symbiotic, Eimeria tenella, performance, severity of infection

Posted Date: July 30th, 2021

DOI: <https://doi.org/10.21203/rs.3.rs-720045/v1>

License: © ⓘ This work is licensed under a Creative Commons Attribution 4.0 International License.

[Read Full License](#)

Abstract

The effect of the dietary supplements; sugarcane molasses (prebiotic), Antox[®] (probiotic) and Enflorax[®] (synbiotic) on gut health, performance and severity of infection with *Eimeria tenella* in broiler chickens were evaluated in this study. Ninety (90) day-old broiler chicks were divided into six groups (A, B, C, D, E and F). Groups B to F were challenged with *Eimeria tenella* (2.0×10^4 oocysts/chick). Groups C, D and E were supplemented from day old with prebiotic, probiotic and synbiotic respectively, while F was administered amprolium. Groups A and B served as negative and positive controls respectively. Feed intake and performance parameters were assessed weekly for each group. After infection clinical signs, morbidity and mortality rates were monitored alongside oocysts output, gross and microscopic caecal lesions. Infected chickens exhibited clinical signs 4 days post infection (dpi) with 100% morbidity in all infected groups. Infected groups showed significant ($P < 0.05$) drop in feed intake and weight gain from 3 - 5 weeks of age. Feed conversion ratio was highest in B but lower in the supplemented groups. Oocysts output in faeces were significantly lower ($P < 0.05$) in the supplemented groups compared with B. Macroscopic lesion scores 7 dpi were significantly lower in the supplemented groups compared with B, though Group F had the lowest mean score. Histopathological examination of caeca tissues showed milder lesions in the supplemented groups. In conclusion, the supplements prebiotic, probiotic and synbiotic ameliorated the consequences of caecal coccidiosis in broiler chickens and therefore recommended for use in broiler production.

Introduction

Coccidiosis, the most economically important parasitic disease of poultry is caused by members of the genus *Eimeria* and its usually characterized by gastrointestinal disturbances, high morbidity and mortality (Fanatico, 2006; Engidaw and Getachew, 2018). Several species of *Eimeria* have been identified in poultry (Fernandez et al. 2003) including the recently discovered *Eimeria zaria*, *E. nagambie* and *E. lata* (Blake et al. 2021), of which *E. tenella* and *E. necatrix* constitute the most pathogenic species (Musa et al. 2010; Owai and Mgbere, 2010) causing caecal and intestinal coccidiosis, respectively (Jatau et al. 2012). Coccidiosis is transmitted through the ingestion of feed, water, litter or other materials contaminated with sporulated *Eimeria* oocysts (Owai and Mgbere, 2010; Patrick and Mgbere, 2010). The disease causes substantial economic losses (Haile, 2018), according to an estimate, the poultry industry loses about 14.4 billion USD annually to coccidiosis (Blake et al. 2020). Growth and feed utilization are known to be severely hampered by the parasite. The most severe damage is said to be inflicted by the developmental stages of the parasite (Engidaw and Getachew, 2018). Sporozoites penetrate various regions of the host's epithelial cells in the gut lining depending on the species of *Eimeria*. *Eimeria tenella* is known to have a predilection for caeca epithelia and is particularly notorious because schizogony also takes place in the lamina propria and crypts of caeca epithelia, causing extensive tissue destruction, hemorrhages and drop in feed intake (Taylor et al. 2007; Engidaw and Getachew, 2018). The merozoites lyse infected host's intestinal epithelial cells to infect new epithelial cells of the intestine, destroying the epithelial cells and in the process interfere with digestion, impair nutrients absorption and caeca function with resultant losses

in productivity which is associated with the disease. Again, trophozoites, a developmental stage of the parasite also absorbs nutrients from the host which further deepens production deficits (Allen and Fetterer, 2002).

The control of coccidiosis relies majorly on chemoprophylaxis (the use of drugs) to prevent disease and vaccination with live or attenuated vaccines (Kheirabdi *et al.* 2014). The frequent use of these medications results in increased production costs and the emergence of drug resistant strains of *Eimeria species* (Chapman, 1997a; Pop *et al.* 2015). Following widespread reports of *Eimeria* resistance to conventional anticoccidials, public health concerns about their tissue residues and various side effects (Kheirabdi *et al.* 2014); a safer method of coccidiosis control is desired. Also, the use of antimicrobials at sub-therapeutic levels as growth promoters in poultry is considered hazardous and gradually being phased out (Portugalia and Fernandez, 2012). Upon the realisation of the connection between what transpires in the lumen of the gastrointestinal tract and numerous homeostatic phenomena in the body, it is no brainer that considerable interests have been kindled in modulation of critical components of the enteric microenvironment— the gut microbiota (Barbra *et al.* 2016); with the hope of beneficially influencing immunity, secretory, motility, sensory and neuroendocrine responses among others (Kabouridis and Pachnis, 2015; Thaïss *et al.* 2016; Dinan and Cryan, 2017). As the importance of the gut microbiota in health and disease is increasingly recognized, interest in interventions that can modulate the microbiota and its interactions with its host has also soared (Markowiak and Slizewska, 2017; Quigley, 2018).

The dietary supplements; prebiotics, probiotics and synbiotics have emerged as potential alternatives for growth enhancers, for their beneficial effects on health and performance (Trafalka and Grazy, 2004; Dankowiakowska *et al.* 2013); they are also reported to be safe, healthy and less hazardous compared with synthetic growth promoters (Onyimonyi and Onu, 2009). The mechanisms underlying probiotics' beneficial effects are thought to be associated with probiotics' antagonistic effects on pathogenic microorganisms through the release of antibiotic compounds, competitive adhesion to the mucosa and epithelium, strengthening of the gut epithelial barrier, immune system modulation among others (Collado *et al.* 2010).

Probiotics are live microbial organisms used as dietary supplements which have positive impact on the host animal's gut microbial balance and health (Hassan *et al.* 2012). Prebiotics are non-digestible feed elements that have favorable effects on the host by encouraging the growth and activity of one or a few beneficial bacteria in the colon (Gibson *et al.* 2010). Synbiotics, on the other hand, are probiotic and prebiotics combinations (Yang *et al.* 2009). The prebiotics create an ideal environment for the probiotic organisms to thrive, flourish and multiply (Sekhon and Jairath, 2010).

The use of these supplements has been adequately explored in the poultry industry especially in improving performance of birds and protection against enteric diseases. However, few have considered their comparative effects on the terribly devastating protozoal infection of poultry, coccidiosis. This study

was therefore designed to determine the comparative effects of a prebiotic, probiotic and synbiotic products on the performance and gut health of broiler chickens challenged with *Eimeria tenella*.

Materials And Methods

Ethical approval /statement of animal ethics

In this study, all procedures involving the use of broiler chicken were carried out in accordance with the Ahmadu Bello University Committee on Animal Use and Care's ethical standards and approval (No: ABUCAUC/2020/63) was obtained.

Housing and management of experimental chickens

The birds were housed at the experimental Poultry Research Pen of the Department of Veterinary Parasitology and Entomology, Ahmadu Bello University Zaria, in cages with wire-floored batteries raised to a height of 10 cm off the floor of the pen. Electric bulbs and large netted wire-meshed windows were used to maintain the recommended temperature. Feed and water were provided *ad libitum* throughout the study period. Feeders and drinkers (3 each) were provided per group with a 200-watt bulb in each of the 6 compartments to provide light and heat. Feeders and drinkers were washed on a daily basis to minimize risks of contamination. Faecal droppings were screened for coccidia oocysts using simple floatation technique as described by Dryden et al. (2005) before experimental infection.

Eimeria tenella parasite

The *Eimeria tenella* oocysts isolated and characterized by Jatau et al. (2016), maintained in 2.5 % potassium dichromate in the refrigerator (+ 4 ° C) at the Department of Veterinary Parasitology and Entomology, Ahmadu Bello University, Zaria was used for this study.

Experimental birds and infection

The study was performed in a 35-day period with experimental birds grouped into six (6) having fifteen (15) birds each, each group was further divided into three (3) replicates, containing five (5) birds. A total of ninety (n = 90) commercial broiler chicks purchased at day old were randomly assigned into the six (6) groups A, B, C, D, E and F. Group A was not supplemented or infected but served as the negative (non-infected) control. Group B birds were not supplemented but infected to serve as the positive (*Eimeria tenella*-infected) control. Groups C and D were supplemented with prebiotics and probiotics at 1 ml/L of drinking water while Group E was supplemented synbiotic at 1 g/L of drinking water from day old till end of the study. Lastly, Group F was not supplemented but administered Amprolium prophylactic treatment; 1 g/L of drinking water prior to infection and 0.25 g/L of drinking water thereafter for 5 and 7 days respectively. All birds in the challenged groups B to F were gavage with 0.15 ml of water containing 2.0×10^4 *Eimeria tenella* sporulated oocysts at 21 days of age as described by Kumar et al. (2014). All birds

were fed a basal diet and water *ad libitum*. Feeds used were purchased from a commercial poultry feed distributor with the following composition (Table 1):

Table 1: Composition of the broiler chicken diets used for the study.

Feed Composition	Starter	Finisher
<i>Ingredients (%)</i>		
Crude protein	22.00	18.0
Crude fat	4.50	5.50
Crude fibre	5.00	5.00
Calcium	1.10	1.0
Phosphorus	0.50	0.43
Lysine	1.33	1.05
Metabolizable energy (kCal/kg)	3000.00	3200.00

Supplements/drug

Sugarcane molasses (prebiotic) used was acquired from a local market in Zaria, Nigeria and it comprised; dry matter, sugar, crude protein, crude ash, potassium, phosphorus, magnesium, and sodium. Antox® (probiotic) used comprises; *Saccharomyces cerevisiae* 4.125×10^{-6} CFU/ml, then Citric acid, Lactic acid, B complex, Calcium chloride, Potassium iodide, Sodium selenite, Zinc chloride, Iron chloride, Magnesium chloride, Manganese chloride, Copper sulphate, and Cobalt chloride. En-florax® (synbiotic), had a mixture of strains of probiotic bacteria (*Enterococcus faecium* 1.5×10^{11} CFU/Kg, *Lactobacillus casei* 1.5×10^{11} CFU/Kg, *L. plantarum* 1.5×10^{11} CFU/Kg, *Pedicoccus acidilactici* 1.5×10^{11} CFU/Kg) and prebiotic substances: maltodextrin, fructo-oligosaccharides, oligofructose, and inulin then Crude protein, Crude fiber, Crude fat, Crude ash, Vitamin B12, Lysine, Methionine, Kwas fohoway, Vitamin B1 and Vitamin B2. The standard drug; Amprolium, is sold as 'Amprolium 250 wsp', a saturated powder of Amprolium hydrochloride (HCl), water-soluble for use in drinking water of poultry; used according to the producer's instruction. 100–150 g per 100 litres of drinking water for 5–7 days followed by 25 g per 100 litres for 1 or 2 weeks.

Observation of clinical signs, morbidity and mortality

Following infection onset of clinical signs, morbidity and mortality were monitored, recorded and calculated for each group. The morbidity and mortality rates were calculated as described by Bai *et al.* (2017):

$$\text{Morbidity rate} = \frac{\text{Number of sick birds}}{\text{Number of birds infected}} \times 100 \%$$

$$\text{Mortality rate} = \frac{\text{Number of dead birds}}{\text{Number of birds infected}} \times 100 \%$$

Determination of feed intake, weight gains and feed conversion ratio

Live body weight and weight gain were assessed on a weekly basis while the feed intake, feed conversion ratio and performance index for each group were determined as described by Jahan et al. (2006) using the formulae below:

$$\text{Daily feed intake (g/bird/day)} = \frac{\text{Feed offered} - \text{Feed left}}{\text{Number of chicks}}$$

$$\text{Feed conversion ratio} = \frac{\text{Feed intake during a period (g)}}{\text{Weight gain in that period (g)}}$$

$$\text{Performance index} = \frac{\text{Average live weight in Kg}}{\text{FCR}} \times 100$$

Faecal oocyst shedding

Faecal samples collected from each pen from 4–13 days post infection was kept in separate airtight plastic bags for determination of oocysts per gram (OPG) of faeces as described by Dalloul et al. (2003). The samples for each day were homogenized and stored at 4°C until processed and oocysts were counted microscopically using a McMaster counting chamber (Hodgson, 1970); all oocysts under the grid of each chamber in the McMaster were counted using a ×10 magnification. Results were then expressed as oocysts per gram of faeces (Dryden et al. 2005).

Caecal lesion scoring

At day 7 post infection, 3 chickens randomly selected from each group were humanely euthanized by cervical decapitation and the paired caeca were exteriorized for lesion scoring as described by Johnson and Reid (1970), caecal tissues were then harvested for microscopic examination.

Histopathology

Caecal tissues harvested were fixed in 10 % formolsaline for 24 h. Fixed tissues were histologically processed according to the method of Bancroft et al. (1990). Tissues were dehydrated through ascending grades of alcohol (70 %, 90 % and 100 %) for 2 h each. The tissues were then cleared in xylene for 2 h (1 h each, 2 changes). Tissues were impregnated/infiltrated in molten paraffin wax 2 h each (1 h each, 2 changes) and embedded in paraffin wax. The tissue blocks were sectioned at 5-micron thickness using Rotary microtome machine (Leica RT 25 made in England). Sectioned tissues were mounted on slides, dried and stained using Hematoxylin and Eosin (H and E) stain. Photomicrograph of stained slides of the tissues were taken using Amscope Digital Camera for microscope version 3.0, made in Japan.

Data analyses

Data obtained were subjected to two-way analysis of variance (ANOVA) followed by Bonferroni *post-hoc* test, lesion scores were analyzed using Kruskal-Wallis non-parametric test; using GraphPad Prism version 8.0.2 (GraphPad software, San Diego, CA, USA) for windows. Values of $P \leq 0.05$ were considered significant. The analyzed data were then expressed as Mean \pm SEM and presented in charts.

Results

Clinical signs

Four (4) days post infection (dpi), infected chickens showed signs of depression with whitish, mucoid diarrhoea and watery brown faeces. By the fifth day, feed intake dropped significantly in infected groups. Whitish, mucoid and brown faeces were seen with minute traces of blood in the infected groups. By 6 dpi faecal droppings had become fully bloody (projectile) diarrhoea. Two mortalities occurred in the positive control group. Other signs observed were; anorexia, somnolence, ruffled feather and weight loss. These signs appeared fairly milder in the amprolium treated and supplemented groups compared to the positive control.

Morbidity and mortality

Morbidity was 100 %. All inoculated chickens showed clinical signs of the infection in all groups. Mortality was 13.33 % (two deaths were recorded in the positive control group; no other group had mortality).

Feed intake

Figure 1 shows total feed intake per bird in all groups throughout the study period. Feed intake dropped after the infection at week 3 and gradually picked up again. There was significant ($P < 0.05$) difference between the feed intake in the non-infected (negative control) and the infected groups and also, between the infected non-supplemented (positive control) and the infected but supplemented groups.

Live body weight

Live body weight gains in the supplemented groups were significantly ($p < 0.05$) higher than infected non-supplemented (positive control) group (Fig. 2) compared with the infected but supplemented groups. Among supplemented groups, maximum weight gain was shown by the prebiotic group which was supplemented with sugarcane molasses followed by the groups supplemented with synbiotic and probiotic.

Weight gain

Body weight gains in the supplemented groups were significantly ($p < 0.05$) higher than infected non-supplemented (positive) control group (Fig. 3). Among supplemented groups, maximum weight gain was noted in the prebiotic group which was supplemented with sugarcane molasses followed by the groups

supplemented with synbiotic and probiotic products, respectively. The supplemented groups also gained more weight than F; administered amprolium prophylactic treatment.

Feed conversion ratio

The results of FCR (Fig. 4) revealed that the FCR values of the prebiotic group was lower compared with other groups prior to infection but rose after infection. Furthermore, the supplemented groups showed lower ($P < 0.05$) FCR compared with the amprolium medicated and infected (positive control) groups. Among the supplemented groups, the best FCR was observed in prebiotic followed by synbiotic.

Performance index

Analysis of weekly performance index showed higher performance in the supplemented groups. There was significant difference ($P < 0.05$) between uninfected (negative) control and the infected chickens 7 dpi in performance. The supplemented groups resolved the losses in production more rapidly by 14 dpi compared even to group F; medicated amprolium prophylactic treatment. The prebiotic, synbiotic and probiotic groups showed remarkable improvement, akin with the negative control (Fig. 5).

Lesion scoring

Figure 6 shows caecal macroscopic lesion scores by the method of Johnson and Reid (1970). Intestinal macroscopic lesions were completely absent in the negative control group, but present in the positive control, supplemented and medicated groups. The amprolium medicated group (F) showed significantly ($P < 0.05$) lower lesion score than the supplemented and infected groups. Among the supplemented groups, the least mean lesion scores were seen in the prebiotic supplemented group.

Faecal oocysts shedding

The result of the faecal oocyst shed (Fig. 7) revealed a pattern relatively similar to that of mean lesion scores among different groups. Oocyst output were lowest in the Amprolium medicated group compared with supplemented but infected groups. Among supplemented groups the maximum reduction in oocyst counts was seen in the prebiotic group followed by the probiotic and synbiotic groups respectively. Oocysts were detected in faeces from 6 dpi till end of the study, with the highest output occurring at 8 dpi after which it began to decline steadily.

Histopathological changes

Comparative histopathological observations of chicken caeca seven (7) days post infection with *Eimeria tenella* (2.00×10^4 sporulated oocysts/chick) are shown in the labelled plates below; beginning with the negative control (non-supplemented, uninfected) showing intact mucosal glands and caecal epithelium (Plate I). Next, is the positive control (non-supplemented, infected) showing desquamation of caecal epithelium and necrotic mucosal glands (Plate II). The supplemented groups showed milder pathologies. Plate III is a photomicrograph of the caecum from the prebiotic (sugarcane molasses) supplemented

group showing slight desquamation of epithelium. Plate IV shows photomicrograph of the caecum from the probiotic (Antox) supplemented group with desquamation of caecal epithelium. Plates V is a photomicrograph of the synbiotic (Enflorax) supplemented group showing necrotic mucosal gland and plate VI is a photomicrograph of Amprolium hydrochloride medicated group showing haemorrhages.

Discussion

Coccidiosis remains a major limiting factor challenging the optimization of the poultry industry in spite of the numerous research and management endeavors geared towards curbing the menace. Caecal coccidiosis caused by *Eimeria tenella* is a potent threat to global poultry production and food security (Malik *et al.* 2016). Jordan *et al.* (2002) noted that the life cycle of *Eimeria species* is rapid with a prepatent period of 4–5 days, which is consistent with the findings of this study where clinical signs became apparent 4 days post infection (dpi). At 6 dpi, *Eimeria tenella* infection in broiler chickens show clinically as bloody diarrhea (Kaewthamasorn *et al.* 2015) as also seen in this study. Assessment of the clinical signs observed in infected groups disclosed that the infection was most severe in the infected (positive) control group but less severe in the supplemented groups given prebiotic (sugarcane molasses), probiotic (Antox) and synbiotic (Enflorax) products while the amprolium hydrochloride medicated group exhibited the least severity in clinical signs as expected since amprolium is a standard anticoccidial drug. The milder severity seen in the supplemented groups compared with the infected control group may have resulted from a possible resistance to colonization of caecal epithelium or a more rapid immune response. Sugarcane molasses like most prebiotics, rich in sugars reportedly compete for sugar receptors with enteric pathogens and thus prevent their adhesion and subsequent colonization (Iji and Tivey, 1998; Awais *et al.* 2011) which consequently enhance their elimination with the flow of digesta (Fernandez *et al.* 2002). Rolfe (1991) stated that one of the means probiotic organisms (which are contained in Antox and Enflorax) exert their protective effects on a host is through the 'competitive exclusion' of pathogenic organisms, by adhering to the mucosal surface to prevent establishment of pathogens on the mucosa. It may be inferred therefore, that the clinical signs were less severe in the supplemented groups because these supplements resisted *Eimeria tenella* sporulated oocysts from colonizing the caeca of the broiler chickens. Also, morbidity rate recorded in this study was 100 %, all inoculated chickens succumbed to the infection in all groups while mortality rate recorded was 13.33 %. This is consistent with the findings of Fanatico (2006), who stated that morbidity and mortality rates in coccidiosis can be quite high. Also, antioxidant properties of the supplements, may have generated oxidative stress on the parasites and neutralized reactive oxygen species, accounting for the greater survival rate seen in supplemented groups (Alia *et al.* 2019).

Holdsworth *et al.* (2004) specified that the World Association for the Advancement of Veterinary Parasitology (WAAVP) needs the determination of live body weight, weight gain and feed conversion ratio to appraise the severity of infection. As a direct correlation exists between these performance parameters and the severity of an infection. The term 'Performance' is used by poultry producers and researchers all the world to judge level of success in terms of financial returns and management and this objective is

assessed through various parameters like live body weight gain, weight gain, feed intake, feed conversion ratio, performance index and so on.

In the present study, feed intake was found to be significantly higher ($p < 0.05$) in the uninfected (negative) control than in the infected groups from 3–5 weeks post infection. *Eimeria* is known to cause depression and injury to intestinal tissues thus discouraging feed intake (Taylor et al. 2007; Engidaw and Getachew, 2018). Among infected groups, the amprolium medicated group showed a significantly higher feed intake (Fig. 1) than others. The supplemented groups also showed better feed intake than the infected (positive) control. The better feed intake in the supplemented groups administered sugarcane molasses, Antox and Enflorax is not unrelated to the aforementioned resistance to *Eimeria* colonization and less severity in clinical signs hitherto.

Live body weight gained in Fig. 2 shows the sugarcane molasses group had the highest final mean live weight gain (2245.23 ± 29.46 g) at the end of the study which was slightly higher (numerically) than the negative control (2211.30 ± 37.40 g) though not statistically significant. Compared with the negative control group, there was significant fall in live body weight gain from 3–5 weeks in chickens infected *Eimeria tenella*, similar to the trend observed in the weekly weight gain assessment. Coccidiosis is known to exert such effects in infected chickens (Taylor et al. 2007; Engidaw and Getachew, 2018). Overall body weight gain of the supplemented and negative control groups was significantly higher ($p < 0.05$) than the infected non-supplemented group. The considerable increase in mean live weight gain in supplemented groups as compared to the infected control group could be attributable to suppression of inflammation in the intestinal mucosa, the implication of which is higher nutrient absorption across the intestinal wall and improved feed conversion ratio in the groups (Gotep *et al.* 2016).

Weight gain assessed on a weekly basis shows the body weight gain from 21 to 35 days of age was significantly reduced in all infected groups (Fig. 3) in comparison to the uninfected (negative) control. The positive control group had the least body weight gain in that period. Amprolium medicated group, recorded better weekly weight gain than the positive control group as should be expected. Variations in body weight gain in broiler chickens challenged with coccidiosis have been linked to changes in maintenance requirements, malabsorption of feed and reduced feed intake (Zhang *et al.* 2016). When birds are infected with coccidiosis, their nutritional needs are known to increase within the first week of infection (Cornelissen *et al.* 2009; Cox *et al.* 2010). Increased metabolic expenditures for healing injured tissues, immune system stimulation and diminished capability to use and transform nutrients into energy are only a few of the documented maintenance requirements (Chen et al. 2016; Grenier *et al.* 2016). The body's innate immune system can also create extra collateral damage, such as fever and inflammatory reactions, which further deplete resources, reduce nutritional stores and increase catabolism (Klasing and Iseri, 2013; Iseri and Klasing, 2014). These account for the severe losses in weight gain in infected chickens.

Another parameter, the feed conversion ratio (FCR) determined weekly was significantly lower in the prebiotic group prior to infection when compared with other groups. This is not surprising, given that

sugarcane molasses is rich in sugars which readily supplied glucose, also; crude ash and proteins. Sugarcane molasses is also known to have rich antioxidant properties (Valli *et al.* 2012), likewise probiotic organisms known to bestow potent antioxidant rich properties to their host (Serban, 2015; Tian *et al.* 2017). Upon *Eimeria* challenge, the raise in FCR seen from 3–5 weeks of age in all infected groups is consistent with coccidiosis (Alia *et al.* 2019). However, the supplemented groups, having had higher resistance to colonization, feed intake and a less severe inflammation with destruction of caeca tissues showed a much lower FCR compared with the infected control.

The results of the performance index point to a significant ($p < 0.05$) difference between the negative and positive controls with amprolium medicated groups. A significant difference also existed between the negative control and amprolium medicated groups and the supplemented groups. Although Geier *et al.* (2009) reported that prebiotics did influence intestinal microbiota and not performance of broiler chickens, several studies have reported significant increase in performance and live weight gains (Hidalgo *et al.* 2009; Ndelekwute *et al.* 2010; Habibu *et al.* 2014). Gultemirian *et al.* (2014) and Hwangbo *et al.* (2013) attributed the better performance to increased short chain fatty acid production in the caeca and lowered intestinal pH which enhanced resistance to pathogens. Moreover, prebiotic ingredients (inulin, oligofructose, fructo-oligosaccharides and maltedextrin) present in the synbiotic supplement enhanced the performance of that group. Overall performance was better in the supplemented groups compared with the infected (positive) control, akin with the uninfected (negative) control suggesting that the supplements amended production inefficiencies typical of caecal coccidiosis.

No oocysts were detected in the faeces of birds in the negative control group, whereas oocyst shedding in faeces rose steadily from the sixth to eighth day post challenge in the infected groups and began to drop gradually thereafter, oocysts shedding in the supplemented groups were significantly lower ($p < 0.05$) compared with the positive control group. Among supplemented groups, birds which received sugarcane molasses shed fewer oocysts while those medicated amprolium hydrochloride shed the least oocysts during the same period ($p < 0.05$). Oocysts were detected in the faeces of infected chickens up to 13 dpi. Prolong shedding of oocysts in faeces of infected chickens even after the clinical disease is common in coccidiosis (Conway and Mckenzie, 2007; Engidaw and Getachew, 2018). The effectiveness of probiotic organisms in reduction of oocyst shedding is well documented (Dalloul *et al.* 2003; Caballero-Franco *et al.* 2007; Lee *et al.* 2011; Fatoba *et al.* 2018). Since *Eimeria* is an intracellular parasite, it has to infiltrate host cells by first sticking to epithelial surfaces in order to reproduce. Probiotic bacteria that have colonized the gut may compete for adhesion sites and share receptors on epithelial cells. This prevents *Eimeria* oocysts from infiltrating and penetrating, as well as their reproducing and shedding oocysts. In broiler chickens, probiotics are said to have an immunoregulatory effect on the local immune system and increased resistance to *Eimeria* (e.g., reduced oocyst shedding) and also increased antibody production against *E. tenella* (Lee *et al.* 2007). Antioxidant rich properties of the supplements must have played a key role here as well, generating reactive oxygen radicals that may have resulted in toxic insult to the parasite with subsequent oxidative damage and death.

The data with regards to macroscopic caeca lesion scores and histopathology by day 7 post infection indicates that *E. tenella* provoked significant injuries to the intestinal mucosa. The lesions seen in the caeca of *E. tenella* infected broiler chickens fed prebiotic, synbiotic and probiotic showed significantly ($p < 0.05$) lesser mean lesion scores and histopathology compared to the positive control. Severe destruction of caecal mucosal layer and penetration of epithelial cells with resultant desquamation of caecal epithelium due to the attachment and invasion by *E. tenella* are characteristic of the disease (Zulpo et al. 2007; Bould et al. 2009). Histopathological lesions in *E. tenella* infection includes loss of caecal villi, necrosis and haemorrhages of caecal mucosa (Adamu et al. 2013; Sharma et al. 2015; Abdelrazek et al. 2020) as seen in the present study. The reduction in caeca lesion scores and histopathology by the supplements may be attributed to lower intestinal pH and conditions appropriate to increase useful microflora (Taherpour et al. 2012). The amprolium medicated group naturally had the least mean lesion score. Lesions in coccidiosis are said to depend on degree of inflammation and injury to gut health and often include thickened intestinal wall, blood-tinged exudates; petechial hemorrhages, hemorrhagic enteritis, profuse bleeding in the caeca and necrosis (Engidaw and Getachew, 2018). Use of probiotic organisms have been widely confirmed to reduce microscopic lesions in chickens infected coccidiosis (Ritzi et al. 2014; Chen et al. 2016).

In conclusion the standard drug (Amprolium) offered protection against severe clinical manifestations, mortality and equally reduced performance deficits consistent with caecal coccidiosis compared with the positive (infected) control. However, it did not enhance overall productivity in the infected chickens as much as the prebiotic, probiotic and synbiotic supplemented groups as seen in results obtained in weekly weight gain, live body weight gain and feed conversion ratio. The dietary supplements offered adequate preservation of gut health following challenge with *Eimeria tenella*; as seen in mean caeca lesion scores, histopathology and faecal oocyst shedding as much as prophylactic treatment with Amprolium hydrochloride which points to their ability to enhance resistance to *Eimeria* colonization. Therefore, the use of these supplements is recommended for broiler production.

Declarations

Funding: No funding was received by any of the authors for this research.

Conflict of interest: The authors declare no potential conflict of interest.

Ethical approval: The ethics governing the use and conduct of experiments on animals were strictly observed, and the experimental protocol was approved by the Ahmadu Bello University Committee on Animal Use and Care (No: ABUCAUC/2020/63).

Acknowledgements

The authors wish to acknowledge contributions of the staff of the Protozoology Research Labouratory, Clinical Pharmacology Labouratory and Pathology Labouratory of the Faculty of Veterinary Medicine, Ahmadu Bello University, Zaria, Nigeria.

Authors' contributions

Ogwiji Matthew, Jatau Isa Danladi, Natala Audu Joseph, Sani Dahiru discussed and came up with the research topic and design; Ogwiji Matthew, Habibu Buhari and Andamin Danlami Aliyu, Kyari Stephen and Gasaliyu Abidemi Khadijat **were involved in the laboratory work as well as statistical analysis of result under the supervision of** Jatau Isa Danladi, Natala Audu Joseph, Sani Dahiru. All authors contributed to the discussion of results.

The animals used for the research were kept and handle according to the ethical guideline/rules on animal handling by the ethics committee.

Availability of data and material

The datasets generated in the current study are available from the corresponding author

Code availability

Not applicable

Consent to participate

Authors have permission to participate.

Consent for publication

Authors have permission for publication.

References

1. Bancroft JD, Stevens A and Turner DR (1990) Theory and practice of histological techniques. 3rd ed. Churchill Livingstone. London, UK. 726 pp
2. Barbara G, Feinle-Bisset C and Ghoshal UC (2016) The intestinal microenvironment and functional gastrointestinal disorders. *Gastroenterology* 18(2): 35–42
3. Bera AK, Bhattacharya D, Pan D, Dhara A, Kumar S and Das SK (2010) Evaluation of economic losses due to coccidiosis in poultry industry in India. *Agricultural Economics Research* 23:91–96.
4. Blake DP, Knox J, Dehaeck B, Huntington B, Rathinam T, Ravipati V, Ayoade S, Gilbert W, Adebambo AO, Jatau ID, Raman M, Parker D, Rushton J and Tomley FM (2020) Re-calculating the cost of coccidiosis in chickens. *Veterinary Research* 51:115 <https://doi.org/10.1186/s13567-020-00837-2>
5. Blake DP, Vrba V, Xi D, Jatau ID, Spiro S, Nolan M J, Underwood G and Tomley FM (2021) Genetic and biological characterisation of three cryptic *Eimeria* operational taxonomic units that infect chickens (*Gallus gallus domesticus*). *International Journal for Parasitology* 12:004 <https://doi.org/10.1016/j.ijpara.2021.12.004>

6. Bould JG, Elsheikha HM and Morsy TA (2009) Avian coccidiosis: The basic pathology to control. *Journal of the Egyptian Society of Parasitology* 39(1): 85–98.
7. Caballero-Franco C, Keller K, De Simone C and Chadee K (2007) The VSL#3 probiotic formula induces mucin gene expression and secretion in colonic epithelial cells. *American Journal of Physiology* 292: G315–G322.
8. Chapman HD (1997a) Milestones in avian coccidiosis research: a review. *Poultry Science* 93(3): 501–511.
9. Chapman HD (1997b) Biochemical, genetic and applied aspects of drug resistance in *Eimeria* parasites of the fowl. *Avian Pathology* 26:221–44. <http://dx.doi.org/10>
10. Chen CY, Chuang LT, Chiang YC, Lin CL, Lien YY, Tsen HY (2016) Use of a probiotic to ameliorate the growth rate and the inflammation of broiler chickens caused by *Eimeria tenella* infection. *Journal of Animal Research and Nutrition* 1(2):1–7
11. Collado MC, Gueimonde M. and Salminen S (2010) Probiotics in adhesion of pathogens: mechanisms of action. In: Watson, R. R. & Preedy, V. R. (Eds): *Bioactive Foods in Promoting Health*, Chennai, Academic Press, Elsevier 23:353–370.
12. Conway D and McKenzie ME (2007) *Poultry Coccidiosis, Diagnostic and Testing Procedures*. 3rd Ed. Pp. 37–40). Ames, Iowa: Blackwell publishing.
13. Dalloul RA, Lillehoj HS, Shellem TA and Doerr JA (2003) Enhanced mucosal immunity against *Eimeria acervulina* in broilers fed a lactobacillus-based probiotic. *Poultry Science* 82(1): 62–66.
14. Dalloul RA, Lillehoj HS, Tamim NM, Shellem TA and Doerr JA (2005) Induction of local protective immunity to *Eimeria acervulina* by a lactobacillus-based probiotic. *Comparative Immunology, Microbiology and Infectious Disease* 28 (5–6):351–361
15. Dankowiakowska A, Kozłowska I and Bednarczyk M (2013) Probiotics, prebiotics and synbiotics in poultry – mode of action, limitation, and achievements. *Journal of Central European Agriculture*, 2013, 14(1): 467–478 DOI: 10.5513/JCEA01/14.1.1222
16. Dinan TG and Cryan JF (2017) The microbiome-gut-brain axis in health and disease. *Gastroenterology Clinical Journal of North America* 46:77–89.
17. Dryden MW, Payne PA, Ridley R and Smith V (2005) Comparison of common fecal flotation techniques for the recovery of parasite eggs and oocysts. *Veterinary Theriogenology* 6(1): 15–28
18. Engidaw A and Getachew G (2018) A review on poultry coccidiosis. *Abyssinia Journal of Science and Technology* 3(1):1–12.
19. Fanatico A (2006) Parasite management for natural and organic poultry Coccidiosis. <http://attra.ncat.Org/attar-pub/PDF/coccidiosis.pdf>. .
20. Fatoba JA and Adeleke MA (2018) Diagnosis and control of chicken coccidiosis: a recent update. *Journal of Parasitic Diseases* 42(4):483–493 <https://doi.org/10.1007/s12639-018-1048-1>
21. Fernandez F, Hinton M and Van-Gils B (2002) Dietary mannan-oligosaccharides and their effect on chicken caecal microflora in relation to *Salmonella enteritidis* colonization. *Avian Pathology* 31: 49–

58.

22. Fernandez S, Pagotto AH, Furtado MM, Katsuyama AM, Madeira AMBN and Gruber AA (2003) Multiplex PCR assay for the simultaneous detection and discrimination of the seven *Eimeria* species that infect domestic fowl. *Parasitology* 127:317–25.
<http://dx.doi.org/10.1017/S0031182003003883>.
23. Geier MS, Torok VA, Allison GE, Ophel-Keller K and Hughes RJ (2009) Indigestible carbohydrates alter the intestinal microbiota but do not influence the performance of broiler chickens. *Journal of Applied Microbiology* 106: 1540–1548
24. Gibson GR, Scott KP, Rastall RA, Tuohy KM, Hotchkiss A, Dubert-Ferrandon A, Gareau M, Murphy EF, Saulnier D. and Loh G (2010) Dietary prebiotics: current status and new definition. *Food Science and Technology Bulletin - Functional Foods* 7:1–19.
25. Gultemirian ML, Corti HR, Perez Chiaia A and Apella MC (2014) Fermentation in vitro of a mixture of dietary fibres and cane molasses by the cecal microbiota: Application on mineral absorption through the laying hens colonic epithelium. *Animal Science Technology* 191: 79–82.
26. Habibu B, Ikira NM, Buhari HU, Aluwong T, Kawu MU, Yaqub L S, Tauheed M and Isa HI (2014) Effect of molasses supplementation on live weight gain, haematological parameters and erythrocyte osmotic fragility of broiler chicken in the hot-dry season. *International Journal of Veterinary Science* 3(4): 181–188.
27. Haile G (2018) Review on *Eimeria*: The role of characteristic lesions as routine diagnostic technique. *International Journal of Current Research and Academic Review* 6(7): 9–18.
28. Hassan ER, Zeinab KME, Girh MA and Mekky HM (2012) Comparative studies between the effects of antibiotic (oxytetracycline); probiotic and acidifier on *E. coli* infection and immune response in broiler chickens. *Journal of American Science* 8:795–801.
29. Hildalgo K, Rodriguez B, Valdivie M and Febles M (2009) Utilizacion de la viniza de destileria como aditivo para pollos en ceba. *Revista Cubana de Cien Agric* 43(3): 281–284.
30. Hodgson JN (1970) Coccidiosis: Oocyst counting technique for coccidiostat evaluation. *Experimental Parasitology* 28:99–102.
31. Holdsworth PA, Conway DP, McKenzie ME, Dayton AD, Chapman HD and Mathis GF (2004) World Association for the Advancement of Veterinary Parasitology (WAAVP) guidelines for evaluating the efficacy of anticoccidial drugs in chickens and turkeys. *Veterinary Parasitology* 121:189–212
<http://dx.doi.org/10.1016/j.vetpar.2004.03.006>
32. Hwangbo J, Choi HC, Park SO, Rhu CM, Park BC, Kang HK, Seo OS and Choi YH (2013) Diet with soya oil, molasses, Methionine, lysine and vitamin C improves the growth performance of broilers exposed to extreme heat stress. *Journal of Animal Veterinary Advances* 12(4): 464–471
33. Iji PA and Tivey DR (1998) Natural and synthetic oligosaccharides in broiler chicken diets. *World's Poultry Science Journal* 54: 129–143.
34. Jahan MS, Asaduzzaman M and Sarkar AK (2006) Performance of broiler fed on mash, pellet and crumble. *International Journal of Poultry Science* 5(3): 265–270

35. Jatau ID, Lawal IA, Kwaga JK, Tomley FM, Blake DP and Nok AJ (2016) Three operational taxonomic units of *Eimeria* are common in Nigerian chickens and may undermine effective molecular diagnosis of coccidiosis. *BMC Veterinary Research* 12, 86
36. Jatau ID, Sulaiman NH, Musa IW, Lawal AI, Okubanjo OO, Isah I and Magaji Y (2012) Prevalence of *Coccidia* infection and preponderance *Eimeria species* in free range indigenous and intensively managed exotic chickens during hot-wet season, in Zaria, Nigeria. *Asian Journal of Poultry Science* 6: 79–88.
37. Johnson J and Reid WM (1970) Anticoccidial drugs: lesion scorings techniques in battery and floor-pen experiments with chickens. *Experimental Parasitology* 28:30–36.
38. Jordan F, Pattison M, Alexander D and Faragher T (2002) Parasitic diseases. In: *Poultry Disease* (5th Ed.) Pp. 405–420. Hong Kong: W.B. Saunders.
39. Kabouridis PS and Pachnis V (2015) Emerging roles of gut microbiota and the immune system in the development of the enteric nervous system. *Journal Clinical Investigation* 125:956–964.
40. Kheirabadi PK, Jahangir KK, Shahab B, Jaime AT, Amir DS and Mehdi C B (2014) Comparison of the Anticoccidial Effect of granulated extract of *Artemisia sieberi* with Monensin in Experimental Coccidiosis in Broiler chickens. *Journal of Experimental Parasitology* 141: 129–133.
41. Kumar S, Garga R, Moftahb A, Clark EL, MacDonald SE, Chaudhry AS, Sparagano O, Banerjeea PS, Kundua K, Tomleyc FM and Blake DP (2014) An Optimised Protocol for Molecular Identification of *Eimeria* from Chickens. *Veterinary Parasitology* 199:24–31
42. Lee SH, Lillehoj HS, Dalloul RA, Park DW and Hong Y H (2007) Influence of *Pediococcus* based probiotic on coccidiosis in broiler chickens. *Poultry Science* 86: 63–6
43. Markowiak P, and Slizewska, K (2017) Effects of Probiotics, Prebiotics, and Synbiotics on Human Health. *Nutrient* 9:10–21; doi:10.3390/nu9091021
44. McDougald LR and Hu J (2001) Blackhead disease (*Histomonas meleagridis*) aggravated in broiler chickens by concurrent infection with caecal coccidiosis (*Eimeria tenella*). *Avian Diseases* 45:307–312.
45. Mohiti-Asli M and Ghanaatparast-Rashti M (2015) Dietary Oregano essential oil alleviates experimentally induced coccidiosis in broilers. *Journal of Preventive Veterinary Medicine* 120:195–202
46. Musa IW, Sa'idu L, Jatau JT, Adamu J, Out MO and Abdu PA (2010) Outbreak of coccidiosis in 5-day old commercial breeder flock in Zaria, Nigeria. *International Journal of Poultry Science* 9(12): 1112–1115.
47. Ndelekwute EK, Uzegbu HO, Igwe IR, Nosike RJ, Odoemelam VU and Inyan UO (2010) Effects of administration of molasses through drinking water on growth and conformation parameters of meat-type chicken. *Animal Production Research Advances* 6(1): 30–34.
48. Onyimonyi E and Onu E (2009) An assessment of Pawpaw leaf meal as protein ingredient for finishing broiler. *International Journal of Poultry Science* 8(10): 995–998

49. Owai PU and Mgbere G (2010) Effects of components of *Melia azadirachta* on coccidia infections in broilers in Calabar, Nigeria. *International Journal of Poultry Science* 9(10): 931–934.
50. Patrick OU and Mgbere M (2010) Effects of components of *Melia azadirachta* on coccidia infections in broilers in Calabar, Nigeria. *International Journal of Poultry Sciences* 9 (10): 931–934.
51. Pop L, Gyorke A, Taraban AF, Dumitrache MO, Kalmar Z, Mircean V, Zagon D, Balea A and Cozma V (2015) Effects of artemisin in broiler chickens challenged with *Eimeria acervulina*, *E. maxima* and *E. tenella* in battery trials. *Journal of veterinary parasitology* 214: 264–271
52. Portugaliza HP and Fernandez TJ (2012) Growth performance of Cobb broilers given varying concentrations of malunggay (*Moringa oleifera* lam) aqueous leaf extract. *Journal of Animal and Feed Research* 2(6):465–469
53. Quigley EMM. (2018) Prebiotics and Probiotics in Digestive Health. *Clinical Gastroenterology and Hepatology* <https://doi.org/10.1016/j.cgh.2018.09.028>
54. Ritzi MM, Abdelrahman W, Mohnl M and Dalloul RA (2014) Effects of probiotics and application methods on performance and response of broiler chickens to an *Eimeria* challenge. *Poultry Science* 93(11):2772–2778.
55. Rolfe RD (1991) Population dynamics of the intestinal tract; in Blankenship LC (ed): *Colonization Control of Human Bacterial Enteropathogens in Poultry*. San Diego, Academic Press, pp 59–75.
56. Ruff MD and Wyatt RD (1978) Influence of dietary aflatoxin on the severity of *E. acervulina* infection in broiler chickens. *Avian Diseases* 22:471–480.
57. Sekhon BS and Jairath S (2010) Prebiotics, probiotics and synbiotics: An overview. *Journal of Pharmaceutical Education and Research* 1:13–36.
58. Taherpour K, Moravej H, Taheri HR and Shivazad M (2012) Effect of dietary inclusion of probiotic, prebiotic and butyric acid glycerides on resistance against coccidiosis in broiler chickens. *Journal of Poultry Science* 49:57–61
59. Taylor MA, Coop RL, and Wall R (2007) *Veterinary Parasitology*. 3rd Ed. Pp. 475–483. Oxford, UK: Blackwell Publishing.
60. Thaiss CA, Zmora N and Levy M (2016) The microbiome and innate immunity. *Nature* 535 65–74
Doi: 10.1038/nature18847/
61. Trafalka E and Grazy BK (2004) An alternative to antibiotics? *Journal of poultry science* 57: 491–498
62. Yang Y, Iji P, and Choct M (2009) Dietary modulation of gut microflora in broiler chickens: A review of the role of six kinds of alternatives to in-feed antibiotics. *World's Poultry Science Journal* 65:97–114
63. Zulpo D, Dauton L, Jaidson P, Leandro M, Elaine L, Marcos RO, Ivens GG, Selwyn AH, Jose da Silva GJ and Joao LG (2007) Pathogenicity and histopathological observations of commercial broiler chicks experimentally infected with isolates of *E. tenella*, *E. acervulina* and *E. maxima*. *Londrina, Semina: ciencias Agrarias* 28(1):97–104.

Figures

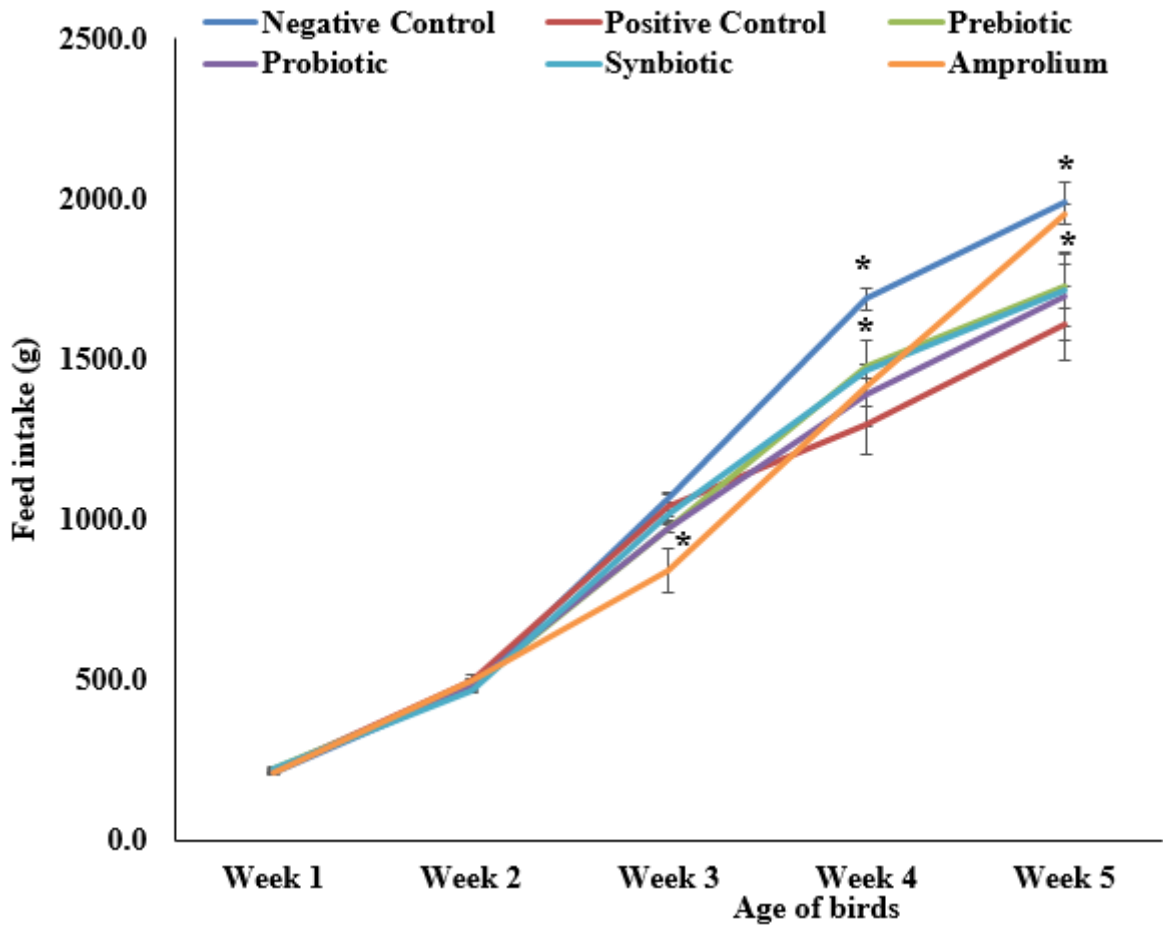


Figure 1

Effect of prebiotic, probiotic and synbiotic supplementation on feed intake per bird in all groups in *E. tenella* challenged broiler chickens. * refers to means that are statistically significant ($p < 0.05$).

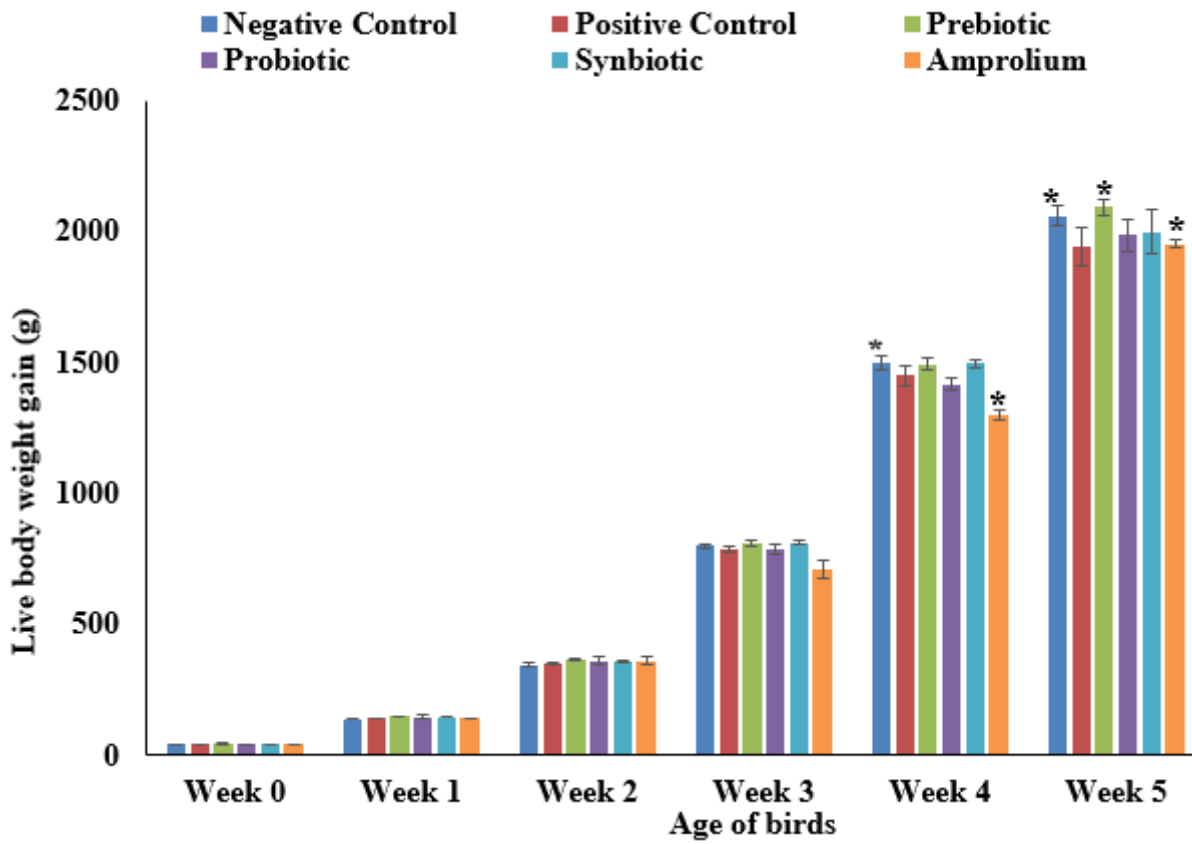


Figure 2

Effect of prebiotic, probiotic and synbiotic supplementation on live body weight gain in *E. tenella* challenged broiler chickens throughout the study period. * refers to means that are statistically significant ($p < 0.05$).

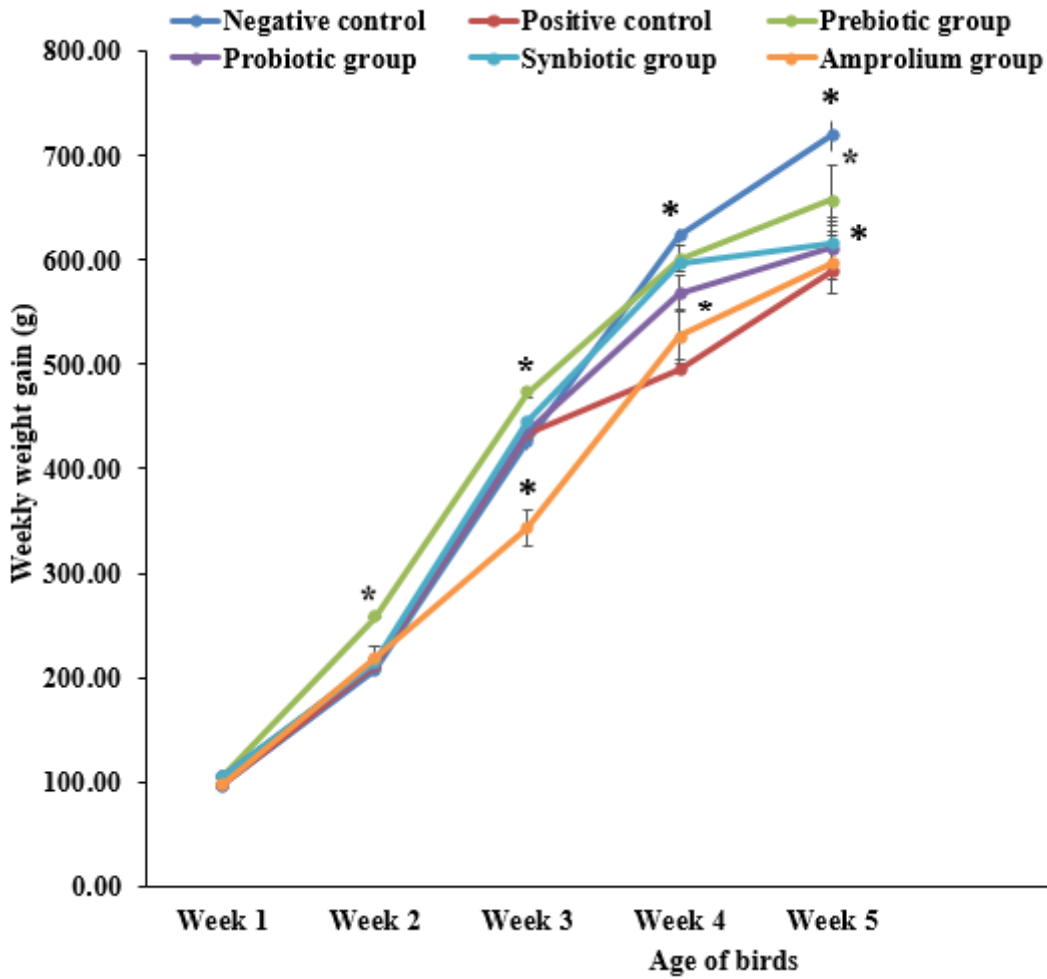


Figure 3

Effect of prebiotic, probiotic and synbiotic supplementation on weekly weight gained in *E. tenella* challenged broiler chickens. * refers to means that are statistically significant ($p < 0.05$).

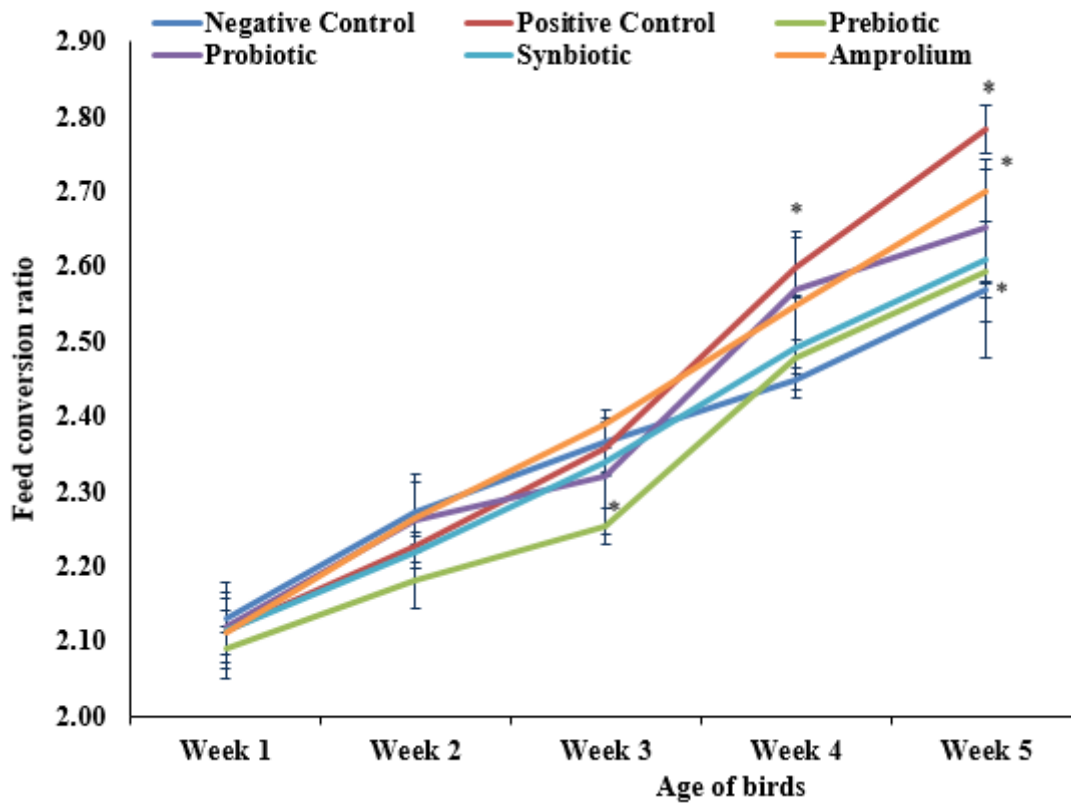


Figure 4

Effect of prebiotic, probiotic and synbiotic supplementation on feed conversion ratio in *E. tenella* challenged broiler chickens. * refers to means that are statistically significant ($p < 0.05$).

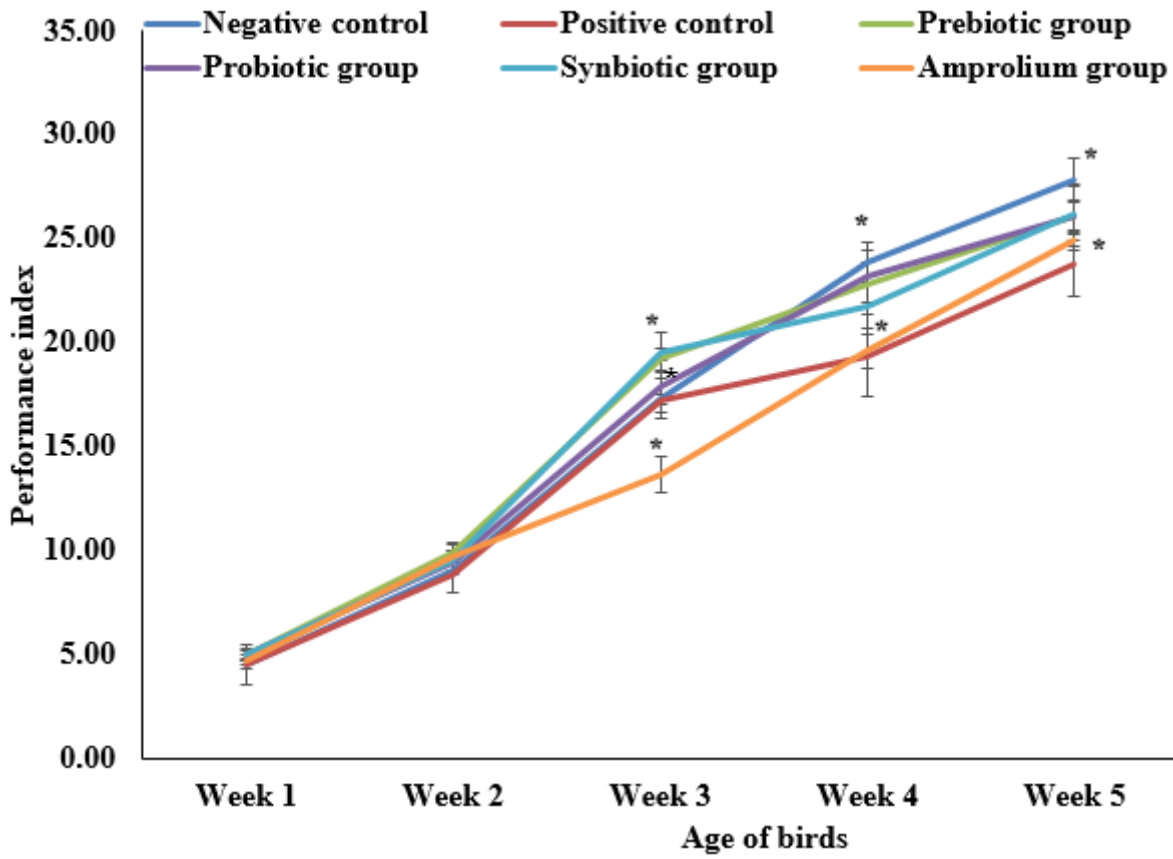


Figure 5

Effect of prebiotic, probiotic and synbiotic supplementation on performance index in *E. tenella* challenged broiler chickens. * refers to means that are statistically significant ($p < 0.05$).

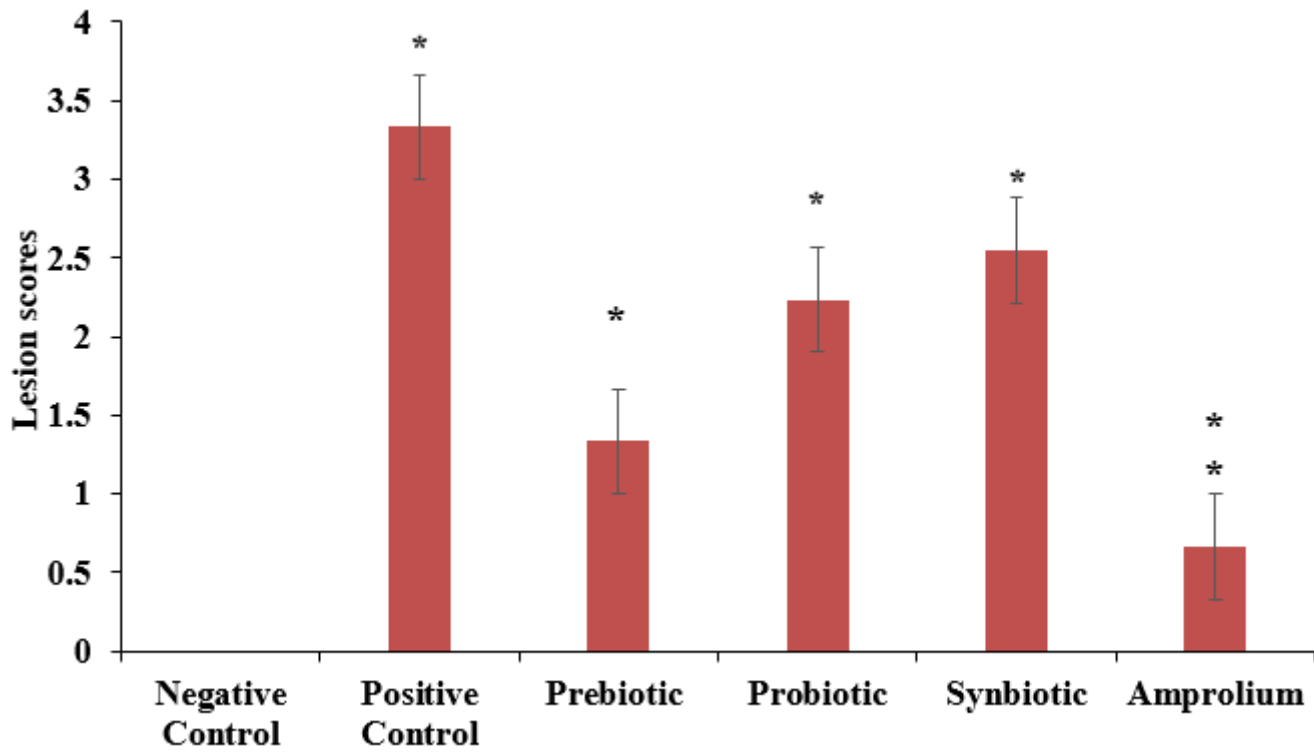


Figure 6

Effect of prebiotic, probiotic and synbiotic supplementation on macroscopic lesion scoring in *E. tenella* challenged broiler chickens. * refers to means that are statistically significant ($p \leq 0.05$).

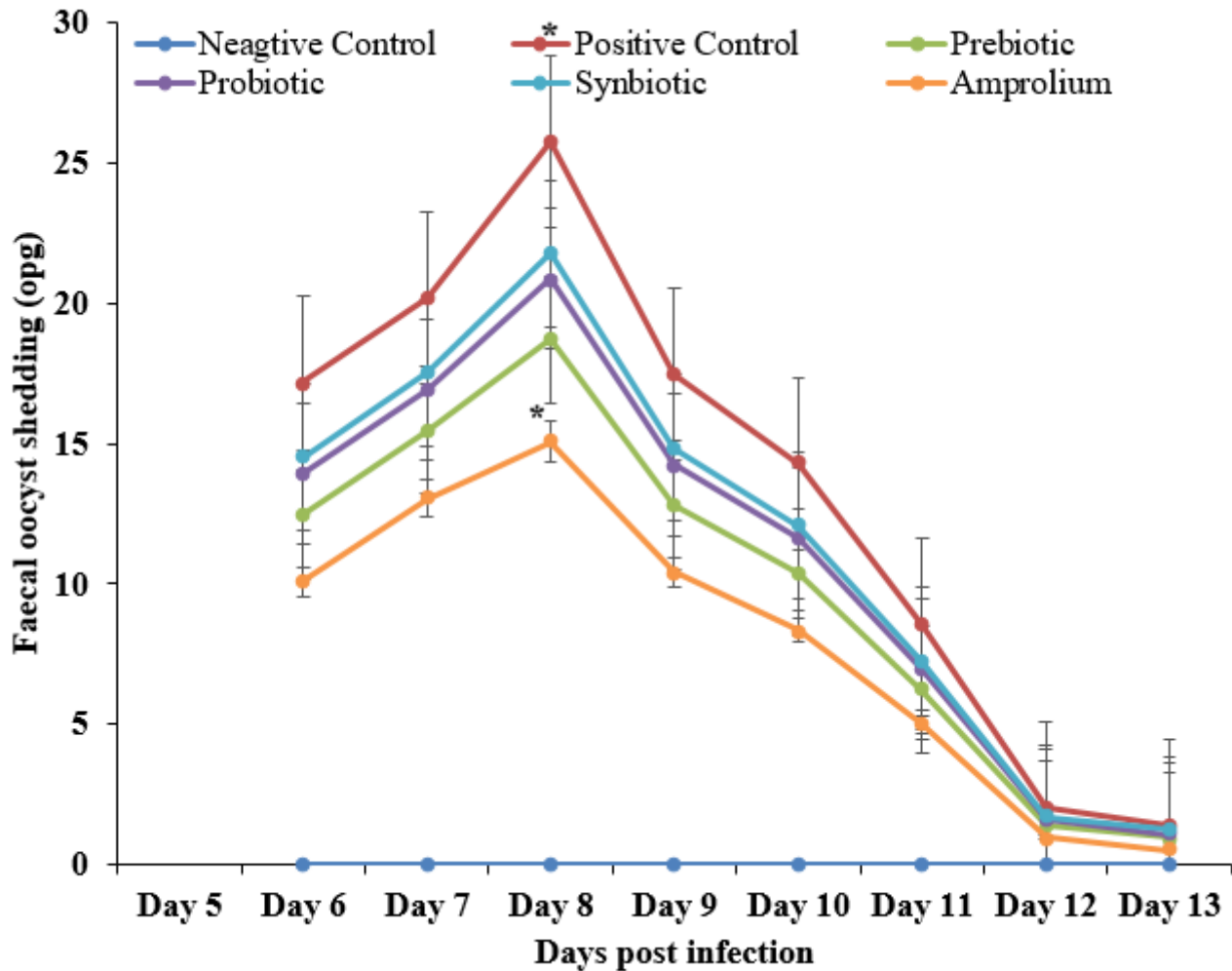


Figure 7

Effect of prebiotic, probiotic and synbiotic supplementation on faecal oocysts shedding in *E. tenella* challenged broiler chickens. * refers to means that are statistically significant ($p < 0.05$).

Supplementary Files

This is a list of supplementary files associated with this preprint. Click to download.

- [plate1.png](#)
- [plate2.png](#)
- [plate3.png](#)
- [plate4.png](#)
- [plate5.png](#)
- [plate6.png](#)