

# Simultaneous Arterial and Venous Brain Infarctions in a Patient with COVID-19.

**Sonia Bermúdez**

Fundacion Santa Fe de Bogotá: Fundacion Santa Fe de Bogota

**Paula Forero** (✉ [paulaforero1129@gmail.com](mailto:paulaforero1129@gmail.com))

Fundacion Santa Fe de Bogotá: Fundacion Santa Fe de Bogota <https://orcid.org/0000-0001-7466-9805>

**Vanessa Salej**

Fundacion Santa Fe de Bogotá: Fundacion Santa Fe de Bogota

**Silvia González**

Fundacion Santa Fe de Bogotá: Fundacion Santa Fe de Bogota

**Jaime Toro**

Fundacion Santa Fe de Bogotá: Fundacion Santa Fe de Bogota

---

## Research Article

**Keywords:** stroke, vascular disease, COVID-19, arterial and venous infarct.

**Posted Date:** July 20th, 2021

**DOI:** <https://doi.org/10.21203/rs.3.rs-693846/v1>

**License:** © ⓘ This work is licensed under a Creative Commons Attribution 4.0 International License.

[Read Full License](#)

---

# Abstract

**Introduction:** Stroke is one of the manifestations of COVID-19 associated coagulopathy. Arterial infarcts are the most common presentation, however involvement of both arterial and venous irrigation is possible but rare. We report, what is, to our knowledge, the second case of concomitant arterial and venous brain thrombosis evidenced in magnetic resonance.

**Case presentation:** A 62-year-old man presented with acute weakness of the left hand and lack of coordination in the left arm. Nine days earlier, he was positive for SARS-CoV-2 RT-PCR. The brain images revealed two subacute infarcts, one corresponding to the territory of the right middle cerebral artery, and the other in the right frontal cortical vein.

**Conclusion:** The existence of both venous and arterial brain infarcts due to COVID-19 infection, has been previously reported once. Most of the cases of stroke are due to only arterial thrombosis, therefore this could be the starting point to start collecting data about simultaneous compromise in order to assess and compare outcomes, severity of the disease, among other variables.

## Introduction

Since the emergence of COVID-19, multiple clinical outcomes have been described, among them the development of a hypercoagulability state, also called COVID-19 associated coagulopathy (CAC) (1). This occurs due to a dysfunction in the three components of Virchow's Triad, which induce the formation of clots in either arterial or venous circulation, mostly manifesting as a ischemic stroke, pulmonary thromboembolism, or deep vein thrombosis (1). Involvement of both arterial and venous irrigation at any part of the body is possible but rare, in this setting we report, what is, to our knowledge, the second case of concomitant arterial and venous brain thrombosis, evidenced in a magnetic resonance angiography (MRA) of the brain, in a patient with COVID-19 diagnosis (2).

## Report Of A Case

A 62-year-old man presented to the emergency department of another institution with acute weakness of the left hand and lack of coordination of the left arm. He had tested positive for SARS-CoV-2 on a real time reverse transcription polymerase chain reaction assay (RT-PCR) of nasopharyngeal swab nine days earlier. The patient's medical history was relevant for a former smoker during 43 years and psoriasis treated with methotrexate. On the examination, the patient showed drooping of the commissure of the left lip, and predominantly distal weakness and dysdiadochokinesia of the left arm. An unenhanced head computed tomography (CT) and a head CT angiogram were performed. The CT results showed hypodense areas in the right parietal and occipital lobes reported as "in an arterial distribution", and increased signal at the right transverse and sigmoid dural sinuses, as well as the right internal jugular vein; findings which were confirmed by a filling defect in the CT angiogram. A diagnosis of dural sinus thrombosis was made and the patient was treated initially with low molecular weight heparin. Two days

later, anticoagulation was switched to apixaban at a dose of 5 milligrams (mg) twice daily. After discharge, the patient was referred to our consult for follow-up, where additional studies were indicated. Amongst the studies performed, the laboratory tests excluded disseminated intravascular coagulation, and other causes of hypercoagulability. Magnetic resonance (MR) imaging of the brain and MR angiography showed two subacute infarcts; one in the arterial territory of the right middle cerebral artery, with triangular shape and with cortical enhancement, and the other in the subcortical venous area, associated with thrombosis of the frontal cortical vein of the same side, and hemorrhage (Fig. 1). Also, partial recanalization of the transverse sinus and right jugular vein thrombosis was seen (Fig. 2).

## Discussion-conclusion

Activation of the coagulation system, producing hypercoagulability is one of the most known consequences of SARS-CoV-2 infection, besides pulmonary manifestations (3). This procoagulant state is due to several mechanisms that include the activation of both extrinsic and intrinsic pathways resulting in an increased factor VIII, fibrinogen, PAI-1, Von Willebrand factor, tissue factor expression, thrombin generation and platelet activation, and a decreased in antithrombin, protein C and thrombomodulin (4).

All of the above converge, triggering episodes like brain thrombosis. In the literature, both arterial and venous strokes have been described independently, presenting either as large artery occlusions, especially in the territory of middle cerebral artery (5), or as cerebral venous sinus obstruction, even in the context of an anticoagulated patient (6). Only one previous case described simultaneous involvement of M1 and M2 segments, and the right sigmoid sinus (2). Evidenced suggest that ischemic strokes due to COVID-19 have worse functional outcome and higher mortality (5), therefore a careful and meticulous diagnosis must be made in order to improve the morbidity and mortality of these patients.

This is a clear example of complicity among clinical and radiological findings. Neurological examination orientated towards a stroke, and images confirmed the diagnosis and revealed the severity and the territory of the disease.

However, there is not enough data about both arterial and venous brain thrombosis that elucidates the differences in characteristics, outcomes, severity of the disease, response to the treatment, among other variables, between arterial stroke alone and venous and arterial compromise.

Throughout time, more is known about COVID-19 manifestations, and more detailed information is under investigation. In this context, our case report could be the starting point of new hypothesis about the matter.

## Declarations

**Funding:** None.

**Conflicts of interest:** The authors declare that they have no conflict of interest.

**Ethics approval:** All procedures performed in studies involving human participants were in accordance with the ethical standards of the institutional and/or national research committee and with the 1964 Helsinki declaration and its later amendments or comparable ethical standards

**Consent to participate/for publication:** Consent to participate and consent for publication was obtained from all individual participants included in the study.

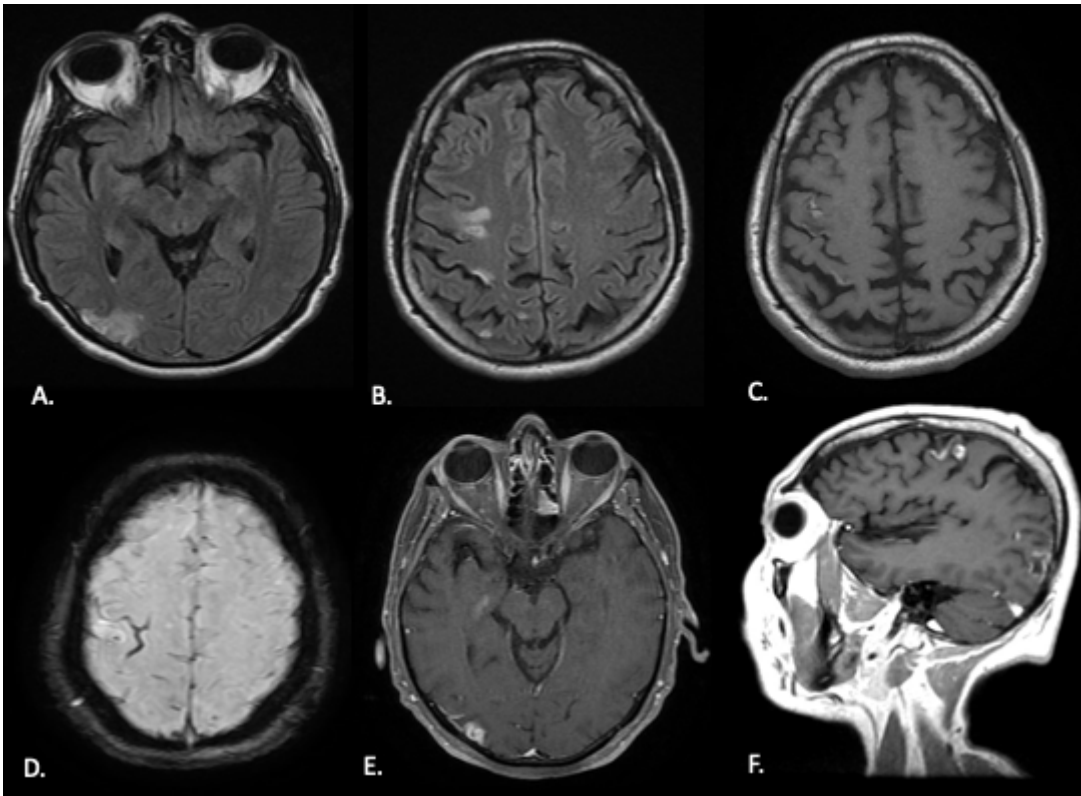
**Availability of data:** The data that support the findings of this study are available from the corresponding author upon reasonable request.

**Authors contributions:** Dr. Bermúdez, Dr. Forero, Dr. Salej, Dr. Gonzalez, Dr. Toro, contributed to the design and implementation of the research, to the analysis of the results and to the writing of the manuscript

## References

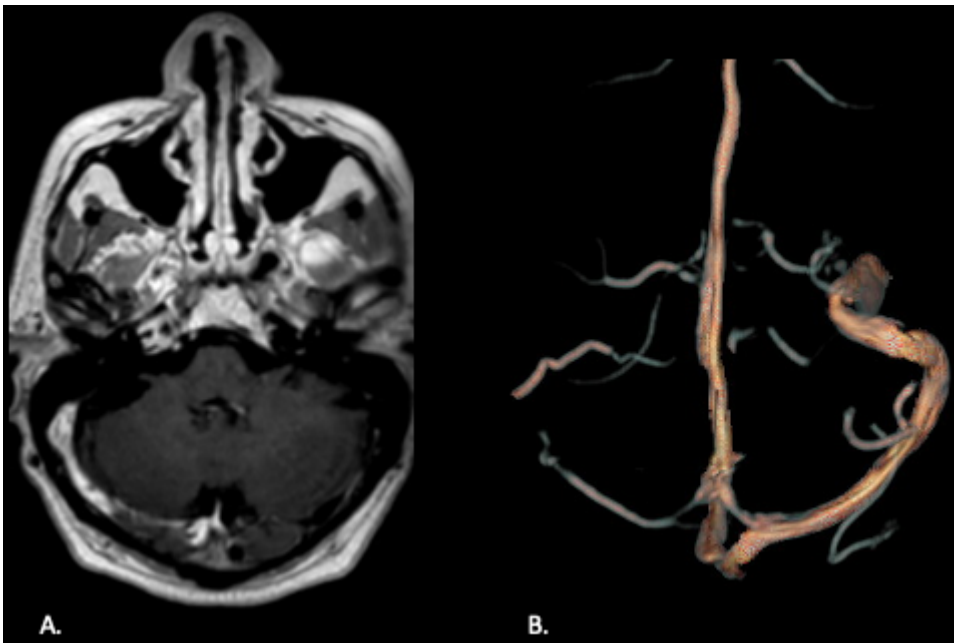
1. Singhania N, Saurabh Bansal , Divya , Nimmatoori P, Abutaleb , Ejaz A, et al. Current Overview on Hypercoagulability in COVID-19. *Am J Cardiovasc Drugs* [Internet]. 123AD;20:393–403. Available from: <https://doi.org/10.1007/s40256-020-00431-z>
2. Malentacchi M, Gned D, Angelino V, Demichelis S, Perboni A, Veltri A, et al. Concomitant brain arterial and venous thrombosis in a COVID-19 patient. *Eur J Neurol*. 2020;27(9):e38–9.
3. Bautista-Vargas M, Bonilla-Abadía F, Carlos , Cañas A. Potential role for tissue factor in the pathogenesis of hypercoagulability associated with in COVID-19. 2020 [cited 2021 Apr 26];50:479–83. Available from: <https://doi.org/10.1007/s11239-020-02172-x>
4. Mazzeffi MA, Chow JH, Tanaka K. COVID-19 Associated Hypercoagulability: Manifestations, Mechanisms, and Management. *Shock*. 2021;55(4):465–71.
5. Ntaios G, Michel P, Georgiopoulos G, Guo Y, Li W, Xiong J, et al. Characteristics and Outcomes in Patients with COVID-19 and Acute Ischemic Stroke: The Global COVID-19 Stroke Registry. *Stroke*. 2020;(September):254–8.
6. Kananeh MF, Thomas T, Sharma K, Herpich F, Urtecho J, Athar MK, et al. Arterial and venous strokes in the setting of COVID-19. *J Clin Neurosci*. 2020 Sep 1;79:60–6.

## Figures



**Figure 1**

A-B. MRI and FLAIR T2W images. Cortical and subcortical high T2 signal in the posterior right temporal lobe and high T2 signal subcortical in the frontal lobe. C. T1W axial view. High subcortical signal due to hemorrhage. D. SWI. Low signal in the thrombosed cortical vein. E. Axial T1W with Gadolinium. Cortical enhancement in arterial stroke. F. Sagittal T1W with Gadolinium. Enhancement of the frontal thrombosed vein and in the cortical temporal stroke.



**Figure 2**

A. MR with Gadolinium. Right transverse and sigmoid sinuses with partial enhancement due to subacute thrombosis. B. MR angiography with significant decrease of the venous flow in the right transverse and sigmoid sinuses due to partially recanalized thrombosis.

## Supplementary Files

This is a list of supplementary files associated with this preprint. Click to download.

- [checklist.docx](#)