

Efficiency of damage control orthopaedics strategy in the management of military ballistic limb trauma

Amri Khalil

Military teaching hospital of Tunis orthopaedic department

Tounsi Ahmed

Military teaching hospital of Tunis orthopaedic department

Oueslati Achraf (✉ oueslati.achraf@yahoo.com)

Military Teaching Hospital of Tunis <https://orcid.org/0000-0002-6090-7945>

Ben Salah Mouhamed

Charles Nicolle Hospital of Tunis

Dhahri Rim

Military teaching hospital of Tunis rheumatology department

Chourabi Chadia

Military teaching hospital of Tunis cardiology department

Nouisri Lotfi

Military teaching hospital of Tunis orthopaedic department

Research article

Keywords: Damage control, Ballistic trauma, Gunshot wound, Fracture, Limb

DOI: <https://doi.org/10.21203/rs.3.rs-68375/v1>

License:  This work is licensed under a Creative Commons Attribution 4.0 International License.

[Read Full License](#)

Abstract

Background:

In conflict areas, orthopaedic surgeon adopted this concept of damage control orthopaedic (DCO) to face limb fracture due to ballistic trauma because of the gravity of the hurts, the limitation of equipment, and precarious conditions of asepsis. They use external fixation as an initial treatment at the nearest health centre. And they delay the definitive treatment to be realized in better conditions. Our study aims to assess the outcome of damage control orthopaedic (DCO) strategy in military ballistic limb trauma according to the experience of the Military Hospital of Tunisia.

Materials and methods:

This study is a retrospective study on patients who were hospitalized for a limb ballistic fracture. It includes military patients treated urgently with primary external fixation at the nearest health centre. We adapted Gustilo classification to describe the wound opening, Winquist and Hansen classification to define the fracture comminution and Grading system for bone loss to evaluate the bone loss. Then all victims were evacuated secondary, to the Military hospital to receive the definitive treatments. The conversion to internal osteosynthesis had taken place according to some criteria. They were the absence of local sepsis, a haemoglobin level (> 10 g/dl), a serum protein level (> 50 g/l) and a negative or falling CRP kinetics. We studied the delay of conversion from external fixation to an internal osteosynthesis, bone healing time and complications.

Result:

Our study included 32 patients, all men, mean age was 31 years. The average follows up was 33,2 months. 88% of trauma concerned lower limb. The average delay for conversion from external fixation to internal osteosynthesis was 7,8 days. The bone union was achieved in 26 cases, with an average delay of 4.23 months. Observed general complications were anaemia, pulmonary embolism and rhabdomyolysis. Local complications were essentially sepsis on osteosynthesis material and pseudarthrosis. These complications were significantly associated with a type III of Gustilo skin opening, a type III and IV of the Winquist fracture comminutions, a type II and III of the Grading system for bone loss, and the delay for conversion from external fixation to internal osteosynthesis.

Conclusion:

DCO is a global strategy which involves all measures participating in the acceleration of the wound healing and fighting against the infection. These measures shorten the delay of conversion from external

fixation into an internal osteosynthesis, which constitutes a key parameter in the management of limb fracture due to ballistic trauma.

Introduction:

Damage control (DC) is not a medical concept; Navy (1) used it in the Second World War to describe all the temporary measures used in the fight to prevent a ship from sinking while pursuing its mission. The damage control surgical was developed to face the abdominal traumas with massive bleeding, to shorten the operating time and avoid the lethal set of three: Hypothermia, coagulopathy and acidosis (2). Thus, it opposes to early total care defined as an ideal and complete coverage of all the hurts from the first passage in the operating room. The DC was applied then to manage a polytraumatic having fractures of the long bones and pelvic and defined as Damage control orthopaedics (DCO). It is a relatively new concept (3) using external fixation because of the gravity of hurts, the limitation of equipment, and precarious conditions of asepsis in the conflict areas. The definitive synthesis is secondarily made as soon as possible, after regression of the inflammatory reaction and oedema.

Our study aims to assess the outcome of DCO strategy in military ballistic limb trauma according to the experience of the Military Hospital of Tunisia.

Materials And Methods:

This study is a retrospective, single-centre, descriptive study on patients who were hospitalized for a gunshot limb trauma at the Orthopaedic and Traumatology Department of the Main Military Hospital of Instruction in Tunis, for seven years from 2011 to 2017. It included military patients with ballistic fractures requiring emergency primary external fixation followed secondarily by conversion to internal synthesis, with a minimum follow-up of 12 months. Patients requiring exo-fixation as definitive treatment and patients lost to follow-up were excluded from this study.

All patients had urgent surgical management at the nearest health centre. It consists of soft tissue debridement, lavage and bone stabilization by external fixation (Fig. 1A, B, C). And the elaboration of lesion assessment. We adapted Gustilo classification to describe the wound opening, Winquist and Hansen classification to define the fracture comminution and Grading system for bone loss to evaluate the bone loss.

A first-line antibiotic therapy based on amoxicillin-clavulanic acid and aminoglycoside with tetanus prophylaxis were administered to all our patients.

Victims evacuation to the military hospital was carried out within 24 hours by land transport, except three victims, presenting vascular lesions, were transferred urgently by air transport.

At J2 post-traumatic, all patients had second-look surgery with debridement. Except for three patients with vascular lesions required immediate revision surgery after radiological exploration.

All the wounds were left open. Wound debridement was repeated once every two days until the wound was closed. Vacuum-Assisted Closure or VAC® Therapy was used to accelerate healing. This procedure was changed every two days following debridement. Hyperbaric oxygen therapy was performed in patients with Gustilo III wound opening.

Bacteriological samplings from deep soft tissues were carried out at each debridement. And, the antibiotic therapy was adapted to the results of the bacteriological examination. Victims underwent biological monitoring with an assessment, including Complete blood count (CBC), C reactive protein (CRP), serum protein, and prothrombin time (PT) at a rate of 1 day / 3.

The conversion to internal osteosynthesis had taken place at different times in our patients. The criteria for determining the time to conversion was the absence of local sepsis, an haemoglobin level (> 10 g/dl), a serum protein level (> 50 g/l) and a negative or falling CRP kinetics.

Our study protocol is resumed in the diagram (Fig. 2).

We noted all the reports of the examinations carried out at the time of the accident, throughout the hospitalization and postoperative follow-up. We studied the delay of conversion from external fixation to an internal osteosynthesis, bone healing time and complications.

The data were collected using a standardized analytical sheet, then entered using SPSS software. We calculated frequencies and relative frequencies (percentage) for the qualitative variables. We evaluated means and determined the range (extreme values = minimum and maximum) for the quantitative variables. The parametric Pearson correlation coefficient was used to study the relation between two quantitative variables. The link between two qualitative variables was evaluated by the chi-2 test and the Fisher test in case of chi-2 test invalidity. The association between a binary qualitative variable and a quantitative variable by Student's t-test. The significance level was set at $p \leq 0.05$ for all tests performed.

Results:

Our study included 32 patients. All of our patients were male. The mean age was 31 years (21–51 years). And nineteen patients had a smoking history.

Ballistic trauma mainly concerned the lower limb (88% of cases) and especially the femur, which represents 50% of lesions of the lower limbs.

The distribution of lesions according to the classification of Gustillo, Winquist and Hansen, and Grading system for bone loss are represented by (Table 1).

Table 1
Lesions distribution according to the classification of Gustillo, Winquist and Hansen, and Grading system for bone loss.

	Type I	Type II	Type III			Type IV
Gustillo	20	0	IIIa	IIIb	IIIc	
			9	0	3	
Winquist et Hansen	0	19	11			2
Grading system for bone loss	12	6	12			2

Three patient had vascular damage treated by an emergency revascularization procedure. And one patient had nerve damage (neurapraxia).

VAC Therapy was used in all our patients. Hyperbaric oxygen therapy was performed in twelve patients with Gustilo III wound opening. Bacteriological analysis isolated "Acinetobacter baumani" in twelve cases, and "Staphylococcus" in seven cases. In the rest of cases, the result was multi-bacterial.

The conversion from external fixation to an internal osteosynthesis took place in an average delay of 7.8 days (1 day – 15 days). Intramedullary nailing was the most used osteosynthesis material in 72% of cases. In the rest 28%, we use the osteosynthesis plate (Fig. 3A, B, C). A pin-site infection was observed in 3 cases, at the conversion surgery, requiring a systemic curettage of the pin sites before any material placement. And finally, the average hospital stay was 13.4 days (10 days – 18 days).

With an average follow up of 33,2 months (12 months – 72 months). The bone union was achieved in 26 cases, with an average delay of 4.23 months (3 months – 8 months) (Fig. 4A, B, C).

Most observed general complications were anaemia, pulmonary embolism and rhabdomyolysis. Anaemia (Hb < 10 g/dl) was observed in sixteen patients treated by transfusion. Pulmonary embolism was detected in three patients. And it has progressed well under anticoagulant treatment, without recourse to reanimation. Rhabdomyolysis was noticed in three patients without an impact on renal function and responded well to medical treatment. No fat embolism, no acute respiratory distress syndrome, and no multiple organ dysfunctions syndrome were observed in our series.

Local complications are essentially summarized in sepsis on osteosynthesis material and pseudarthrosis. Five patients suffered from sepsis on osteosynthesis material, and six patients have evolved into non-union treated by a spongy graft with internal synthesis.

The analysis of these complications objective a significant association between the sepsis on osteosynthesis material and four settings: smoking ($p = 0.005$), pin-site infection ($p = 0.009$), a Gustillo type III skin opening ($p = 0.03$) and the delay of conversion to internal osteosynthesis, as shown in Table 2.

Table 2
the association between the delay of conversion and sepsis on osteosynthesis material

	Presence of sepsis	Absence of sepsis	Significance
Average conversion delay	12.6 days	6.9 days	P = 0.003

The non-union rate was also associated with smoking ($p = 0.001$), a type III and IV of the Winquist fracture comminutions ($p = 0.013$), a type II and III of the Grading system for bone loss ($p = 0.016$). And the delay of conversion to internal osteosynthesis, as shown in table 3.

Table 3: The association between the delay of conversion and a non-union rate.

	Fracture non-union	Fracture union	Significance
Average conversion delay	12.1 days	6.8 days	P = 0.008

Discussion:

Our study objective that DCO strategy in the management of fractures due to ballistic trauma is efficient, with a consolidation rate $> 80\%$, and a relatively low percentage of general complications. These complications had minor severity, and they were easy to manage.

Local complications, mainly sepsis on osteosynthesis material and pseudarthrosis had relatively low rates. Our analyses showed that they were associated with several parameters. These parameters can be divided into non-modifiable risk factors such as the history of smoking, the wound opening, the fracture comminution, and bone loss. And a modifiable risk factors, mainly the delay of conversion from external fixation to internal osteosynthesis. The local complications rate was lower when this delay of conversion was shorter.

Our study is distinguished by strict inclusion and exclusion criteria. It was carried out in an institution that has good experience in the field of ballistics. Its protocol was interested not only at the results of the DCO strategy but also at the parameters which could affect this strategy. However, our study also has some limitations, mainly a selection bias due to its retrospective nature, and the relatively small number of patients.

The DCO is a relatively new concept (3), adopted in the management of ballistic limb trauma, appeared to solve the defects of an older approach, which consists of early stabilization of skeletal lesions called early total care.

The early total care was the principal strategy for management of polytrauma and war wounded in the 1980s and 1990. However, recent studies have shown that adoption of this strategy, in groups of patients with hemodynamic instability, is more associated with significant complications such as pulmonary embolism and acute respiratory distress syndrome, and multiple organ dysfunctions syndrome. And this

was exceptionally observed in the intra-medullary femur nailing (4). Studies have associated the occurrence of these complications with changes in pro-inflammatory markers (5). Indeed, the initial accident causes inflammatory and immunological reactions proportional to the severity of the trauma called "First hit" (6). This reaction is characterized by local and systemic proliferation of various pro-inflammatory mediators such as cytokines, complement, coagulation proteins and others. Besides, the prolonged duration of the surgery and the bleeding lead to another significant inflammatory and immunological reactions called "Second Hit". This second hit potentiates the effect of the first hit, and this may lead to a severe consequence in patients.

From these observations, a new strategy, based on minimizing the impact of the second hit by shortening the initial operating time and delaying the definitive treatment, was adapted to manage limb ballistic trauma. This strategy was called the DCO. Therefore, the treatment of long bone fractures of soldiers wounded on the battlefield is based on the temporary external fixation whose objective is controlling haemorrhage, restoring perfusion of the limb, debridement of necrotic soft tissue and ensuring bone stability. And without disturbing resuscitation care measures (7).

However, after hemodynamic stabilization, control of inflammatory phenomena and improvement of the local wound condition, this external fixation would be better converted into an internal osteosynthesis. Because even though the external fixation does not always allow an anatomical reduction, it is often associated with a high rate of pin-site infection and low-quality bone callus. Respet and al attempted to determine the time between the realization of external fixation and the onset of pin site infection. They found that pins bacteriological cultures were positive in 50% of the cases in 2 weeks and 67% in 4 weeks (8). These results were also confirmed later by Clasper and al (9). Also, Sigurdson and al (10, 11) experimented on rats. To study the quality of the bone callus after an osteotomy, initially treated with an external fixator and then followed by conversion to internal synthesis, with different delays. This conversion delay was seven days in A group, 14 days in B group, 30 days in C group and the control group D without conversion. All the groups had better consolidation than the control group, but only group A had a significant difference. Biomechanically, the rigidity and quality of the callus in group A were better than other groups.

These studies not only show the interest of the conversion from external fixation to internal osteosynthesis, but it also proves the interest of the delay of this conversion. The shorter it is, the better the quality of bone callus, and the lower the risk of pin site infection and sepsis. This result is consistent with our study, which objectified that the delay of conversion is a risk factor for both septic and non-union complications.

In our study, this conversion time was relatively short compared to other papers in the literature(12–15). It was possible by care aimed at accelerating deferent phases of the wound healing process and fighting infection. Indeed, VAC therapy allows a permanent elimination of exudates from the wound bed. Associated with repetitive debridement, it accelerated the inflammatory phase of the wound healing process. Hyperbaric oxygen therapy improves tissue oxygenation. Also, it enhances fibroblast and

collagen synthesis, neovascularization, and the closure of arterial-venous shunts (16), which shortened the time to granulation formation, especially in open wound fracture Gustillo III (17). As well, several studies had proven the effect of VAC therapy to accelerate granulation tissue formation (18–20). With normal haemoglobin and serum protein levels, they hasten the proliferative phase of the wound healing. Furthermore, in addition to adapted antibiotic therapy, hyperbaric oxygen therapy and VAC therapy had a confirmed role against infection.

Conclusion:

The DCO is a management strategy not only limited to shortening the initial management and delaying the definitive treatment, aimed to reduce severe or even fatal complications. But it is a global strategy which involves all measures participating in the acceleration of the wound healing and fighting against the infection. These measures shorten the delay of conversion from external fixation into an internal osteosynthesis, which constitutes a key parameter in the management of limb fracture due to ballistic trauma.

Abbreviations

DCO

Damage control orthopaedics

VAC

Vacuum-Assisted Closure

Declarations

- **Ethics approval and consent to participate**

Ethical approval for this study was obtained from Medical ethics and scientific editorial committee of the Tunis military hospital.

- **Consent for publication**

Not applicable

- **Availability of data and materials**

The datasets used and/or analysed during the current study are available from the corresponding author on reasonable request.

- **Competing interests**

The authors declare that they have no competing interests.

- **Funding**

There were no sources of support from any funding agency.

- **Acknowledgements**

Not applicable

- **Authors' contributions**

Study conception and design: AK, TA, OA

Acquisition of the data: CC, DR

Analysis and interpretation of the data: MBS, TA

Drafting of the manuscript: OA, AK

Critical revision: NL,

References

1. Herman S, Loeser CT. Damage Control—The Last Line of Shipboard Defense. *Nav Eng J*. 1992;104(1):63–79.
2. Rotondo MF, Schwab CW, McGonigal MD, Phillips GR 3rd, Fruchterman TM, Kauder DR, et al. « Damage control »: an approach for improved survival in exsanguinating penetrating abdominal injury. *The Journal of trauma*. 1993;35(3):375–82.
3. Burgess AR. Damage control orthopaedics. *LWW*; 2004.
4. Ecke H, Faupel L, Quoika P. Considerations on the time of surgery of femoral fractures. *Unfallchirurgie*. 1985;11(2):89.
5. Gebhard F, Huber-Lang M. Polytrauma—pathophysiology and management principles. *Langenbeck's archives of surgery*. 2008;393(6):825.
6. Scalea TM. Optimal timing of fracture fixation: have we learned anything in the past 20 years? *Journal of Trauma Acute Care Surgery*. 2008;65(2):253–60.
7. Mathieu L, Ouattara N, Poichotte A, Saint-Macari E, Barbier O, Rongi eras F, et al. Temporary and definitive external fixation of war injuries: use of a French dedicated fixator. *International orthopaedics*. 2014;38(8):1569–76.
8. Respet PJ, Kleinman PG, Meinhard BP. Pin tract infections: a canine model. *Journal of orthopaedic research*. 1987;5(4):600–3.
9. Clasper JC, Parker SJ, Simpson A, Watkins PE. Contamination of the medullary canal following pin-tract infection. *J Orthop Res*. 1999;17(6):947–52.

10. Sigurdson UE, Reikeras O, Utvag SE. External fixation compared to intramedullary nailing of tibial fractures in the rat. *Acta Orthop*. 2009;80(3):375–9.
11. Sigurdson U, Reikeras O, Utvag SE. The Effect of timing of conversion from external fixation to secondary intramedullary nailing in experimental tibial fractures. *J Orthop Res*. 2011;29(1):126–30.
12. Höntzsch D, Weller S, Engels C, Kaiserauer S. Change in the procedure from external fixator to intramedullary nailing osteosynthesis of the femur and tibia. *Aktuelle Traumatologie*. 1993;23:21.
13. Winkler H, Hochstein P, Pfrengle S, Wentzensen A. Change in procedure to reamed intramedullary nail in diaphyseal femoral fractures after stabilization with external fixator. *Zentralbl Chir*. 1998;123(11):1239–46.
14. Iannacone WM, Taffet R, DeLong WG Jr, Born CT, Dalsey RM, Deutsch LS. Early exchange intramedullary nailing of distal femoral fractures with vascular injury initially stabilized with external fixation. *The Journal of trauma*. 1994;37(3):446–51.
15. Mody RM, Zapor M, Hartzell JD, Robben PM, Waterman P, Wood-Morris R, et al. Infectious complications of damage control orthopedics in war trauma. *Journal of Trauma Acute Care Surgery*. 2009;67(4):758–61.
16. Zamboni WA, Browder LK, Martinez J. Hyperbaric oxygen and wound healing. *Clin Plast Surg*. 2003;30(1):67–75.
17. Roje Z, Roje Ž, Eterović D, Družijanić N, Petričević A, Roje T, et al. Influence of adjuvant hyperbaric oxygen therapy on short-term complications during surgical reconstruction of upper and lower extremity war injuries: retrospective cohort study. *Croatian Med J*. 2008;49(2):224.
18. Armstrong DG, Lavery LA, Consortium DFS. Negative pressure wound therapy after partial diabetic foot amputation: a multicentre, randomised controlled trial. *The Lancet*. 2005;366(9498):1704–10.
19. DeFranzo AJ, Argenta LC, Marks MW, Molnar JA, David LR, Webb LX, et al. The use of vacuum-assisted closure therapy for the treatment of lower-extremity wounds with exposed bone. *Plastic reconstructive surgery*. 2001;108(5):1184–91.
20. Saxena V, Hwang C-W, Huang S, Eichbaum Q, Ingber D, Orgill DP. Vacuum-assisted closure: microdeformations of wounds and cell proliferation. *Plastic reconstructive surgery*. 2004;114(5):1086–96.

Figures

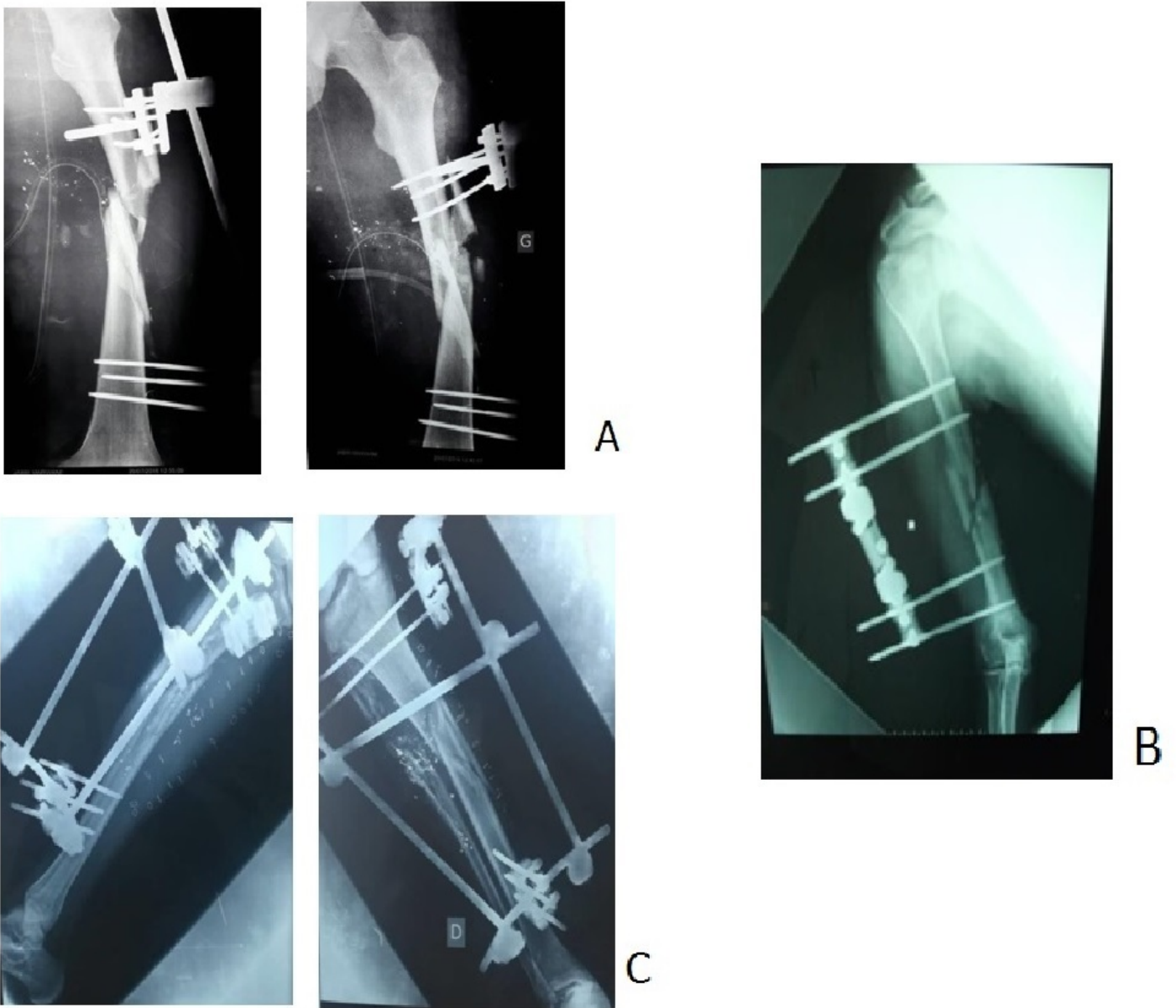


Figure 1

- A: - X-ray of external fixation of femur fracture. - B: - X-ray of external fixation of a humeral fracture. - C: - X-ray of external fixation of tibial fracture.

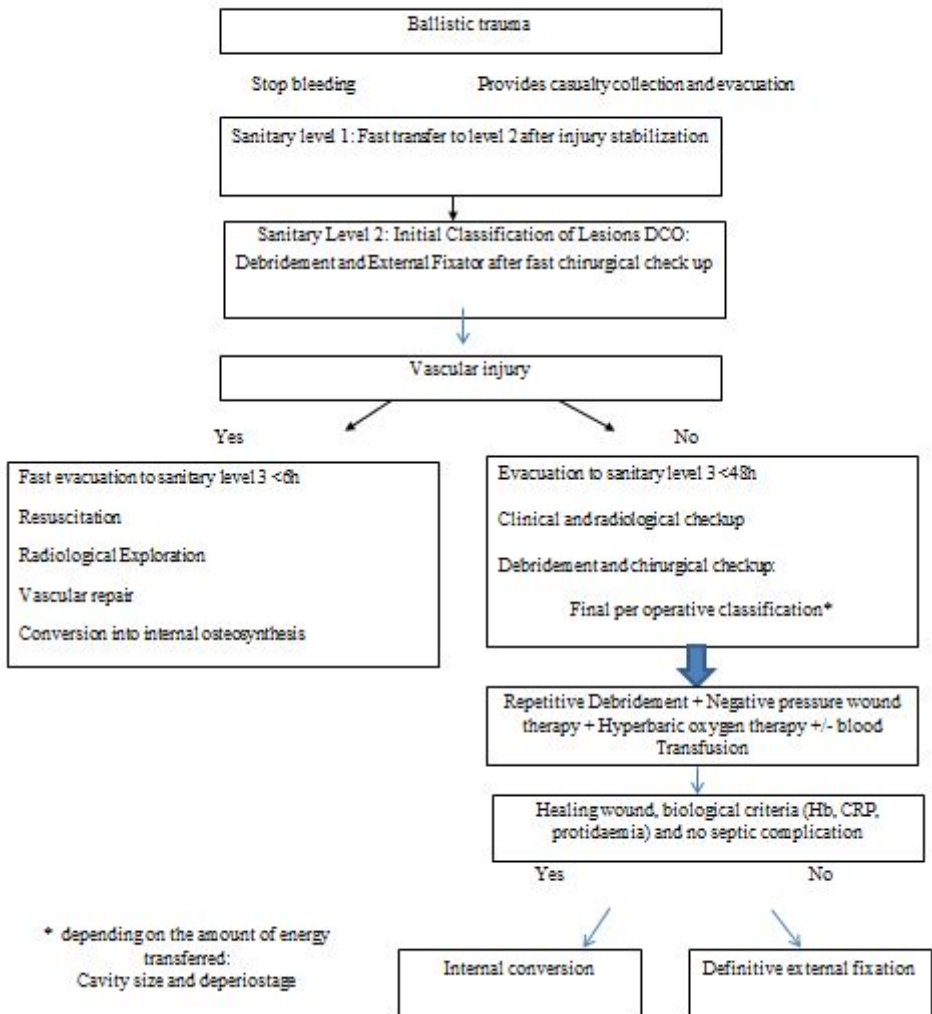


Figure 2

- A: - X-ray image for the internal conversion of a femur fracture. - B: - X-ray after internal conversion of a humeral fracture. - C: - X-ray after internal conversion of a tibial fracture

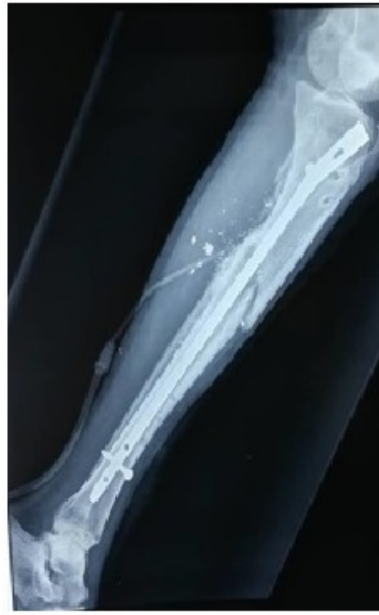
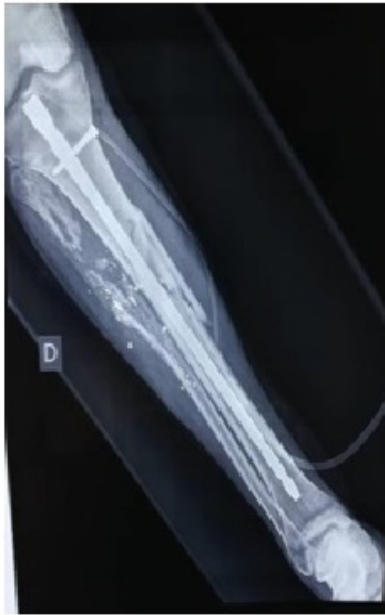
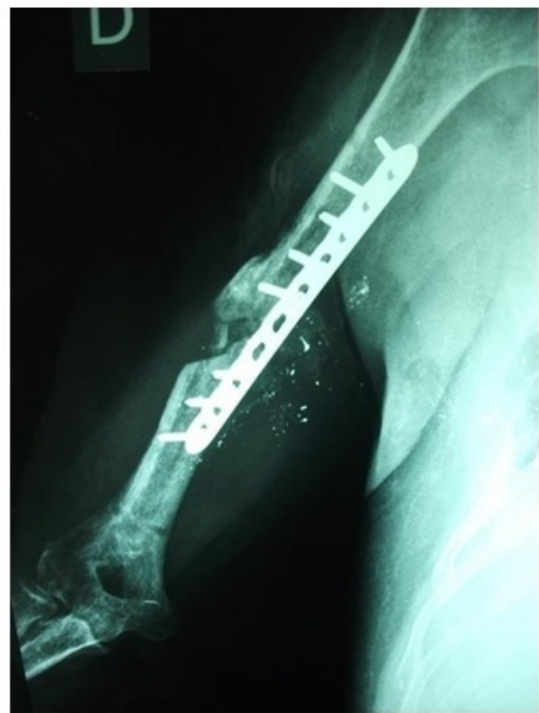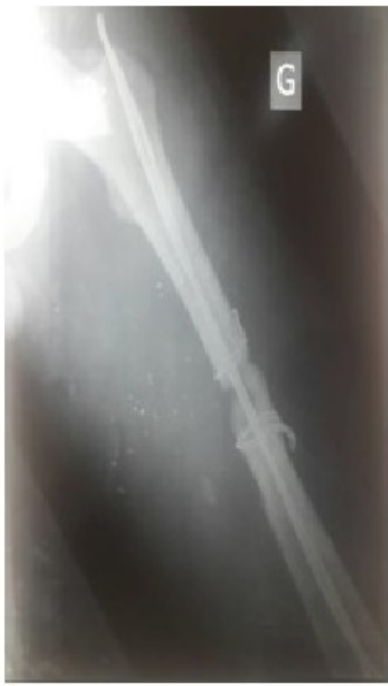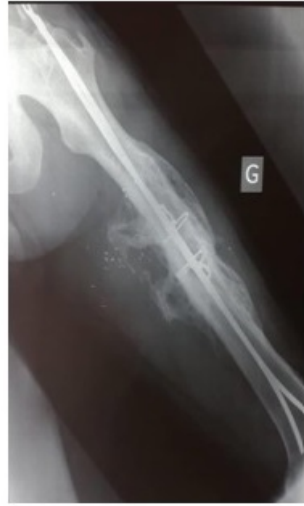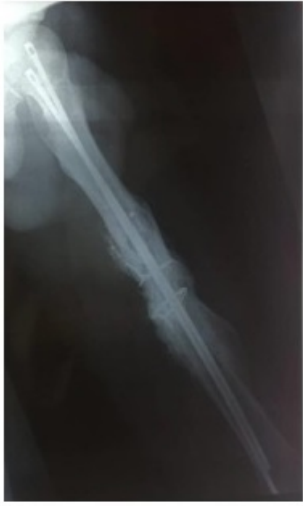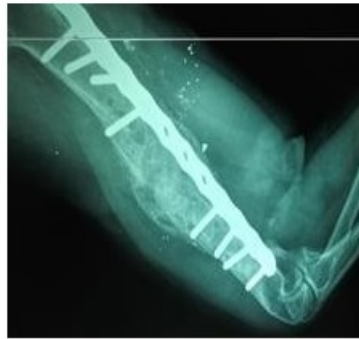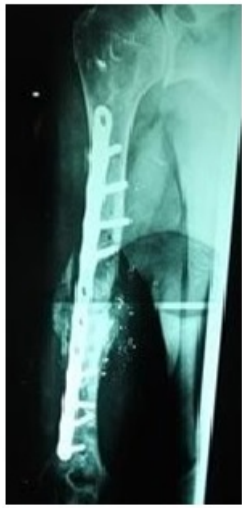Figure 3

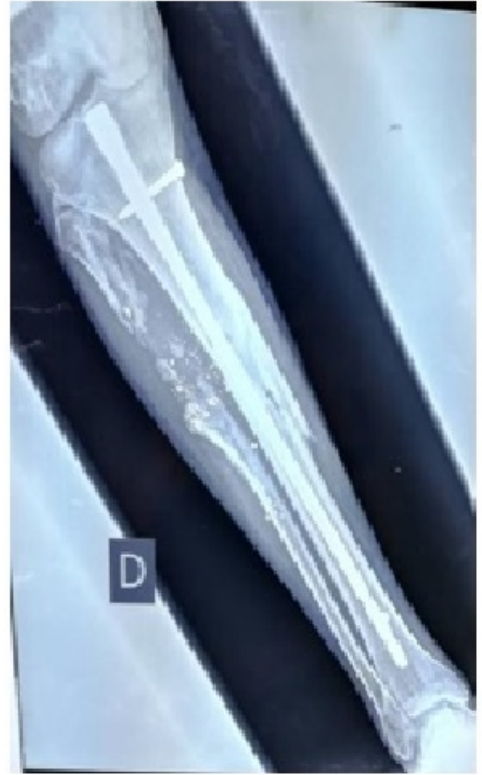- A: - X-ray image of a femur fracture after the bone union. - B: - X-ray of a humeral fracture after the bone union. - C: - X-ray of a tibial fracture after the bone union



A



B



C

Figure 4

Fig4