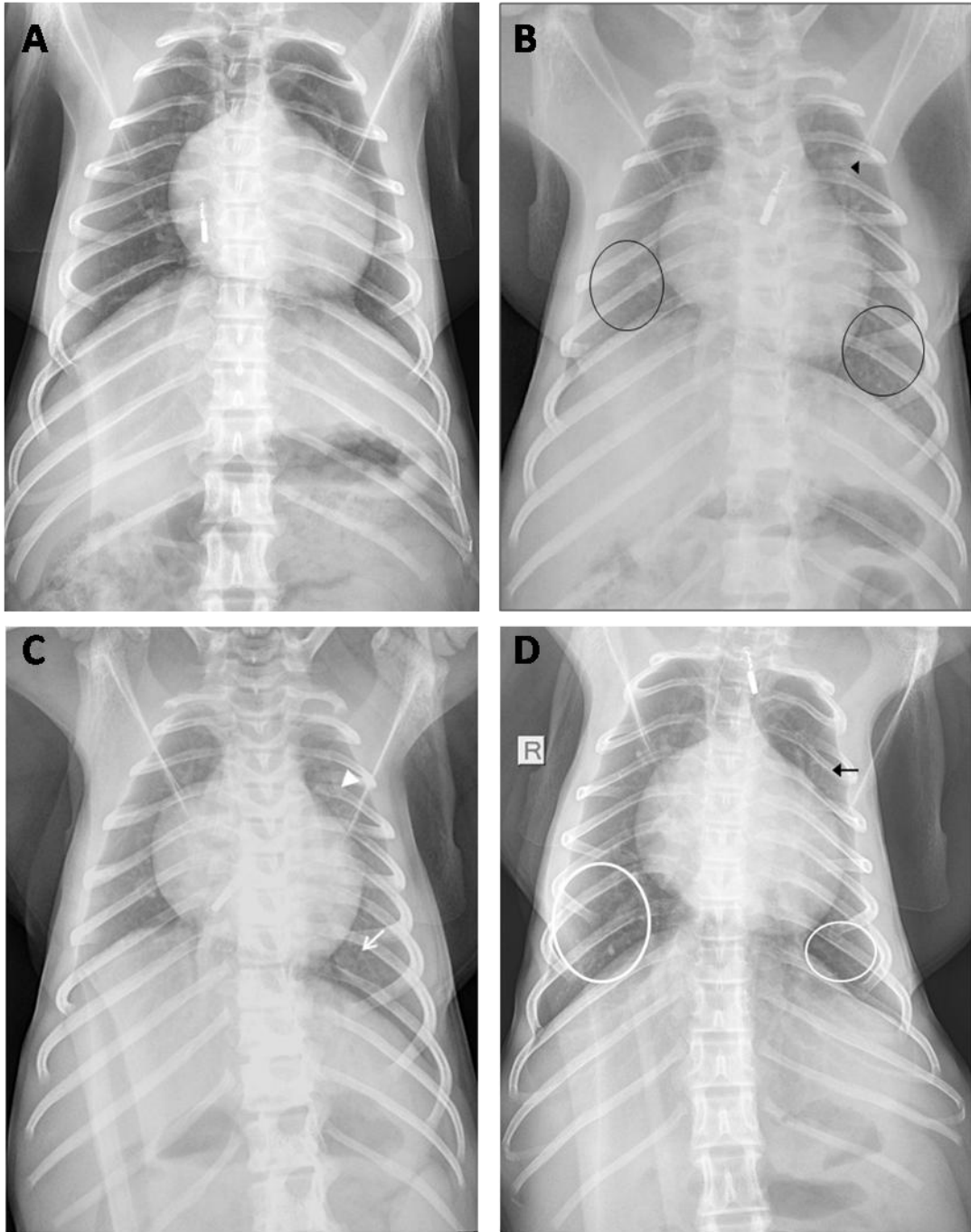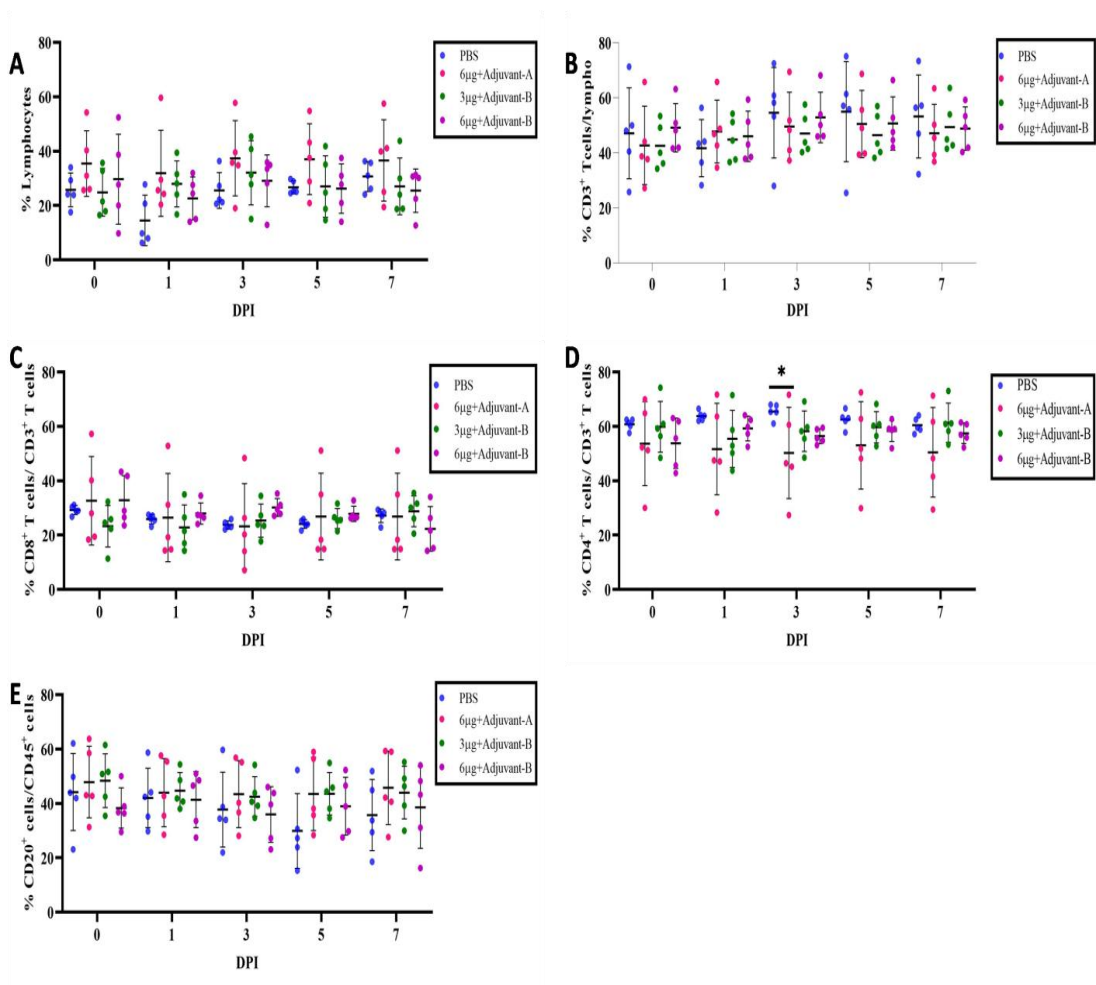


Extended Data Figure. 1 | Anteroposterior (AP) chest radiographs obtained from different animals. (A) Normal chest X-ray. (B) Infiltrate in left upper lobe (black arrowhead), bronchopneumonia in lower lobes of both the lungs (black circles). (C) Infiltrate in left upper lobe (white arrowhead) and lobar consolidation in left lower lobe (white arrow) (D) Lobar consolidation in left upper lobe (black arrow) with bilateral lower lobe bronchopneumonia (white circles) where 'R' represents the position indicator for the right side of the animal.



Extended Data Figure. 2| Lymphocyte profile in animals of each group at 0,1,3,5 and 7 DPI. (A) Lymphocyte percentage. (B) Percentage of CD3⁺ T cells/lymphocytes. (C) Percentage of CD8⁺ T cells/ CD3⁺ T cells, (D) Percentage of CD4⁺ T cells/ CD3⁺ T cells. (E) Percentage of CD20⁺ T cells/ CD45⁺ cells.