

Coinfection with SARS-CoV-2 and dengue virus: a case report

Prasetyo Hariadi

Tangerang District Hospital

Dewi Lokida

Tangerang District Hospital; Indonesia Research Partnership on Infectious Disease (INA-RESPOND)

Adhella M Naysilla

Indonesia Research Partnership on Infectious Disease (INA-RESPOND)

Nurhayati Lukman

Indonesia Research Partnership on Infectious Disease (INA-RESPOND)

Herman Kosasih (✉ hkosasih@ina-respond.net)

Indonesia Research Partnership on Infectious Disease (INA-RESPOND) <https://orcid.org/0000-0003-1095-3422>

Yan Mardian

Indonesia Research Partnership on Infectious Disease (INA-RESPOND)

Gestana Andru

Tangerang District Hospital

Inggar Pertiwi

Tangerang District Hospital

Retna I Sugiyono

Indonesia Research Partnership on Infectious Disease (INA-RESPOND)

Antonius A Pradana

Indonesia Research Partnership on Infectious Disease (INA-RESPOND)

Gustiani Salim

Indonesia Research Partnership on Infectious Disease (INA-RESPOND)

Deni P Butar-butar

Indonesia Research Partnership on Infectious Disease (INA-RESPOND)

Chuen-Yen Lau

National Institutes of Health, Bethesda

Muhammad Karyana

Indonesia Research Partnership on Infectious Disease (INA-RESPOND); National Institute of Health Research and Development (NIHRD), Ministry of Health

Keywords: coinfection, dengue virus, SARS-CoV-2

DOI: <https://doi.org/10.21203/rs.3.rs-63867/v1>

License:  This work is licensed under a Creative Commons Attribution 4.0 International License.

[Read Full License](#)

Abstract

Background: Since its emergence in China, SARS-CoV-2 has infected more than 15.5 million people worldwide, including in regions where dengue virus (DENV) is hyperendemic such as Latin America and Southeast Asia, including Indonesia. Hence, anticipation for simultaneous infection by DENV and SARS-CoV-2 has been raised.

Case presentation: We describe a 68-year-old woman with diabetes mellitus type II who was admitted to the Tangerang District Hospital on 14 April 2020. She lived in a neighborhood where a few people were contracting dengue fever. She presented with five days of fever, malaise, anorexia, nausea, myalgia, and arthralgia. Hematology results revealed anemia, thrombocytopenia, normal leukocyte count, increased neutrophil proportion, and decreased lymphocyte proportion and absolute lymphocyte. Her chest X-ray showed right pericardial infiltrates. Although dengue was clinically suspected, as she met COVID-19 screening criteria, she was also tested for SARS-CoV-2 infection. The patient was treated with ceftriaxone, paracetamol, azithromycin, oseltamivir, and chloroquine. She was clinically improved four days later and was discharged from the hospital on 25 April 2020 after SARS-CoV-2 rRT-PCR was negative on two consecutive samples. Dengue was diagnosed retrospectively based on sero-conversion of dengue IgM and a very high dengue IgG index (Focus Diagnostics®, ELISA), and sero-conversion of dengue IgM and positive IgG (PanBio® Dengue duo cassette), which was equivalent to high hemagglutination inhibition antibody titer found in secondary dengue infection.

Conclusion: The overlapping clinical presentations of COVID-19 and dengue; limited diagnostic capacity of laboratories in resource constrained settings; and complexities of interpreting results make identification of COVID-19 in the dengue endemic setting challenging. Clinicians in endemic areas must maintain a high index of suspicion for the possibility of COVID-19 coinfection with DENV and other tropical pathogens.

Background

Since its emergence at the end of December 2019 in Wuhan, China, severe acute respiratory syndrome coronavirus 2 (SARS-CoV-2) has infected more than 15.5 million people worldwide, including in regions where dengue virus (DENV) is hyperendemic such as Southeast Asia and Latin America.¹ Anticipation for simultaneous infection by DENV and SARS-CoV-2 has been raised.²⁻⁵ Indonesia is highly affected by both viruses. Since Indonesia's first reported coronavirus disease 2019 (COVID-19) case in early March 2020, the number of confirmed cases has risen to >97,000 with an estimated 5% mortality rate.¹ Dengue, despite having a lower mortality rate (0.6%) than COVID-19, caused >70,000 cases from January to July 2020.⁶ As no report on coinfection with SARS-CoV-2 and DENV has been published, we would like to describe the first identified coinfection between these two viruses in Indonesia.

Case Presentation

A 68-year-old woman with chronic diabetes mellitus (DM) type II was referred to Tangerang District Hospital on 14 April 2020 by a general practitioner with a clinical diagnosis of dengue fever. She presented with five days of fever, malaise, anorexia, nausea, myalgia, and arthralgia. Cough and diarrhea had appeared one day later. She reported living in a neighborhood where a few people were contracting dengue fever, and participating in a religious meeting four days prior to symptom onset. On exam, vital signs were within normal limits, except for mildly elevated blood pressure (150/90 mmHg). No rash or bleeding was observed. Chest X-ray showed right pericardial infiltrates, suggesting bronchopneumonia (Figure 1). Hematology results revealed anemia (Hemoglobin 10.9 mg/dL), thrombocytopenia (99,000/mm³), normal leukocyte count (8,000/mm³), increased neutrophil proportion (78%), decreased lymphocyte proportion (13%), and absolute lymphocyte (1040/mm³). Her random blood sugar, ureum and creatinine levels were normal (110 mg/dL, 24 mg/dL, and 0.8 mg/dL, respectively). She was treated regularly with glibenclamide, and she had no history of heart or kidney disease.

The emergency room clinician agreed with the diagnosis of dengue. As she met the screening criteria for COVID-19 (fever, pericardial infiltrates on chest X-ray and group exposure 4 days before onset of illness), internal medicine and pulmonology were consulted. A serologic rapid diagnostic test (RDT) was ordered and returned faintly positive for IgM and IgG antibody combined (Wondfo®). The patient was admitted to the isolation room for supportive care. Pending SARS-CoV-2 real-time reverse transcription polymerase chain reaction (rRT-PCR) results⁷ from mixed nasopharyngeal and oropharyngeal specimens, the patient was empirically treated with Ceftriaxone and paracetamol. Azithromycin, Oseltamivir, and Chloroquine were added after specimens collected on 15 April 2020 were confirmed positive for SARS-CoV-2 (cycle threshold (Ct) value 29.9 and 31.1 for nucleocapsid 1 (N1) and nucleocapsid 2 (N2) genes) two days later. As COVID-19 had been confirmed, laboratory work up for dengue (DENV IgM/IgG RDT) was not performed. The patient clinically improved (resolution of fever, improvement of constitutional symptoms and normal platelet count (189,000/mm³) by 18 April 2020. SARS-CoV-2 rRT-PCR was negative on two consecutive tests 24 hours apart (21 and 22 April 2020). She was discharged from the hospital on 25 April 2020.

Retrospective serology for SARS-CoV-2 IgM and IgG antibodies using RDT (SD Biosensor®) was performed in addition to rRT-PCR testing. The IgM and IgG bands appeared faint in acute serum (day 6 of illness) and were strongly positive in the convalescent serum (day 11). Dengue diagnosis tests were also performed retrospectively. The diagnosis of DENV infection was based on seroconversion of IgM (index values of 0.85 in acute to 2.03 in convalescent sera) by enzyme-linked immunosorbent assay (ELISA) and by rapid test (from negative to positive, PanBio ®Dengue duo cassette) and the positive IgG in acute and convalescent sera by rapid test (PanBio ®Dengue duo cassette). This was confirmed by high index (11.2) values of IgG ELISA (Focus Diagnostics®). The IgG detection threshold for this rapid immunochromatography test is set at a high IgG titer, equivalent to hemagglutination inhibition titer of ≥ 1280 . Thus, positive rapid IgG test in both acute and convalescent sera was considered indicative of acute secondary dengue infection. DENV non-structural protein 1 (NS1) (PanBio ®Dengue early) and rRT-PCR from acute serum were negative. Clinical course and laboratory results are shown in Figure 2.

Discussion And Conclusion

Despite having dual DENV and SARS-CoV-2 infections on the backdrop of DM type II, this patient's clinical manifestations were moderate. This may be attributable to well-controlled blood sugar, the absence of DM related complications such as heart or kidney diseases,⁸ and possibly the rapid clearance of DENV in blood during recurrent infection. In recurrent DENV infection, IgG antibodies rise quickly during acute illness, often in the absence or with low titers of IgM antibodies.⁹ This may explain the negative DENV rRT-PCR and NS1. It has been reported that DENV in secondary infection peaks on day 2 of illness and then decreases rapidly to undetectable on day 5.¹⁰ Similarly, NS1 in secondary infection disappears earlier than in primary infection and is often undetected.¹⁰⁻¹² Our patient's conversion to SARS-CoV-2 rRT-PCR negativity by day 12 of illness is within the range expected.^{13,14} However, we do not know precisely when SARS-CoV-2 cleared as we did not have swabs between day seven (positive) and day 12 (negative).

The overlapping clinical presentations of COVID-19, dengue and typhoid fever; limited diagnostic capacity of laboratories in resource constrained settings; and complexities of interpreting results make identification of COVID-19 in the dengue endemic setting challenging. This is reflected by the diagnoses made by the general practitioner and emergency room physician, both of whom suspected dengue based on clinical presentation and ongoing local transmission of DENV. Subsequently, the pulmonologist suspected COVID-19 despite the existing DENV clinical diagnosis in light of the consistent respiratory, laboratory and imaging findings. It was then discovered that the patient had contact with a confirmed COVID-19 case 4 days prior to emergence of symptoms. Despite reports of low sensitivity of the COVID-19 RDT during acute illness,¹⁵ its use in this patient was vital as missing this test would exclude her from being managed as a COVID-19 patient. Difficulty in distinguishing COVID-19 and dengue, particularly when diagnostics perform suboptimally, has been reported in other countries including Singapore¹⁶ and Thailand.¹⁷ Positive dengue infection should not prevent evaluation for COVID-19, particularly when patients have a history of contact with suspected or confirmed COVID-19 cases.

At this time, the standard of care for both dengue and COVID-19 in Indonesia is supportive care. Thus, clinical management of the patient would not have been altered by knowledge of the diagnosis. However, delayed diagnosis of COVID-19 presents epidemiological risks, particularly the possibility of transmission to hospital staff and other patients. This patient's household contacts were tested for SARS-CoV-2 IgM and IgG using RDT and found to be negative. Ideally appropriate isolation precautions would be employed at presentation for patients at risk for COVID-19. Management strategies specifically for resource limited settings in which health care systems are already overburdened are needed. For example, point-of-care RDTs will be useful for triaging patients. Preventive and therapeutic approaches for both DENV and COVID-19 will also be helpful for alleviating risks to patients as well as burden on the healthcare system. In the meantime, clinicians in endemic areas must maintain a high index of suspicion for the possibility of COVID-19 coinfection with DENV and other tropical pathogens.

Abbreviations

COVID-19: coronavirus disease 2019; Ct: cycle threshold; DENV: dengue virus; DM: diabetes mellitus; ELISA: enzyme-linked immunosorbent assay; N1: nucleocapsid 1; N2: nucleocapsid 2; NS1: non-structural protein 1; RDT: rapid diagnostic test; rRT-PCR: real-time reverse transcription polymerase chain reaction; SARS-CoV-2: severe acute respiratory syndrome coronavirus 2.

Declarations

Acknowledgments

We would like to thank Indonesia Research Partnership on Infectious Disease (INA-RESPOND) for the support. Thank you for the laboratory team (Wahyu Nawang Wulan, Yuanita Jayadi, and Rizki Amalia Sari) at Tangerang District Hospital, Tangerang, Indonesia. We also would like to thank Aly Diana for technical assistance of the manuscript.

Authors' contributions

Conceptualization and Methodology, P.H, D.L, A.M.N, N.L., H.K., C.Y.L. and M.K.; Software, Y.M and A.A.P.; Laboratory Work, D.L., N.H., G.S. and D.P.B.; Formal Analysis, P.H, D.L. and H.K.; Investigation and Data Curation, P.H., D.L., A.M.N, G.A. and I.P; Writing – Original Draft Preparation, H.K., A.M.N, and C.Y.; Writing – Review & Editing, all authors; Visualization, Y.M., H.K., R.I.S. and A.A.P.; Supervision, P.H., D.L., H.K. and M.K.

Funding

There are no funding sources to declare.

Availability of data and materials

The data used during the current study are available from corresponding author on reasonable request.

Ethics approval and consent to participate

Not applicable.

Consent for publication

The patient provided written informed for her personal or clinical details with any identifying images to be published in this study.

Competing interests

The authors declare that they have no known competing financial interests or personal relationships that could have appeared to influence the work reported in this paper.

References

1. Situational Report - 188. 2020. <https://www.who.int/emergencies/diseases/novel-coronavirus-2019/situation-reports> (accessed 26th July 2020).
2. Saavedra-Velasco M, Chiara-Chilet C, Pichardo-Rodriguez R, Grandez-Urbina A, Inga-Berrosipi F. [Coinfection between dengue and covid-19: need for approach in endemic zones.]. *Rev Fac Cien Med Univ Nac Cordoba* 2020; 77(1): 52-4.
3. Lam LTM, Chua YX, Tan DHY. Roles and challenges of primary care physicians facing a dual outbreak of COVID-19 and dengue in Singapore. *Fam Pract* 2020.
4. Wu D, Lu J, Liu Q, Ma X, He W. To alert coinfection of COVID-19 and dengue virus in developing countries in the dengue-endemic area. *Infect Control Hosp Epidemiol* 2020: 1.
5. Lorenz C, Azevedo TS, Chiaravalloti-Neto F. COVID-19 and dengue fever: A dangerous combination for the health system in Brazil. *Travel Med Infect Dis* 2020: 101659.
6. Kementerian Kesehatan Republik Indonesia. Hingga Juli, Kasus DBD di Indonesia Capai 71 Ribu. *Kemkes Republik Indonesia* (9th July 2020). <https://www.kemkes.go.id/article/view/20070900004/hingga-juli-kasus-dbd-di-indonesia-capai-71-ribu.html> (accessed 26th July 2020).
7. US-CDC. Real-Time RT-PCR Panel for Detection 2019-Novel Coronavirus. 2020.
8. Zhu L, She ZG, Cheng X, et al. Association of Blood Glucose Control and Outcomes in Patients with COVID-19 and Pre-existing Type 2 Diabetes. *Cell Metab* 2020.
9. Kosasih H, Alisjahbana B, Nurhayati, et al. The Epidemiology, Virology and Clinical Findings of Dengue Virus Infections in a Cohort of Indonesian Adults in Western Java. *PLoS Negl Trop Dis* 2016; 10(2): e0004390.
10. Muller DA, Depelsenaire AC, Young PR. Clinical and Laboratory Diagnosis of Dengue Virus Infection. *J Infect Dis* 2017; 215(suppl_2): S89-S95.
11. Tricou V, Minh NN, Farrar J, Tran HT, Simmons CP. Kinetics of viremia and NS1 antigenemia are shaped by immune status and virus serotype in adults with dengue. *PLoS Negl Trop Dis* 2011; 5(9): e1309.
12. Kosasih H, Alisjahbana B, Widjaja S, et al. The diagnostic and prognostic value of dengue non-structural 1 antigen detection in a hyper-endemic region in Indonesia. *PLoS One* 2013; 8(11): e80891.
13. Xiao AT, Tong YX, Zhang S. Profile of RT-PCR for SARS-CoV-2: a preliminary study from 56 COVID-19 patients. *Clin Infect Dis* 2020.
14. Sethuraman N, Jeremiah SS, Ryo A. Interpreting Diagnostic Tests for SARS-CoV-2. *JAMA* 2020.
15. Cassaniti I, Novazzi F, Giardina F, et al. Performance of VivaDiag COVID-19 IgM/IgG Rapid Test is inadequate for diagnosis of COVID-19 in acute patients referring to emergency room department. *J Med Virol* 2020.

16. Yan G, Lee CK, Lam LTM, et al. Covert COVID-19 and false-positive dengue serology in Singapore. *Lancet Infect Dis* 2020; 20(5): 536.
17. Joob B, Wiwanitkit V. COVID-19 can present with a rash and be mistaken for dengue. *J Am Acad Dermatol* 2020; 82(5): e177.

Figures

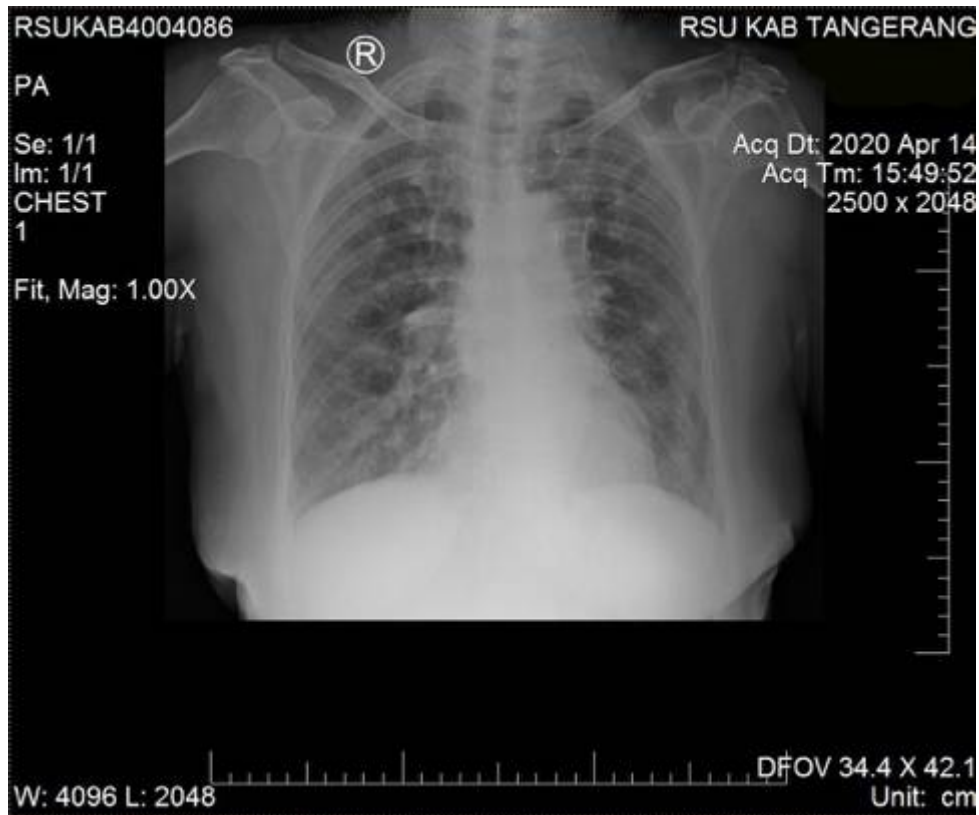


Figure 1

Chest X-ray on day of hospitalization. Pericardial infiltrates suggest bronchopneumonia

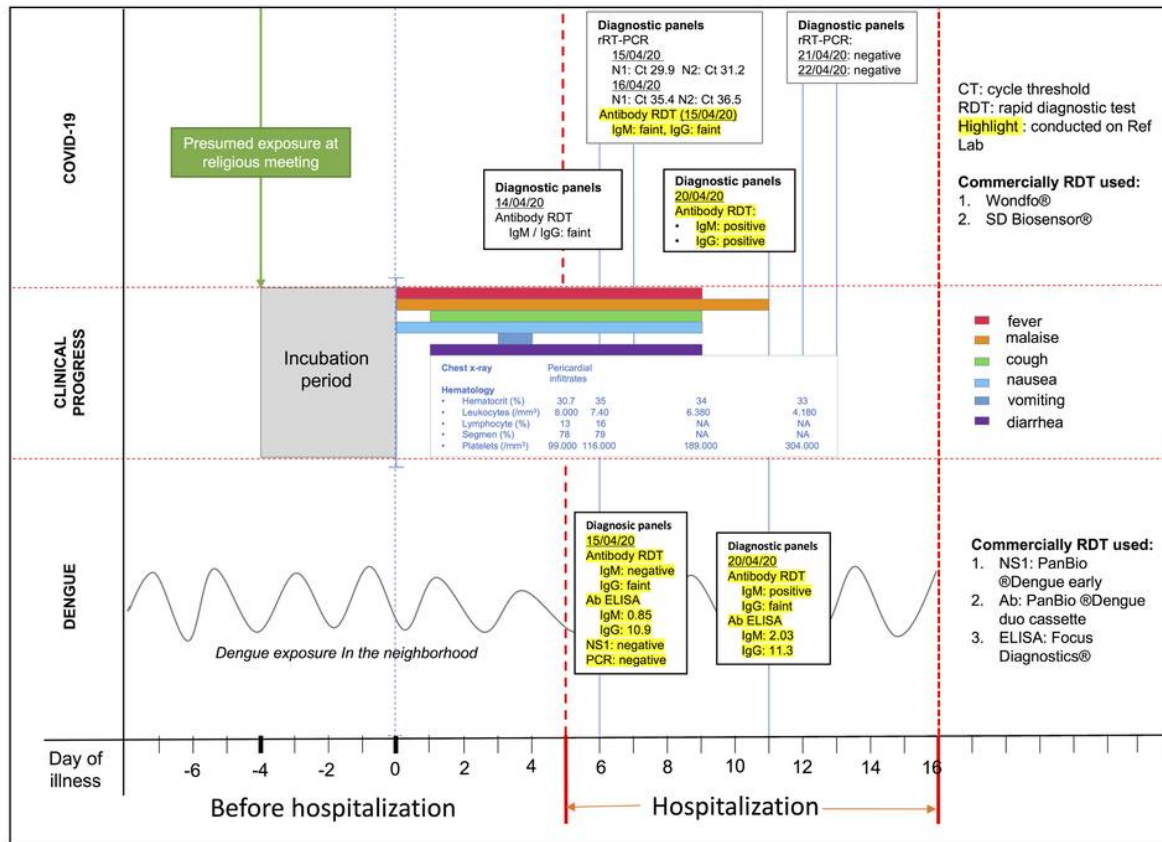


Figure 2

Time course of clinical and laboratory findings. COVID-19 specific data is shown at the top, dengue specific data is shown at the bottom. Procedures highlighted in yellow were performed retrospectively for research