

Encapsulated Papillary Carcinoma of The Breast: A Case Series

Zhaorui Wang

The first Affiliated Hospital of Anhui Medical University

Jingjing Wang

The First Affiliated Hospital of Anhui Medical University

Yubo Pan

The First Affiliated Hospital of Anhui Medical University

Jing Pei (✉ peijing@ahmu.edu.cn)

The first Affiliated Hospital of Anhui Medical University <https://orcid.org/0000-0003-2496-3795>

Research

Keywords: encapsulated papillary carcinoma, breast cancer, prognosis, therapy

Posted Date: June 14th, 2021

DOI: <https://doi.org/10.21203/rs.3.rs-607865/v1>

License: © ⓘ This work is licensed under a Creative Commons Attribution 4.0 International License.

[Read Full License](#)

Abstract

Introduction: Encapsulated papillary carcinoma (EPC) of the breast is a rare type of breast cancer with excellent prognosis. It is usually considered a variant of ductal carcinoma in situ (DCIS). However, no consensus on EPC treatment and management has been achieved. We provide some data from our clinical centers to help better manage this disease.

Methods: We performed a retrospective analysis of patients diagnosed with EPC from March 2015 to December 2019 at The First Affiliated Hospital of Anhui Medical University. Demographic information, tumor details, immunohistochemical markers, clinical data, stage of the disease, treatment modalities, and oncological outcomes were collected.

Results: Eleven cases were included in this retrospective study: three cases had pure EPC, six cases had EPC associated with DCIS, and two cases had EPC associated with invasive cancer. Among the patients, two had lymph node metastases. The mean age of female patients at diagnosis was 53.6 years. The one male patient was 48 years old. The mean tumor size was 2.4 cm. Myoepithelial cell layers were completely absent in all cases. Ten patients were estrogen receptor and progesterone receptor positive and human epidermal growth factor receptor-2 negative. Nine patients underwent mastectomy, and two underwent breast-conserving surgery.

Conclusion: Adequate local therapy results in excellent prognosis. Radiation therapy should be offered to patients with EPC who undergo breast-conserving surgery. Immunohistochemistry is necessary in diagnosing EPC and excluding other papillary lesions. Excisional biopsy should be performed to achieve comprehensive diagnosis. Sentinel lymph node biopsy is recommended for patients with EPC.

Introduction

Papillary lesion of breast cancer is a distinct form of breast cancer in terms of clinical features, pathological characteristics, biopsy methods, and therapy management. Whether encapsulated papillary carcinoma (EPC) is carcinoma in situ or invasive has been a matter of ongoing debate. In the 2012 version of "WHO Classification of the Tumors of the Breast", EPC is classified as papillary lesion of the breast, the three other types of which are intraductal papilloma, intraductal papillary carcinoma, and solid papillary carcinoma.

EPC of the breast, also commonly referred to as intracystic papillary carcinoma, is a rare form of breast cancer that accounts for less than 1–2% of breast cancer cases [1]. EPC mostly occurs in postmenopausal women but also in men in some cases [2]. The WHO maintains that if EPC is not accompanied by infiltrative oncogenic components, it should be staged as papillary carcinoma in situ, which has an excellent prognosis [3].

Partial or complete absence of myoepithelium around EPC [4] and axillary lymph node metastasis [5] may indicate the propensity of EPC for invasive cancer. From the perspective of clinical biological

behavior or biological genetics, more experts prefer EPC to be somewhere between intraductal carcinoma in situ and intraductal invasive carcinoma. Notably, the long-term prognosis of EPC with or without invasive carcinoma is excellent compared with non-EPC breast cancers [6].

Herein, we present a case series of patients who were diagnosed with EPC. Our report complements the currently available outcome data on EPC with respect to therapy management.

This study was approved by the bioethics committees of The First Affiliated Hospital of Anhui Medical University and The First Affiliated Hospital of University of Science and Technology of China.

Methods

From March 2015 to December 2019, 11 patients who were diagnosed with EPC from The First Affiliated Hospital of Anhui Medical University were included. Demographic information, tumor details, immunohistochemical markers, stage of the disease, treatment modalities, clinical outcomes, and survival data were reviewed prospectively. The patients were followed up until December 12, 2020.

Results

Among the patients, 1 was male and 10 were females. The average age of the female patients was 53.6 (34–66) years, and the only male patient was 48 years old. Two patients initially presented with nipple discharge, and nine patients presented with breast masses. Three cases had pure EPC, two cases had EPC associated with DCIS, and six cases had EPC associated with invasive cancer. The male patients was one of the three patients who had pure EPC.

Modified radical mastectomy was performed in four patients, breast-conserving surgery plus sentinel node biopsy was performed in two patient, and mastectomy plus sentinel node biopsy was performed in five patients. All patients were evaluated for axillary lymph nodes. Two patients had lymph node metastases, and both patients had invasive cancer components. Regretfully, no further immunohistochemical examination of metastatic lymph nodes was performed to obtain more information. The histologic diagnoses of eight patients who had initial core needle biopsy (CNB) were intraductal papillomas in five cases, atypical papillomas in two cases, and papilocarcinoma in one patients. These diagnoses were confirmed by excision biopsy or mastectomy combined with immunohistochemistry examination. Immunohistochemical examination of all patients showed three cases of pure EPC, two cases of EPC associated with invasive carcinoma, and six cases of EPC associated with ductal carcinoma in situ (DCIS). No myoepithelial cell (MEC) layers were observed in the periphery of EPC nodules in all cases. Cytokeratin 5/6 (CK5/6), protein p63, and calponin were detected as MEC markers in the cases reviewed, and all of them were negative. (Fig. 1, Fig. 2, Fig. 3, Fig. 4)

Only two patient who underwent breast-conserving surgery received radiation therapy. Five patients, all with EPC associated with invasive carcinoma, received chemotherapy. Of the 11 patients, 10 were both hormone receptor-positive and HER-2 receptor-negative. One patient was negative for all three receptors. Seven patients received endocrine therapy.

Discussion

EPC is a rare malignancy of the breast and considered a variant of DCIS. It accounts for less than 0.5–1% of breast cancer cases and mostly occurs in postmenopausal women but also in men in some cases [1, 2]. EPC is usually considered a variant of carcinoma in situ and treated in accordance with carcinoma in situ management [3]. Papilloma shows positive MEC layers in the papillary lobe, whereas in papillary carcinoma, MEC layers are either completely disappeared or substantially reduced. Moreover, the presence of a layer of MEC at the periphery of nests of papillary carcinoma is used to define the lesion as being in situ rather than invasive. Studies showed that the tumor papilla and periphery of involved spaces lack MEC layers in contrast to DCIS [7, 8]. The lack of MEC layers is an important criterion for distinguishing EPC from other papillary lesions. In the present case, MEC was examined for all lesions, and most papillary carcinomas were evaluated with calponin, CK5/6, and P63 as MEC markers. We were unable to use any of the MEC markers to identify the layer of MEC in the periphery of these lesions that was consistent with that of a previous study [9].

Hill and Yeh [8] suggested that differences in intraductal cases without basal membrane endothelial cell staining are best seen as part of a continuum of progression between DCIS and invasive disease. A study that compared the expression of invasion-related proteins in EPC, DCIS, and invasive carcinoma demonstrated that the expression of MMP-1 and MMP-9 in EPC is higher than that in DCIS, and the difference between them and invasive carcinoma is not statistically significant. The expression levels of MMP-2 and MMP-7 are similar in EPC and DCIS, but the expression levels of both are lower than that of invasive tumors [4]. These observations may indicate that EPC has the potential to become an invasive cancer and display a clinically indolent behaviour. Pure EPC reportedly has lymph node metastasis and lung metastasis [6]. These features may also indicate that EPC is not DCIS or does not have the potential to become an invasive cancer. Considering EPC as a particular form between DCIS and invasive cancer may be more appropriate. Owing to the low incidence of EPC and the lack of prospective studies, the biological behavior, treatment, and prognosis of this disease remain unclear.

The majority of patients with EPC enrolled in previous studies were postmenopausal women. Males and young women with this disease are rare. In the present case report, one was male, and the average age of the female patients was 53.6 (34–66), which was lower than the average age reported in previous studies [10].

In this case report, eight patients received CNB, and three cases received excision biopsy initially. EPC was diagnosed in one patient via CNB. Surgical removal of atypical papillary lesions or papillary carcinomas in a core biopsy specimen is generally accepted. In a previous study, the false-negative rate of CNB in differentiating benign from malignant papillary lesions was 8.8%. Moreover, three out of eight patients who were diagnosed with atypical papilloma via CNB was upgraded to malignant lesions after surgical biopsy [11]. On the basis of our experience with CNB, we usually operate parallel to the long axis of the solid part of the tumor. The amount of tissue in this biopsy is not sufficient, and limited CNBs may omit

areas of atypia or invasive cancer in the sample provided. Therefore, diagnosing papillary lesions via CNB is challenging. Further excision biopsy should be taken to ensure accurate pathologic diagnosis.

The cases included herein were examined via color doppler ultrasound. EPC always demonstrates solid and cystic components in ultrasound test. Color ultrasonography often shows round cystic solid masses with clear boundaries with or without calcification. A cystic wall accompanied by papillary nodules is the characteristic sonographic appearance of EPC.

Regardless of whether EPC is associated with DCIS or invasive carcinoma, EPC has a better prognosis than non-EPC breast cancer [6]. A retrospective study of 917 patients with EPC at San Diego Medical Center found no remarkable difference between pure EPC and EPC associated with invasive cancer in terms of long-term survival [12]. A study conducted in China found that at 5 and 10 years, the overall survival rate is 92.2% and 85.6% and the relapse-free rate is 97.2% and 92.0%, respectively [13]. Given that older patients with EPC have more complications than younger patients, the impact on survival rate is inevitable. The relative cumulative survival time of all patients with IPC is 97.3% and 95.6% after 5 and 10 years, respectively [12].

The surgical treatment of EPC is not controversial, but the optimal surgical method has not been determined yet because of the low incidence of this disease. The three commonly used methods of surgical treatment are modified radical mastectomy, mastectomy combined with sentinel lymph node biopsy (SLNB), and breast-conservation therapy with or without SLNB [10, 14]. In the present case report, two patients received breast-conservation therapy. Breast-conservation therapy is now more widely accepted than in the past, and this therapy does not lead to a substantial increase in tumor recurrence and cancer-related deaths [12, 14]. Some studies on lumpectomy or excisional biopsy without further surgical intervention found that the local recurrence rate of this type of treatment is higher than that of mastectomy, but it has no obvious effects on cancer-related deaths [10, 15] probably because the extent of mass resection does not guarantee a negative margin; nevertheless, this observation also indicates that local treatment has a good therapeutic effect on EPC.

In this study, SLNB was performed in four patients, and ALND was performed in seven patients. None of the patients who underwent SLNB had lymph node metastasis. The patients with positive lymph nodes were those who had EPC associated with invasive carcinoma. These results were consistent with those of previous studies, which reported that positive lymph nodes are mostly related to invasive components [16]. Although lymph node metastasis is well recognized, it has been rarely reported in patients with pure EPC. Lymph node micrometastases were reported in two patients with pure EPC in a previous study [5]. The tumors in both patients were larger than 4 cm in diameter. Nodal involvement tended to be seen with larger tumors. Although the authors noted that occult breast cancer outside of EPC could not be ruled out, diagnosis of pure EPC without axillary lymph node evaluation is still not prudent. Wong et al. [17] examined sentinel lymph node metastases in patients with different breast cancer histologic subtypes. They found axillary metastases in 7% of patients with papillary cancer and in 8% of patients with DCIS with microinvasion. In view of the current recommendation for the treatment of EPC in accordance with

DCIS and because many authors suggest that EPC is a specific form between DCIS and invasive cancer, SLNB is recommended for patients with this disease.

Surgical treatment is the primary therapy for this disease. However, the role of adjuvant therapy is unclear. Pathologic studies suggested that EPC tends to be strongly ER/PR positive and HER2 negative [18], which is the molecular basis of endocrine therapy. EPC associated with invasive cancer or DCIS are candidates for endocrine therapy of young patients with pure EPC [6]. Endocrine treatment is also recommended for patients who are unfit for surgery and those with recurrent disease [19]. A previous study reported that the incidence of recurrence and the likelihood of death in a third of the patients with EPC who underwent radiotherapy were not affected by this therapy [20]. However, the significance of this result was limited by the limited number of cases and the inconsistent criteria for inclusion of radiotherapy they implemented. A SEER Database study retrospectively enrolled 2568 patients. Among the patients, 34.9% received radiation therapy. The survival rate of patients who received radiation therapy improved compared with that of those who did not receive this therapy. This study recommended radiotherapy for patients who choose to have lumpectomy [14]. The effects of radiation and endocrine therapy on patients with EPC remain unknown. We believe that adjuvant therapy is not an overtreatment, and that additional adjuvant therapy is appropriate for EPC that cannot be adequately excised or is associated with DCIS or invasive cancer components.

Conclusion

Whether EPC can be divided into DCIS or an invasive carcinoma is still a matter of debate. Nevertheless, studies have shown that EPC has good prognosis with adequate local treatment. Therefore, EPC can be treated as if it is DCIS. Overtreatment can be avoided, but its invasion potential cannot be ignored.

Declarations

Competing interests

The authors declare that they have no conflicts of interest

Ethics approval and consent to participate

This study was approved by the Institutional Research Ethics Committee of the First Affiliated Hospital of Anhui Medical University

Ethical code: PJ 2020-15-29

Consent for Publication

Written informed consent for publication was obtained from all participants

Funding

Authors' contributions

Zhaorui Wang participated in the design of the study, and drafted the manuscript. Jingjing Wang participated in conceived of the study and helped to draft the manuscript. Yubo Pan participated the collection of pathological data. All authors read and approved the final manuscript. Yubo Pan participated in collection of cases. Jing Pei participated in its design and coordination and helped to draft the manuscript. All authors read and approved the final manuscript.

Availability of data and materials

The datasets used and analysis during the current study are available from the corresponding author on reasonable request.

Acknowledgment

Not applicable

References

1. Esposito NN, Dabbs DJ, Bhargava R. Are encapsulated papillary carcinomas of the breast in situ or invasive? A basement membrane study of 27 cases. *Am J Clin Pathol.* 2009;131:228–42.
2. Stolnicu S, Giurgi A, Bauer O, et al. Encapsulated papillary breast carcinoma in a male patient in association with microdeposits of carcinoma cells in the needle track and sentinel lymph node treated conservatively. *Pol J Pathol.* 2018;69:185–8.
3. Sinn HP, Kreipe H. A Brief Overview of the WHO Classification of Breast Tumors, 4th Edition, Focusing on Issues and Updates from the 3rd Edition. *Breast Care (Basel)* 2013; 8: 149–154.
4. Rakha EA, Tun M, Junainah E, et al. Encapsulated papillary carcinoma of the breast: a study of invasion associated markers. *J Clin Pathol.* 2012;65:710–4.
5. Mulligan AM, O'Malley FP. Metastatic potential of encapsulated (intracystic) papillary carcinoma of the breast: a report of 2 cases with axillary lymph node micrometastases. *Int J Surg Pathol.* 2007;15:143–7.
6. Fayanju OM, Ritter J, Gillanders WE, et al. Therapeutic management of intracystic papillary carcinoma of the breast: the roles of radiation and endocrine therapy. *Am J Surg.* 2007;194:497–500.
7. Collins LC, Schnitt SJ. Papillary lesions of the breast: selected diagnostic and management issues. *Histopathology.* 2008;52:20–9.
8. Hill CB, Yeh IT. Myoepithelial cell staining patterns of papillary breast lesions: from intraductal papillomas to invasive papillary carcinomas. *Am J Clin Pathol.* 2005;123:36–44.

9. Collins LC, Carlo VP, Hwang H, Barry TS, Gown AM, Schnitt SJ. Intracystic papillary carcinomas of the breast: a reevaluation using a panel of myoepithelial cell markers. *Am J Surg Pathol*. 2006;30(8):1002–7. doi:10.1097/00000478-200608000-00011.
10. Li X, Xu Y, Ye H, et al. Encapsulated papillary carcinoma of the breast: A clinicopathological study of 49 cases. *Curr Probl Cancer*. 2018;42:291–301.
11. Kil WH, Cho EY, Kim JH, et al. Is surgical excision necessary in benign papillary lesions initially diagnosed at core biopsy? *Breast*. 2008;17:258–62.
12. Grabowski J, Salzstein SL, Sadler GR, Blair S. Intracystic papillary carcinoma: a review of 917 cases. *Cancer*. 2008;113:916–20.
13. Zhang J, Zhang T, Wu N, et al. Intracystic papillary carcinoma of the breast: Experience of a major Chinese cancer center. *Pathol Res Pract*. 2018;214:579–85.
14. Mogal H, Brown DR, Isom S, et al. Intracystic papillary carcinoma of the breast: A SEER database analysis of implications for therapy. *Breast*. 2016;27:87–92.
15. Carter D, Orr SL, Merino MJ. Intracystic papillary carcinoma of the breast. After mastectomy, radiotherapy or excisional biopsy alone. *Cancer*. 1983;52(1):14–9.
16. Hassan Z, Boulos F, Abbas J, et al. Intracystic papillary carcinoma: clinical presentation, patterns of practice, and oncological outcomes. *Breast Cancer Res Treat*. 2020;182:317–23.
17. Wong SL, Chao C, Edwards MJ, et al. Frequency of sentinel lymph node metastases in patients with favorable breast cancer histologic subtypes. *Am J Surg*. 2002;184(6):492–8. doi:10.1016/s0002-9610(02)01057-7.
18. Yee C, Drost L, Niglas M, et al. Early Local Recurrence in a Patient With Encapsulated Papillary Carcinoma of the Breast. *Clin Breast Cancer*. 2018;18:e447–8.
19. Collins LC, Carlo VP, Hwang H, Barry TS, Gown AM, Schnitt SJ. Intracystic papillary carcinomas of the breast: a reevaluation using a panel of myoepithelial cell markers. *Am J Surg Pathol*. 2006;30(8):1002–7.
20. Solanki MH, Derylo AF, Visotcky AM, Jorns JM. Encapsulated and solid papillary carcinomas of the breast: Tumors in transition from in situ to invasive? *Breast J*. 2019;25(3):539–41.

Figures

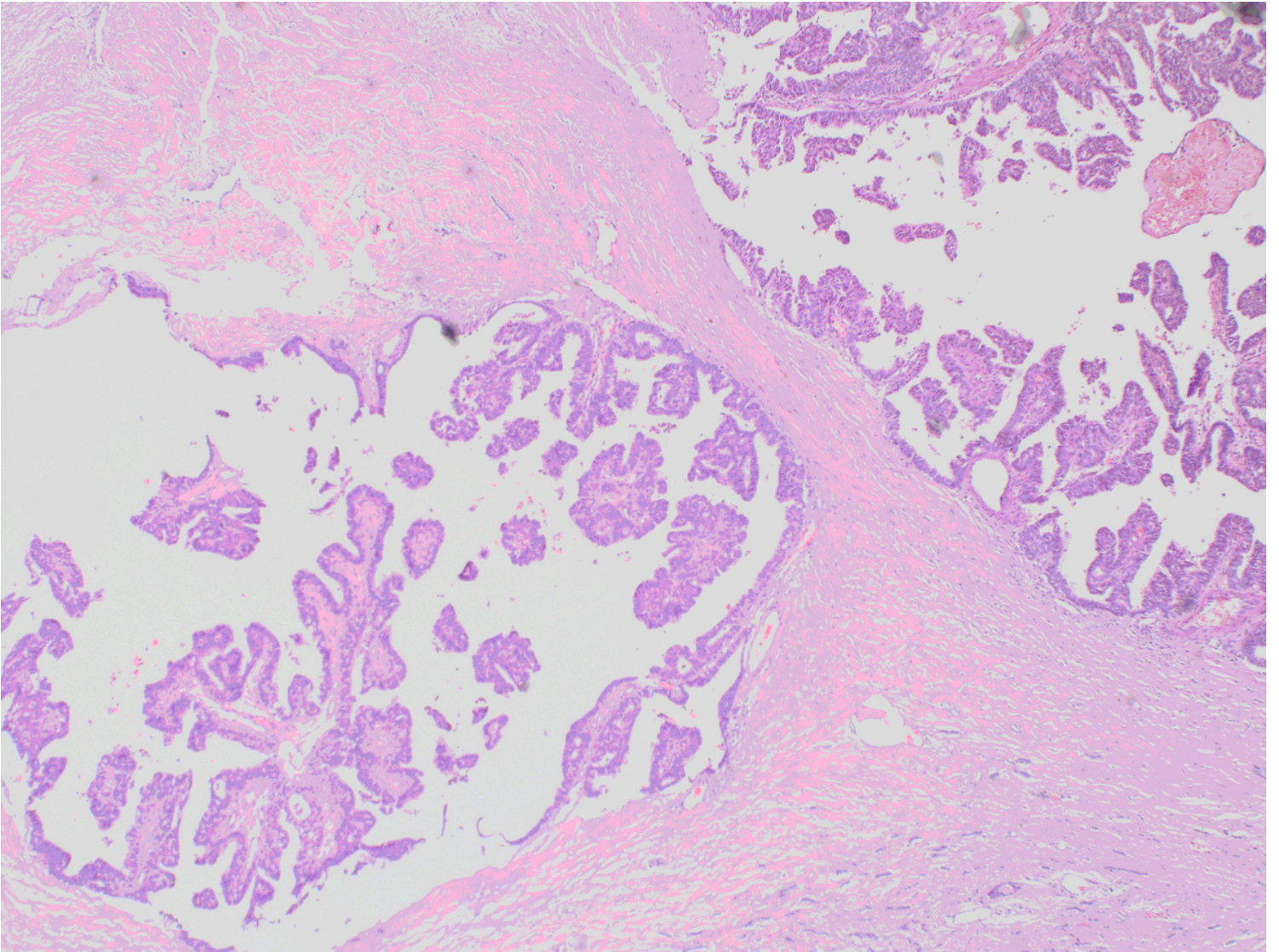


Figure 1

HE staining: The tumor presents as a papillary hyperplasia surrounded by a thick capsule

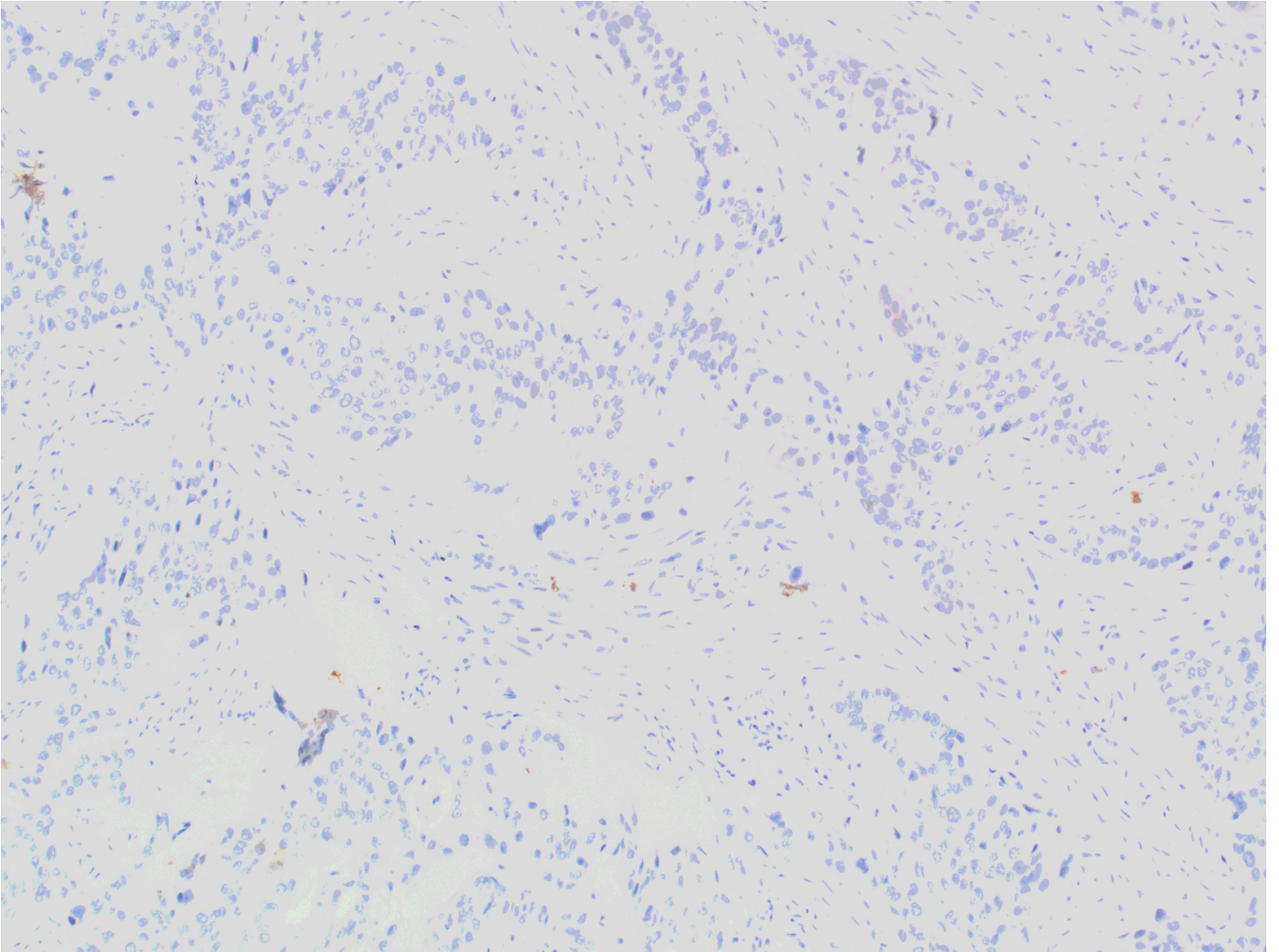


Figure 2

CK5/6 staining: negative for CK5/6 in the papillae and surrounding lesions

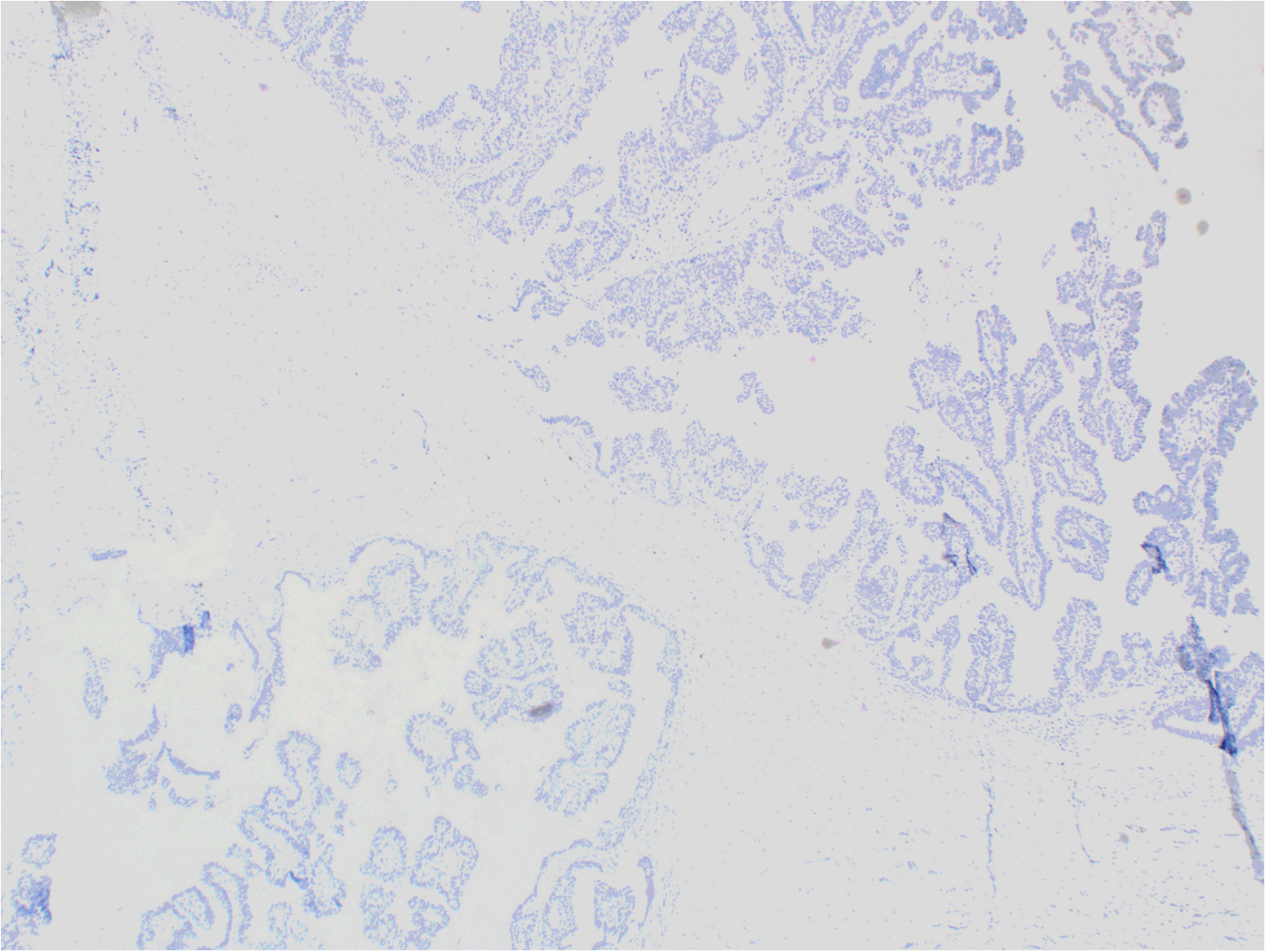


Figure 3

P63 staining: complete absence of myoepithelial cells in and around the papillae

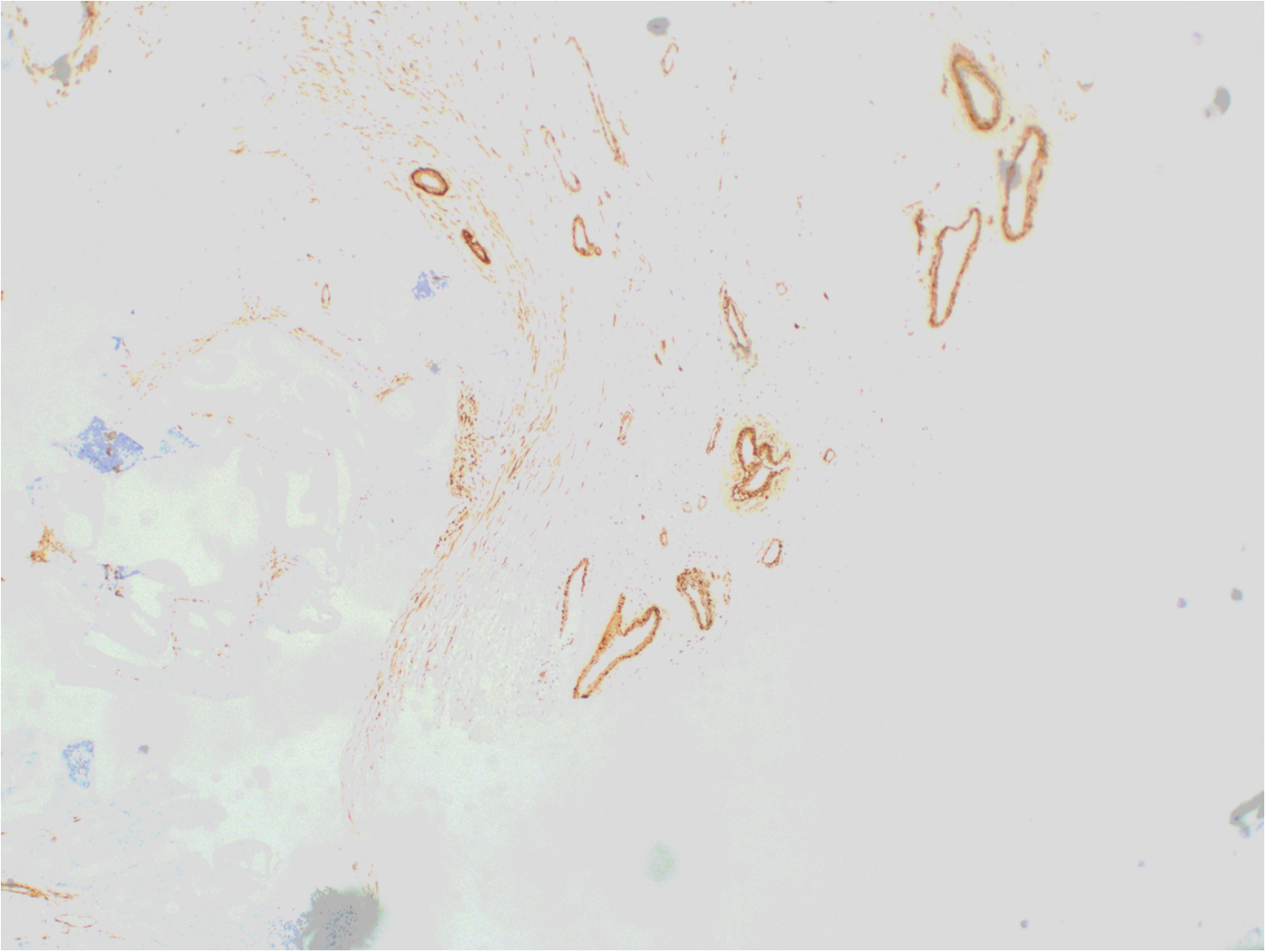


Figure 4

Calponin staining: Calponin was negative around the lesion