Research Square

Preprints are preliminary reports that have not undergone peer review. They should not be considered conclusive, used to inform clinical practice, or referenced by the media as validated information.

The Optimal Arthroscopic Release Plane of External Snapping Hip

Min Zhu
Shanghai Tenth People's Hospital https://orcid.org/0000-0003-1447-1279

Chao Xue
Shanghai Tenth People's Hospital

Mengxiong Song
Affiliated Hospital of Medical College Qingdao University

Qiuchen Cai
Shanghai Tenth People's Hospital

Biao Cheng
Shanghai Tenth People's Hospital

FuBo Chen
Shanghai Tenth People's Hospital

Peng Wu (wupeng03010814@163.com)
Shanghai Tenth People's Hospital https://orcid.org/0000-0001-7140-5388

Research article

Keywords: External snapping hip, Arthroscopy, Release plane, Grouping

Posted Date: August 19th, 2020

DOI: https://doi.org/10.21203/rs.3.rs-60468/v1

License: This work is licensed under a Creative Commons Attribution 4.0 International License. Read Full License

Abstract

Background: Some studies have reported arthroscopic release of external snapping hip(ESH). However, there is no research on the effect of different arthroscopic release plane for ESH. We will study the effect of release plane on arthroscopic surgery, and suggest an optimal release plane.

Methods: From September 2017 to December 2018, 177 bilateral and 6 unilateral ESH patients who would receive arthroscopic release of ESH and agree to attend at this study were enrolled. One release plane was randomly offered for each operation hip out of 6 different arthroscopic release planes(referred to the apex of the great trochanter(GT), including planes of -2cm, 0cm, 2cm, 4cm, 6cm and 8cm groups). All patients received continuous follow-up, comparing preoperative and postoperative hip snapping, hip adduction and flexion angles and Harris Hip Scores(HHS).

Results: There was no difference in age, gender, body mass index (BMI) and average operation time among different release plane groups ($p>0.05$). In terms of surgical success rate, the release plane group 4cm (98.33%)> 6cm (96.67%)> 2cm (95.00%)> 0cm (91.67%)> 8cm (8.33%)>-2cm (5.00%) ($p<0.05$). Although the hip adduction and flexion angles were improved in each group after operation ($p<0.05$), the improvement in the release plane -2cm and 8cm groups was significantly lower than that in the other four release plane groups ($p<0.05$). In addition, at 12 months of follow-up, all patients had significantly improved adduction and flexion angles and HHS ($p<0.05$).

Conclusions: The arthroscopic release plane for ESH can affects the surgical effect, and the optimal arthroscopic release plane is 0-6 cm .

Background

Gluteal muscle contracture (GMC) is often referred to as external snapping hip (ESH)in clinical, the main feature is that the obvious thickened tissue including the tensor fascia lata (TFL),iliotibial band (ITB) and anterior gluteus maximus. During active hip flexion and extension, thickened tissue slides over the great trochanter（GT）making a snapping sound, with or without pain. GMC was first reported by Valderrama [1] in 1970,often accompanied by unique gait and signs, such as difficulty knee squatting, abnormal gait and hip snapping. According to the etiology, snapping hips can be divided into intra-articular and extra-articular forms. Intra-articular type mainly refers to the lesions of the joint itself, including fracture fragments, joint synovial chondroma, or intra-articular free bodies. The extra-articular snapping hip is further divided into internal snapping and external snapping hip (ESH). The internal snapping hip is caused by the iliac psoas tendon sliding over the iliac pubic carina or femoral head [2], and ESH is the most common clinically. In recent years, domestic and foreign literatures have advocated early surgical treatment, and arthroscopic release of ESH has gradually become the first choice for surgeons [3]. Compared with open surgery, the arthroscopic release of ESH has the characteristics of small scars, light pain, fast recovery, and few complications [4, 5]. At present, there is no unified standard for the surgical method of arthroscopic release of ESH. From the literature reports, as long as the contracture tissue is fully released, various surgical methods also have good results [6, 7].

We performed about 200 arthroscopic releaseof ESH every year, have more than 2000 arthroscopic release of ESH experience. According to our routine arthroscopic methods and clinical experience (the surgeons are all right-handed) (Fig. 1), we found that postoperative effects in patients with bilateral ESH are not completely consistent, right side are usually better than left side, suggesting that the release plane affects surgical effect. However, few studies have verified this view. Therefore, in order to confirm the relationship between the release plane and the surgical effect, we conducted this study and further provided the optimal surgical release planes for patients with ESH.

Materials And Methods

subjects

From September 2017 to December 2018, this study prospectively included 183 ESH patients (including 177 bilateral and 6 unilateral ESH) who received arthroscopy in our hospital. A senior surgeon performed the operation under general anesthesia. This study was approved by the Institutional Review Board of Tenth People's Hospital affiliated to Tongji University (Shanghai, China), and all patients or their parents signed an informed consent form. ESH is mainly diagnosed based on medical history, clinical manifestations, and physical examinations. All patients have varying degrees of hip adduction, internal rotation dysfunction, unable to squat with knees, and cannot cross legs, showing frog legs, gait, etc. Loud clicks can be heard during active hip flexion or squatting, sometimes accompanied by pain, and severe cases can also include pelvic tilt, scoliosis, unequal length of both lower extremities, and hip skin depression. The exclusion criteria are as follows: (1) intra-articular snapping and internal type snapping caused by iliac psoas muscle contracture. (2) conventional pelvic slices exclude bone and joint abnormalities, such as hip dysplasia or subluxation (3) combined with other chronic diseases or not suitable for surgery. In this study, we will randomly divide all 360 hips (183 patients) into 6 groups of release planes, 60 hips in each group. Patients were postured at lateral position with hip and knee flexion at 90 degree, touched the apex of the GT and moved 2 cm backword, marked as original point. 0 cm, -2cm, 2 cm, 4 cm, 6 cm, and 8 cm distal to the original point are recorded as the release plane group of 0 cm, -2 cm, 2 cm, 4 cm, 6 cm, and 8 cm, respectively.

Surgical Procedures and Methods

All patients received arthroscopic surgery and postoperative rehabilitation exercises. The range of motion (ROM) of hip adduction and flexion in all patients was measured before operation. (Fig. 2). All operations were performed by a senior orthopedic surgeon. After the general anesthesia, the lateral position of the affected hip is placed on the standard operating table and moderately tilted back. The position of the GT and the incision is marked before surgery. The contralateral lower limb is straightened, and the operating hip and knee are bend to 90 degree, and the hip joint is repeatedly moved from flexion to extension to make the contracture band easy to touch. In general, we make two 0.5 cm incisions in size, we define the original point at 2 cm backword to the apex of the GT. The surgeon is a right-handed, and the first incision on his left hand side is the arthroscopy observation portal(portal a), the second incision locating about 2-4cm right to observation portal a is recorded as the working portal b which is used to release contracture zone by an arthroscopic plasma hook knife perpendicular to the femoral. Position of portal b determines the release plane, a release plane of -2cm, 0 cm, 2 cm, 4 cm, 6 cm, and 8 cm in this study means that the working portal b locates at -2cm, 0 cm, 2 cm, 4 cm, 6 cm, and 8 cm distal to the original point, observation portal a is 2-4cm left to the working portal b (Fig. 3). In general, we first use an arthroscopic blunt puncture head to puncture from the incision along the superficial layer of the deep fascia to separate the subcutaneous tissue to form an arthroscopic working cavity, and continue to properly clean the surface tissue of the fascia with a shaver, using a low-temperature plasma knife to completely stop bleeding, and release the contracture tissue from front to back fully through the working portal b. Usually the broad fascia is released first, then the ITB, and at last the anterior edge of the contracture gluteus maximus (Fig. 4). During the operation, damage to normal muscle tissue and sciatic nerve should be avoided. After complete release, hip flexion and adduction and internal rotation of the hip joint were repeated,Disappearance of the bounce and negative ober's sign indicated the completion of the release. The fluid was drawn and the incision was closed. Especially pay attention, when the release is completed on a certain release plane, if there is still a snapping during the intraoperative examination, the ober’s sign is positive and it is recorded as a failed operation. Then, according to our previous experience, select an extra release plane at between 0 cm-4 cm to continue the operation until the operation is successful (Fig. 5), usually just change the observation portal into release plane is enough, an extra incision is often not necessary. After the operation, the patient is encouraged to exercise early and perform functional exercises such as knee squat, hip flexion, knee

crossing and leg sitting with the aid of brace. The exercise amplitude and intensity gradually increase with time. Each patient arranges a similar rehabilitation plan.

Data collection and analysis

We evaluated the intraoperative hip snap, whether the ober's sign was negative, and the ROM of hip adduction and flexion during surgery. At the same time, the operation time of each group of patients, hip adduction, flexion angles and Harris Hip Scores(HHS) before and after 12 months of each group were recorded. At each follow-up, physical examination and questionnaire were conducted. All data were measured by two independent researchers and their average value was calculated.

Statistical analysis

Use SPSS26.0 software for all data statistical analysis. The paired t test was used to compare the hip adduction, flexion angles and HHS before and after operation. The Chi-square test was used to compare the surgical success rate of each group. The analysis of variance was used to compare between groups. $P < 0.05$ indicated that there was statistics difference.

Results

In this study, the subjects included 79 male and 104 female patients with ages ranging from 15 to 44 years, and the mean age of patients was 30.4 ± 5.37 years.There was no significant difference in the gender, age, BMI and the surgical release time ($P > 0.05$), but there was a significant difference in the surgical success rate between groups, the success rate of 4 cm release plane was 98.33% >6 cm (96.67%) > 2 cm (95.00%) > 0 cm (91.67%) > 8 cm (8.33%)>-2cm (5.00%) ($P < 0.05$, Table 1),but there was no significant difference in release plane 0 cm,2 cm ,4 cm and 6 cm groups($\chi2 = 3.335$, $P = 0.420$)(Fig. 6). We also compared the ROM of hip adduction and flexion before and after operation. The postoperative adduction and flexion angles of each group were significantly improved compared with those before operation ($P < 0.05$), however, there were no differences in the degree of improvement of adduction and flexion angle among the 0 cm, 2 cm, 4 cm and 6 cm groups($P = 0.542$, $P = 0.819$), but the improvement ROM of hip adduction and flexion in these four groups was significantly higher than that in -2cm and 8 cm groups ($p < 0.001$) (Table 2).We followed up all patients continuously, without complications such as hip snapping and pain, wound infection, blood vessel and nerve injury, and all patients had no difficulty in crossing their legs and squatting with their knees. During the follow-up, the adduction angle of 183 patients increased from − 31.7°±10.26°to 25.4°±2.12°, the flexion angle increased from 73.7° ±13.80°to 121.8°±4.57°, and the HHS increased from 77.2 ± 8.45 to 96.7 ± 2.70, the differences were statistically significant (Table 3, $P < 0.05$).

Discussion

The pathogenesis of ESH is very complex, and it has not yet been fully elucidated[5, 6]. The disease mainly occurs in Asia, and it is rarely reported in Europe and the United States. The epidemiology of China shows that the incidence rate is 0.7–10.1% [8, 9]. Most of the disease starts in children, which may be related to repeated injection of penicillin and other drugs in the hips as a child[10, 11]. Due to the increasing emphasis on etiology prevention, the number of new cases of GMC has been greatly reduced [12]. Patients with ESH mainly present with hip adduction, flexion and internal rotation disorders, often accompanied by special gait and hip snapping, and are more common in competitive training such as cyclists [13] and ballet dancers [14], so some scholars believe that chronic strain may be related [15], which seriously affects patients' daily activities and quality of life. As the course of the disease progresses, the scar tissue of

the contracture is severe, which can lead to hip dysplasia, pelvic tilt, and even scoliosis. The main reason for the occurrence of ESH is the thickening of the posterior edge of the ITB or the front edge of the gluteus maximus tendon. When the hip joint is flexed, adducted, and internally rotated, it is visible and can feel the tight contracture band sliding over the GT, so the tension contracture of the ITB and the excessive protruding of the GT are the key factors leading to this disease[16].

Early diagnosis and treatment are imortant for ESH, surgical release of GMC under arthroscopy is popular so far. FUD [17] believes that exercise will not improve contractile muscles, so once conservative treatment is ineffective, the patient's clinical symptoms do not improve, and all should be promptly operated. Zhao CG [18] and others found that the main factor affecting the efficacy of ESH treatment is age. Whether in non-surgical or surgical treatment, the efficacy of the childhood group is better than that of the juvenile group[18]. At present, many studies have confirmed that arthroscopic surgery has more advantages than open surgery [4, 5, 17], so the current arthroscopic release is the gold standard for the treatment of GMC [18].

However, at present, there is no uniform standard for the selection of the incision approach for arthroscopic GMC release and the choice of intraoperative release plane. Our research shows that the operation effect is the best when the release plane is located at 0-6cm, and the patient's ROM of hip adduction and flexion are greatly improved, and the snapping sounds is disappeared. After 12 months of follow-up, all patients' snapping sounds disappeared, the ROM of hip adduction and flexion, and HHS were significantly improved, which shows that as long as the ITB and its contracture tissue are fully released during the operation, a good surgical effect can be achieved. ZHAN GT [5] releases the second-class gluteal muscle contracture under arthroscopy, the first observation incision is located in the middle and lower 1/3 of the line between the apex of GT and the posterior superior iliac spine(PSIS). The second is the incision generally in the apex of GT, this incision is often adjusted along the GT for release according to the preoperatively determined contracture band and the expected release area. Ilizaliturri VM [20] established an observation portal 3 cm above the apex of GT, away from the bottom of its 3 cm,a second portal,the release incision,is established on the ITB,and both portals were aligned with the femoral axis. After the vertical release of the ITB on the working portal, a lateral cut was made to form a cross shape, and finally the remaining 4 flaps were removed to form a diamond-shaped defect. Liu Y [7] chose to establish two portals above the GT, the first portal was at the anterior border of the contracture gluteal muscle, and the second portal was at the posterior border of the contracture gluteal muscle, When facing the patient's buttocks or abdomen, the operator can choose different portals as work portal to release the contracture band without changing the position.Rai S [6] also used the F and C release methods under arthroscope to release the gluteal muscles. He chose two portals, first releasing ITB, from the center of GT, continue move about 10 cm upward in the longitudinal axis and release the contracture of tensor fascia lata (TFL) forward to the anterior superior iliac spine(ASIS), and then releasing the contracture band of the gluteus maximus muscle about 1 cm below the upper pole of GT, that is, completing the release of type F. finally, he released the contracture of the gluteus medius and gluteus minimus and other deep tissues around the GT in a C-type method. From the results of postoperative follow-up, no matter which release method is used for surgery, the clinical symptoms of this patient are significantly improved or relieved, and good results are achieved.

The choice of optimal arthroscopic release plane of ESH relies on the anatomy. According to the anatomy of ITB(Figure.7), we know that the ITB starts from the iliac crest between the ASIS and the iliac tubercle, and stops at the lateral condyle of the tibia. The proximal gluteus maximus starts from the posterior part of the iliac crest, and the distal tendon is combined with the ITB(joint part) before stopping at the GT, and the ITB is pulled backward to maintain its tension. Because the GT protrudes outward, the ITB is lifted, and its force is applied to the junction of ITB on the surface of GT. The contracture band of the snnaping hip affects the movement function of the hip joint through the joint of ITB, so the key part of the surgical release is the joint of the ITB [21]. From the anatomical structure, the starting and terminus of ITB is the fascia bundle from the iliac bone to the lateral condyle of the tibia. In theory, any position of arthroscopic release of ITB should be effective. However, our study found that only when the release plane is located at

0-6cm from the apex of the GT, the effect is better, but the success rate is not 100%,the failure of this part of the patients may be related to a wide range of muscle contractures. When the release plane is above the GT or near the knee joint, the effect is very poor, and there are almost all residual snapping sounds after the operation.Wang LP [22] shows that the ITB is composed of thinner circular fibers in the outer layer and thicker longitudinal fibers in the inner layer, and the circular fibers are arranged from front to back,while the longitudinal fibers of the inner layer between the upper edge of the patella and the TFL are cross-linked with the muscle fibers of the deep muscle from the bottom to up, We suspect that only by cutting off the cross-linking between the inner longitudinal fibers and the deep muscles can ITB be completely released.Of course, this needs to be further confirmed by the post-mortem experiment.

Our study also has some limitations. First of all, we did not group the release planes more carefully and ignored the individual differences of the patients and the severity of the contracture zone. The second study only came from a single central hospital, which may bring some differences between regions and medical institutions. Finally, we did not compare with open surgery.

Conclusions

Arthroscopic release of the ITB and contracture tissue is an effective operation for all patients with ESH, and the release plane will affect the surgical effect. The optimal release plane of ESH is found at 0-6cm far from the apex of the GT, which results in the best surgical effect.

Abbreviations

ESH: External snapping hip; GT: Great trochanter; HHS: Harris hip scores; BMI: Body mass index; GMC: Gluteal muscle contracture; TFL:Tensor fascia lata; ITB: iliotibial band; ROM: Range of motion; PSIS: Posterior superior iliac spine; ASIS: Anterior superior iliac spine.

Declarations

Acknowledgements

Not applicable.

Funding

The study was supported by the grants from the Shanghai Committee of Science and Technology (No. 20ZR1443200) and Shanghai Tenth People's Hospital (No. 040319122).

Availability of data and materials

Please contact author for data requests.

Authors’ contributions

Min Zhu collected the clinical data, performed the statistical analysis, and drafted the manuscript. Chao Xue and Biao Cheng helped in collecting the clinical data and participated in the design of the study. Wu Peng and FuBo Chen

participated in the statistical analysis. Mengxiong Song and Qiuchen Cai conceived of the study and participated in its design. All authors read and approved the final manuscript.

Competing interests

The authors declare that they have no competing interests.

Consent for publication

Informed consent for publication of photographs was obtained from all the subjects.

Ethics approval and consent to participate

The study was approved by the Institutional Review Board of Shanghai Tenth People's Hospital. Written informed consent was obtained for each Participant.

References

1. Fernandez, D.V.J. and D.M.R. Esteve, Fibrosis of the gluteus maximus: a cause of limited flexion and adduction of the hip in children. Clin Orthop Relat Res, 1981(156): p. 67-78.
2. Ilizaliturri, V.J., et al., Internal snapping hip syndrome: treatment by endoscopic release of the iliopsoas tendon. Arthroscopy, 2005. 21(11): p. 1375-80.
3. Rai, S., et al., Gluteal muscle contracture: diagnosis and management options. SICOT J, 2017. 3: p. 1.
4. Dai, Z., et al., Comparison of arthroscopic versus open surgery on external snapping hip caused by gluteal muscle contracture. Hip Int, 2018. 28(2): p. 173-177.
5. Zhang, T., et al., Comparison of the clinical effects of arthroscopic surgery vs. open surgery for grade II gluteal muscle contracture in adults. Exp Ther Med, 2018. 16(1): p. 364-369.
6. Rai, S., et al., Arthroscopic release using F and C method versus conventional open release method in the treatment of gluteal muscle contracture: a comparative study. BMC Musculoskeletal Disorders, 2017. 18(1): p. 113.
7. Liu, Y.J., et al., Arthroscopic gluteal muscle contracture release with radiofrequency energy. Clin Orthop Relat Res, 2009. 467(3): p. 799-804.
8. Yizhou, W., et al., The epidemiological investigation of gluteal muscle contracture of male students in the physical examination for navy pilot recruitment. Chinese Journal of Aerospace Medicine, 2015. 26(3): p. 203-207.
9. Xiaojun, H., et al., Epidemiological survey of gluteal muscle contracture of primary and secondary students in Rongchang county. Chongqing Medicine, 2015(3): p. 368-368,371.
10. Yuan, B., et al., Histology and molecular pathology of iliotibial tract contracture in patients with gluteal muscle contracture. Bioscience reports, 2019. 39(9).
11. Xintao, Z., et al., Arthroscopic revision release of gluteal muscle contracture after failed primary open surgery. International Orthopaedics, 2017. 41(8).
12. Cai, J.H., et al., Iliac hyperdense line: a new radiographic sign of gluteal muscle contracture. Pediatr Radiol, 2005. 35(10): p. 995-7.
13. Little, T.L. and J. Mansoor, Low back pain associated with internal snapping hip syndrome in a competitive cyclist. Br J Sports Med, 2008. 42(4): p. 308-9; discussion 309.

14. Winston, P., et al., Clinical examination and ultrasound of self-reported snapping hip syndrome in elite ballet dancers. Am J Sports Med, 2007. 35(1): p. 118-26.
15. Spina, A.A., External coxa saltans (snapping hip) treated with Active Release Techniques: a case report. J Can Chiropr Assoc, 2007. 51(1): p. 23-9.
16. Shrestha, A., et al., Clinical outcomes of arthroscopic surgery for external snapping hip. J Orthop Surg Res, 2017. 12(1): p. 81.
17. Fu, D., et al., Comparison of endoscopic surgery and open surgery for gluteal muscle contracture. J Pediatr Orthop, 2011. 31(5): p. e38-43.
18. Zhao, C.G., et al., Classification of gluteal muscle contracture in children and outcome of different treatments. BMC Musculoskelet Disord, 2009. 10: p. 34.
19. Huang, J.B., et al., The role of arthroscopic release of gluteal muscle contracture in improving patellofemoral instability. J Orthop Surg Res, 2019. 14(1): p. 159.
20. Ilizaliturri, V.J., et al., Endoscopic iliotibial band release for external snapping hip syndrome. Arthroscopy, 2006. 22(5): p. 505-10.
21. Weinan, C., et al., Applied anatomy of external snapping hip. Chinese Journal of Anatomy, 2008(05): p. 703-705.
22. WANG, L., et al., Applied anatomy of iliotibial tract. Chinese Journal of Anatomy, 2004(03): p. 314-316.

Tables

Table.1
Baseline characteristics of patients in each group

R-P(cm)	-2	0	2	4	6	8	P value
Number	30	31	31	31	30	30	
Gender(M/F)	11/19	17/14	12/19	16/15	13/17	10/20	0.470
Age(year)	30.7 ± 5.96	29.8 ± 5.75	30.6 ± 5.97	31.0 ± 4.99	31.23 ± 4.56	29.0 ± 4.90	0.613
BMI	22.3 ± 1.91	22.1 ± 1.94	21.6 ± 1.77	21.9 ± 1.88	22.3 ± 1.71	21.8 ± 1.81	0.696
R-T(min)	11.1 ± 3.05	10.1 ± 3.16	10.7 ± 2.67	10.4 ± 2.28	10.5 ± 1.96	11.4 ± 2.35	0.217
Success rate (/60 hips)	3/60 (5%)	55/60(91.67%)	57/60(95.00%)	59/60(98.33%)	58/60(96.67%)	5/60 (8.33%)	< 0.001

R-P Release plane ▯R-T Release time▯M/F male/female

Table.2
Comparison of pre-operative and post-operation ROM in each group

	Adduction		p value	Flexion		p value
R-P(cm)	Pre-op	Post-op		Pre-op	Post-op	
-2	-31.1 ± 8.37	-25.4 ± 13.74	< 0.001	71.6 ± 12.33	76.4 ± 14.05	< 0.001
0	-31.9 ± 10.46	19.0 ± 11.56	< 0.001	71.5 ± 15.31	110.4 ± 8.68	< 0.001
2	-30.8 ± 9.49	19.6 ± 7.93	< 0.001	74.2 ± 13.18	111.8 ± 5.87	< 0.001
4	-31.5 ± 11.06	21.2 ± 4.64	< 0.001	74.9 ± 14.31	114.0 ± 6.95	< 0.001
6	-29.9 ± 10.44	20.0 ± 5.78	< 0.001	77.6 ± 12.13	115.3 ± 5.60	< 0.001
8	-34.8 ± 11.19	-27.0 ± 18.00	< 0.001	72.4 ± 14.79	79.3 ± 17.44	< 0.001
p value	0.154	< 0.001		0.114	< 0.001	

R-P Release plane, Pre-op pre-operation, Post-operation

Table.3
Comparison of the ROM in 183 patient pre-operation and 12 months follow-up post-operation.

	Adduction	Flexion	HHS
Pre-op	-31.7 ± 10.26	73.7 ± 13.80	77.23 ± 8.45
post-12 ms	25.4 ± 2.12	121.8 ± 4.57	96.68 ± 2.70
p value	< 0.001	< 0.001	< 0.001
Pre-op:pre-operation,post-12ms: 12 months follow-up post-operation			

Figures

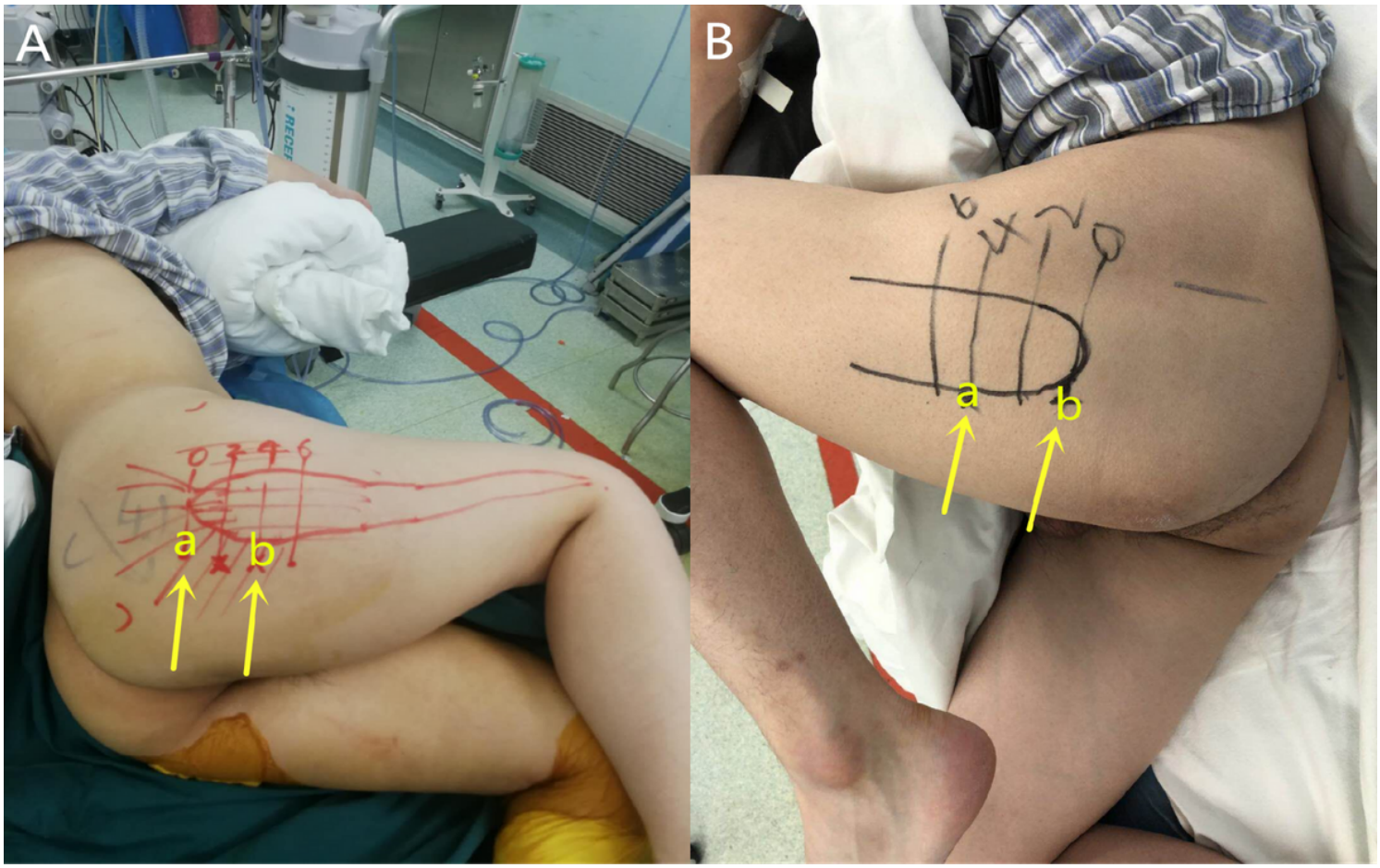

Figure 1

In our previous routine arthroscopic incision, we used two portal incisions about 2-4cm apart on the left and right sides. Patients were postured at lateral position with hip and knee flexion at 90 degree, touched the apex of GT and moved 2 cm backword, marked as the original point(a in figure1A, b in figure1B). Observe portal a: enter the arthroscopy. Work portal b: enter the plasma hook knife and release it perpendicular to the femur or contracture band. In left hip the release plane (portal b) located at the original point, while in the right hip the release plane (portal b) located at 4cm distal to the original point.

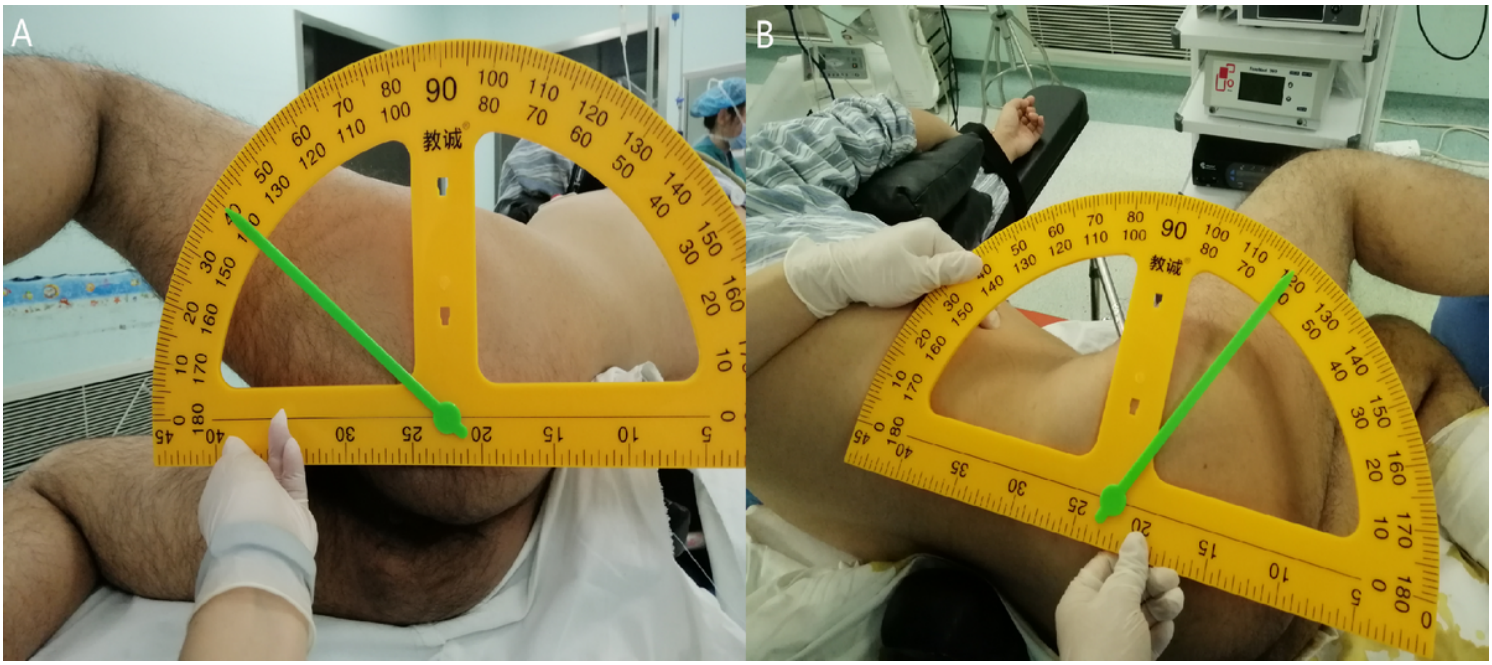

Figure 2

Measure the ROM of hip adduction (A) and flexion (B) in patients with ESH pre-operation at the lateral position after general anesthesia.

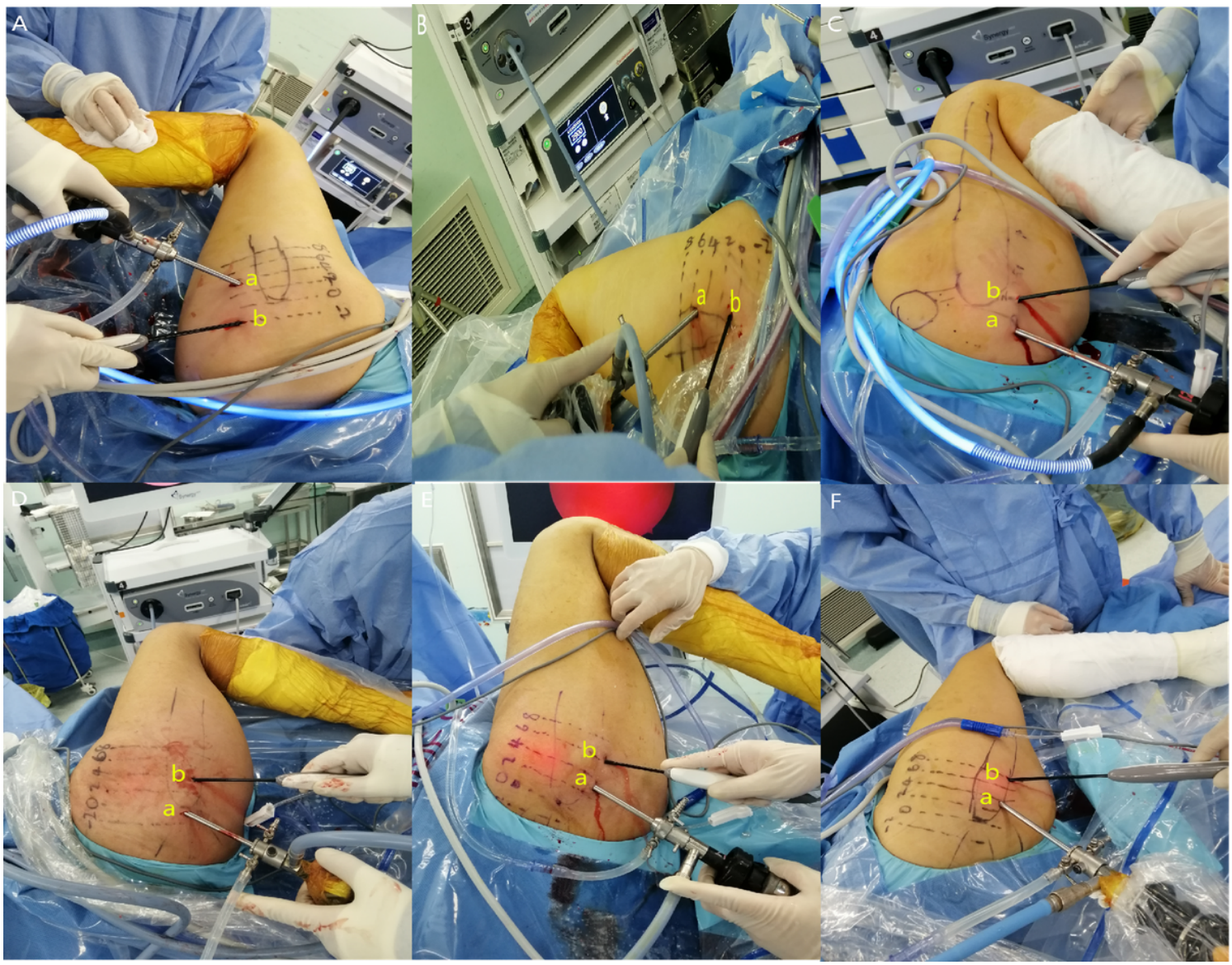

Figure 3

Different arthroscopic surgical release planes for each group (observation portal a and working portal b). The A-F release planes are recorded as -2cm, 0cm, 2cm, 4cm, 6cm, 8cm, respectively.

Figure 4

The detailed surgical procedure of arthroscopic ESH release. A: Determine the location of the contracture band by moving the hip joint. B: Insert arthroscopy and plasma hook knife in portal a and portal b respectively. C: Release intraoperatively ITB and other contracture tissues. D: Suture two incisions after surgery

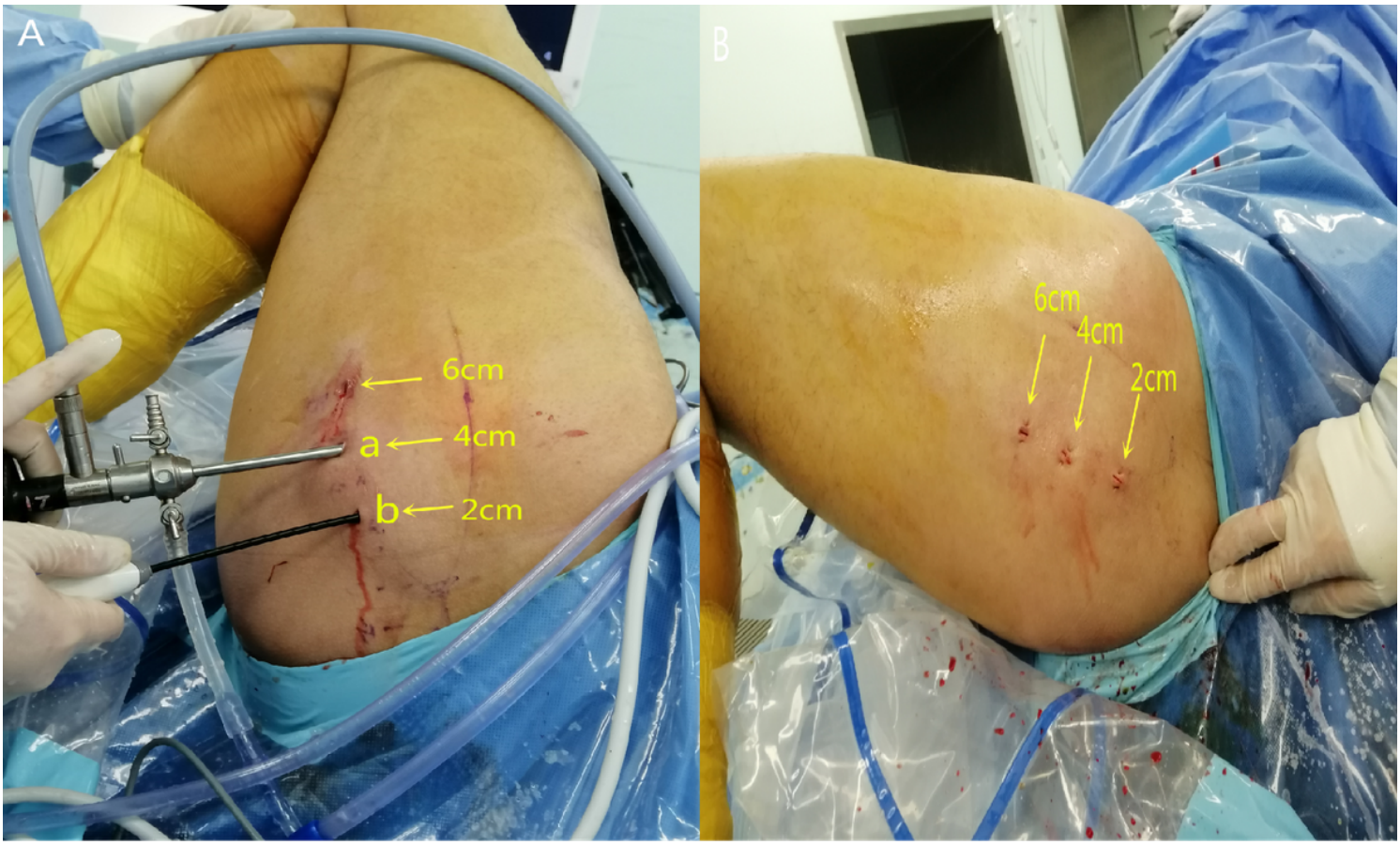

Figure 5

After the operation, the operation failed at 4 cm release plane and was successful at an extra 2 cm the release plane. A: Release plane at 2 cm and 4 cm. B: Suture three incisions after surgery.

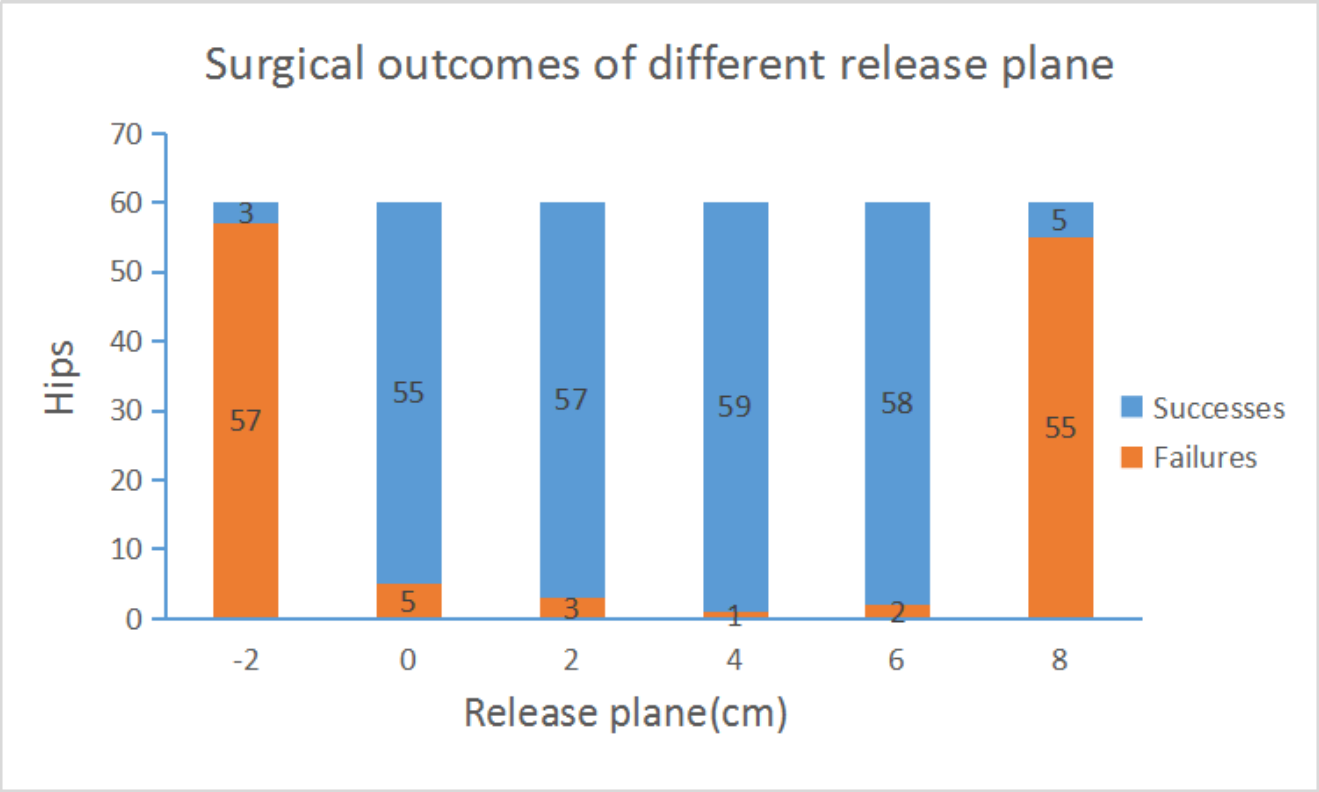

Figure 6

Number of hips with success and failure for different release planes

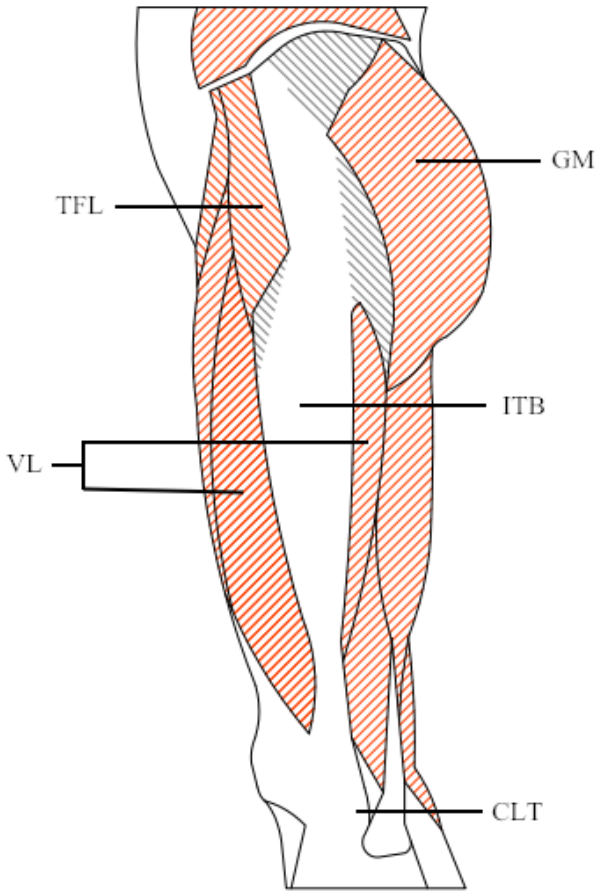

Figure 7

The side view of the left thigh shows the iliotibial band and its adjacent muscle marks.tensor fascia lata (TFL) ,gluteus maximus(GM),iliotibial band (ITB),Vastus lateralis (VL),Condylus lateralis tibiae(CLT)