

Suprainguinal Fascia Iliaca Block Accelerates General Anesthesia Recovery and Relieves Postoperative Pain in Elderly Patients After Total Hip Arthroplasty: A Retrospective Study

Yali Wang

the second affiliated hospital of xuzhou medical university

Yunqing Liu

the second affiliated hospital of xuzhou medical university

Hua Ni

the second affiliated hospital of xuzhou medical university

Xinlei Zhang

the second affiliated of xuzhou medical university

Li Ding

the second affiliated hospital of xuzhou medical university

Fei Tong

the second affiliated hospital of xuzhou medical university

Hongye Chen

the second affiliated hospital of xuzhou medical university

Xinhua Zhang

the second affiliated hospital of xuzhou medical university

Mingjian Kong (✉ mjkong@126.com)

Department of Anesthesiology, The Second Affiliated Hospital of Xuzhou Medical University, Xuzhou 221000, Jiangsu, People's Republic of China

Research article

Keywords: Suprainguinal fascia iliaca block, Elderly patients, Total hip arthroplasty, General anesthesia recovery, Postoperative pain

DOI: <https://doi.org/10.21203/rs.3.rs-60108/v1>

License: © ⓘ This work is licensed under a Creative Commons Attribution 4.0 International License.

[Read Full License](#)

Abstract

Background: Peripheral regional block combined with general anesthesia might be a preferable anesthetic regimen for elderly patients receiving total hip arthroplasty. To investigate whether suprainguinal fascia iliaca block accelerates recovery after general anesthesia and relieves early postoperative pain in elderly patients undergoing total hip arthroplasty.

Methods: Patients who underwent total hip arthroplasty under general anesthesia in 2015 or 2019 at the Second Affiliated Hospital of Xuzhou Medical University were retrospectively analyzed. The patients were grouped based on whether preoperative suprainguinal fascia iliaca block was performed. The time to tracheal extubation and spent in the post anesthesia care unit (PACU), intraoperative remifentanil dosage, fentanyl consumption in PACU, postoperative cumulative fentanyl consumption within 48 h after operation, visual analog scale (VAS) at rest and during movement on the first and second days after surgery, and adverse reactions were compared.

Results: Thirty-one patients were included in the study (block group:16, no-block group: 15). The VAS at rest and during movement on the first and second days were significantly lower in the block group than in the no-block group (all $P<0.05$). The intraoperative remifentanil dosage, fentanyl consumption given in PACU, and postoperative cumulative fentanyl consumption in 48 h after operation were lower in the block group (all $P<0.01$). The time to tracheal extubation and the time spent in PACU in the block group were shorter (all $P<0.01$).

Conclusion: Suprainguinal fascia iliaca block led to faster recovery after general anesthesia and early postoperative pain relief in elderly patients undergoing total hip arthroplasty.

Background

Hip fracture is a fracture of the upper portion of the femur, typically resulting in groin and thigh pain; if the fracture is displaced, manifested as shortened affected limb (with hip positioned in external rotation and abduction), and the patient is unable to bear weight [1, 2]. Adults > 65 years old most commonly present with hip fractures [1, 3]. With the aging of the population in China, the incidence of hip fractures in elderly individuals is also increasing [4, 5].

Surgical treatment, mainly total hip arthroplasty, is the preferred choice for treating hip fractures, and it effectively improves the quality of life of elderly patients, reduces complications such as pneumonia, bedsores, and lowers the mortality rate [1–3, 6]. Nevertheless, the declining physiological functions of important organs and systems or various complications in elder patients pose significant risks and challenges to the anesthesiologists during anesthesia and surgery.

Intraspinal anesthesia has advantages in orthopedic surgery of the lower limbs, such as intraoperative and postoperative analgesia, reducing postoperative opioids consumption [7], blood hypercoagulability [8], and pulmonary complications after total hip arthroplasty in patients with chronic obstructive

pulmonary disease (COPD) [9]. Nevertheless, the application of intraspinal anesthesia has some limitations, especially for elderly patients. For example, spinal puncture can be difficult or even fail in some elderly patients with spinal degeneration [10]; besides, the patients are often non-cooperative as intraspinal anesthesia causes pain, tension, and dementia [11]. Compared to intraspinal anesthesia, general anesthesia is often accompanied by more stable hemodynamics during hip fracture surgery [12], thus is an alternative anesthetic regimen for patients with hemodynamic instability, contraindication of intraspinal anesthesia, or failure of intraspinal block puncture.

Peripheral regional block combined with general anesthesia might be a preferable anesthetic regimen for elderly patients receiving total hip arthroplasty. This regimen reduces the incidences of postoperative delirium and early postoperative cognitive dysfunction [13]. Bullock et al. [14] described superior inguinal ligament fascia iliaca compartment block for the first time. This new method might block the lateral femoral cutaneous nerve more effectively than the traditional inferior inguinal ligament fascia iliaca compartment block, providing analgesia for incision after total hip arthroplasty.

The present study aimed to determine whether preoperative suprainguinal fascia iliaca block could accelerate recovery after general anesthesia and relieve the postoperative pain in elderly patients undergoing total hip arthroplasty. The results could provide a clinical support for the application of preoperative suprainguinal fascia iliaca block in these patients.

Methods

Study design and patients

This retrospective study was approved by the Ethics Committee of the Second Affiliated Hospital of Xuzhou Medical University. The need for individual consent was waived by the committee.

The inclusion criteria were: 1) underwent total hip arthroplasty in 2015 or 2019; 2) received general anesthesia before surgery; 3) 65–90 years of age; and 4) American Society of Anesthesiologists (ASA) grades I–II. The exclusion criteria were: 1) serious chronic diseases of the heart, lung, or brain; 2) history of chronic pain and chronic use of opioids; 3) history of related drug allergies; 4) intellectual or understanding disorders, unable to communicate normally; or 5) failure to complete the operation and was discharged from the hospital.

All included patients were divided into two groups based on whether preoperative suprainguinal fascia iliaca block was performed. No-block group: no suprainguinal fascia iliaca block was performed before the operation in 2015. Block group: suprainguinal fascia iliaca block was performed before the operation in 2019.

Procedure

All patients underwent ECG, peripheral oxygen oxygenation (SPO₂), invasive radial arterial pressure, end-tidal CO₂, and bispectral index (BIS) monitoring during the operation and underwent all surgical procedures under general anesthesia. The patients in the block group received suprainguinal fascia iliaca block 15 min before general anesthesia by the same anesthesiologist who was specifically trained in ultrasound-guided nerve block.

Suprainguinal fascia iliaca block was performed according to the method described by Bullock et al. [14], but was conducted under the guidance of an in-plane. The patient was placed in the supine position, and the position of the anterior superior iliac spine was marked. Routine gloving, disinfection, and draping were conducted. A high-frequency linear array probe (6–13 Hz, Sonosite) was applied to sterile ultrasound gel. The probe was transversely placed over the anterior superior iliac spine (Fig. 1). The hypoechoic image of the anterior superior iliac spine was shown on screen. The ultrasound probe was rotated towards the umbilicus until it clearly showed the anterior superior iliac spine, iliacus, fascia iliaca, medial internal oblique, transversus abdominis, and psoas major muscle. The suprainguinal fascia iliaca gap lies between the fascia iliaca and iliacus. Under ultrasound, using the in-plane technique, a 10-cm puncture needle was inserted from the umbilicus to the anterior superior iliac spine. When the tip of the needle reached the space between the fascia iliaca and iliacus (Fig. 2), 2 ml of normal saline was injected to expand the gap between the fascia iliaca and iliacus. Then, 20 ml of 0.375% ropivacaine was injected. The diffusion of the liquid up and down along the fascia iliaca and iliacus was monitored by ultrasound.

In the two groups, general anesthesia was induced with fentanyl 50 µg, propofol 1-1.5 mg/kg, rocuronium 0.6 mg/kg intravenously (i.v.), and 5 ml of 2% lidocaine on the supraglottic and subglottic surface before tracheal intubation. General anesthesia was maintained with sevoflurane 1.0-1.5%, and remifentanyl 0-0.3 µg/kg/min (according to the BIS and hemodynamics) and continued until skin closure. The patients were ventilated with 50/50 oxygen/air mixture through tracheal intubation to maintain an end-tide CO₂ between 35 and 45 mmHg. Before surgically suturing the skin, ondansetron 8 mg, ketochromic acid 30 mg, and fentanyl 15 µg were administered intravenously. During the operation, the vital signs were maintained at 80%-120% of baseline for systolic blood pressure (SBP) and 55–75 bpm for heart rate (HR). If necessary, vasoactive drugs such as phenylephrine, esmolol, urapidil, etc., were used to maintain the values.

After the operation, the patients were sent to the post anesthesia care unit (PACU), where they were monitored for at least 30 min. When the patients opened their eyes spontaneously, responded to verbal commands, and respiratory efforts were within the normal clinical range, the tracheal tube was removed. A bolus of 10 µg of fentanyl was intravenously given at 10-min intervals until the visual analog score (VAS) was < 4. The level of sedation was recorded as Ramsay scores. If the patients experienced severe sedation or had a Ramsay sedation score of > 5 or respiratory depression, then the fentanyl administration was discontinued. When the patients were fully awake and had stable VAS of ≤ 4, they could be transferred to the general ward. All patients were provided with a patient-controlled intravenous analgesia (PCIA) pump with a 10-µg fentanyl bolus and a 20-min lockout period with no background.

Data Collection

The baseline data of the patients enrolled, such as age, sex, body mass index, ASA grades, and adverse events after surgery were collected. Besides, the intraoperative remifentanyl dosage, time to tracheal extubation, time spent in PACU, fentanyl dosage given by intravenous titration in PACU and given by PCIA within 48 h after surgery, VAS score (with 0 indicating no pain and 10, the worst imaginable pain) at rest and during movement on the first and second days after surgery, any complications and adverse events within 48 h after surgery were recorded.

Statistical analysis

Statistical analysis was performed using SPSS 17.0 (SPSS Inc., Chicago, USA). The Kolmogorov-Smirnov test was used to determine the normal distribution of continuous data. Normally distributed data were presented as means \pm standard deviations and analyzed using Student's t-test. Continuous data with a skewed distribution were presented as medians (interquartile range) and analyzed using the Mann-Whitney U-test. Categorical data were presented as numbers and percentages and were compared using the chi-square test or Fischer's exact test. Two-sided (except for the chi-square test) P-values < 0.05 were considered statistically significant.

Results

Characteristics of the patients

In this study, 15 patients who underwent the surgery in 2015 were included in the no-block group and 16 patients who received the surgery with preoperative suprainguinal fascia iliaca block in 2019 were included in the block group. Suprainguinal fascia iliaca block were performed successfully and all the patients in the block group showed decrease or disappearance of skin sensation to cold stimuli 15 minutes after the nerve block in the lateral thigh region. There were no significant differences in age ($P = 0.74$), body mass index ($P = 0.739$), sex ($P = 0.553$), ASA ($P = 0.398$), and operation time ($P = 0.747$) between the two groups (Table 1).

Table 1
Characteristics of the patients

Characteristics	No-block group (n = 15)	Block group (n = 16)	P
Age (years)	80.1 ± 4.2	79.6 ± 4.2	0.740
Body mass index (kg/m ²)	22.4 ± 2.3	22.2 ± 2.2	0.739
Male/female	10/5	10/6	0.553
ASA □/□	11/4	10/6	0.398
Duration of surgery (min)	60.3 ± 6.9	59.5 ± 8.3	0.747
ASA: American Society of Anesthesiologists.			

Suprainguinal Fascia Iliaca Block Relieves Postoperative Pain

The intraoperative remifentanil dosage (103.0 ± 37.9 vs. 316.0 ± 62.5 µg, P < 0.01), fentanyl consumption given by intravenous titration in PACU (1.9 ± 4.0 vs. 22 ± 8.6 µg, P < 0.01), and postoperative cumulative fentanyl consumption by PCIA in 48 h after operation (204.3 ± 43.0 vs. 406.6 ± 70.9 µg, P < 0.01) were significantly lower in the block group than in the no-block group (Table 2). The VAS at rest and during movement on the first and second days were significantly lower in the block group than in the no-block group (all P < 0.05) (Table 3).

Table 2
The use of intraoperative and postoperative analgesics.

Analgesics	No-block group (n = 15)	Block group (n = 16)	P
intraoperative remifentanil dose (µg)	316.0 ± 62.5	103 ± 37.9	< 0.01
Fentanyl given by intravenous titration in the PACU (µg)	22 ± 8.6	1.9 ± 4.0	< 0.01
Fentanyl consumption by PCIA device in 48 h after operation (µg)	406.6 ± 70.9	204.3 ± 43.0	< 0.01
PACU: post anesthesia care unit; PCIA: patient-controlled intravenous analgesia.			

Table 3
Postoperative VAS during rest and movement

Postoperative time (d)	VAS during rest			VAS during movement		
	No-block group	Block group	P	No-block group	Block group	P
	(n = 15)	(n = 16)		(n = 15)	(n = 16)	
1st	3.6 ± 0.5	2.7 ± 0.4	< 0.01	4.9 ± 0.7	3.4 ± 0.5	0.011
2nd	3.4 ± 0.6	3.0 ± 0.6	< 0.01	4.2 ± 0.8	3.4 ± 0.5	0.002

1st : the first day after operation; 2nd: the second day after operation; VAS: visual analog score.

Suprainguinal Fascia Iliaca Block Accelerates General Anesthesia Recovery

The time to tracheal extubation (17.1 ± 2.2 vs. 28.0 ± 2.8 min, $P < 0.01$) and the time spent in PACU (39.7 ± 9.0 vs. 68 ± 9.4 min, $P < 0.01$) in the block group were significantly shorter than in the no-block group (Table 4).

Table 4
Complications and adverse events.

Complications and adverse events	No-block group (n = 15)	Block group (n = 16)	P
Dizziness, n (%)	6 (40)	1 (6.25)	0.037
Postoperative nausea and vomiting, n (%)	3 (20)	1 (6.25)	0.333
Respiratory depression, n (%)	0	0	/
Severe sedation, n (%)	0	0	/

Complications And Adverse Events

Respiratory depression and severe sedation were not observed in either of the groups. No infection of the puncture point and local hematoma was observed in the block group. The incidence of postoperative nausea and vomiting was similar in the two groups ($P = 0.333$). The incidence of dizziness was higher in the no-block group than in the block group ($P = 0.037$) (Table 1).

Discussion

This study examined whether suprainguinal fascia iliaca block can accelerate recovery after general anesthesia and relieve early postoperative pain in elderly patients undergoing total hip arthroplasty. The results suggest that ultrasound-guided in-plane suprainguinal fascia iliaca block led to faster recovery after general anesthesia and early postoperative pain relief in elderly patients undergoing unilateral total hip arthroplasty.

The innervation of the hip joint is complex and the sensation of skin incision during total hip arthroplasty is mainly innervated by the lateral femoral cutaneous nerve. A complete lateral femoral cutaneous nerve block provides good postoperative incision analgesia for hip surgery [15]. The fascia iliaca compartment is a potential space for anesthesia that was initially proposed by Dalens et al. in 1989 [16]. It is simple to operate and does not directly involve an injection into the nerve, lowering the risk of neurovascular injury. It is currently the most widely used peripheral nerve block regimen for postoperative analgesia of the lower limbs. Previous studies confirmed that single or continuous block provides good postoperative analgesia for lower limb surgery, such as for the knee joints [14, 17–23].

However, the failure rate of lateral femoral cutaneous nerve block in the fascia iliaca compartment block remains as high as 13%-37% [16, 17, 19], and the greater variability of this lateral femoral cutaneous nerve below the inguinal ligament might be the cause of failure. Autopsy studies revealed that the lateral femoral cutaneous nerve either run on the superficial, middle, and deep inside the inguinal ligament or run on the lateral side of the inguinal ligament within 0–9 cm [22, 24, 25]. In contrast to this, the lateral femoral cutaneous nerve has a relatively stable route distribution in the pelvic region above the inguinal ligament that passes between the iliacus and fascia iliaca [26]. Hebbard et al. [20] revealed the distribution of the dye around the lateral femoral cutaneous nerve of the pelvic region after inserting a needle from the inferior inguinal ligament, passing through the inguinal ligament, and reaching the fascia iliaca above the inguinal ligament. And previous studies confirmed the feasibility and effectiveness of performing fascia iliaca compartment block here [18, 21, 23].

In the present study, the patients who received suprainguinal fascia iliaca block had faster anesthesia recovery and significantly lower postoperative VAS than those without peripheral nerve block. Those results suggest that general anesthesia combined with suprainguinal fascia iliaca block might be considered more suitable for elderly patients with poor baseline conditions. It can also accelerate the recovery from general anesthesia, relieve early postoperative pain, and reduce complications. In addition to effectiveness, the safety of suprainguinal fascia iliaca block was verified. During surgery, the higher needle insertion point of the fascia iliaca block between the anterior superior iliac spine and umbilicus remains far from the surgical incision and inguinal ligament, reducing the surgeons' concerns about puncture-induced incision infection. Besides, suprainguinal fascia iliaca block reduced the incidence of complications and adverse events in elderly patients undergoing unilateral total hip arthroplasty.

This study has limitations. One of them is the small number of cases. Besides, since this was a retrospective study, the analgesic effect and time course were not compared at different concentrations of local anesthetics. Finally, the patients were not included continuously because of technical and

conditional restrictions. The technology of ultrasound-guided nerve block was not available in hospital until 2019. Although the low iliac fascia nerve blocks were used during 2015–2019, the effect is not stable. So the patients in the block group were operated in 2019, while those in the no-block group were operated in 2015, which could lead to a bias inevitable.

Conclusions

In conclusion, ultrasound-guided in-plane suprainguinal fascia iliaca block in elderly patients undergoing unilateral total hip arthroplasty might accelerate the recovery after general anesthesia and relieve early postoperative pain. This method could be a reliable method and could lead to better outcomes in elderly patients.

List Of Abbreviations

SF, suprainguinal fascia

PACU, postanesthesia care unit

VAS, visual analog score

COPD, chronic obstructive pulmonary disease

ASA, American Society of Anesthesiologist

BIS, bispectral index

SBP, systolic blood pressure

HR, heart rate

CTA, computed tomographic angiography

ASIS, anterior superior iliac spine

IM, iliacus muscle

IO, internal oblique muscle

TA, transverse abdominus muscle

FI, Fascia iliaca

PCIA, patient-controlled intravenous analgesia

Declarations

Ethics approval and consent to participate

This retrospective study was approved by the Ethics Committee of the Second Affiliated Hospital of Xuzhou Medical University. The need for individual consent was waived by the committee.

Consent for publication

Not applicable

Availability of data and materials

Data sharing is not applicable to this article as no new data were created or analyzed in this study.

Competing interests

The authors declare that they have no competing interests

Funding

Not applicable

Authors' contributions

KMJ, WYL and LYQ participated in interpretation of data, drafted and critically revised the manuscript. KMJ, WYL, LYQ and NH contributed to study design, interpretation of data, and critically revised the manuscript. ZXL, DL and TF analyzed and assisted in interpretation of the data and assisted in drafting the manuscript. CHY and ZXH contributed to interpretation of data and critically revised the manuscript. All authors read and approved the final manuscript.

Acknowledgements

Not applicable

References

1. Florschütz AV, Langford JR, Haidukewych GJ, Koval KJ. Femoral neck fractures: current management. *J Orthop Trauma*. 2015;29:121-9.
2. Sheehan SE, Shyu JY, Weaver MJ, Sodickson AD, Khurana B. Proximal Femoral Fractures: What the Orthopedic Surgeon Wants to Know. *Radiographics*. 2015;35:1563-84.
3. LeBlanc KE, Muncie HL, Jr., LeBlanc LL. Hip fracture: diagnosis, treatment, and secondary prevention. *Am Fam Physician*. 2014;89:945-51.
4. Xia WB, He SL, Xu L, Liu AM, Jiang Y, Li M, et al. Rapidly increasing rates of hip fracture in Beijing, China. *J Bone Miner Res*. 2012;27:125-9.

5. Chen W, Lv H, Liu S, Liu B, Zhu Y, Chen X, et al. National incidence of traumatic fractures in China: a retrospective survey of 512 187 individuals. *Lancet Glob Health*. 2017;5:e807-e17.
6. SooHoo NF, Farnig E, Chambers L, Zmigmond DS, Lieberman JR. Comparison of complication rates between hemiarthroplasty and total hip arthroplasty for intracapsular hip fractures. *Orthopedics*. 2013;36:e384-9.
7. Harsten A, Kehlet H, Ljung P, Toksvig-Larsen S. Total intravenous general anaesthesia vs. spinal anaesthesia for total hip arthroplasty: a randomised, controlled trial. *Acta Anaesthesiol Scand*. 2015;59:298-309.
8. Song B, Qiao Y, Jiang H, Yan X. Effects of neuraxial and general anaesthesia for total joint arthroplasty: a meta-analysis. *Journal of Clinical Anesthesiology*. 2017;33:52-8.
9. Neuman MD, Silber JH, Elkassabany NM, Ludwig JM, Fleisher LA. Comparative effectiveness of regional versus general anesthesia for hip fracture surgery in adults. *Anesthesiology*. 2012;117:72-92.
10. Keorochana G, Taghavi CE, Tzeng ST, Morishita Y, Yoo JH, Lee KB, et al. Magnetic resonance imaging grading of interspinous ligament degeneration of the lumbar spine and its relation to aging, spinal degeneration, and segmental motion. *J Neurosurg Spine*. 2010;13:494-9.
11. Apan A, Apan O. *Complications in Spinal Anaesthesia*. Whizar-Lugo V, editor. London: IntechOpen; 2014.
12. Parker MJ, Handoll HH, Griffiths R. Anaesthesia for hip fracture surgery in adults. *Cochrane Database Syst Rev*. 2004:CD000521.
13. Mei B, Zha H, Lu X, Cheng X, Chen S, Liu X, et al. Peripheral Nerve Block as a Supplement to Light or Deep General Anesthesia in Elderly Patients Receiving Total Hip Arthroplasty: A Prospective Randomized Study. *Clin J Pain*. 2017;33:1053-9.
14. Bullock WM, Yalamuri SM, Gregory SH, Auyong DB, Grant SA. Ultrasound-Guided Suprainguinal Fascia Iliaca Technique Provides Benefit as an Analgesic Adjunct for Patients Undergoing Total Hip Arthroplasty. *J Ultrasound Med*. 2017;36:433-8.
15. Liu SS, Ngeow JE, Yadeau JT. Ultrasound-guided regional anesthesia and analgesia: a qualitative systematic review. *Reg Anesth Pain Med*. 2009;34:47-59.
16. Dalens B, Vanneuville G, Tanguy A. Comparison of the fascia iliaca compartment block with the 3-in-1 block in children. *Anesth Analg*. 1989;69:705-13.
17. Capdevila X, Biboulet P, Bouregba M, Barthelet Y, Rubenovitch J, d'Athis F. Comparison of the three-in-one and fascia iliaca compartment blocks in adults: clinical and radiographic analysis. *Anesth Analg*. 1998;86:1039-44.
18. Desmet M, Vermeylen K, Van Herreweghe I, Carlier L, Soetens F, Lambrecht S, et al. A Longitudinal Supra-Inguinal Fascia Iliaca Compartment Block Reduces Morphine Consumption After Total Hip Arthroplasty. *Reg Anesth Pain Med*. 2017;42:327-33.
19. Foss NB, Kristensen BB, Bundgaard M, Bak M, Heiring C, Virkelyst C, et al. Fascia iliaca compartment blockade for acute pain control in hip fracture patients: a randomized, placebo-controlled trial.

- Anesthesiology. 2007;106:773-8.
20. Hebbard P, Ivanusic J, Sha S. Ultrasound-guided supra-inguinal fascia iliaca block: a cadaveric evaluation of a novel approach. *Anaesthesia*. 2011;66:300-5.
 21. Kumar K, Pandey RK, Bhalla AP, Kashyap L, Garg R, Darlong V, et al. Comparison of conventional infrainguinal versus modified proximal suprainguinal approach of Fascia Iliaca Compartment Block for postoperative analgesia in Total Hip Arthroplasty. A prospective randomized study. *Acta Anaesthesiol Belg*. 2015;66:95-100.
 22. Martins RS, Siqueira MG, Silva FC, Jr., Heise CO, Teixeira MJ. A practical approach to the lateral cutaneous nerve of the thigh: an anatomical study. *Clin Neurol Neurosurg*. 2011;113:868-71.
 23. Swenson JD, Davis JJ, Stream JO, Crim JR, Burks RT, Greis PE. Local anesthetic injection deep to the fascia iliaca at the level of the inguinal ligament: the pattern of distribution and effects on the obturator nerve. *J Clin Anesth*. 2015;27:652-7.
 24. Aszmann OC, Dellon ES, Dellon AL. Anatomical course of the lateral femoral cutaneous nerve and its susceptibility to compression and injury. *Plast Reconstr Surg*. 1997;100:600-4.
 25. Benezis I, Boutaud B, Leclerc J, Fabre T, Durandeau A. Lateral femoral cutaneous neuropathy and its surgical treatment: a report of 167 cases. *Muscle Nerve*. 2007;36:659-63.
 26. Shteynberg A, Riina LH, Glickman LT, Meringolo JN, Simpson RL. Ultrasound guided lateral femoral cutaneous nerve (LFCN) block: safe and simple anesthesia for harvesting skin grafts. *Burns*. 2013;39:146-9.

Figures

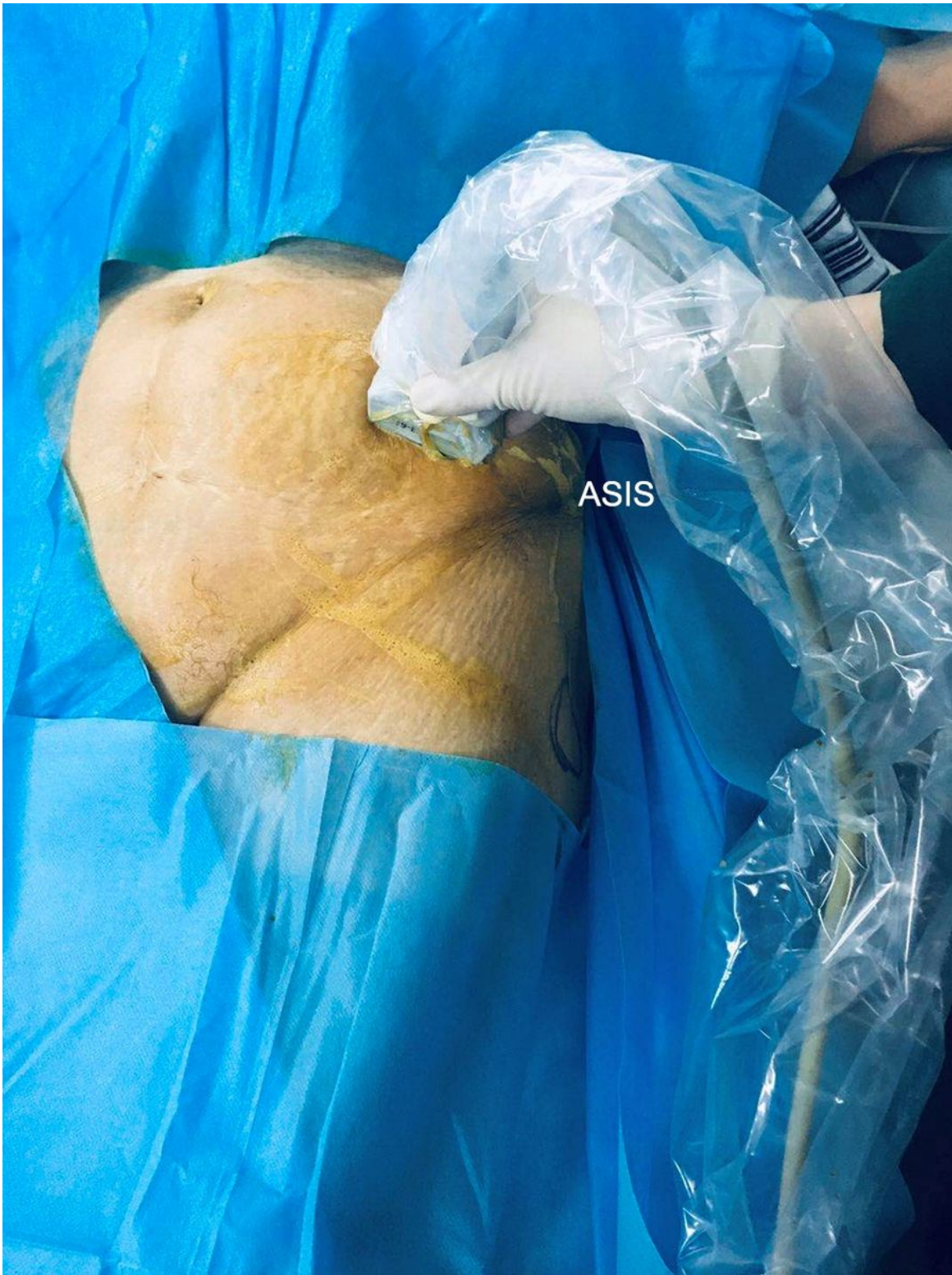

Figure 1

Position of the ultrasound probe.

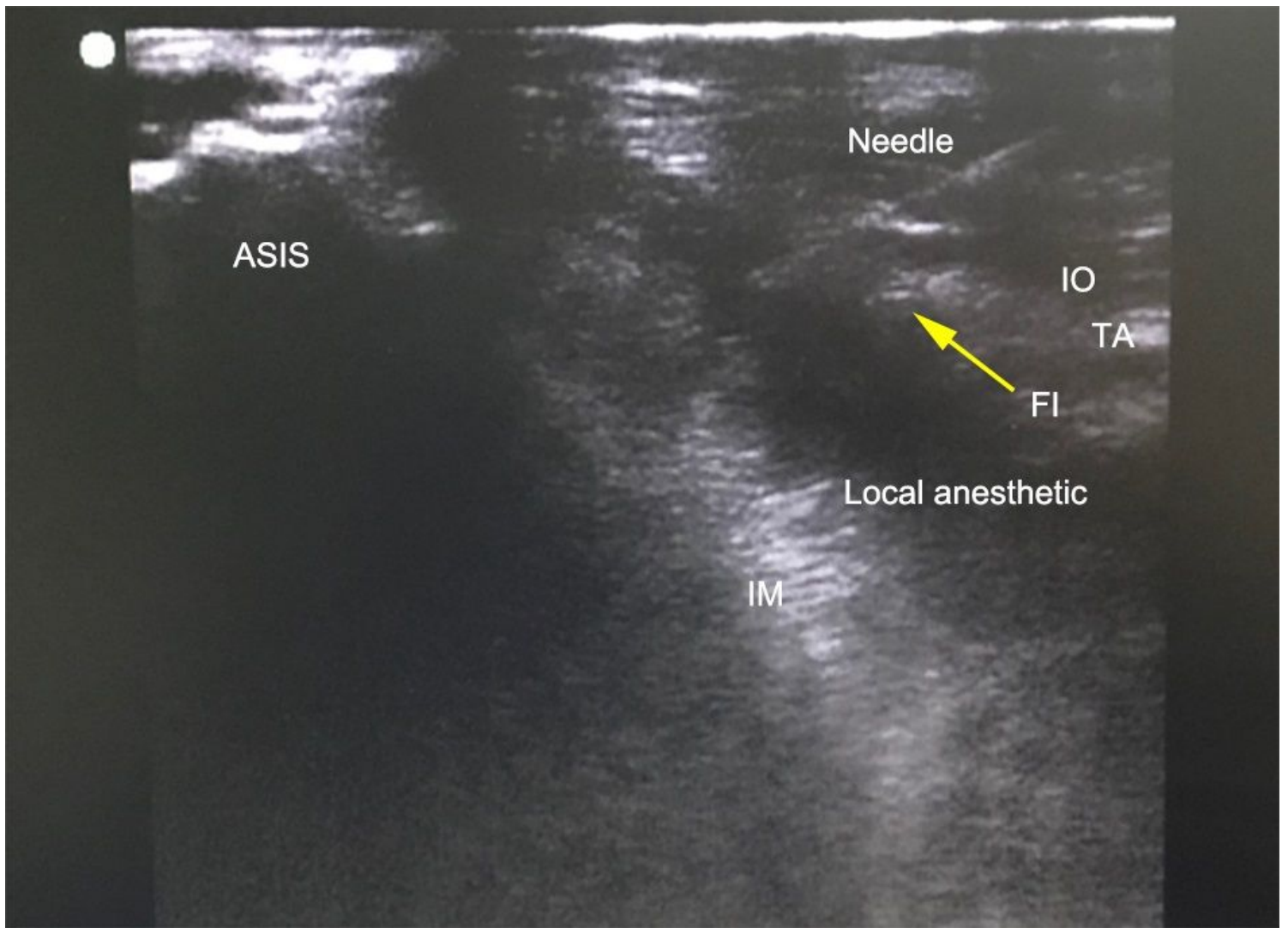


Figure 2

The location of the puncture needle and the diffusion of local anesthetic under the iliac fascia showed by the in-plane technique. ASIS: anterior superior iliac spine; IM: iliacus muscle; IO: internal oblique muscle; TA: transverse abdominus muscle; FI: Fascia iliaca.