

Chordoid Glioma of the Third Ventricular with Rare Patterns and Mutation in PRKCA: a case report and review of literature

xiaomei ma (✉ maxiaomei2001@126.com)

zhi zhu

Changzheng Hospital

yin wang

Huashan Hospital Fudan University Department of Integrative Medicine

weiqing li

Changzheng Hospital

Case Report

Keywords: chordoid glioma, alveolar, pseudoglandular, papillary, fusiform, fibrosing

Posted Date: October 19th, 2020

DOI: <https://doi.org/10.21203/rs.3.rs-59341/v3>

License: © ⓘ This work is licensed under a Creative Commons Attribution 4.0 International License.

[Read Full License](#)

Abstract

Background: Chordoid gliomas are rare, low-grade neoplasms of the third ventricle. In the updated 4th edition of the 2016 WHO classification of tumours of the CNS, it described some three less common histological patterns and rare tissue patterns.

Case presentation: Here we reported a case with all the uncommon patterns. It was a 52-year-old woman with dizziness and blurred vision. Imaging showed a solid tumor located in the third ventricle with a well-circumscribed border. Histological, almost tumor cells formed into atypical glands with different sizes and irregular shapes in an abundant of solid or loosely collagen matrix. Some tumor cells formed into papillary patterns, micro-papillary patterns. pseudoglandular patterns. Some focal tumor cells were spindle-shape. Only few epithelioid tumor cells formed into clusters and cords embedded into a myxoid stroma like the chordoma. No anaplastic features were identified in any lesion. Immunohistochemically, all the tumor cells were strong reactivity for TTF-1. Some tumor cells strong but focal reactivity for GFAP, NEU-N, and CD34. It showed a recurrent D463H missense mutation in PRKCA. All these findings confirm that the diagnosis was chordoid glioma of the third ventricular.

Conclusions: There may be lots of histopathological features in one chordoid glioma case. It maybe suggested that PRKCA D463H mutation and TTF-1 positive may help to diagnose it.

Background

Chordoid gliomas of the third ventricular are extremely rare entities in the central nervous system. Histologically, they are most often composed of clusters and cords of epithelioid tumor cells within a variably mucinous stroma. It was reported in the literature that it also had a rare special histological structure, such as papillary [5]. Here we report a case with less common and rare patterns such as papillary, alveolar, pseudoglandular, solid, fusiform and fibrosing. Till now, we had no found a case in the literature with all these histological structures.

Case Presentations

A 52-year-old woman presented with dizziness and blurred vision for six months without causative factor. The patient did not have any other discomforts. The general physical and neurological examination was normal. CT scans showed that there was a solid tumor in the third ventricle with densely enhanced and characteristically exhibited a well-circumscribed border (Fig 1). The MRI scan showed that isointensity on T1WI, and hyperintensity on T2WI. After Gd-diethylenetriamine pentaacetic acid (Gd-DTPA) administration, the tumor showed homogeneous (Fig 2). The MRI diagnosis was germ cell tumor.

During surgery, the tumor located at the optic cross and the end plate pool, which pushing the bilateral optic nerves downward. The tumor was hard with rich blood supply. It adhered to the surrounding tissues tightly. The patient had gross total resection. In gross specimen, the tumor tissue was grayish yellow and broken into piles with the size 2.5x1.0x1.0cm.

Microscopically, the border between the tumor and adjacent brain was well defined, with no evidence of tumor infiltration (Fig 3). There were many histological patterns. We introduced them according to the proportion of these histological patterns. Almost tumor cells formed into various forms glands with different sizes and irregular shapes invading the fibrous stroma (Fig 4). The tumor cells cubic or polygonal, some cells have long protrusions linked to the wall of the ducts. Cells have abundant cytoplasmic eosinophils (Fig 5). In some areas there were rare tumor cells formed into clusters or cords or gland in an abundant of solid or loosely collagen matrix (Fig5, 6). Some tumor cells arranged along the central fibrovascular core and formed into papillary structures and even secondary papillaries. The tumor cells anchored to blood vessels by short, stout cytoplasmic processes. Unipolar cytoplasmic processes anchor neoplastic cells to stromal blood vessels in formations of radial, papillary or ribboned profiles. These columnar or subtly tapered processes were shorter and stouter than those of perivascular pseudorosettes and do not collect as an ependyma pseudorosettes which with anuclear zones (Fig 7). Many tumor cells have nuclear inclusions and nuclear grooves (Fig 8). Some areas the tumor cells formed into micro-papillary structures (Fig 9). The cytoplasm of some tumor cells was vacuolated. The nucleus located at the edge of the cell. These cytoplasmic vacuole-like cells came together to form a pseudoglandular (Fig 10). There were some focal areas that the tumor cells were spindle-shaped. This pattern made the tumor parenchyma and stroma was unclear (Fig 11). There were few areas that the epithelioid tumor cells formed into clusters and cords embedded into a myxoid stroma like the chordoma (Fig 12). There were varied degrees lymphoplasmacytic infiltrate in the tumor and the periphery brain tissue (Fig 13). No anaplastic features were identified in any lesion. Mitotic figures were absent in the tumor.

Immunohistochemically, all the tumor cells were strong reactivity for TTF-1 (Fig 14). Some tumor cells strong but focal reactivity for GFAP (Fig 15), NEU-N (Fig 16), and CD34. Few tumor cells were slightly reactivity for CKp, EMA and Syn. All the tumor cells were negative for PLAP, CD117, AFP, CD30, CD15, PR, Villin, CK7, CK20, Tg, NapA, P63, CgA, HCG, PRL, TSH, LH, FSH, Olig-1, H3k27m, STAT-6, E-cadherin, p53 and D2-40. The percentage of Ki67 positive cells was approximately 3%.

Here we performed genomic profiling on the case. It identified a recurrent D463H missense mutation in PRKCA, which localizes in the kinase domain of the encoded protein kinase C alpha (PKCα) (Fig 17).

The pathological diagnosis was chordoid glioma of the third ventricular.

The patient was alive 15 months after surgery without any adjuvant therapy.

Discussion

To date, approximately 100 cases of chordoid glioma have been reported in the literatures. They most occur frequently in adults. Chordoid gliomas occupy the anterior portion of the third ventricle, with larger tumors also filling the middle and posterior aspects. They generally arise in the midline and displace normal structures in all directions as they enlarge (2). While there were a few reports that chordoid glioma located outside the third ventricle, such as hemisphere, thalamus, parieto-temporal extra-ventricular,

juxtaventricula et al (8). This made the diagnosis difficult and had challenges. Considering these entities may be not limited to the third ventricle, the nomenclature may require an amendment with more clinical and radiological evidence supports.

Most chordoid glioma patients had signs and symptoms of obstructive hydrocephalus, including headache, nausea, vomiting and ataxia. Other clinical features include endocrine abnormalities reflecting hypothalamic compression, visual field disturbances due to compression/displacement of the optic chiasm, and personality changes including psychiatric symptoms and memory abnormalities.

In imaging, chordoid gliomas present as solid or cystic-solid and characteristically exhibit a well-circumscribed border within the third ventricle. On MRI, the solid portion of tumors showed isointense or hypointensity on T1-weighted and hyperintensity in most cases on T2WI. (8).

In microscopy, chordoid gliomas are most often composed of clusters and cords of epithelioid tumor cells within a variably mucinous stroma that typically contains a lymphoplasmacytic infiltrate. Neoplastic nuclei are moderate in size, ovoid, and relatively uniform. Mitoses are absent in most tumors, when present, they are rare. A stroma lymphoplasmacytic infiltrate, often containing numerous Russell bodies, is a consistent finding. In the updated 4th edition of the WHO Classification of Tumours of the CNS (2016) (4) described that maybe there were three less common histological patterns had been reported: a solid pattern with sheets of polygonal epithelioid tumor cells without mucinous stroma, a fusiform pattern with groups of spindle-shaped cells among loose collagen, and a fibrosing pattern with abundant fibrosis. The fibrosing pattern tends to be more common in older patients. Other (rare) tissue patterns include papillary [3], alveolar, and pseudoglandular patterns. Individual tumor cells have abundant eosinophilic cytoplasm. In some cases, limited glial differentiation in the form of coarsely fibrillar processes can also be seen. Reactive astrocytes, Rosenthal fibres, and often chronic inflammatory cells including lymphocytes, plasma cells, and Russell bodies are seen in adjacent non-neoplastic tissue. In our case, there were common pattern and three less common patterns and three rare patterns. Such case was really rare.

The immunohistochemical feature of chordoid glioma is the tumor cells strong reactivity for GFAP, vimentin and TTF-1. CD34 is positive focally. Immunoreactivity for S100, EMA and cytokeratin is variable. Neuronal and neuroendocrine markers, such as synaptophysin, neurofilaments, and chromograin-A, are consistently negative. The proliferation is low. Neither IDH mutation nor BRAF V600E mutation were found in the literature. In our case, there were focal tumor cells positive for NeuN which had no related literature reports retrieved.

Goode et al reported that all the 13 chordoid gliomas had a recurrent D463H missense mutation in PRKCA, which localizes in the kinase domain of the encoded PKC α (2). Our case had D463H missense mutation and had no D294G mutation in PKC α .

Differential diagnosis of histopathology

1. Adenocarcinoma brain metastases: The patient has a history of adenocarcinoma of other organs. Immunohistochemical, the CKp was strong positive.
2. Pituitary ependymoma: At present, only 10 pituitary ependymoma cases with TTF-1 positive have been reported in the English literature. All these cases located in the pituitary (7).
3. Ependymoma of the third ventricle: The ependymoma of the third ventricle was positive for TTF-1 in the literature reported. While it's histology was typical morphology of the ependymoma (9).
4. Meningiomas: Meningiomas maybe have adenoid structures. However, in immunohistochemical, EMA is diffusely positive and TTF-1 is negative.
5. Pituitary adenoma: The histology of the tumor is adenoid structures, but the tumor is located in the pituitary gland. Immunohistochemical, the tumor cells are strongly diffuse positive for Syn and negative for TTF-1.
6. Solitary fibrous tumor/haemangiopericytoma: Histologically, they are maybe have adenoid structures in some area. Immunohistochemically, the tumor cells are positive for STAT-6 and negative for TTF-1.

The ultrastructural demonstration of microvilli and hemidesmosome-like structures in chordoid glioma support an ependymal histogenesis. Further evidence of ependymal or specialized ependymal differentiation has been supplied by a report of abnormal cilia in a juxtanuclear location (6). The presence of a cytological zonation pattern and secretory vesicles indicated a specialized ependymal differentiation, as might be expected of cells derived from a circumventricular organ such as the lamina terminalis. A recent study reported strong expression of TTF-1 in both chordoid gliomas and the organum vasculosum of the lamina terminalis, suggesting an organum vasculosum origin (1).

Chordoid gliomas are histologically low-grade. Gross total resection is the treatment of choice and can result in long-term recurrence-free survival. However, the tumors location in the third ventricle and their attachment to hypothalamic and suprasellar structures often make complete resection impossible. Postoperative tumor enlargement has been noted in half of all patients who undergo subtotal resection. Among the reported cases of chordoid gliomas, approximately 20% of the patients died in the perioperative period or from tumor regrowth (3).

Abbreviations

Gd-DTPA : Gd-diethylenetriamine pentaacetic acid

PKCα: protein kinase C alpha

Declarations

Acknowledgments

We thank Shanghai Ackerman Medical Laboratory for helping us with the PRKCA genetic test Authors' contributions

MXM and ZZ designed the experiments, interpreted the results and wrote the manuscript. WY guided experiments. LWQ performed the experiments. All authors read and approved the final manuscript.

Availability of data and materials

The authors confirm that the data supporting the findings of this study are available within the article.

Ethics approval and consent to participate

This study was approved by the Pathology Department of Changzheng Hospital of Naval Military Medical University, China. Written informed consent was obtained from each subject.

Consent for publication

All authors consent to the publication of the manuscript in Diagnostic Pathology.

Competing interests

The authors declare that they have no competing interests

References

1. Bielle F1, Villa C, Giry M, Bergemer-Fouquet AM, Polivka M, Vasiljevic A, Aubriot-Lorton MH et al (2015) Chordoid gliomas of the third ventricle share TTF-1 expression with organum vasculosum of the lamina terminalis. *Am J Surg Pathol* 39:948-56.
2. Goode B, Mondal G, Hyun M, Ruiz DG, Lin YH, Van Ziffle J, et al (2018). A recurrent kinase domain mutation in PRKCA defines chordoid glioma of the third ventricle. *Nat Commun* 23:810 .
3. Kurian KM1, Summers DM, Statham PF, Smith C, Bell JE, Ironside JW (2005). Third ventricular chordoid glioma: clinicopathological study of two cases with evidence for a poor clinical outcome despite low grade histological features. *Neuropathol Appl Neurobiol* 31:354-61.
4. Louis DN, Ohgaki H, Wiestler OD, Cavenee WK, Ellison D, Figarella-Branger D, et al (2016) WHO classification of tumours of the central nervous system. Revise 4th edition. Lyon: IARC Press
5. Ni HC, Piao YS, Lu GH, Fu YJ, Ma XL, Zhang XJ (2013) Chordoid glioma of the third ventricle: Four cases including one case with papillary features. *Neuropathology* 33: 134–9.
6. Pasquier B, Péoc'h M, Morrison AL, Gay E, Pasquier D, Grand S, et al (2002). Chordoid glioma of the third ventricle: a report of two new cases, with further evidence supporting an ependymal differentiation, and review of the literature. *Am J Surg Pathol* 26:1330-42.
7. Wang S, Zong W, Li Y, Wang B, Ke C, Guo D (2018). *Pituitary Ependymoma: A Case Report and Review of the Literature*. *World Neurosurg* 110:43-54.
8. Yang, B, Yang, C, Du, J, Fang J, Li G, Wang S, et al (2019) Chordoid glioma: an entity occurring not exclusively in the third ventricle. *Neurosurg Rev* <https://doi:10.1007/s10143-019-01161-w>

9. Zamecnik J, Chanova M, Kodet R (2004) Expression of thyroid transcription factor 1 in primary brain tumours. J Clin Pathol 57:1111– 3.

Figures

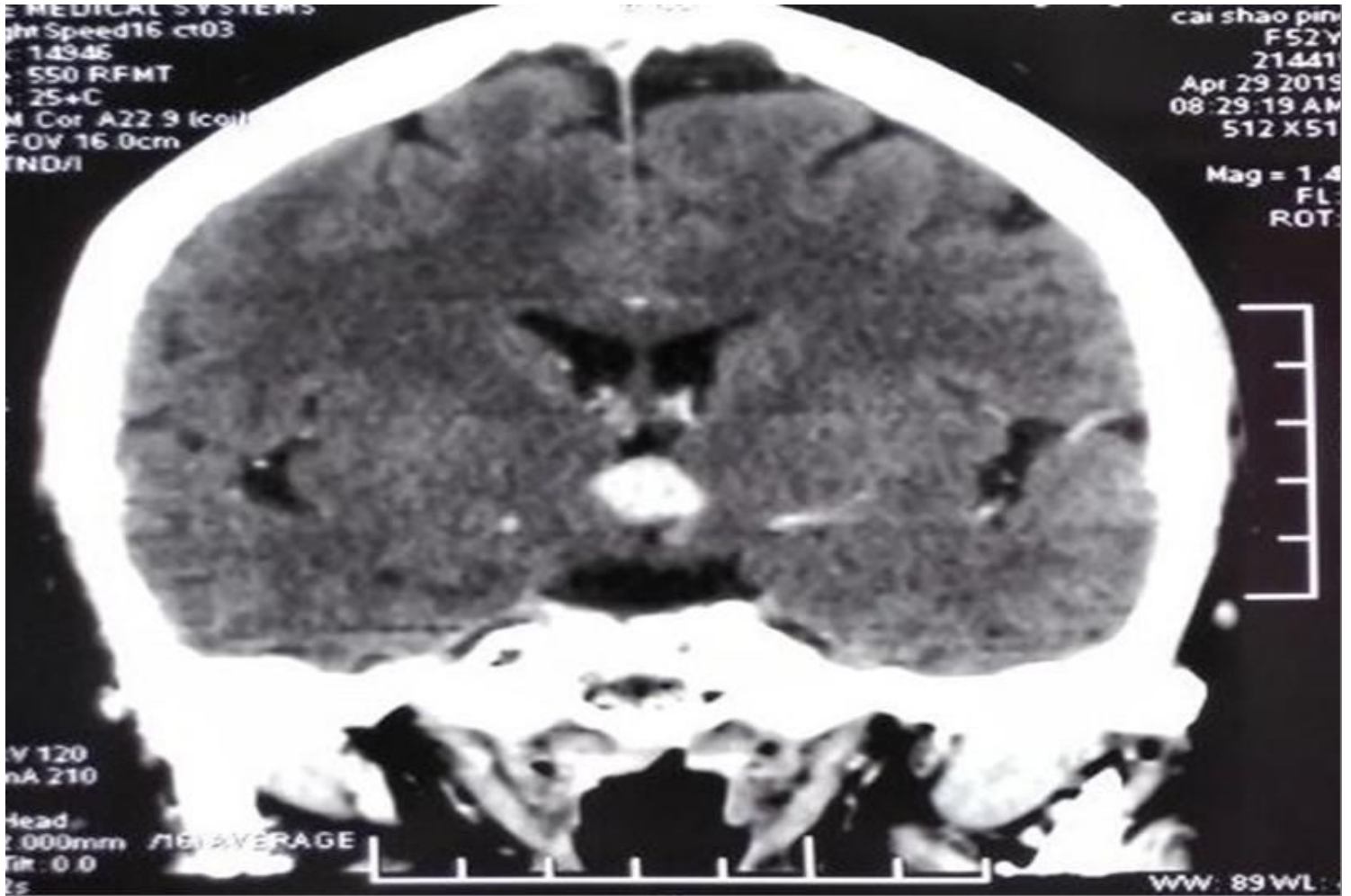


Figure 1

CT scans showed that there was a solid tumor in the third ventricle with densely enhanced and characteristically exhibited a well-circumscribed border

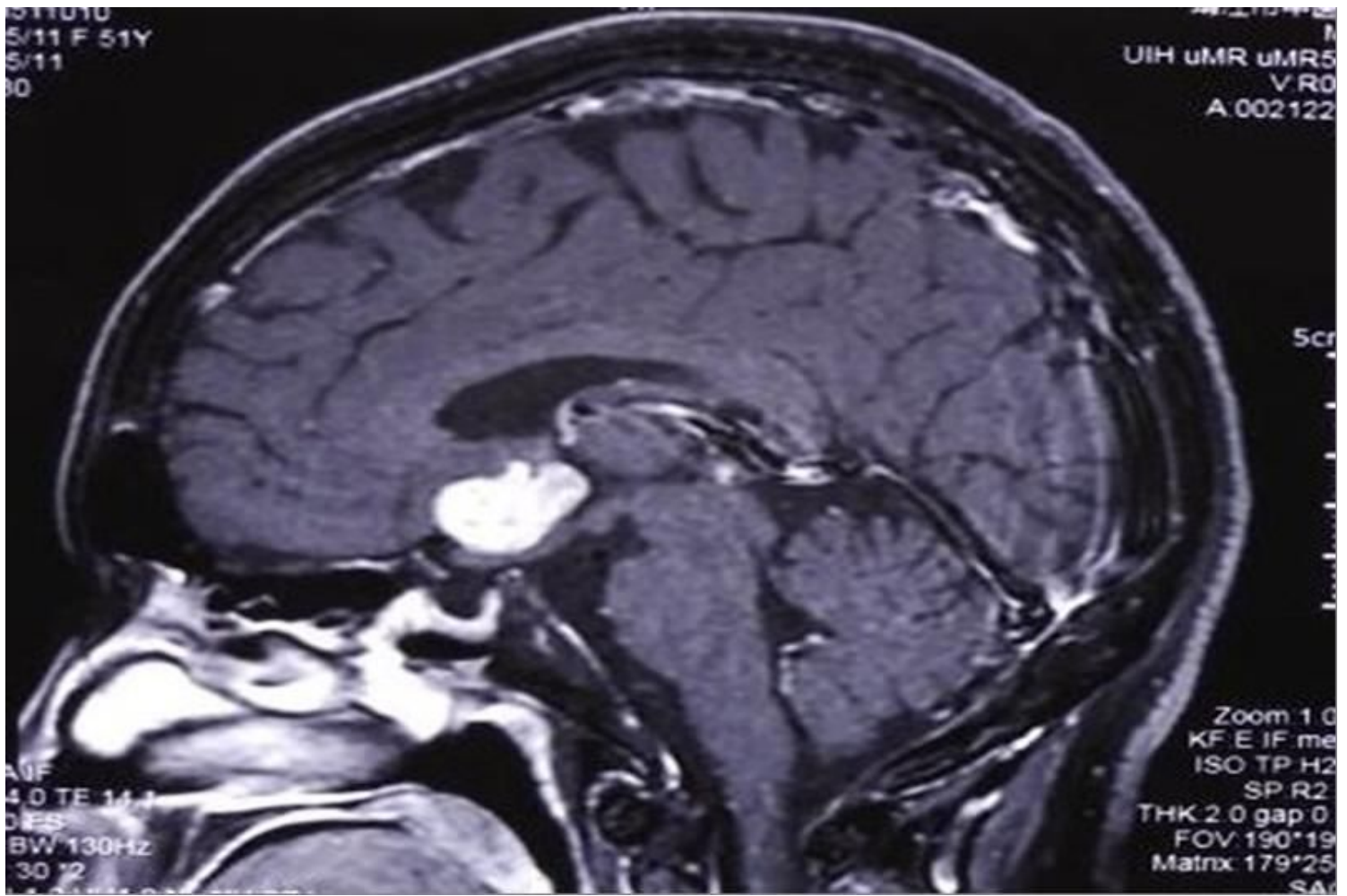


Figure 2

CT scans showed that there was a solid tumor in the third ventricle with densely enhanced and characteristically exhibited a well-circumscribed border

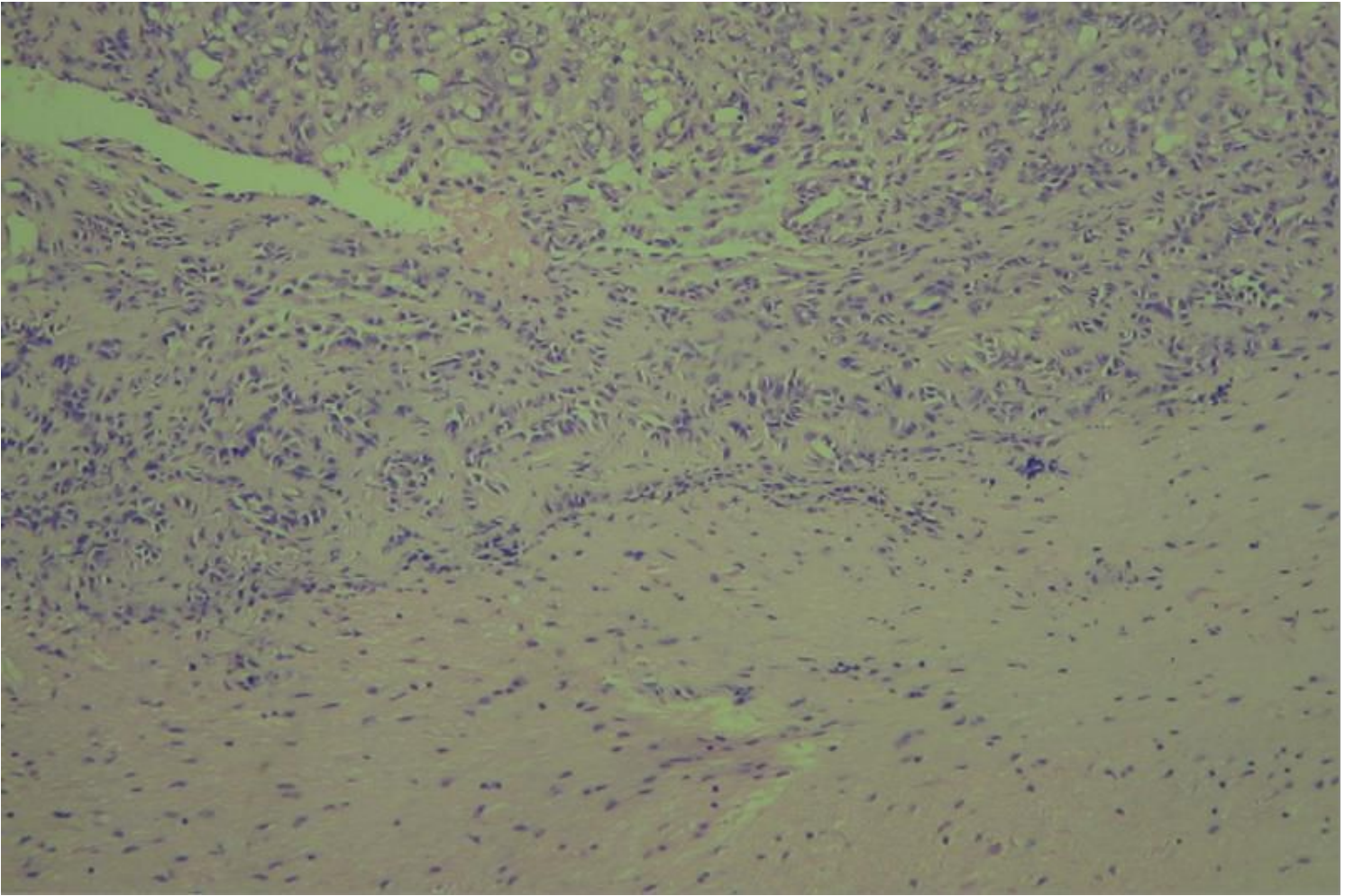


Figure 3

CT scans showed that there was a solid tumor in the third ventricle with densely enhanced and characteristically exhibited a well-circumscribed border

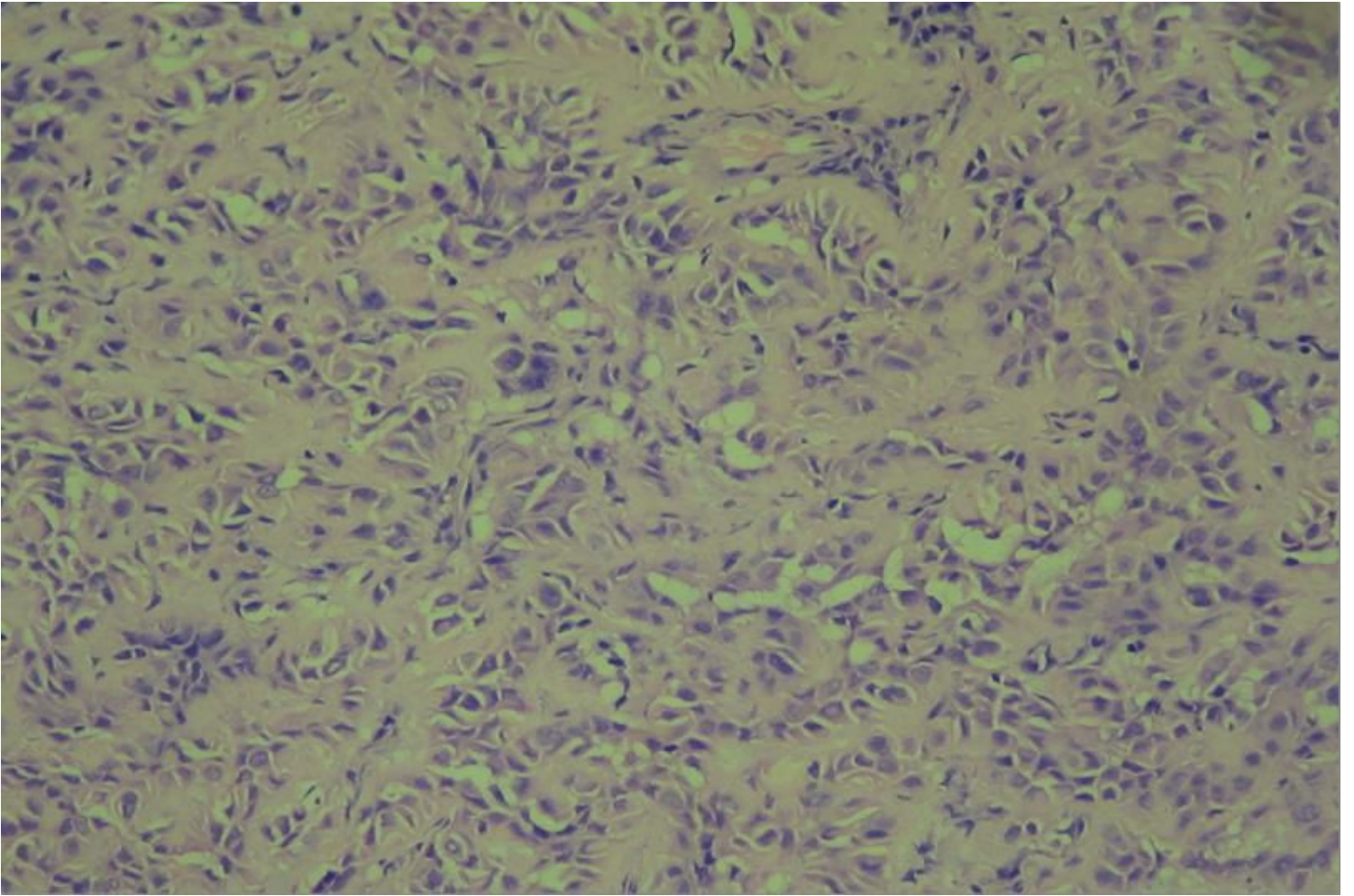


Figure 4

CT scans showed that there was a solid tumor in the third ventricle with densely enhanced and characteristically exhibited a well-circumscribed border

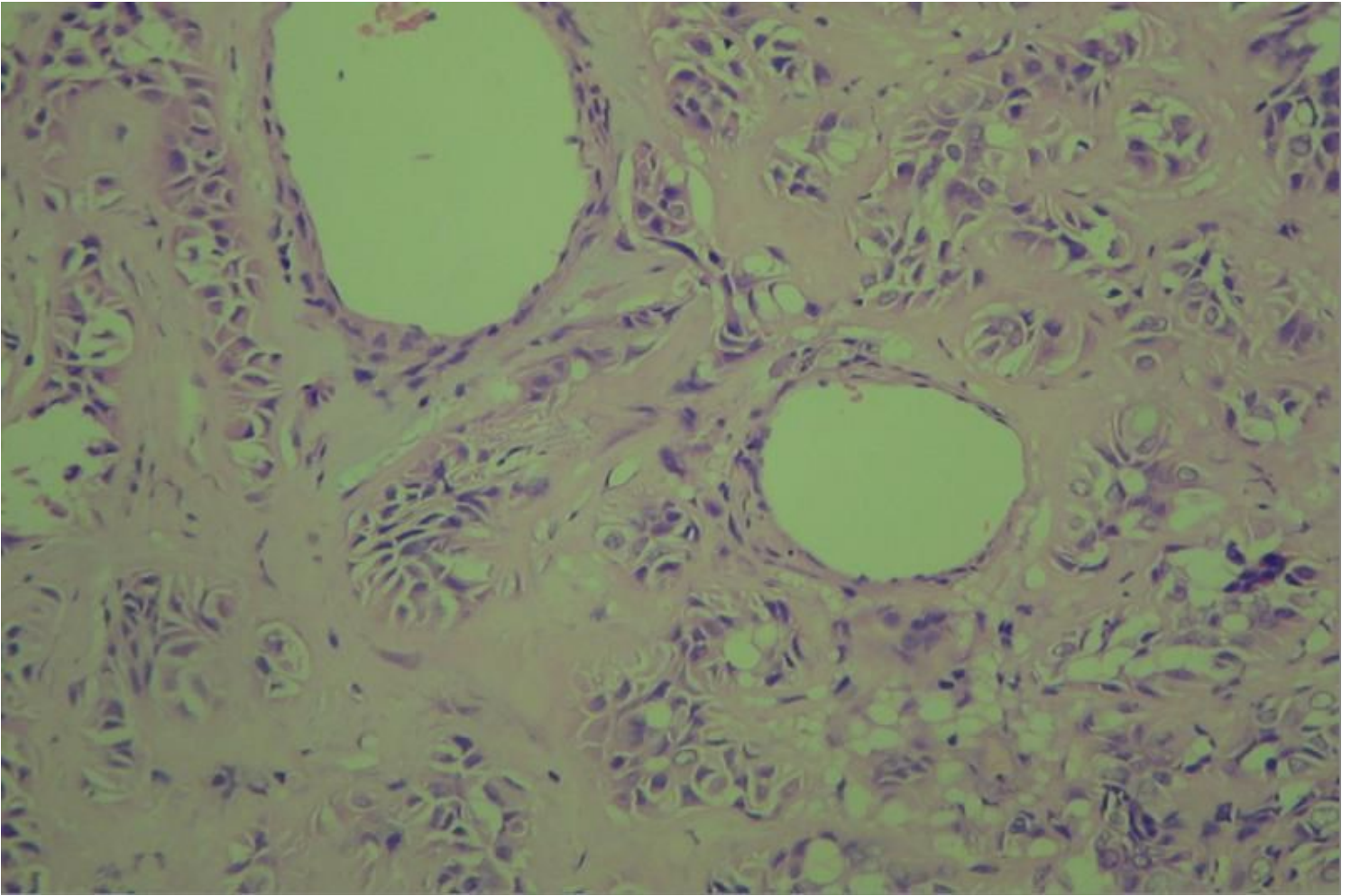


Figure 5

The tumor cells cubic or polygonal, some cells have long protrusions linked to the wall of the ducts. Cells have abundant cytoplasmic eosinophils in an abundant of solid collagen matrix. (hematoxylin and eosin; original magnification $\times 400$)

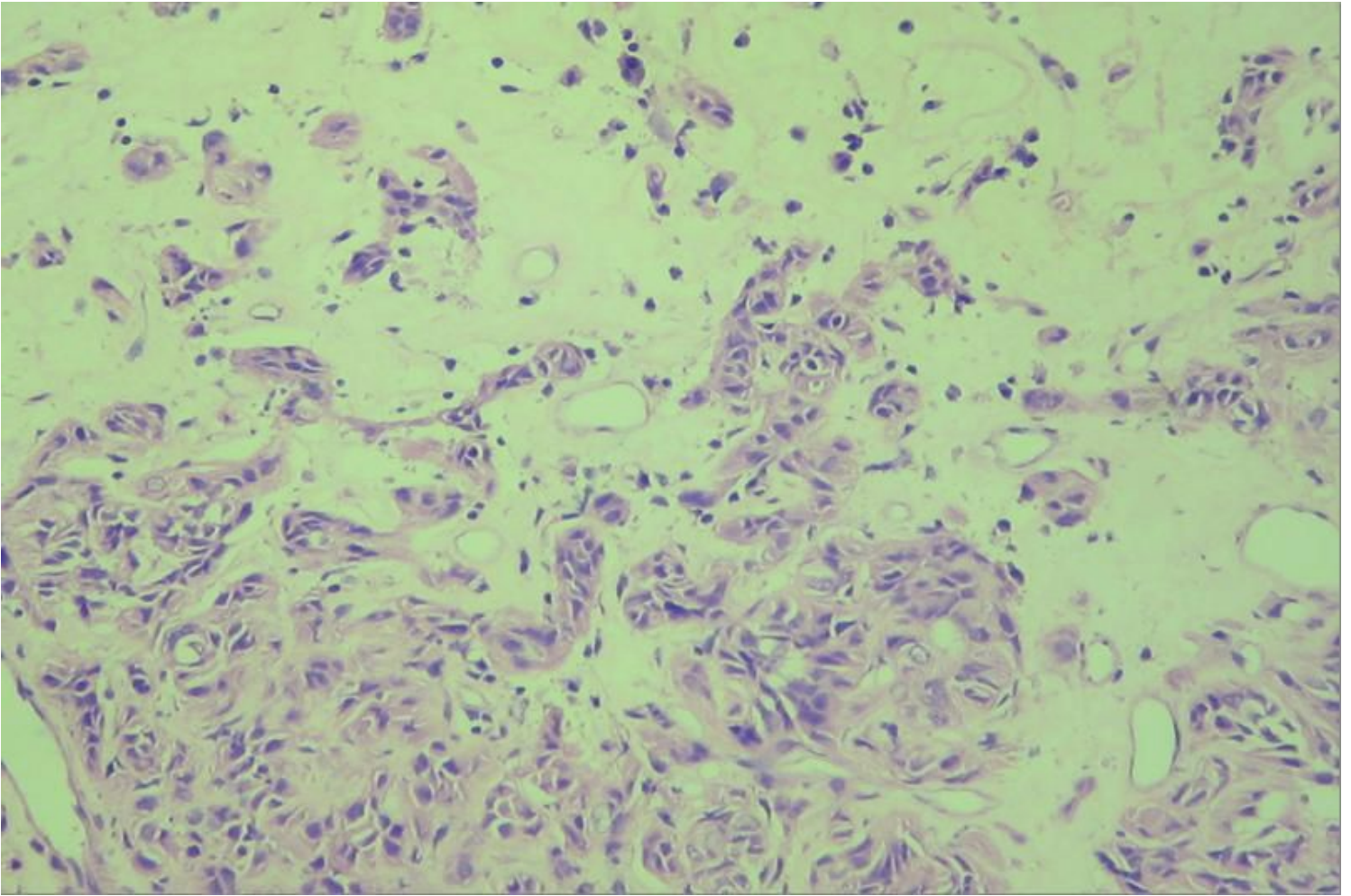


Figure 6

Some areas the tumor cells lied in an abundant of loosely mucoid matrix (hematoxylin and eosin; original magnification $\times 200$).

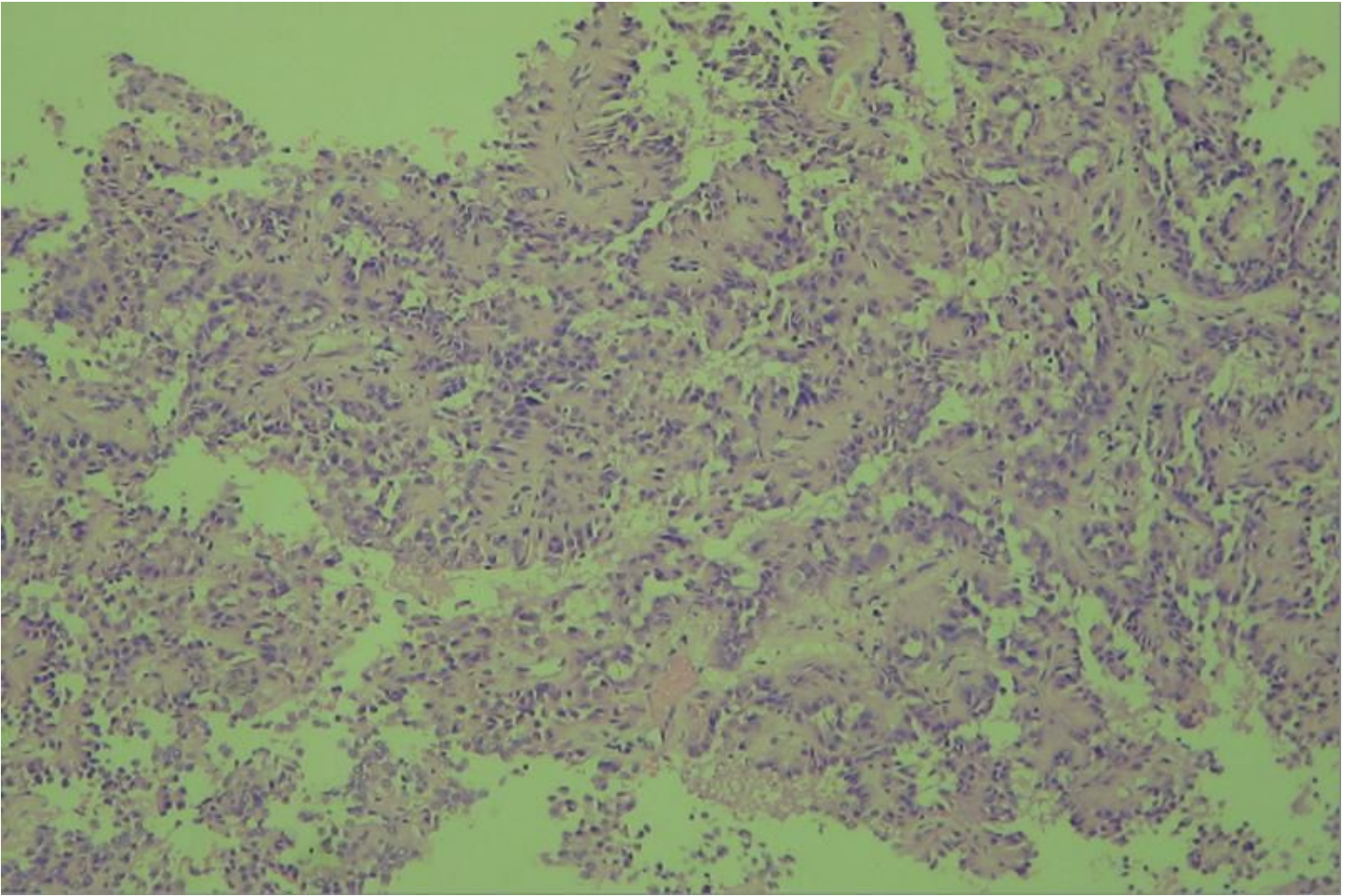


Figure 7

Some tumor cells arranged along the central fibrovascular core and formed into papillary structures and even secondary papillaries (hematoxylin and eosin; original magnification $\times 100$).

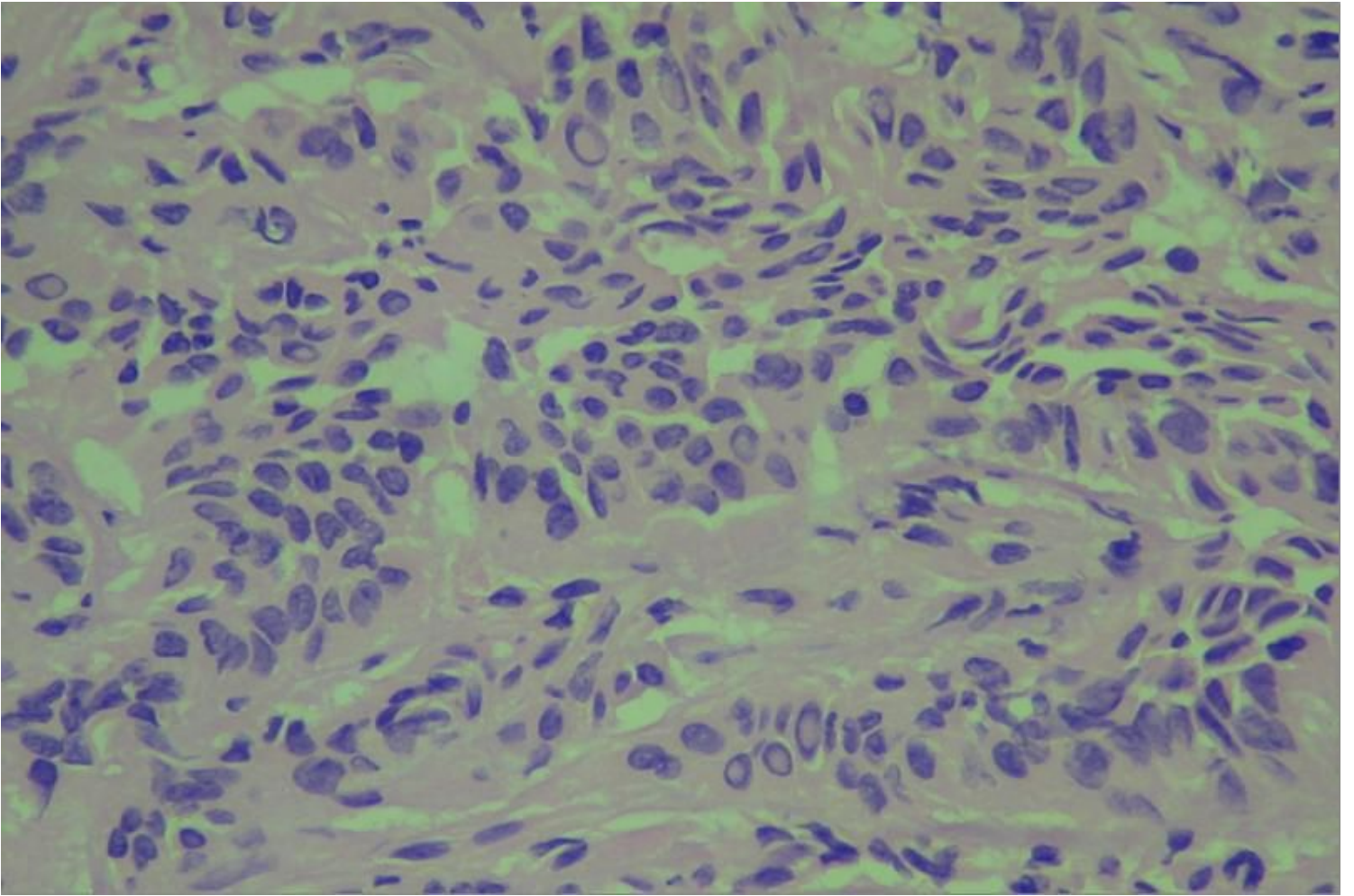


Figure 8

Many tumor cells which formed into papillary structures have nuclear inclusions and nuclear grooves (hematoxylin and eosin; original magnification $\times 400$).

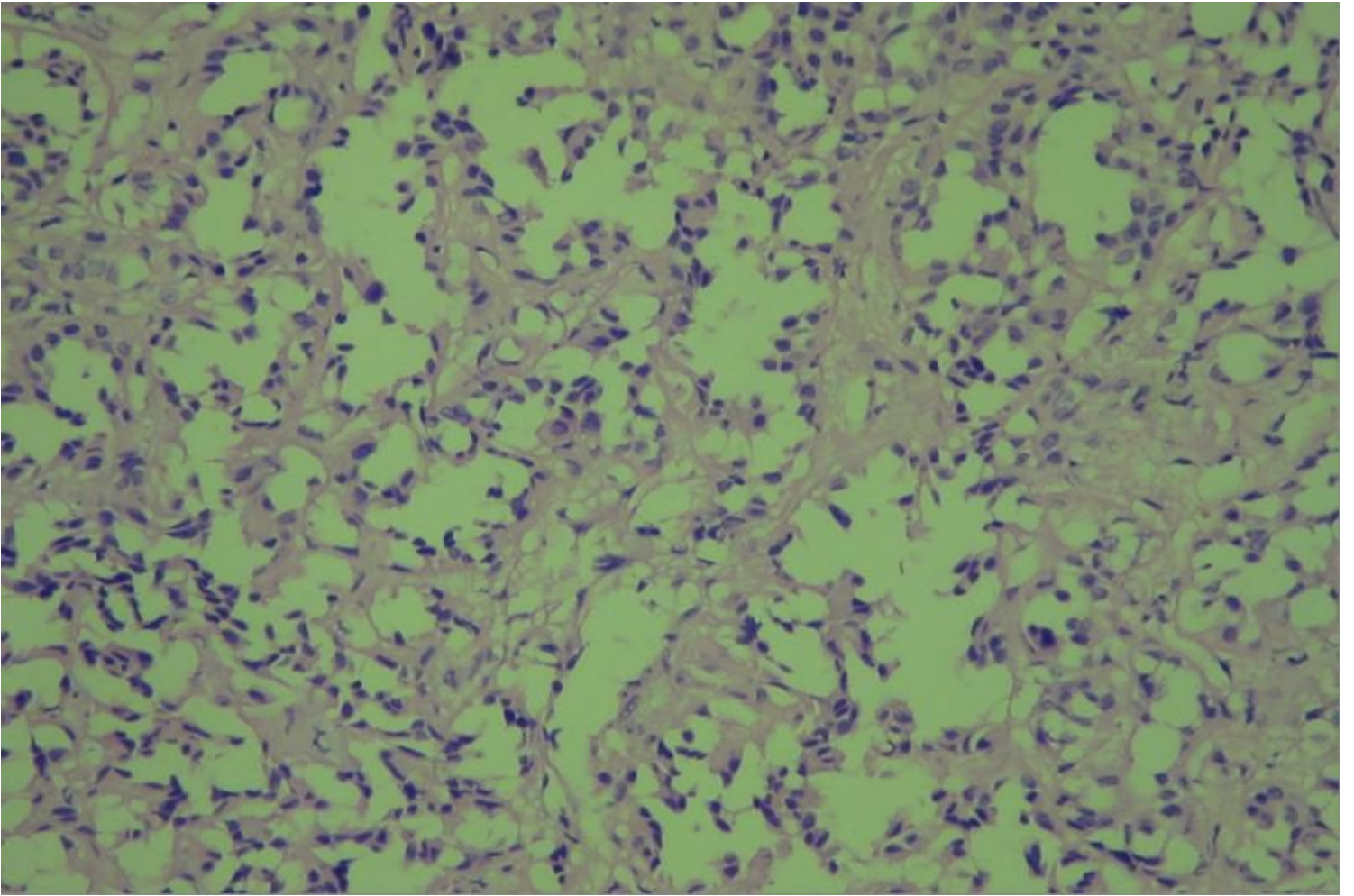


Figure 9

The tumor cells formed into micro-papillary structures (hematoxylin and eosin; original magnification $\times 200$).

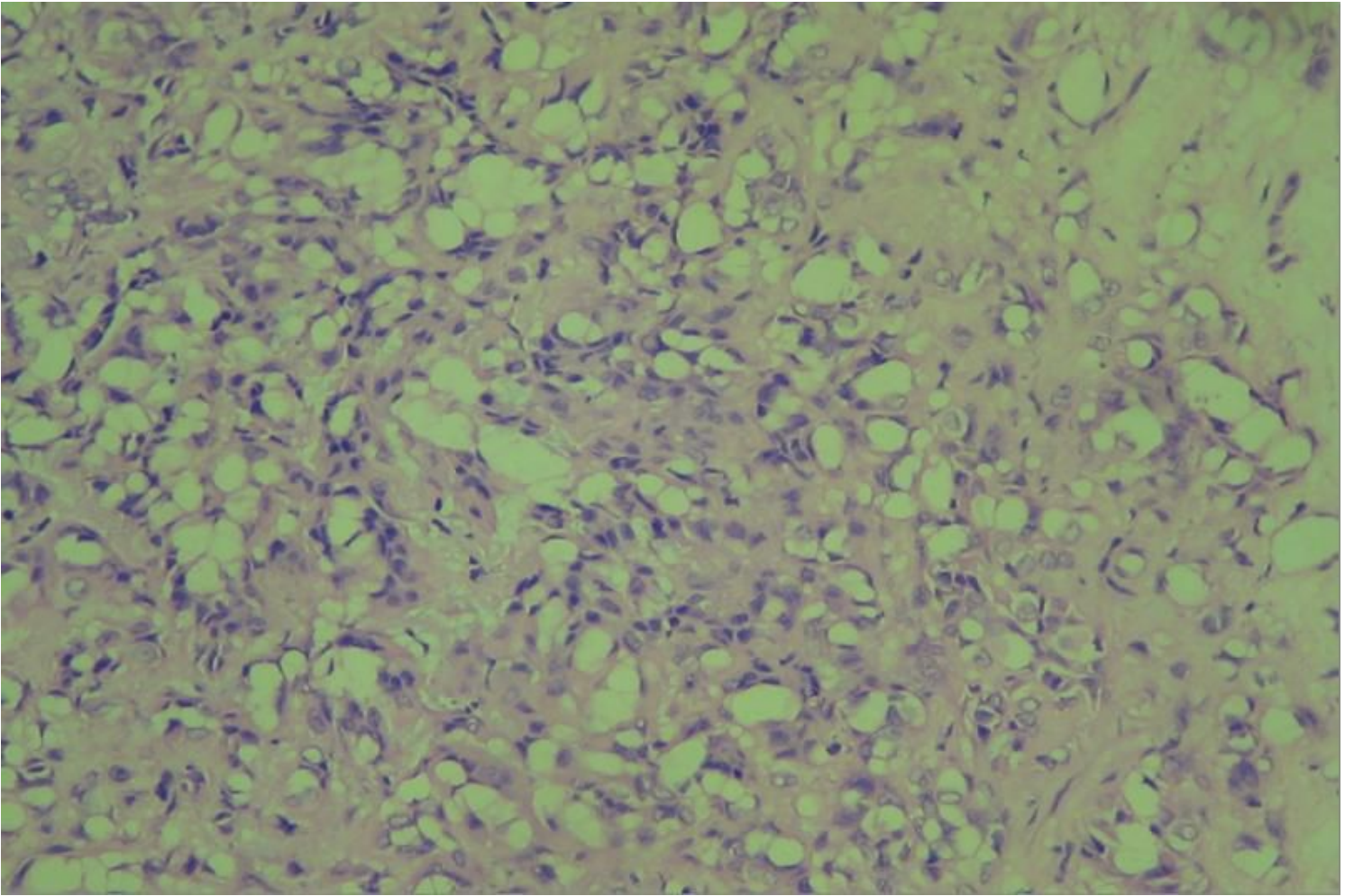


Figure 10

Some tumor cells with clear cytoplasm like lipoblast formed into pseudoglandular structure. (hematoxylin and eosin; original magnification $\times 200$).

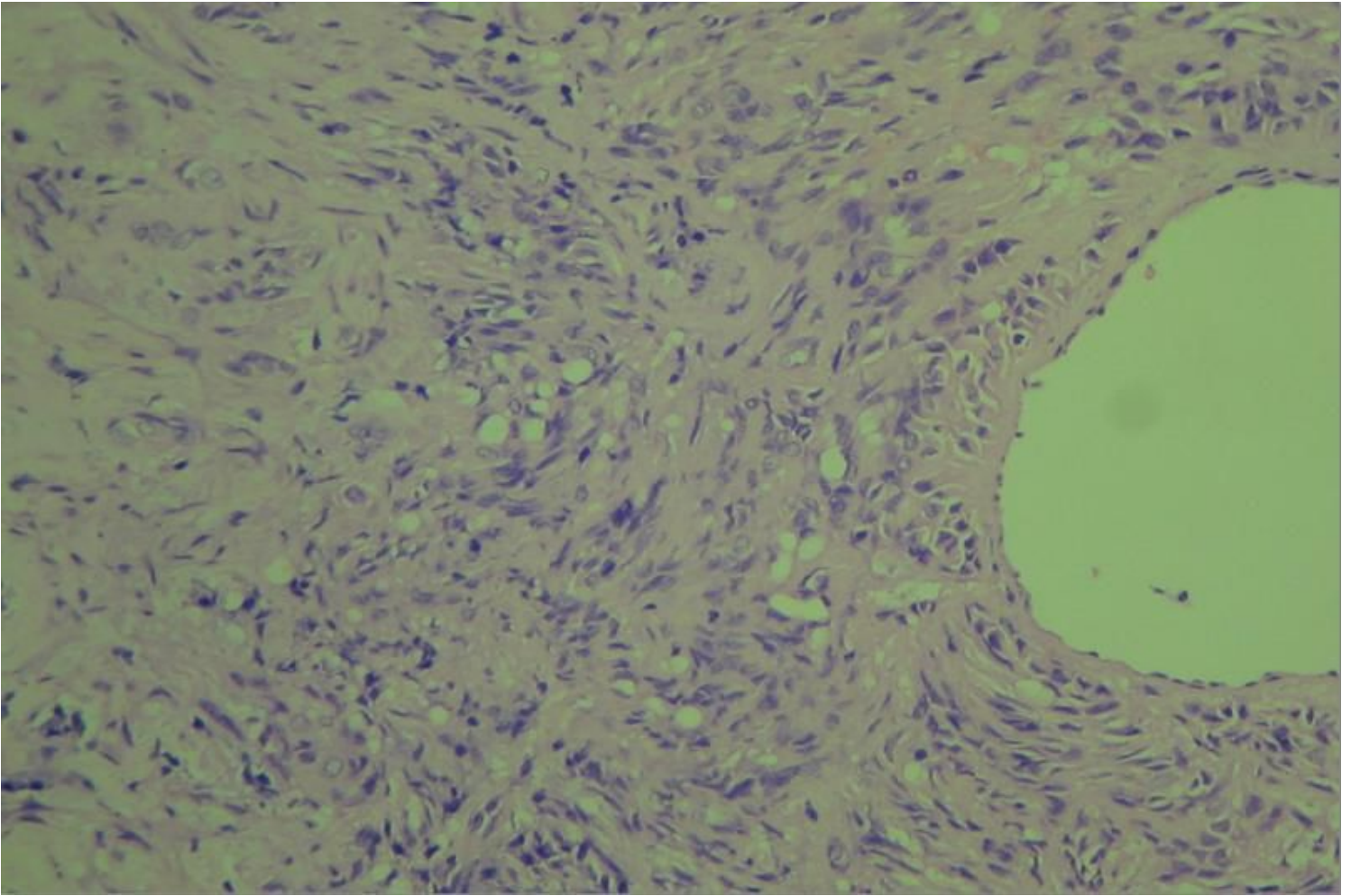


Figure 11

Some focal areas the tumor cells were spindle-shaped (hematoxylin and eosin; original magnification $\times 200$)

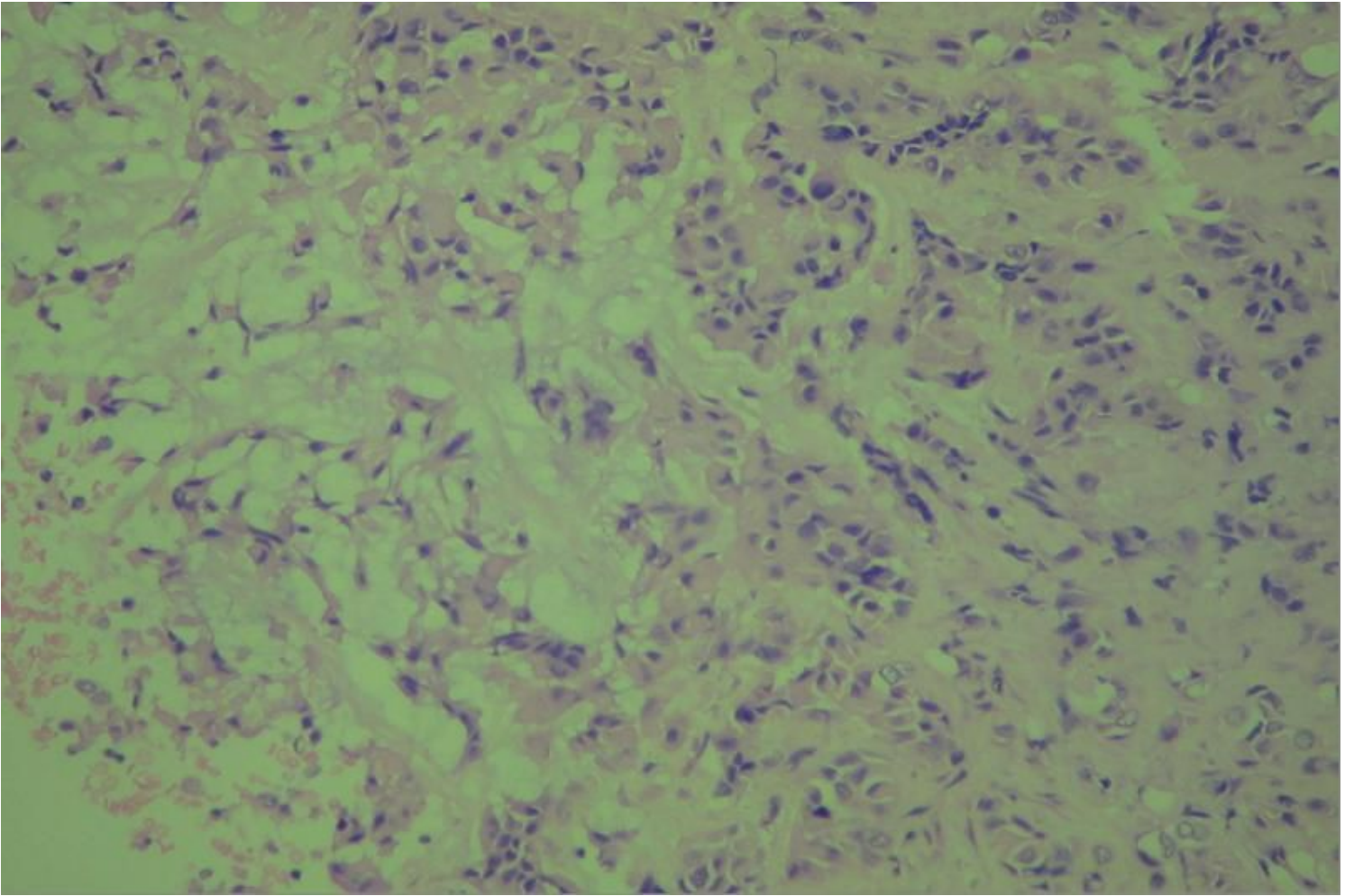


Figure 12

Some focal areas the tumor cells were spindle-shaped (hematoxylin and eosin; original magnification $\times 200$)

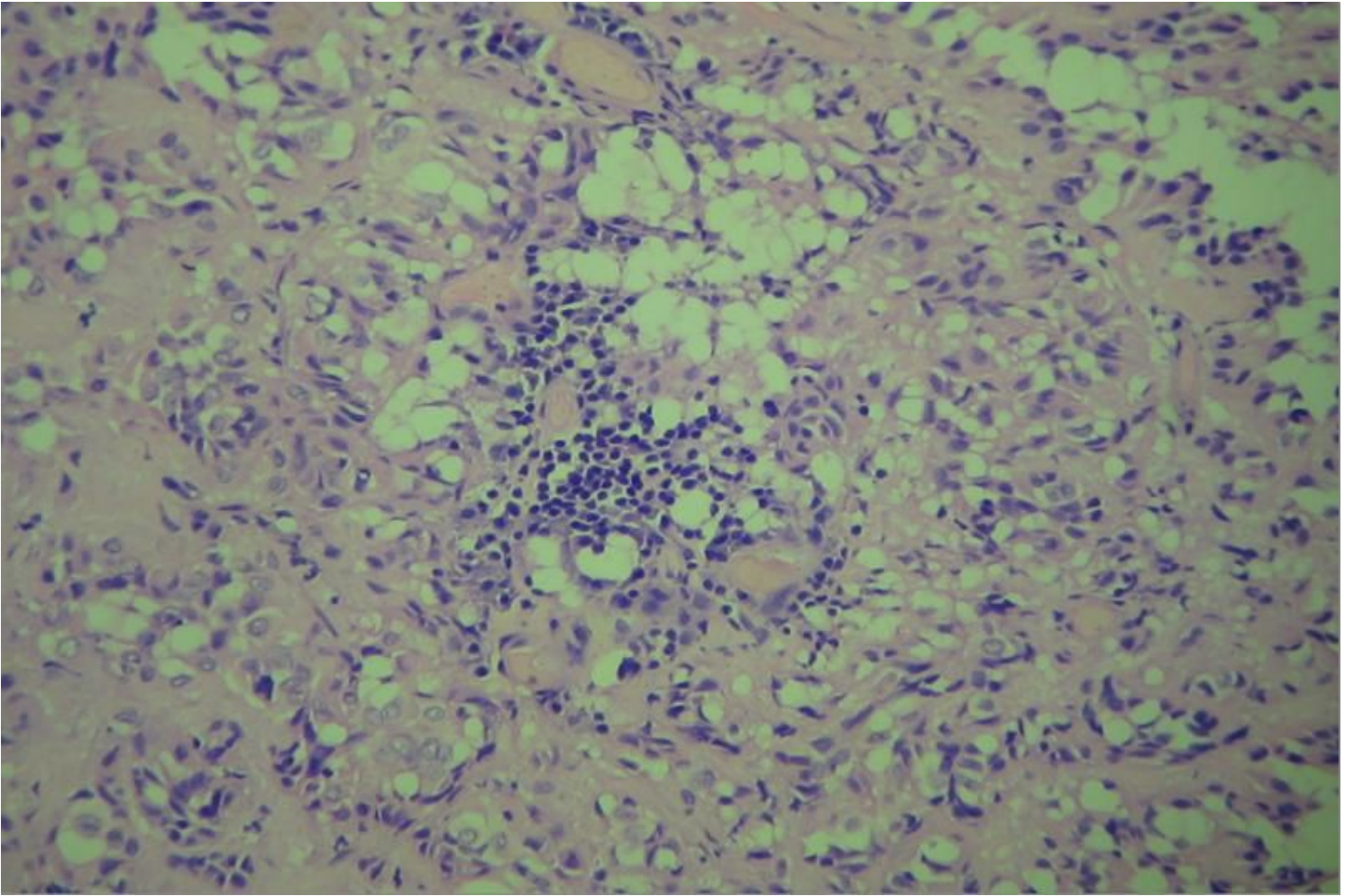


Figure 13

Focal lymphocyte aggregated in tumor tissue. There were pseudoglandulars above the lymphocytes (hematoxylin and eosin; original magnification $\times 200$)

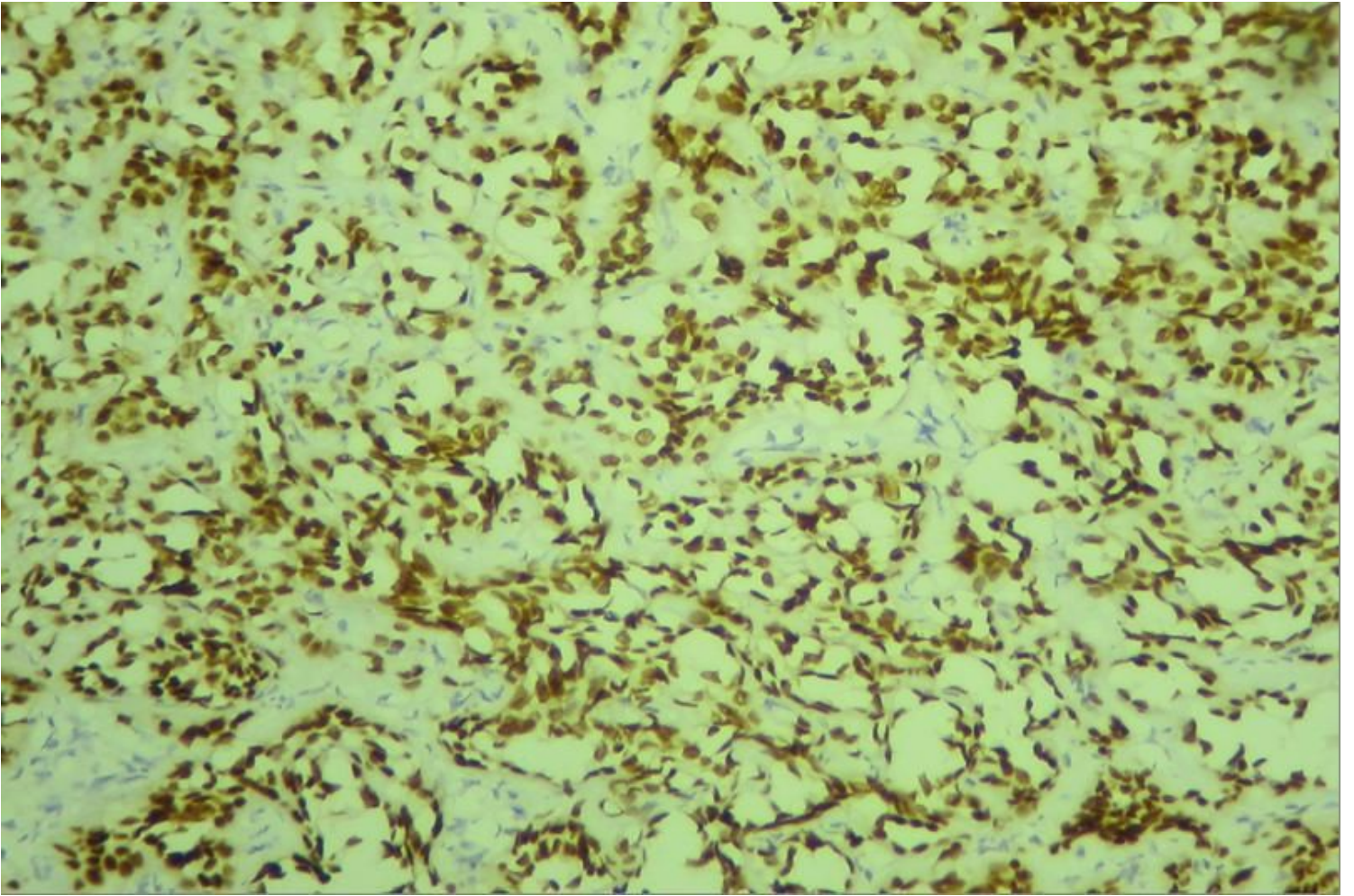


Figure 14

All the tumor cells were positive for TTF-1.

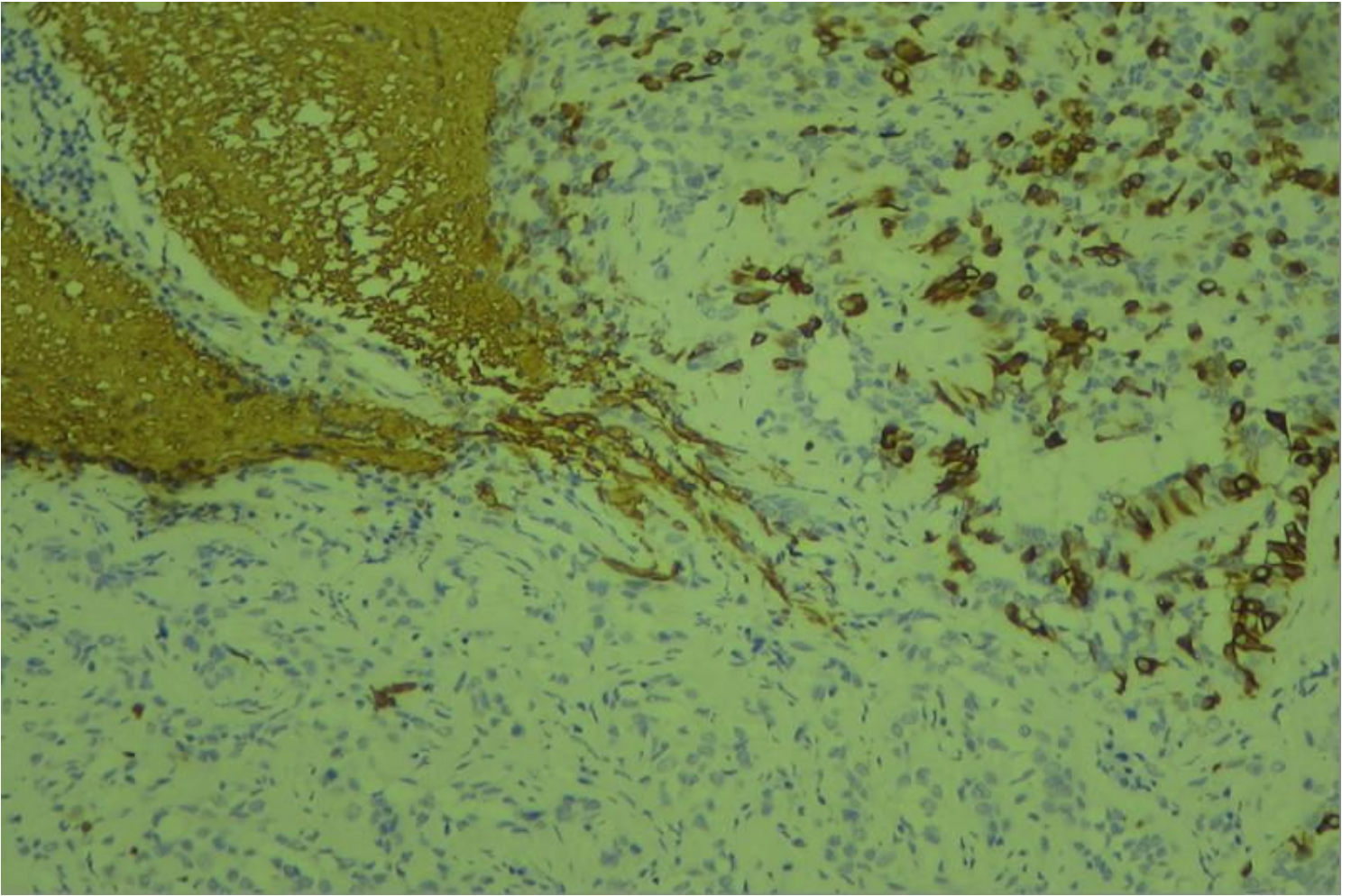


Figure 15

Some tumor cells were positive for GFAP. The brain tissue lied in the upper left around the tumor was strong positive for GFAP.

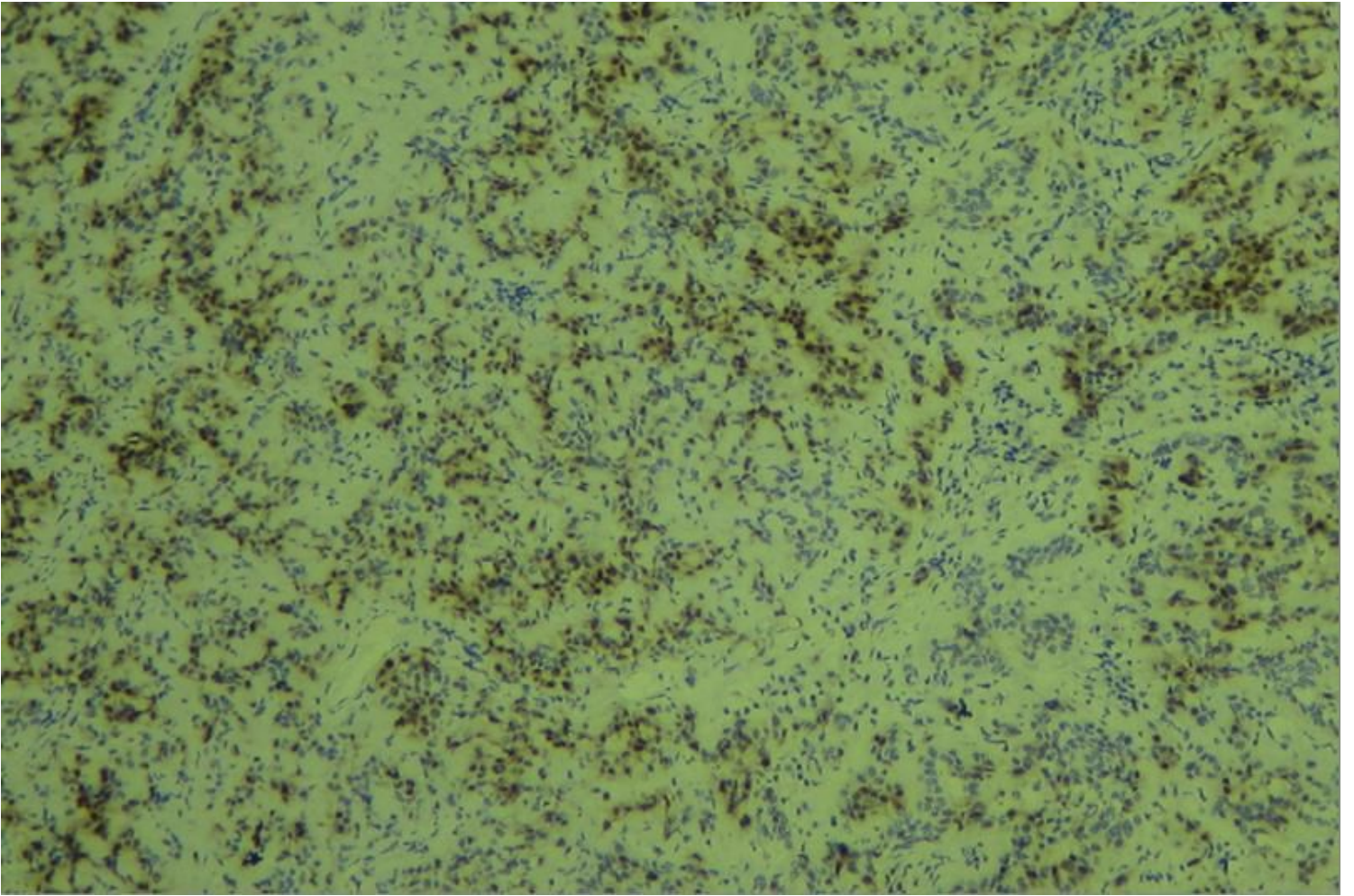
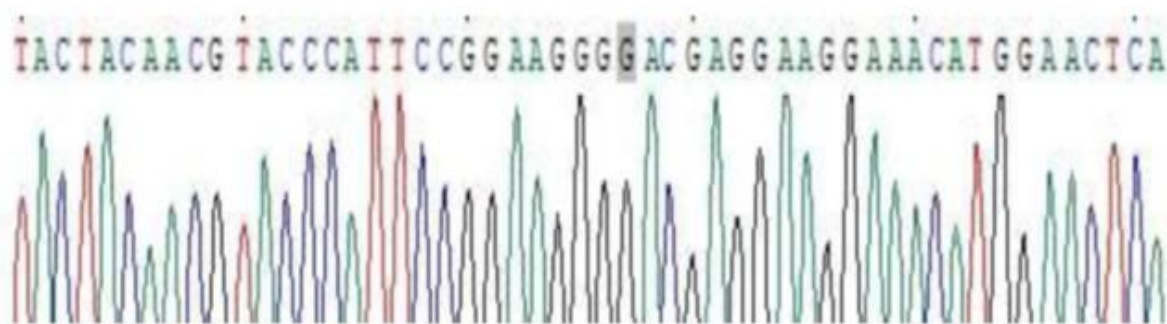


Figure 16

Some tumor cells strong but focal reactivity for NEU-N.

D294G



D463H

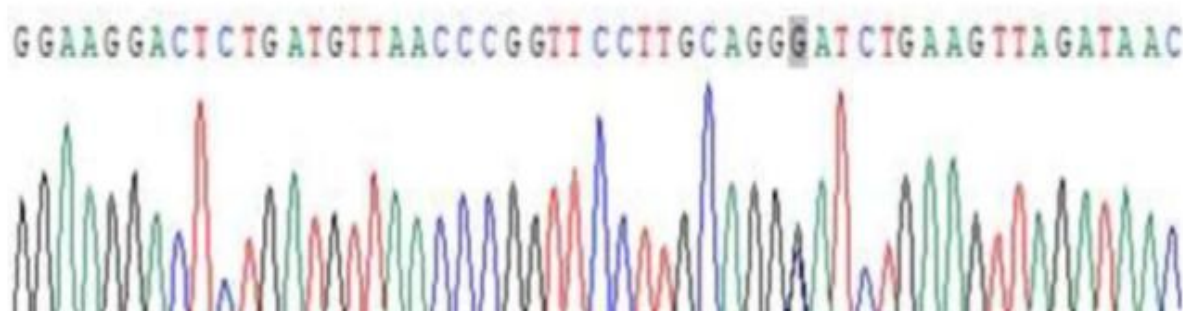


Figure 17

Genomic profiling showed that D463H missense mutation in PRKCA.

Supplementary Files

This is a list of supplementary files associated with this preprint. Click to download.

- [renamededc82.jpg](#)