

Neoadjuvant EGFR-TKI Therapy for EGFR-Mutant NSCLC in Traditionally Unresectable Patients

Ke-Cheng Chen (✉ cskchen@gmail.com)

National Taiwan University Hospital and National Taiwan University College of Medicine

Shuenn-Wen Kuo

National Taiwan University Hospital and National Taiwan University College of Medicine

Chen-Hao Hsiao

Division of Thoracic Surgery, Department of Surgery, Cheng Hsin General Hospital

Jing-Shing Chen

National Taiwan University Hospital and National Taiwan University College of Medicine

Research Article

Keywords: Neoadjuvant, NSCLC, EGFR, TKI

Posted Date: June 9th, 2021

DOI: <https://doi.org/10.21203/rs.3.rs-578508/v1>

License: © ⓘ This work is licensed under a Creative Commons Attribution 4.0 International License.

[Read Full License](#)

Abstract

Introduction

Advanced stage non-small cell lung cancer (NSCLC) patients harboring epidermal growth factor receptor (EGFR) mutations may have benefit from tyrosine kinase inhibitors (TKI). However, the role of multidisciplinary management including neoadjuvant TKI therapy and thoracic surgery is uncertain. This study assessed the possible impact of neoadjuvant TKI therapy and thoracic surgery in selected advanced stage patients.

Methods

Advanced stage of IIIB and IVA NSCLC patients were retrospectively reviewed from 2010 to 2013. Patients with EGFR mutations who received neoadjuvant TKI followed by surgical resection were included. All patients were followed up for 5 years or until death.

Results

There were total 15 advanced stage lung adenocarcinoma patients in the study. 8 patients were stage IIIB and 7 were stage IVA. All tumor sizes significantly decreased after neoadjuvant TKI therapy (p value = 0.0002). 11 patients received adjuvant TKI therapy after surgical resection and others received adjuvant cisplatin-based chemotherapy. Progression-free survival was superior in the group of adjuvant TKI therapy than in the group of adjuvant chemotherapy (median 14 months versus 5.9 months, p value = 0.016). Overall survival (OS) was not different between two groups (p value = 0.755). In the group of adjuvant TKI therapy, median OS in patients harboring exon 19 deletion and exon 21 L858R was 60 months and 44.9 months, respectively (p value = 0.078).

Conclusion

TKI may decrease the size of EGFR mutation lung adenocarcinoma. A multidisciplinary management including neoadjuvant TKI therapy and thoracic surgery may be discussed in selected advanced stage lung adenocarcinoma.

Introduction

Non-small cell lung cancer (NSCLC) remains the leading cause of cancer-related mortality in the developed world [1]. The 5-year relative survival rate is 18% for all stages of lung cancer and only 16% patients are localized stage with 55% of 5-year survival rate [1]. Most patients are advanced stage of III or IV with poor survival [1,2]. These patients are mainly treated with different management options, including systemic platinum-based chemotherapy, palliative radiotherapy, personalized target therapy, or immunotherapy [3-5]. Surgery alone is not recommended for advanced stage NSCLC patients. However, multidisciplinary management, including surgical resection in selected advanced stage NSCLC patients, can improve overall survival [6-10]. Unfortunately, the use of such treatments is decreasing [7].

The breakthrough identification of epidermal growth factor receptor (EGFR) in NSCLC in 2004 explicated the relation of overexpression of EGFR to poor prognosis [11]. The development of gefitinib, an EGFR tyrosine kinase inhibitor (TKI), provided a notable advance in treating advanced stage EGFR-mutation positive NSCLC [12]. Following a dramatic therapeutic response, TKIs were applied in advanced stage patients to improve progression-free survival (PFS) [4,5,13]. Currently, TKIs are a first-line treatment for advanced stage EGFR-mutation positive NSCLC patients [4,5,13]. TKIs have also been applied in localized resected NSCLC as a neoadjuvant therapy or adjuvant therapy in several clinical trials and studies [14-17]. However, no significant improvements of PFS were reported as compared to placebo [14-17].

In general, stage IIIA N2 NSCLC patients receive neoadjuvant chemotherapy followed by surgical resection in the absence of tumor progression [18]. However, neoadjuvant chemotherapy followed by surgical resection is recommended in small or single station mediastinal lymph nodes not in unresectable stage IIIA N2 NSCLC [19,20]. While thoracic surgery may possibly improve survival in advanced stage NSCLC patients and TKIs are a critical treatment for advanced stage EGFR-mutation positive NSCLC, the role of neoadjuvant TKI therapy followed by thoracic surgical resection in advanced stage EGFR-mutation positive NSCLC is still unclear. Several case reports failed to provide definite prognosis [6, 21-27]. Our study investigated the possible impact of neoadjuvant TKI therapy, followed by thoracic surgery in advanced stage EGFR-mutation positive NSCLC patients.

Materials And Methods

This observational study was approved by the Institutional Review Board of the National Taiwan University Hospital (No. 201712235RIND) and confirmed that all methods were performed in accordance with the relevant guidelines and regulations. The informed consent was waived, which was also approved by the Institutional Review Board of the National Taiwan University Hospital (No. 201712235RIND) due to its retrospective nature. NSCLC patients with stage IIIB and IVA (eighth edition of the TNM) were retrospectively identified by the Department of Surgery, National Taiwan University Hospital from 2010 to 2013. Progression-free survival (PFS) and overall survival (OS) were observed for five years.

Patient Inclusion and Exclusion Criteria

This study considered patients above the age of 20 who had initially presented with stage IIIB and IVA NSCLC patients treated with TKI therapy without tumor progression followed by surgical resection. Stage IIIB NSCLC patients without pathology proven positive N2 or N3 disease before neoadjuvant TKI therapy were excluded. Stage IVA patients without pathology proven metastases or positron emission tomography scan proven positive metastatic lesions before TKI therapy were also excluded. Patients with unknown EGFR mutant status or unknown EGFR mutant status prior to TKI treatment were excluded. Patients without regular follow-up were also excluded.

Assessments

PFS was assessed from the date of surgical resection to disease recurrence, or death from any cause, or at the end of observation. OS was assessed from the date of initial treatment to death from any cause or at the end of observation. Patients were evaluated every three to four months for two years after surgical resection and then every six months for three years. Additional evaluations were arranged if any symptoms or signs of disease recurrence were suspected. Follow-up evaluations included patient history, physical examination, chest and upper abdominal computed tomography, and brain magnetic resonance imaging. Bone scintigraphy was obtained when related symptoms occurred or bone metastasis was suspected.

Statistics

SPSS version 18 (SPSS Inc., Chicago, IL, USA) was used to analyze all data. All statistical tests were two sided. Categorical variables were compared using Fisher's exact tests between two groups. Continuous variables were presented as median and range and were compared by paired t tests. The Kaplan-Meier method was used to estimate survival curves and a log-rank test was used to compare the PFS and OS between different groups. Cox regressions were also used to calculate the hazard ratios (HRs) between different groups. A *p* value less than 0.05 was considered to be statistically significant.

Results

A total of 15 advanced stage lung adenocarcinoma patients were included in the study: 2 men and 13 women with a median age of 56 years (range, 27-71). 8 patients were stage IIIB and 7 patients were stage IVA. Of the stage IVA patients, 1 patient had pleural seeding, 1 patient had adrenal gland metastasis, 4 patients had single brain metastasis, and 1 patient had single bone metastasis. Four brain metastasis patients presented with single brain tumor and initially received brain tumor excision followed by whole brain radiotherapy. The single bone metastasis patient received stereotactic ablative radiotherapy and intensity modulated radiotherapy combined with neoadjuvant TKI therapy. Two patients (13.3%) were smokers. Initially, the median tumor size in maximal diameter was 5 cm (range, 1.7-7.8). All patients received tyrosine kinase inhibitors followed by surgery. Fourteen patients (93.3%) underwent lobectomy and one patient (6.7%) received wedge resection. 2 of 15 patients received thoracotomy due to the large tumor sizes. The other patients received video-assisted thoracoscopy surgery. Of the resected tumors, the median size in maximal diameter was 2.5 cm (range, 1.0-6.6). The median follow-up time was 60.0 months (range, 28.2-60.0). Demographics and characteristics of the patients were summarized in Table 1.

As shown in Table 1, nine patients (60%) were exon 19 deletion and six patients were exon 21 L858R mutation. In terms of neoadjuvant TKI therapy, thirteen patients (86.7%) were prescribed gefitinib and two patients were prescribed erlotinib. Initially, the median tumor size was 5 cm in maximal diameter. After neoadjuvant TKI therapy, the median resected tumor size was 2.5 cm in maximal diameter. Tumor size of maximal diameter decreased after neoadjuvant TKI therapy with statistical significance (*p* value = 0.0002).

As shown in Table 2, three patients had R1 positive resection margins with initial large tumor sizes of 7.8 cm, 6.6 cm, and 5 cm in maximal diameter. No patients died within day 90 after operation. All patients received adjuvant therapies: either TKI or cisplatin-based chemotherapy. There were 11 patients continually prescribing TKI therapy after operation. Ten of 11 patients received Gefitinib. The other four patients received adjuvant chemotherapy. Fourteen patients (93.3%) developed tumor recurrences. Eight patients had intrathoracic recurrence and eight patients had extrathoracic recurrence. Brain metastasis was predominant (50%) in the extrathoracic group and recurrent lung tumor was predominant (75%) in the intrathoracic group. Ten patients were survival till the end of 5 years observation.

Of all patients, the median PFS was 9.2 months (range, 4.2 to 60.0). In the group of adjuvant TKI therapy, the median PFS was 14.0 months (range, 5.6 to 60.0). In the other group of adjuvant chemotherapy, the median PFS was 5.9 months (range, 4.2 to 9.2). Among both groups, there was significant difference in PFS (p value = 0.016, figure 1). Hazard ratio (HR) was 0.209 with 95% confidence interval (CI) from 0.051 to 0.849 (p value = 0.029). In the group of adjuvant TKI therapy, seven patients harbored exon 19 deletion and four patients harbored exon 21 L858R mutation. Among these two EGFR mutations, no significant difference was found in PFS (p value = 0.135, figure 2). HR was 0.316 with 95% CI from 0.064 to 1.55 (p value = 0.156).

At the end of five years observation, the median OS of all patients was 60.0 months (range, 25.3 to 60.0). The 5-year survival rate of all patients was 66.7%. As shown in figure 3, there was no significant difference in OS among adjuvant TKI therapy group and adjuvant chemotherapy group (p value = 0.755). HR was 1.415 with 95% CI from 0.158 to 12.680 (p value = 0.756). The median OS in the adjuvant TKI therapy group was also 60.0 months (range, 25.3 to 60.0). The 5-year survival rate of the adjuvant TKI therapy group was 63.6%. Among two EGFR mutations of the adjuvant TKI therapy group, there was no significant difference in OS (p value = 0.078, figure 4). HR was 6.074 with 95% CI from 0.622 to 59.283 (p value = 0.121).

Discussion

Recently, thoracic surgery has been considered to be helpful as local consolidative therapy in advanced stage NSCLC [8,10]. Some authors reported performing salvage surgery in advanced stage NSCLC and viewed it as one part of multidisciplinary management [6,9]. Thoracic surgery for primary lung cancer may improve survival in selected advanced stage NSCLC [6-11]. In addition, EGFR TKI therapy in advanced stage NSCLC is a critical treatment with excellent tumor response and improvement of PFS [3,4,13,28]. Many clinical trials have assessed EGFR TKI as a neoadjuvant or adjuvant therapy in early stage NSCLC [14-17], while other reports used EGFR TKI as a neoadjuvant therapy followed by thoracic surgery in advanced stage NSCLC [21-27].

In our study, we retrospectively reviewed our advanced stage EGFR-mutation positive lung adenocarcinoma patients receiving neoadjuvant TKI therapy followed by thoracic surgery. The tumor sizes decreased significantly after neoadjuvant TKI therapy. The difference in tumor sizes may be an

effect of the high response rate of EGFR TKIs in EGFR-mutation patients [3,13]. Because tumor size is a risk factor that patients may receive thoracotomy or convert from VATS to thoracotomy [29]. The benefit of decreased tumor size may let patients receive minimally invasive thoracic surgery as feasible. Although two patients in our study still received thoracotomy due to tumors respectively measuring 5.6 cm and 6.0 cm in maximal diameter, the tumor sizes were decreased after receiving neoadjuvant TKI therapy. The most patients received VATS uneventfully. Our study showed that advanced stage EGFR-mutation positive lung adenocarcinoma patients receiving neoadjuvant TKI therapy may experience decreased tumor size, allowing for the use of VATS as possible instead of thoracotomy.

Many clinical trials have shown that median PFS gradually decreases as disease progresses from early stage to advanced stage [3,13-17,30]. Median PFS in the advanced stage was around five to fourteen months associated with different types of management [3,13]. However, there is an issue that what kind of adjuvant management is feasible for the patients receiving neoadjuvant TKI therapy followed by thoracic surgery. In our study, the median PFS of all patients was 9.2 months, similar to previous clinical findings. The mean neoadjuvant TKI interval in the group receiving adjuvant TKI therapy and adjuvant chemotherapy was 107.2 days and 73 days, respectively. The difference was not significant (p value = 0.7177). Our patients received adjuvant TKI therapy or adjuvant chemotherapy after operation, the median PFS in the group receiving adjuvant TKI therapy was 14.0 months. The result was significantly better than the group receiving adjuvant chemotherapy. Previous studies in stage II to IIIA NSCLC reported the superior results in adjuvant TKI therapy versus adjuvant chemotherapy [31]. There was also the same trend in our patients with the advanced stages of stage IIIB and IVA. The result might give us a hint that advanced stage lung adenocarcinoma patients with EGFR mutation receiving TKI as a neoadjuvant and adjuvant therapy might be an acceptable multidisciplinary management with comparable PFS. In addition, some studies have shown that patients harboring exon 19 deletion have better PFS than those with exon 21 L858R mutation, while others show different findings [13,28,32-33]. However, PFS showed no significant difference between exon 19 deletion and exon 21 L858R mutation in our study.

Generally, median OS and five-year survival rate gradually decreased corresponding to staging [1,2,30]. In our study, the 5-year survival rate was 66.7%. OS differences between patients treated with TKI or chemotherapy were not statistically significant in many studies and remain uncertain [3,13,28,32-33]. Our study also showed the same result. Although the 5-year survival rate of our patients seem to be superior to general population of advanced NSCLC patients, we could not explain where the benefit on OS coming from. Many factors involved during a whole course of treatment and influenced a result of OS. Multidisciplinary management might be a trend to deal with advanced stage NSCLC patients. No single management would be a critical role in treating advanced stage cancer patients. Besides, OS results reported by some studies show patients harboring exon 19 deletion treated with TKI have longer survival than patients harboring exon 21 L858R mutation [34]. However, our OS results were not different between these two mutations. Not all patients received adjuvant TKI therapy and 26.7% patients received adjuvant chemotherapy. This might be a factor to influence the result of OS in our study.

Limitation

Our study is retrospective and is limited to a small number of patients, thus being prone to have selection bias. The neoadjuvant TKI interval is not consistent nor definitely rule-based. Our result revealed that the tumor size was decreased after neoadjuvant TKI therapy, but we could not get the conclusion how long interval should patients take neoadjuvant TKI therapy. There is also a bias in adjuvant chemotherapy. The doublet regime of adjuvant chemotherapy was cisplatin-based not totally uniform due to a retrospective study. Because our patient number was small that we could not get the conclusion in OS between two mutation statuses even the patients harboring exon 19 deletion have the trend of superiority.

Conclusion

In selected advanced stage EGFR-mutation positive adenocarcinoma patients, they may possibly have a benefit from TKI therapy in decreasing tumor size. Adjuvant TKI therapy seem to have a trend of superiority in PFS comparing to adjuvant chemotherapy. The multidisciplinary management including neoadjuvant TKI therapy, surgery, and adjuvant TKI therapy maybe an issue to discuss in advanced stage NSCLC. Future work will increase the patient sample size. A randomized control study should be performed in selected advanced stage NSCLC patients.

Declarations

Acknowledgments and disclosures

This study was not supported by any grants. All authors declare no conflicts of interest.

References

1. Siegel RL, Miller KD, Jemal A. Cancer statistics, 2017. *CA Cancer J Clin* 2017; 67:7-30.
2. Goldstraw P, Chansky K, Crowley J, et al. The IASLC Lung Cancer Staging Project: proposals for revision of the TNM stage groupings in the forthcoming (eighth) edition of the TNM classification for lung cancer. *J Thorac Oncol* 2016; 11:39–51.
3. Mok TS, Wu YL, Thongprasert S, et al. Gefitinib or carboplatin-paclitaxel in pulmonary adenocarcinoma. *N Engl J Med* 2009;361:947-957.
4. Reck M, Heigener DF, Mok T, Soria JC, Rabe KF. Management of non-small-cell lung cancer: recent developments. *Lancet* 2013;382:709-719.
5. Reck M, Rodriguez-Abreu D, Robinson AG, et al. Pembrolizumab versus chemotherapy for PD-L1-positive non-small-cell lung cancer. *N Engl J Med* 2016; 375:1823-1833.
6. Uramoto H, Tanaka F. Salvage thoracic surgery in patients with primary lung cancer. *Lung Cancer* 2014;84:151-155.
7. David EA, Canter RJ, Chen Y, Cooke DT, Cress RD. Surgical management of advanced stage NSCLC is decreasing but remains associated with improved survival. *Ann Thorac Surg* 2016;102:1101-1109.

8. Gomez DR, Blumenschein GR Jr, Lee JJ, et al. Local consolidative therapy versus maintenance therapy or observation for patients with oligometastatic non-small-cell lung cancer without progression after first-line systemic therapy: a multicenter, randomized, controlled, phase 2 study. *Lancet Oncol* 2016;17:1672-1682.
9. Shimada Y, Suzuki K, Okada M, et al. Feasibility and efficacy of salvage lung resection after definitive chemoradiation therapy for Stage III non-small-cell lung cancer. *Interact Cardiovasc Thorac Surg* 2016;23:895-901.
10. David EA, Clark JM, Cooke DT, Melnikow J, Kelly K, Canter RJ. The role of thoracic surgery in the therapeutic management of metastatic non-small-cell lung cancer. *J Thorac Oncol* 2017;12:1636-1645.
11. Selvaggi G, Novello S, Torri V, et al. Epidermal growth factor receptor overexpression correlates with a poor prognosis in completely resected non-small-cell lung cancer. *Ann Oncol* 2004;15:28-32.
12. Santoro A, Cavina R, Latteri F, et al. Activity of a specific inhibitor, gefitinib (Iressa, ZD1839), of epidermal growth factor receptor in refractory non-small-cell lung cancer. *Ann Oncol* 2004;15:33-37.
13. Zhou C, Wu YL, Chen G, et al. Erlotinib versus chemotherapy as first-line treatment for patients with advanced EGFR mutation-positive non-small-cell lung cancer (OPTIMAL, CTONG-0802): a multicenter, open-label, randomized, phase 3 study. *Lancet Oncol* 2011;12:735-742.
14. Lara-Guerra H, Waddell TK, Salvarrey MA, et al. Phase II study of preoperative gefitinib in clinical stage I non-small-cell lung cancer. *J Clin Oncol* 2009;27:6229-6236.
15. Janjigian YY, Park BJ, Zakowski MF, et al. Impact on disease-free survival of adjuvant erlotinib or gefitinib in patients with resected lung adenocarcinomas that harbor EGFR mutations. *J Thorac Oncol* 2011;6:569-575.
16. Goss GD, O'Callaghan C, Lorimer I, et al. Gefitinib versus placebo in completely resected non-small-cell lung cancer: results of the NCIC CTG BR19 study. *J Clin Oncol* 2013;31:3320-3326.
17. Kelly K, Altorki NK, Eberhardt WE, et al. Adjuvant erlotinib versus placebo in patients with stage IB-IIIA non-small-cell lung cancer (RADIANT): a randomized, double-blind, phase III trial. *J Clin Oncol* 2015;33:4007-4014.
18. Rosell R, Gomez-Codina J, Camps C, et al. A randomized trial comparing preoperative chemotherapy plus surgery with surgery alone in patients with non-small-cell lung cancer. *N Engl J Med* 1994;330:153-158.
19. Van Meerbeeck JP, Kramer GW, Van Schil PE, et al. Randomized controlled trial of resection versus radiotherapy after induction chemotherapy in stage IIIA-N2 non-small-cell lung cancer. *J Natl Cancer Inst* 2007;99:442-450.
20. Decaluwe H, De Leyn P, Vansteenkiste J, et al. Surgical multimodality treatment for baseline resectable stage IIIA-N2 non-small cell lung cancer. Degree of mediastinal lymph node involvement and impact on survival. *Eur J Cardiothorac Surg* 2009;36:433-439.
21. Takamochi K, Suzuki K, Sugimura H, et al. Surgical resection after gefitinib treatment in patients with lung adenocarcinoma harboring epidermal growth factor gene mutation. *Lung Cancer* 2007;58:149-

155.

22. Kappers I, Klomp HM, Burgers JA, Van Zandwijk N, Haas RL, van Pel R. Neoadjuvant (induction) erlotinib response in stage IIIA non-small-cell lung cancer. *J Clin Oncol* 2008;26:4205-4207.
23. Hishida T, Nagai K, Mitsudomi T, et al. Salvage surgery for advanced non-small cell lung cancer after response to gefitinib. *J Thorac Cardiovasc Surg* 2010;140:e69-71.
24. Liu M, Jiang G, He W, Zhang P, Song N. Surgical resection of locally advanced pulmonary adenocarcinoma after gefitinib therapy. *Ann Thorac Surg* 2011;92:e11-12.
25. Ong M, Kwan K, Kamel-Reid S, Vincent M. Neoadjuvant erlotinib and surgical resection of a stage IIIA papillary adenocarcinoma of the lung with an L861Q activating EGFR mutation. *Curr Oncol* 2012;19:e222-226.
26. Lopez-Gonzalez A, Almagro E, Salas C, Varela A, Provencio M. Use of a tyrosine kinase inhibitor as neoadjuvant therapy for non-small cell lung cancer: A case report. *Respir Med Case Rep* 2013;9:8-10.
27. Marech I, Vacca A, Gnoni A, Silvestris N, Lorusso V. Surgical resection of locally advanced epidermal growth factor receptor (EGFR) mutated lung adenocarcinoma after gefitinib and review of the literature. *Tumori* 2013;99:e241-244.
28. Castellanos E, Feld E, Horn L. Driven by mutations: the predictive value of mutation subtype in EGFR-mutated non-small cell lung cancer. *J Thorac Oncol* 2017;12:612-623.
29. Puri V, Patel A, Majumder K, et al. Intraoperative conversion from video-assisted thoracoscopic surgery lobectomy to open thoracotomy: a study of causes and implications. *J Thorac Cardiovasc Surg* 2015;149:55-61.
30. Crino L, Weder W, van Meerbeeck J, Felip E, ESMO Guidelines Working Group. Early stage and locally advanced (non-metastatic) non-small-cell lung cancer: ESMO Clinical Practice Guidelines for diagnosis, treatment and follow-up. *Ann Oncol* 2010;21:v103-105.
31. Wu JX, He Q, Ye F, et al. EGFR-TKI-based vs non-EGFR-TKI-based adjuvant therapy in resected non-small-cell lung cancer with EGFR mutations: a meta-analysis of randomized controlled trials. *OncoTargets and Therapy* 2018;11:6803-6810.
32. Mitsudomi T, Morita S, Yatabe Y, et al. Gefitinib versus cisplatin plus docetaxel in patients with non-small-cell lung cancer harbouring mutations of the epidermal growth factor receptor (WJTOG3405): an open label, randomized phase 3 trial. *Lancet Oncol* 2010;11:121-128.
33. Rosell R, Carcereny E, Gervais R, et al. Erlotinib versus standard chemotherapy as first-line treatment for European patients with advanced EGFR mutation-positive non-small-cell lung cancer (EURTAC): a multicenter, open-label, randomized phase 3 trial. *Lancet Oncol* 2012;13:239-246.
34. Riely GJ, Pao W, Pham D, et al. Clinical course of patients with non-small cell lung cancer and epidermal growth factor exon 19 and exon 21 mutations treated with gefitinib or erlotinib. *Clin Cancer Res* 2006;12:839-844.

Tables

Table 1. Patient demographics and characteristics

Patients	Gender	Age	Stage	Tumor size (cm)	EGFR mutation	Neo-adjuvant TKI	Operation	Resected tumor size (cm)
No.1	Male	57	IIIB	2.2	Exon 21 L858R	Gefitinib	Lobectomy	1.5
No.2	Female	56	IIIB	1.7	Exon 21 L858R	Gefitinib	Wedge resection	1.7
No.3	Female	48	IVA	6.9	Exon 19 deletion	Gefitinib	Lobectomy	5.0
No.4	Female	50	IVA	2.3	Exon 19 deletion	Gefitinib	Lobectomy	1.9
No.5	Male	59	IIIB	7.8	Exon 21 L858R	Gefitinib	Lobectomy	5.6
No.6	Female	69	IIIB	6.6	Exon 21 L858R	Gefitinib	Lobectomy	6.0
No.7	Female	60	IIIB	6.4	Exon 19 deletion	Gefitinib	Lobectomy	2.5
No.8	Female	51	IVA	7.1	Exon 19 deletion	Gefitinib	Lobectomy	5.0
No.9	Female	36	IVA	2.6	Exon 19 deletion	Gefitinib	Lobectomy	1.7
No.10	Female	58	IVA	4.0	Exon 19 deletion	Gefitinib	Lobectomy	2.5
No.11	Female	27	IVA	5.0	Exon 19 deletion	Gefitinib	Lobectomy	1.5
No.12	Female	65	IIIB	7.7	Exon 21 L858R	Erlotinib	Lobectomy	4.0
No.13	Female	71	IIIB	2.7	Exon 19 deletion	Erlotinib	Lobectomy	2.5
No.14	Female	49	IVA	5.3	Exon 19 deletion	Gefitinib	Lobectomy	1.5
No.15	Female	52	IIIB	2.6	Exon 21 L858R	Gefitinib	Lobectomy	1.0

Table 2. Neoadjuvant and adjuvant therapy

Patients	Neo-adjuvant TKI interval (days)	Margin	Mortality Post-operation 90 days	Adjuvant therapy	Recurrence	Mortality at the end of Observation
No.1	48	R0	No	TKI (Gefitinib)	Extra-thoracic	Expired
No.2	209	R0	No	TKI (Erlotinib)	Intra-thoracic	Expired
No.3	40	R0	No	TKI (Gefitinib)	Extra-thoracic	Survival
No.4	61	R0	No	TKI (Gefitinib)	Extra-thoracic	Survival
No.5	47	R1	No	TKI (Gefitinib)	Intra-thoracic & Extra-thoracic	Expired
No.6	37	R1	No	Chemotherapy (Cisplatin + Etoposide)	Extra-thoracic	Survival
No.7	48	R0	No	TKI (Gefitinib)	Intra-thoracic	Survival
No.8	106	R0	No	TKI (Gefitinib)	Intra-thoracic	Survival
No.9	91	R0	No	Chemotherapy (Cisplatin + Vinorelbine)	Intra-thoracic	Expired
No.10	254	R0	No	TKI (Gefitinib)	Extra-thoracic	Survival
No.11	87	R1	No	TKI (Gefitinib)	Intra-thoracic & Extra-thoracic	Expired
No.12	78	R0	No	Chemotherapy (Cisplatin + Gemcitabine)	Extra-thoracic	Survival
No.13	86	R0	No	Chemotherapy (Cisplatin + Vinorelbine)	Intra-thoracic	Survival
No.14	36	R0	No	TKI (Gefitinib)	Intra-thoracic	Survival
No.15	243	R0	No	TKI (Gefitinib)	Nil	Survival

Figures

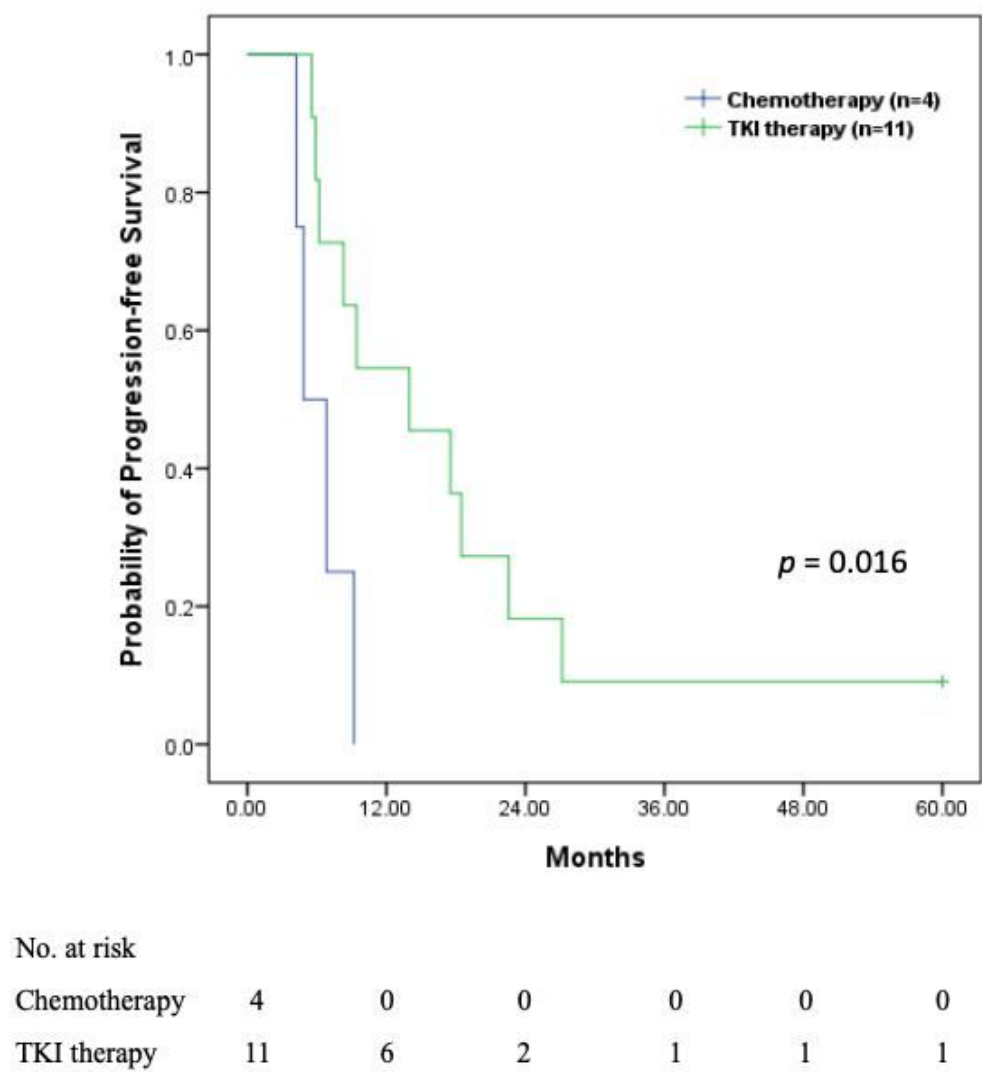
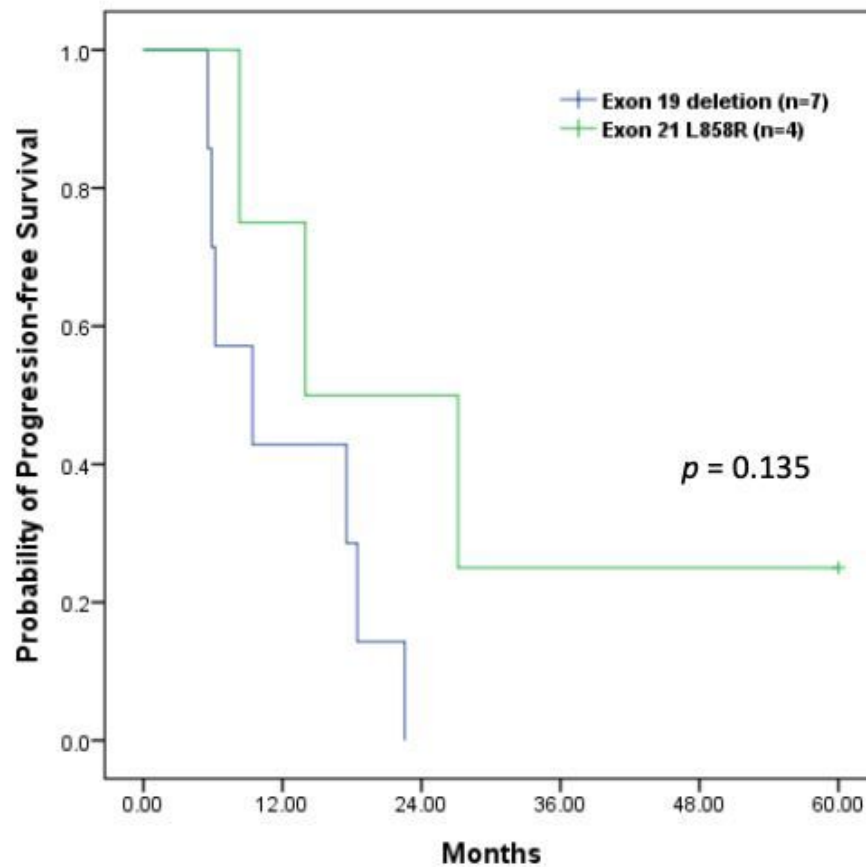


Figure 1

Progression-free survival of patients 11 patients received TKI therapy after thoracic surgery and 4 patients received adjuvant chemotherapy. PFS in the group of TKI therapy was superior to the group of chemotherapy.

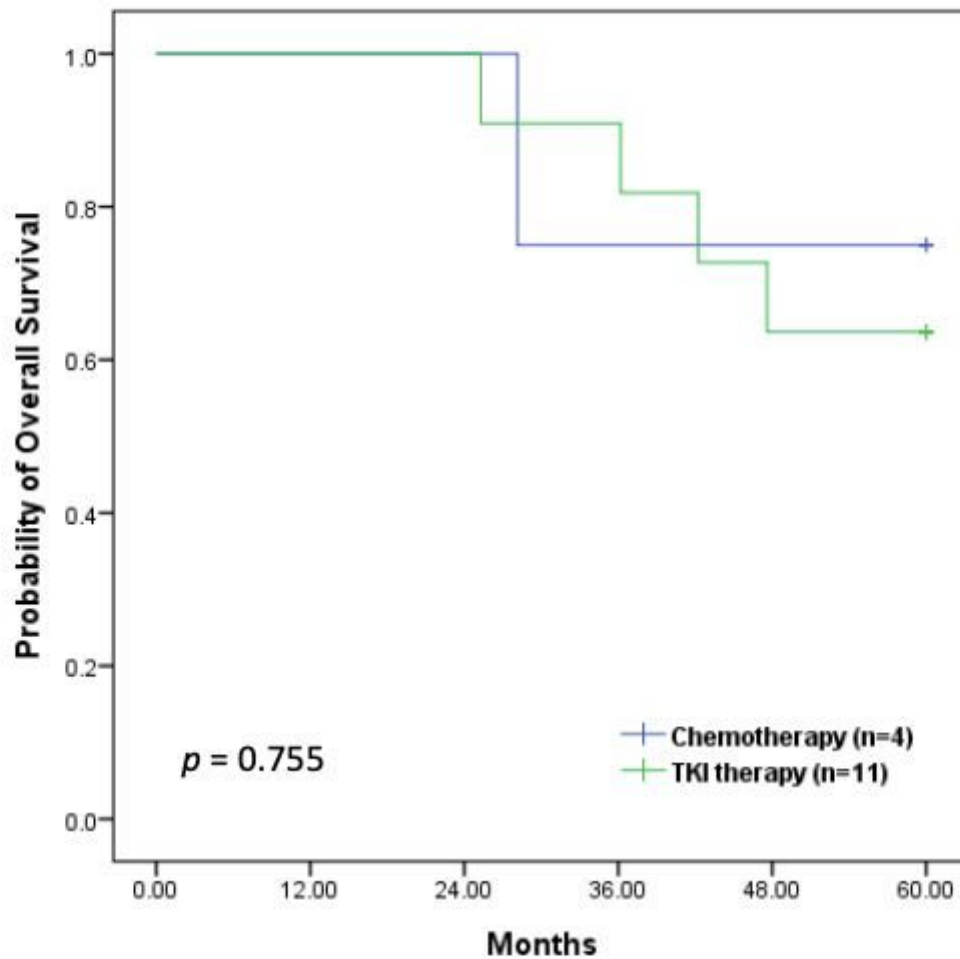


No. at risk

Exon 19 deletion	7	3	0	0	0	0
Exon 21 L858R	4	3	2	1	1	1

Figure 2

Progression-free survival of two EGFR mutants The median PFS in the group of exon 19 deletion was 9.4 months. The median PFS in the group of exon 21 L858R was 20.6 months.

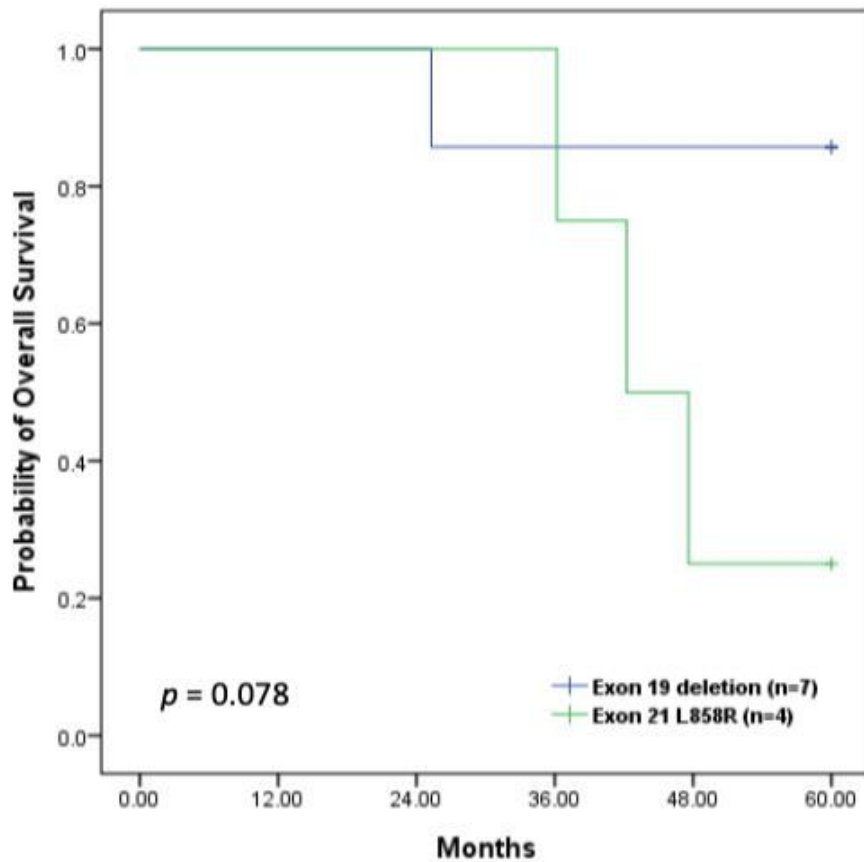


No. at risk

Chemotherapy	4	4	4	3	3	3
TKI therapy	11	11	11	10	7	7

Figure 3

Overall survival of patients 5-year survival rate was 75% in the group of adjuvant chemotherapy. 5-year survival rate was 63.6% in the group of adjuvant TKI therapy.



No. at risk						
Exon 19 deletion	7	7	7	6	6	6
Exon 21 L858R	4	4	4	4	1	1

Figure 4

Overall survival of two EGFR mutants 5-year survival rate was 85.7% in the group of exon 19 deletion. 5-year survival rate was 25% in the group of exon 21 L858R.