

Possible Vertebral Brucellosis Infection in a Neanderthal

Martin Haeusler (✉ Martin.Haeusler@iem.uzh.ch)

University of Zürich

Bruce Rothschild

Carnegie Museum of Natural History

Research Article

Keywords: brucellosis infection, Neanderthal, La Chapelle-aux-Saints 1, *Brucella melitensis*, vertebral

Posted Date: June 2nd, 2021

DOI: <https://doi.org/10.21203/rs.3.rs-567955/v1>

License: © ⓘ This work is licensed under a Creative Commons Attribution 4.0 International License.

[Read Full License](#)

Abstract

The La Chapelle-aux-Saints 1 skeleton of an old male Neanderthal is renowned for the advanced osteoarthritis of its spinal column and hip joint, and their implications for posture and lifestyle in these Mid- to Late Pleistocene humans. Reassessment of the pathologic lesions reveals erosions at multiple non-contiguous vertebrae and reactive bone formation extending far beyond the left hip joint, which suggests the additional diagnosis of brucellosis. This implies the earliest secure evidence of this zoonotic disease in hominin evolution. Brucellosis might have been transmitted via butchering or eating raw meat and is well compatible with the range of prey animals documented for Neanderthals. The associated infertility perhaps contributed to the demise of these late archaic humans.

Introduction

Review of the pathologic findings initially reported in the La Chapelle-aux-Saints 1 Neanderthal ¹⁻⁵ revealed alterations that appear attributable to the brucellosis. Today, brucellosis is globally the most prevalent zoonosis ⁶. It was first described by David Bruce on the island of Malta in 1885 ⁷ and originally referred to as Malta fever. Evans ⁸ provided the appellation brucellosis and its discovery in Malta is reflected in one of its species names, *Brucella melitensis*. Hughes ⁹ suggests that Hippocrates described it in 1450 BCE. The first clinical description is attributed to Marston ¹⁰. Other names derived from its symptoms [undulant fever and Lazybones disease (in China)], the veterinarian who identified its cause (Bang's disease), the employment of those affected by it (Corps disease), its epidemiologic geography (undulant Mediterranean fever or gastric remittent fever, Neapolitan fever, Gibraltar or Rock fever, Cyprus fever, Maltese fever, Crimean fever) ¹¹⁻¹⁴.

Brucellosis is caused by an acid-fast non-motile, gram negative facultative intracellular coccobacillus related to animal (*Anaplasma*, *Bartonella*, *Rickettsia* and *Wolbachia*) and plant pathogens (*Agrobacterium*, *Ochrobactrum* and *Sinorhizobium*) ^{15,16}. Although it occurs worldwide, it is predominantly recognized in the Mediterranean region, Asia and Latin America ¹⁷. There are at least 500,000 and perhaps 5–12 million new human cases each year ^{18,19}.

Brucellosis has a long history. The earliest occurrence was claimed in a 2.1-2.5-million-year-old *Australopithecus africanus* skeleton, StW 431 ²⁰. A re-examination of the affected lumbar vertebrae L4 and L5 of StW 431 suggested, however, that the vertebral marginal lesions are more likely attributable to a limbus vertebra, i.e., an anterior disc herniation ⁵. Other occurrences of brucellosis have been described in 3200 – 3000 BCE Bab edh-Dhra in Jordan ²¹, 350 BCE – 1200 CE Nubia ²², 2nd -4th century BCE Butrint Albania ²³, and 1st century Herculaneum ²⁴. A study of mitochondrial genomes in early Bronze Age humans from the Novosvobodnaya North Caucasus site revealed *Brucella abortus* ²⁵. We now examine evidence for its presence in a Neanderthal.

Results

All preserved vertebrae of La Chapelle-aux-Saints 1 showed mild to advanced osteoarthritic changes. Except for the cervical vertebrae, the ventral margin of the vertebral bodies was damaged. In the upper thoracic and the lumbar vertebrae, the ventral portions of the vertebral bodies were reconstructed by Boule¹ with plasticine. Nevertheless, the first two thoracic vertebrae were relatively well preserved and, as the lower cervical vertebrae, sustained only minor damage see also^{3,4,26}.

Confluent vertebral endplate erosions with new bone formation were observed at the inferior vertebral surface of C5 (Fig. 1). Anterior endplate grooves with smooth bases were observed in C6. Note the marginal endplate erosions (arrows).

Erosions were observed at the right facet joint C4/C5 (Fig. 2), the right facet joint C7/T1 (Fig. 3), and T9/T10 (Fig. 4).

The left hip bone is fragmentary (Fig. 5). The articular surface in the weight-bearing posterosuperior portion of the acetabulum is eburnated. The acetabular margin bears large osteophytes and shows reactive new bone formation with erosions extending to the extraarticular portion of the lower ilium and upper ischium. The left proximal femur is not preserved. The right hip joint showed moderate osteoarthritic changes. Eburnation of the subchondral bone was also observed in both proximal humeri.

Discussion

The possibility of osteoarthritis has been considered as an explanation for the vertebral and hip joint lesions observed in the La Chapelle-aux-Saints 1 Neanderthal²⁻⁴. More precisely, La Chapelle-aux-Saints 1 was thought to have suffered from both osteoarthritis and spondylosis deformans, as the term osteoarthritis is reserved for the disease of diarthrodial joints, while that appellation has been replaced by the term spondylosis deformans for the intervertebral disk articulations²⁷⁻²⁹. Both spondylosis deformans and osteoarthritis are recognized by production of osteophytes³⁰⁻³⁴.

Spondylosis and facet joint osteoarthritis as well as osteoarthritis of the peripheral joints affecting both glenohumeral joints and both hip joints can undoubtedly be observed in La Chapelle-aux-Saints 1. Yet, the presence of erosions and reactive bone formation extending far beyond the left hip joint and the presence of actual subchondral and marginal erosions at the vertebrae precludes attribution of all damage to osteoarthritis^{27,29}. Although the term erosion has also been applied to the cartilage damage that osteoarthritis produces, this damage is characterized by mechanical abrasion and fissures rather than by the inflammatory process that produce erosions in spondyloarthropathy or infection^{27,29,34,35}.

The pattern of the pathological changes observed in La Chapelle-aux-Saints 1 is characteristic of brucellosis infection. Thus, vertebrae are involved in 2–53% of brucellosis infections^{17,36,37}. Typically, the disease initially affects a single vertebral endplate, mostly in the lumbar spine, but it can also be observed at multiple levels, affecting non-contiguous endplates and facet joints also in the thoracic and cervical spine^{17,37}. In addition, monoarthritis or oligoarthritis may occur, with the knee and hip joints being most

commonly affected¹². The lesions have a specific erosive character and location seemingly pathognomonic for the disease, initially manifesting as an osteolysis/groove on the anterior aspect of superior vertebral endplates^{17,38-41}. Specifically referred to as Pedro i Pons' sign^{42,43}, such grooves are not found with pyogenic (e.g., *Staphylococcus*) vertebral infections⁴⁴ or tuberculosis²⁷. Unfortunately, this characteristic destruction of the anterosuperior margin of the lumbar vertebrae cannot be observed in La Chapelle-aux-Saints 1 due to taphonomic damage of the anterior portion of all thoraco-lumbar vertebrae.

Examination of vertebrae C5 and C6 of La Chapelle-aux-Saints 1 revealed, however, erosive changes to the inferior vertebral surface (Fig. 1) that do not occur in spondyloarthropathy^{27,29,45}. The smooth character of the base of the groove in C6 evidences reactive new bone formation and not simply taphonomic bone loss (which would have exposed trabecular bone). Confluent erosion with new bone formation is quite different from the edge (Romanus) lesions noted with spondyloarthropathy^{27,46}. That appellation refers to apophyseal ring erosion, producing loss of the edge of the endplate in spondyloarthropathy, in contrast to production of a groove on its subchondral (disk-facing) surface. Such vertebral endplate grooves, however, are quite characteristic of the damage caused by brucellosis^{17,38-43}. In later stages of the infection, the erosive changes gradually expand over the entire vertebral endplate, producing the condition seen in vertebra C5.

Notation of erosions of the right facet joint of C4-C5 and C7-T1 and both facet joints of T9-T10 (Fig. 2-4) suggested differential diagnostic consideration of spondyloarthropathy or granulomatous infection. Facet joint involvement is found in up to one-third of individuals with brucellosis^{6,39,47,48}. However, such erosions of the facet joints and vertebral endplate are not anticipated with spondyloarthropathy^{27,29,45}. In addition, the transverse process of T1 and the laminae of T10 show large erosions characteristic of a space-occupying granulomatous process (see Figs. 3 and 4)^{27,49-51}. The latter are caused by infectious processes attributed to tuberculosis, fungal disease and brucellosis^{27,29}. Fungal disease produces erosions that do not respect variation in bone density, preserving a spheroid shape⁴⁹. Tuberculosis is characterized by zones of bone resorption^{29,51}. Neither pattern is observed in the La Chapelle-aux-Saints 1 Neanderthal.

The severe arthritic changes at the left hip joint have previously been attributed to trauma³, but there is otherwise no evidence for trauma. The presence of erosions and new bone formation suggest that on top of the age-related primary osteoarthritis that might initially have been present (and which can also be observed in the right hip joint and both humeri), a secondary phenomenon, i.e., hip joint infection by brucellosis occurred. In fact, osteoarthritis-related changes would be confined to the joint region itself and do not extend to the extra-articular region as it is the case of La Chapelle-aux-Saints 1. Inflammatory processes that extend beyond the joint region are, however, not unusual in brucellosis, analogous to the paraspinal granulomas probably present in vertebrae T1 and T10 see also¹².

Neanderthals likely were infected by brucellosis during butchering of prey animals, not unlike the abattoir experience today¹³, or by eating raw meat. The main causative organisms of brucellosis have been found in a wide range of wildlife. Particularly, *Brucella melitensis* has been reported in ibex and chamois, while *B. abortus* and *B. suis* have a preference for most other bovines and suids, including wild sheep, goats, horses, wild cattle, European bison, reindeer, roe and red deer, wild boar, but also hares and marmots⁵²⁻⁵⁶. All these animals were important components of the Neanderthal diet⁵⁷⁻⁵⁹. Only the two largest Neanderthal prey animals, mammoths and woolly rhinoceros, might not have been reservoirs for *Brucella* as inferred from their extant relatives⁶⁰⁻⁶². The host preference of the different *Brucella* species might suggest that La Chapelle-aux-Saints 1 was infected by *B. abortus* rather than *B. melitensis*. While the latter species often leads to acute pain and immobilization, *B. abortus* is known to cause a milder course of the disease. This might therefore explain the advanced stage of the arthritis in La Chapelle-aux-Saints 1 and his survival to the advanced age of perhaps well over 60 years²⁶.

Symptoms of brucellosis not only include fever, arthritis, endocarditis, neurologic defects, spinal deformity, reduced milk production, but also epididymitis/orchitis, infertility, still births and abortions⁶³. The latter could perhaps have been part of what led to the demise of Neanderthals, although the prevalence of brucellosis in Upper Palaeolithic modern humans is still unknown.

Material And Methods

The La Chapelle-aux-Saints 1 burial of an old male Neanderthal was discovered in 1908 in a pit in the Bouffia Bonneval cave near the village of La Chapelle-aux-Saints in south-western France¹, together with dental remains of four additional individuals. Electron spin resonance (ESR) dating suggested a geological age of 47 ka ± 3 ka BP (early U-uptake model) or 56 ka ± 4 ka BP (linear U-uptake model)⁶⁴. The auricular surface of the ilium suggests an individual age of 62 ± 13 years²⁶. The partial skeleton preserves an almost complete skull with extensive post-canine tooth loss, a scapular fragment, portions of all long bones and both hipbones, as well as 19 variously complete vertebrae and a partial sacrum. The vertebrae include C1 and C2, C4 to T2, two fragmentary upper thoracic vertebrae (possibly T3 or T4 and T6 or T7), T8 to T12, L1, and L3 to S2^{26,65}.

The vertebrae of the La Chapelle-aux-Saints 1 Neanderthal were examined macroscopically and at 10× electronic magnification to characterize the presence and nature of vertebral endplate and facet alterations. In addition, CT scans of the vertebrae performed by the Musée de l'Homme were examined. All fossil bones were also surface scanned using a high-resolution surface scanner (PT-M4c, Polymetric GmbH, Darmstadt, Germany)⁶⁶.

The right hipbone is currently missing, and a cast as well as old photographs (courtesy of Eric Trinkaus) were examined.

Declarations

Acknowledgements

We thank D. Grimaud-Hervé, L. Huet, V. Laborde, and A. Balzeau (Musée de l'Homme, Muséum Nationale d'Histoire Naturelle, Paris) for access to the La Chapelle-aux-Saints fossil remains. Financial support was provided by the Swiss National Science Foundation Grant Nos. 31003A_156299 and 31003A_176319 as well as the Mäxi Foundation, Switzerland.

Author contribution

BR and MH conceived the study, analysed the data and wrote the manuscript.

Competing interests

The authors declare no competing interests.

Data and materials availability

All data analysed during this study are included in this published article. The La Chapelle-aux-Saints 1 skeleton is housed at the Musée de l'Homme, Paris.

References

1. Boule, M. L'homme fossile de La Chapelle-aux-Saints. *Annales de Paléontologie* **6-8**, 1–271 (1911-1913).
2. Straus, W. L. & Cave, A. J. E. Pathology and the posture of Neanderthal man. *Q. Rev. Biol.* **32**, 348–363 (1957).
3. Trinkaus, E. Pathology and the posture of the La Chapelle-aux-Saints Neandertal. *Am. J. Phys. Anthropol.* **67**, 19–41 (1985).
4. Dawson, J. E. & Trinkaus, E. Vertebral osteoarthritis of the La Chapelle-aux-Saints 1 Neanderthal. *J Archaeol Sci* **24**, 1015–1021 (1997).
5. Haeusler, M. in *Spinal Evolution: morphology, function, and pathology of the spine in hominoid evolution* (eds Ella Been, A. Gómez-Olivencia, & P.A. Kramer) Ch. 10, 213–245 (Springer, 2019).
6. Buzgan, T. *et al.* Clinical manifestations and complications in 1028 cases of brucellosis: a retrospective evaluation and review of the literature. *Int. J. Infect. Dis.* **14**, e469–e478 (2010).
7. Gotuzzo, E. in *Tropical Infectious Diseases: Principles, Pathogens and Practice* (eds Richard L Guerrant, David H Walker, & Peter F Weller) 498–504 (Churchill Livingstone, 2011).
8. Evans, A. C. Further studies on *Bacterium abortus* and related bacteria II. A comparison of *Bacterium abortus* with *Bacterium bronchisepticus* and with the organism which causes Malta fever. *J. Infect. Dis.* **22**, 580–593, doi:10.1093/infdis/22.6.580 (1918).
9. Hughes, M. L. *Mediterranean, Malta or undulant fever.* (Macmillan, 1897).
10. Marston, J. Report on fever (Malta). *Army Medical Department Reports* **3**, 486–521 (1861).

11. Bang, B. The etiology of epizootic abortion. *Journal of Comparative Pathology and Therapeutics* **10**, 125–149 (1897).
12. Madkour, M. M. *Madkour's Brucellosis*. 2nd edn, (Springer, 2001).
13. Rossetti, C. A., Arenas-Gamboa, A. M. & Maurizio, E. Caprine brucellosis: A historically neglected disease with significant impact on public health. *PLoS Neglected Tropical Diseases* **11**, e0005692 (2017).
14. Zhang, J. *et al.* Prediction and control of brucellosis transmission of dairy cattle in Zhejiang Province, China. *PLoS ONE* **9**, e108592 (2014).
15. Guzmán-Verri, C. *et al.* *Brucella ceti* and brucellosis in cetaceans. *Frontiers in Cellular and Infection Microbiology* **2**, 00003, doi:10.3389/fcimb.2012.00003 (2012).
16. Martirosyan, A., Moreno, E. & Gorvel, J. P. An evolutionary strategy for a stealthy intracellular *Brucella* pathogen. *Immunol. Rev.* **240**, 211–234 (2011).
17. Raptopoulou, A. *et al.* Brucellar spondylodiscitis: noncontiguous multifocal involvement of the cervical, thoracic, and lumbar spine. *Clin. Imaging* **30**, 214–217 (2006).
18. Hull, N. C. & Schumaker, B. A. Comparisons of brucellosis between human and veterinary medicine. *Infection Ecology & Epidemiology* **8**, 1500846 (2018).
19. Pappas, G., Papadimitriou, P., Akritidis, N., Christou, L. & Tsianos, E. V. The new global map of human brucellosis. *Lancet Infect Dis* **6**, 91–99, doi:10.1016/S1473-3099(06)70382-6 (2006).
20. D'Anastasio, R., Zipfel, B., Moggi-Cecchi, J., Stanyon, R. & Capasso, L. Possible brucellosis in an early hominin skeleton from Sterkfontein, South Africa. *PLoS ONE* **4**, e6439, doi:10.1371/journal.pone.0006439 (2009).
21. Rashidi, J., Ortner, D., Frohlich, B. & Jonsdottir, B. Brucellosis in Early Bronze Age Jordan and Bahrain: an analysis of possible cases of *Brucella* spondylitis. *Am. J. Phys. Anthropol. Suppl.* **32**, 122–123 (2001).
22. Aubin, M. M. Brucellosis in ancient Nubia: Morbidity in biocultural perspective through time at Semna South, Sudan. *Am. J. Phys. Anthropol. Suppl.* **37**, 56 (2004).
23. Mutolo, M. J., Jenny, L. L., Buszek, A. R., Fenton, T. W. & Foran, D. R. Osteological and molecular identification of Brucellosis in ancient Butrint, Albania. *Am. J. Phys. Anthropol.* **147**, 254–263, doi:10.1002/ajpa.21643 (2012).
24. Capasso, L. Brucellosis at Herculaneum (79 AD). *Int J Osteoarchaeol* **9**, 277–288, doi:10.1002/(Sici)1099-1212(199909/10)9:5<277::Aid-Oa489>3.3.Co;2-S (1999).
25. Sokolov, A. S. *et al.* Six complete mitochondrial genomes from Early Bronze Age humans in the North Caucasus. *J Archaeol Sci* **73**, 138–144, doi:10.1016/j.jas.2016.07.017 (2016).
26. Haeusler, M. *et al.* Morphology, pathology and the vertebral posture of the La Chapelle-aux-Saints Neandertal. *Proc. Natl. Acad. Sci. U.S.A.* **116**, 4923–4927, doi:10.1073/pnas.1820745116 (2019).
27. Resnick, D. *Diagnosis of Bone and Joint Disorders*. (Saunders, 2002).
28. Rothschild, B. M. *Lumbar spondylosis*, 2020).

29. Rothschild, B. M. & Martin, L. D. *Skeletal impact of disease*. Vol. 33 (New Mexico Museum of Natural History and Science, 2006).
30. Altman, R. *et al.* Development of criteria for the classification and reporting of osteoarthritis. Classification of osteoarthritis of the knee. Diagnostic and Therapeutic Criteria Committee of the American Rheumatism Association. *Arthritis Rheum.* **29**, 1039–1049 (1986).
31. Altman, R. *et al.* The American-College-of-Rheumatology criteria for the classification and reporting of osteoarthritis of the hand. *Arthritis Rheum.* **33**, 1601–1610, doi:10.1002/art.1780331101 (1990).
32. Altman, R. *et al.* The American-College-of-Rheumatology criteria for the classification and reporting of osteoarthritis of the hp. *Arthritis Rheum.* **34**, 505–514, doi:10.1002/art.1780340502 (1991).
33. Rothschild, B. M. Radiologic assessment of osteoarthritis in dinosaurs. *Annals of Carnegie Museum* **49**, 295–301 (1990).
34. Rothschild, B. M. (ed B. Rothschild) (InTech, Rijeka, Croatia, 2012).
35. Rothschild, B. M. Reply to a letter by Inoue *et al.* *Rheumatology (Oxford)*. **40**, 1073–1074, doi:10.1093/rheumatology/40.9.1073 (2001).
36. Lifeso, R. M., Harder, E. & McCorkell, S. J. Spinal brucellosis. *The Journal of bone and joint surgery. British volume* **67**, 345–351 (1985).
37. Colmenero, J. D. *et al.* Complications associated with *Brucella melitensis* infection: a study of 530 cases. *Medicine (Baltimore)*. **75**, 195–211 (1996).
38. Ariza, J. *et al.* Brucellar spondylitis: a detailed analysis based on current findings. *Rev. Infect. Dis.* **7**, 656–664 (1985).
39. Chelli Bouaziz, M., Ladeb, M. F., Chakroun, M. & Chaabane, S. Spinal brucellosis: a review. *Skeletal Radiol.* **37**, 785–790, doi:10.1007/s00256-007-0371-x (2008).
40. Madkour, M. M. & Sharif, H. in *Madkour's Brucellosis* (ed M. Monir Madkour) 92–132 (Springer, 2001).
41. Zhao, Y. T., Yang, J. S., Liu, T. J., He, L. M. & Hao, D. J. Sclerosing vertebra in the spine: typical sign of spinal brucellosis. *Spine J* **15**, 550–551, doi:10.1016/j.spinee.2014.10.025 (2015).
42. Pedro i Pons, A. La espondilitis melitococica. *Anales de Medicina: Butlletí Mensual de L'Acadèmia: Laboratori de Ciències Mèdiques de Catalunya* **23**, 227–236 (1929).
43. Pedro-Pons, A. & Valenti, P. F. *La Brucelosis Humana (Fiebre de Malta – enfermedad de Bang)*. (Salvat Editores, 1944).
44. Waldvogel, F. A., Medoff, G. & Swartz, M. N. Osteomyelitis: a review of clinical features, therapeutic considerations and unusual aspects. *N. Engl. J. Med.* **282**, 260–266 (1970).
45. Rothschild, B. M. & Woods, R. J. Spondyloarthropathy: erosive arthritis In representative defleshed bones. *Am. J. Phys. Anthropol.* **85**, 125–134 (1991).
46. Hermann, K.-G. A. *et al.* Spinal changes in patients with spondyloarthritis: Comparison of MR imaging and radiographic appearances. *Radiographics* **25**, 559–569, doi:10.1148/rg.253045117 (2005).

47. King-Brown, R. & Recht, W. *Brucella spondylitis*: Review of the literature and report on two cases. *Postgrad. Med. J.* **28**, 250–254 (1952).
48. Özaksoy, D. *et al.* Brucellar spondylitis: MRI findings. *Eur. Spine J.* **10**, 529–533, doi:10.1007/s005860100285 (2001).
49. Hershkovitz, I., Rothschild, B. M., Dutour, O. & Greenwald, C. Clues to recognition of fungal origin of lytic skeletal lesions. *Am. J. Phys. Anthropol.* **106**, 47–60 (1998).
50. Rothschild, B. M. & Rothschild, C. in *Tuberculosis, Past and Present* (eds G Palfi, O Dutour, J Deak, & I Hutás) 293–298 (Golden Book Publisher Ltd., Tuberculosis Foundation, 1999).
51. Rothschild, B. M. *et al.* *Mycobacterium tuberculosis* complex DNA from an extinct bison dated 17,000 years before the present. *Clin. Infect. Dis.* **33**, 305–311 (2001).
52. Angus, R. D., Brown, G. M. & Gue, C. S., Jr. Avian brucellosis: A case report of natural transmission from cattle. *Am. J. Vet. Res.* (1971).
53. D'Anastasio, R., Staniscia, T., Milia, M. L., Manzoli, L. & Capasso, L. Origin, evolution and paleoepidemiology of brucellosis. *Epidemiol. Infect.* **139**, 149–156 (2011).
54. Godfroid, J., Garin-Bastuji, B., Saegerman, C. & Blasco, J. M. Brucellosis in terrestrial wildlife. *Rev. Sci. Tech.* **32**, 27–42, doi:10.20506/rst.32.1.2180 (2013).
55. Vana, S. Brucellosis in wildlife. *Iowa State Univ. Vet.* **42**, 4 (1980).
56. Scholz, H. C. *et al.* *Brucella inopinata* sp. nov., isolated from a breast implant infection. *Int J Syst Evol Microbiol* **60**, 801–808, doi:10.1099/ijms.0.011148-0 (2010).
57. Discamps, E., Jaubert, J. & Bachellerie, F. Human choices and environmental constraints: deciphering the variability of large game procurement from Mousterian to Aurignacian times (MIS 5-3) in southwestern France. *Quaternary Science Reviews* **30**, 2755–2775, doi:10.1016/j.quascirev.2011.06.009 (2011).
58. Germonpré, M., Udrescu, M. & Fiers, E. The fossil mammals of Spy. *Anthropologica et praehistorica* **123**, 298–327 (2013).
59. Weyrich, L. S. *et al.* Neanderthal behaviour, diet, and disease inferred from ancient DNA in dental calculus. *Nature* **544**, 357–361, doi:10.1038/nature21674 (2017).
60. Aruho, R., MacLeod, E. T., Manirakiza, L. & Rwego, I. B. A serological survey of brucellosis in wildlife in four major National Parks of Uganda. *BMC Veterinary Research* **17**, 95, doi:10.1186/s12917-021-02782-4 (2021).
61. Fischer-Tenhagen, C., Hamblin, C., Quandt, S. & Frölich, K. Serosurvey for selected infectious disease agents in free-ranging black and white rhinoceros in Africa. *J. Wildl. Dis.* **36**, 316–323, doi:10.7589/0090-3558-36.2.316 (2000).
62. Ngamkala, S., Angkawanish, T., Nokkaew, W. & Thongtip, N. Serological study on brucellosis in captive elephants (*Elephas maximus*) and stray dogs in North Thailand. *Veterinary world* **13**, 1992–1997, doi:10.14202/vetworld.2020.1992-1997 (2020).

63. Lokamar, P. N., Kutwah, M. A., Atieli, H., Gumo, S. & Ouma, C. Socio-economic impacts of brucellosis on livestock production and reproduction performance in Koibatek and Marigat regions, Baringo County, Kenya. *BMC veterinary research* **16**, 1–13 (2020).
64. Raynal, J.-P. in *La Chapelle-aux-Saints et la préhistoire en Corrèze* (eds J. P. Raynal & Y. Pautrat) 43–46 (Association pour la Recherche Archéologique en Limousin, 1990).
65. Gómez-Olivencia, A. Back to the old man's back: Reassessment of the anatomical determination of the vertebrae of the Neandertal individual of La Chapelle-aux-Saints. *Annales de Paléontologie* **99**, 43–65, doi:10.1016/j.annpal.2012.07.002 (2013).
66. Häusler, M., Schweitzer, W., Braun, M., Brüscheiler, W. & Bär, W. Evaluation von 3D-Scanner für den Einsatz in der Rechtsmedizin. *Rechtsmedizin* **14**, 356–357 (2004).

Figures

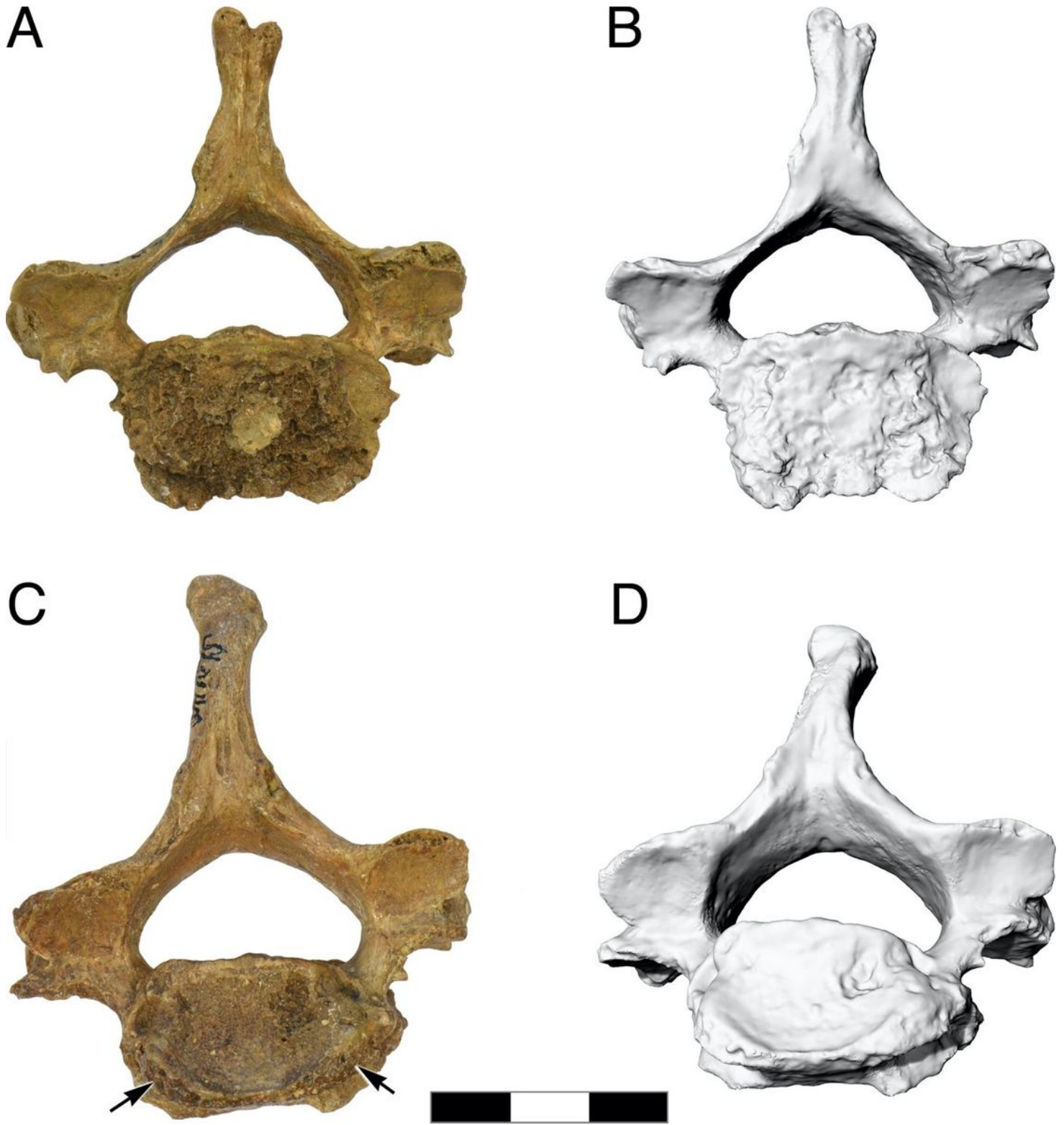


Figure 1

La Chapelle-aux-Saints 1 cervical vertebrae C5 and C6. A, B) Photograph and 3D surface scan of vertebra C5, inferior view, C, D) photograph and 3D surface scan of vertebra C6, inferior view. Note the marginal erosions (arrows). Scale bar 3 cm.

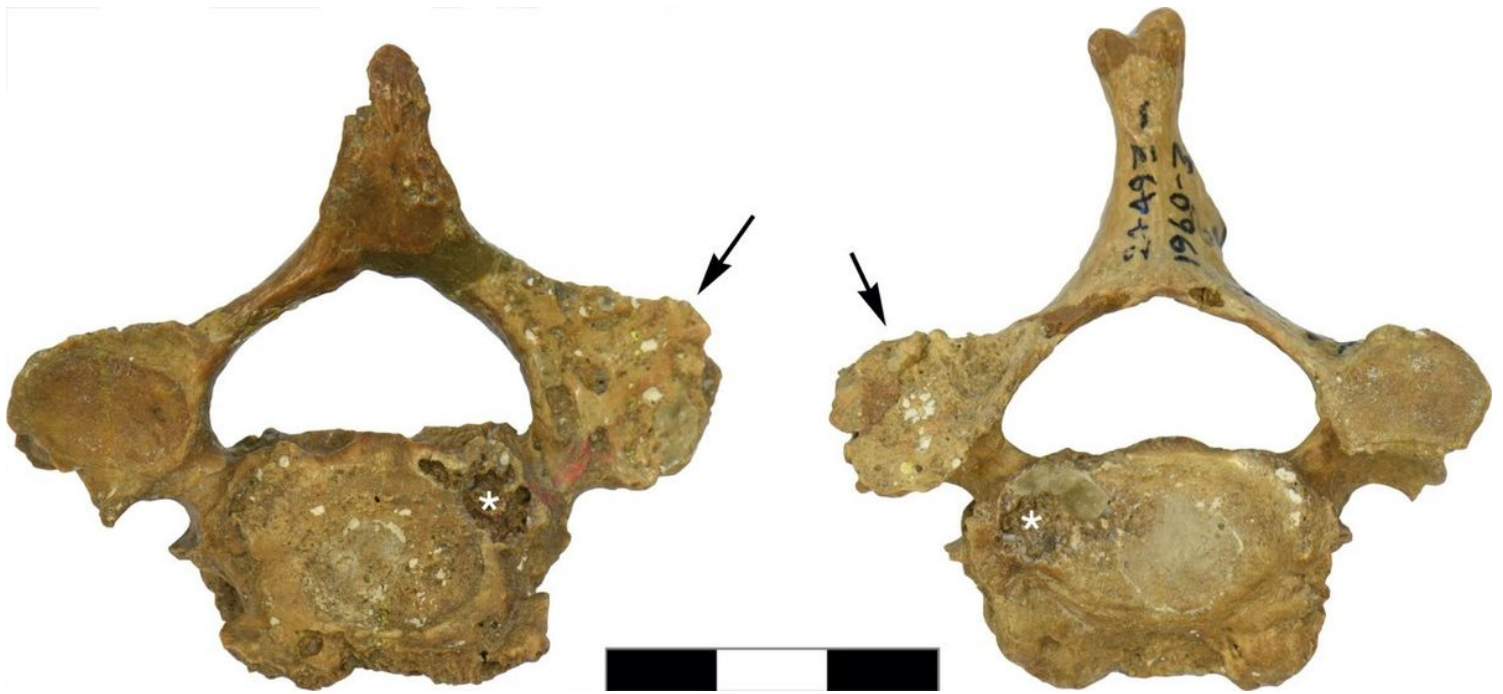

Figure 2

La Chapelle-aux-Saints 1 cervical vertebra 4, inferior view (left) and cervical vertebra 5, superior view (right). The right facet joint of C4-C5 is severely remodeled and shows multiple fine erosions (arrows). White asterisks (*) denote taphonomic damage to the vertebral surface. Scale bar 3 cm.

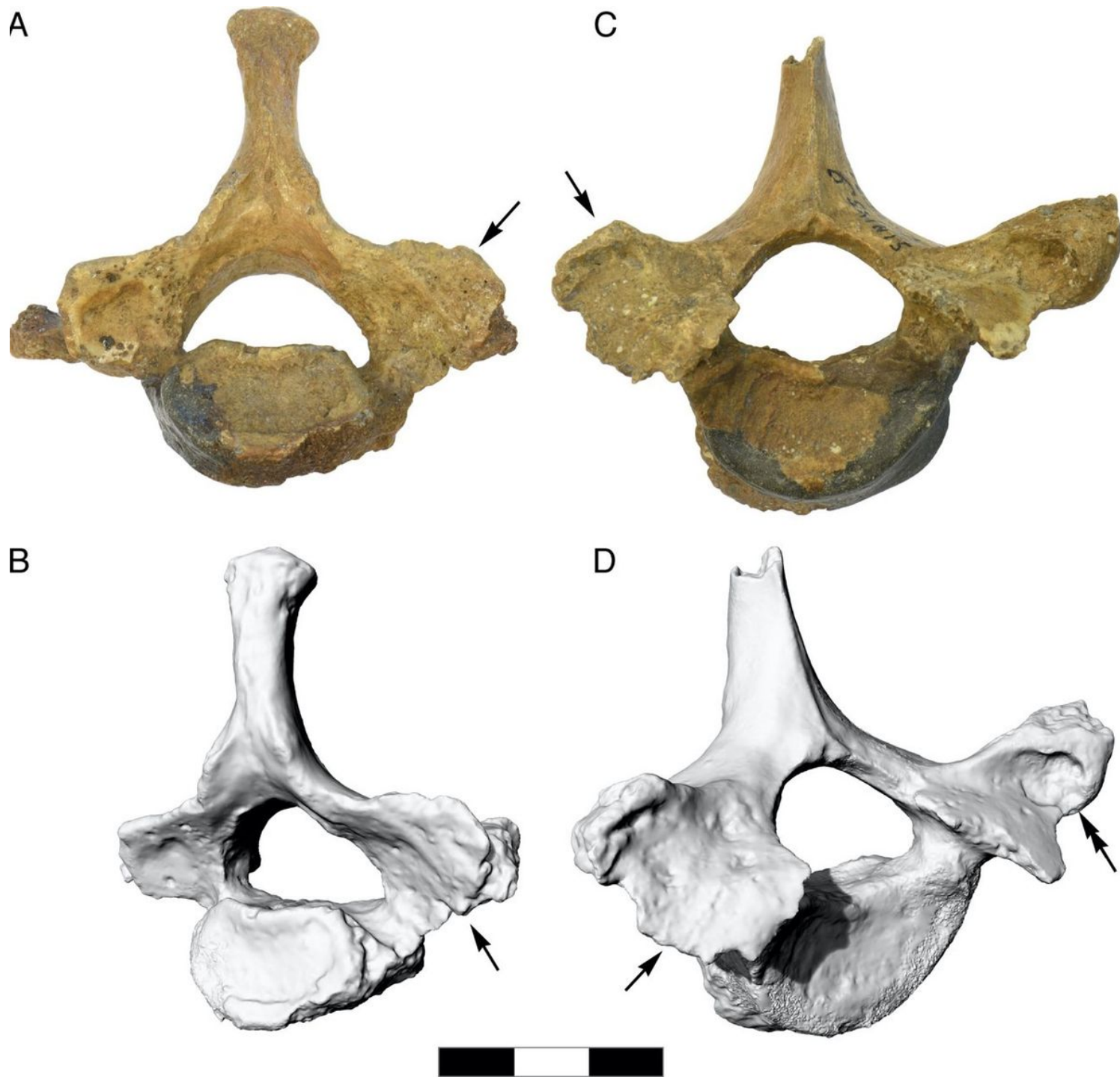


Figure 3

La Chapelle-aux-Saints 1 cervical vertebra C7 and thoracic vertebra T1. A, B) Photograph and 3D surface scan of C7, inferior view, C, D) photograph and 3D surface scan of T1, superior view. The right facet joint of C7-T1 is severely remodeled and shows multiple fine erosions (arrows). The transverse process of T1 shows a large erosive defect suggestive of a space-occupying granulomatous process (double arrows). Scale bar 3 cm.

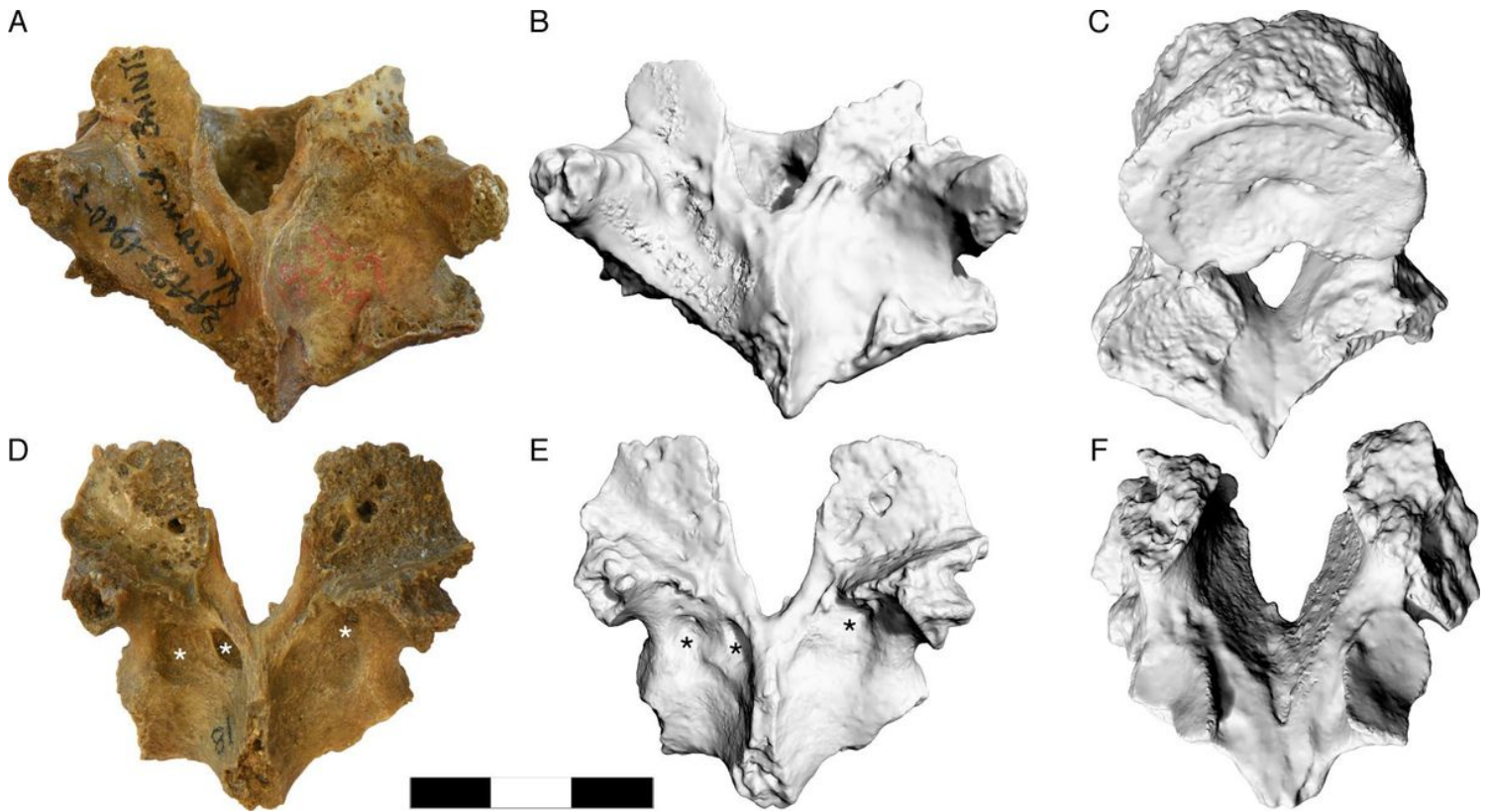


Figure 4

La Chapelle-aux-Saints 1 thoracic vertebrae 9 and 10, showing erosion of the facet joints T9-T10. A) photograph of T9, dorsal view; the left superior facet joint of T9 is unaffected, while the right superior facet joint shows osteoarthritic changes with eburnation; the left inferior facet joint of T9 is broken off, the right inferior facet joint is severely remodeled and shows multiple fine erosions, B) 3D surface scan of T9, dorsal view, C) 3D surface scan of T9, oblique inferior view. D) photograph of T10, dorsal view, E) 3D surface scan of T10, dorsal view, F) 3D surface scan of T10, oblique inferior view; the inferior facet joints of T10 are unaffected. Asterisks denote possible erosive defects caused by space-occupying granulomatous processes. Scale bar 3 cm.

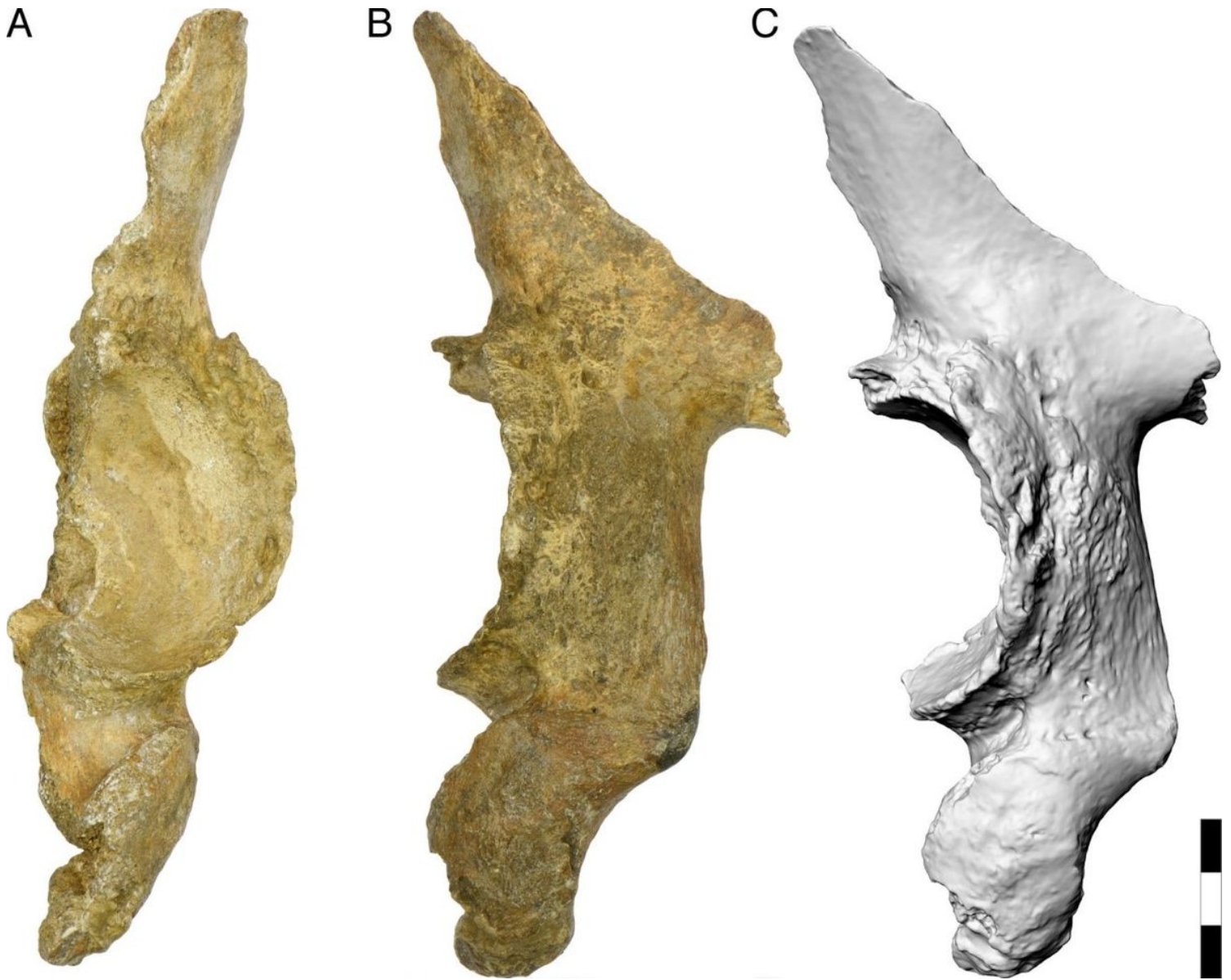


Figure 5

The partial left hipbone of La Chapelle-aux-Saints 1, A) photograph in lateral view, B) posterior view. C) 3D surface scan, oblique posterior view. Note the presence of erosions and new bone formation that extends far beyond the hip joint. This does not occur in osteoarthritis, but is compatible with extra-articular granulomas in brucellosis. Scale bar 3 cm.