

# Diagnosis and Individualized Nutritional Management of Primary Intestinal Lymphangiectasia in Children: A Clinical Conundrum

Yang Niu (✉ [niuyang@xinhumed.com.cn](mailto:niuyang@xinhumed.com.cn))

Shanghai Jiaotong University School of Medicine Xinhua Hospital <https://orcid.org/0000-0002-7074-3382>

Qingqing Wu

Shanghai Jiaotong University School of Medicine Xinhua Hospital

Ying Wang

Shanghai Jiaotong University School of Medicine Xinhua Hospital

Lina Lu

Shanghai Jiaotong University School of Medicine Xinhua Hospital

Wei Cai

Shanghai Jiaotong University School of Medicine Xinhua Hospital

Qingya Tang

Shanghai Jiaotong University School of Medicine Xinhua Hospital

---

## Research Article

**Keywords:** Primary intestinal lymphangiectasia, Diagnosis, Treatment, MCT diet

**Posted Date:** June 2nd, 2021

**DOI:** <https://doi.org/10.21203/rs.3.rs-552541/v1>

**License:** © ⓘ This work is licensed under a Creative Commons Attribution 4.0 International License. [Read Full License](#)

---

# Abstract

**Background:** Primary Intestinal Lymphangiectasia (PIL) is a rare congenital and digestive disease, which could present through a broad spectrum of clinical manifestations, diagnostic and treatment management. The aim of this study was to introduce the diagnosis and nutrition treatment of children with IL through the twelve years of experience.

**Methods:** The patients diagnosed with PIL admitted to the Department of Gastroenterology and Nutrition in Xinhua Hospital from June, 2006 to September, 2017 were included in the study. Basic information and laboratory results were collected from the medical records.

**Results:** Ten patients were found to have PIL. The mean age was 66 months at the time of diagnosis and 11 months at onset. The main clinical manifestations were diarrhea, edemas and abdominal distention. Marked dilatation of the intestinal lymphatic vessels was the characteristic of the endoscopic. All the patients presented with hypoproteinemia and hypoimmunoglobulinia. 6 of them were treated with parenteral nutrition, and 9 of them were treated with a low-LCT (long-chain triglycerides), high-protein diet supplemented with MCT (medium-chain triglycerides). The clinical symptoms of the patients have improved after the MCT diet therapy.

**Conclusion:** PIL should be considered first when there are clinical manifestations of chronic diarrhea, edema and abdominal distention, and biochemical results indicated the hypoproteinemia and hypoimmunoglobulinia, and the general treatment is invalid. Gastroscopy and E-colonoscopy with biopsies are the preferred method of diagnosis. MCT diet is the cornerstone and longtime medical treatment, which can improve the nutritional status and promote the survival quality of patients with IL.

**Trial registration:** This study was reviewed and approved by the Research Ethics Committee of Xinhua Hospital, School of Medicine, Shanghai Jiao Tong University.

## Background

Defined in 1961 by Waldmann TA <sup>[1]</sup>, Primary intestinal lymphangiectasia (PIL) is a rare disorder of the lymphatic system. PIL can be characterized by dilatation of lymphatics of mucosa, submucosa, serosa and mesentery of bowel resulting in secondary lymphatic leakage <sup>[2]</sup>. The incidence of PIL is very low, but the exact worldwide prevalence and incidence of PIL are still unknown <sup>[3–4]</sup>. After 1961, Less than 200 cases have been reported worldwide <sup>[8]</sup>. There is no special predilection for sex and ethnicity <sup>[4]</sup>. The age at time of diagnosis of PIL is commonly at or before 3 years <sup>[4–5]</sup>. Nevertheless, diagnoses after the age of 3 in the literature were also reported, such as the study published by V Surampalli in 2017 and Suresh in 2008 <sup>[13–14]</sup>. PIL can present through a broad spectrum of clinical manifestations, diagnostic and treatment management. The aim of this study was to introduce the clinical manifestations, biochemical, radiologic, endoscopic characteristics and treatment of children with PIL through the twelve years of experience.

## Materials And Methods

A descriptive and retrospective study was conducted on children diagnosed with PIL. From June, 2006 to September, 2017. Ten inpatient children at Xinhua Hospital diagnosed with PIL were enrolled into this study. A complete medical history was taken for each patient, including sex, age at the time of diagnosis, height, weight, physical examination, clinical manifestations, laboratory test (Total Protein, Albumin, Calcium, Cuprum, Zinc, IgA, IgG, IgM and Lymphocytes), imagological examination (Gastroscopy, E-colonoscopy and Capsule Endoscopy) and treatments.

## Statistical analysis

The variables were analyzed using the SPSS version 24.0 program. Frequencies and measures of central tendency and dispersion were used for the categorical variables and the quantitative variables respectively.

## Results

Ten patients diagnosed with PIL from June, 2006 to September, 2017 were enrolled in our study, and 5 of them were male. The mean age at the time of diagnosis was 66 months (range from 14 to 144 months), and the mean age at onset was 11 months (range from 0 to 48 months) in Table 1. The age at onset of 90% (9/10) of patients was before 2 years old. However, only 40% (4/10) of patients were diagnosed before 3 years old, 60% (6/10) were diagnosed after 7 years from the time of onset because of misdiagnosis or indefinite diagnosis in other hospitals. The clinical manifestations were shown in Table 1. 80% (8/10) of patients were present with edema as a consequence of hypoproteinemia and diarrhea at the same time. Abdominal distention were observed in 90% (9/10) of patients. The weight of patient 6 and patient 10 was within the abnormal range according to the standard of 2000 CDC Growth Charts.

Table 1  
Clinical characteristics of the 10 patients with PIL

Patient	Sex(M/F)*	Age at time of diagnosis(month)	Age at onset(month)	Diarrhea	Edemas	Abdominal Distention	Weight at time of diagnosis (kg)	Percentile (%)
1	M	75	9	Y	Y	N	19	P10-P25
2	M	20	4	Y	Y	Y	12	P50-P75
3	F	25	4	Y	Y	Y	14	P75-P90
4	M	144	48	N	N	Y	40	P50
5	F	96	0	N	N	Y	24	P25-P50
6	F	66	18	Y	Y	Y	14.5	<P3
7	M	14	6	Y	Y	Y	11	P75-P90
8	F	121	0.25	Y	Y	Y	31.5	P25-P50
9	M	20	8	Y	Y	Y	13	P75-P90
10	F	88	12	Y	Y	Y	19	P3-P10
*Male/Female								

The main biochemical parameters in Table 2 showed that hypoalbuminemia and hypogammaglobulinemia were found in all of our patients except patient 8, whereas lymphocytopenia was only observed in 5 of 10, hypocalcemia 4 of 9. From the imagological examination, histologic and treatments in Table 3, we found that Gastrosocopy and E-colonoscopy were used in 8/10 of the patients, and only 40% (4/10) of children in this study used capsule endoscopy. All the patients had a biopsy and pathological findings. As can be seen in Table 4, 5 of 10 were received the injections of human albumin. 8 of 10 were given MCT diet, 6 of 10 were given PN. Most patients' diets started with a fat free (or low fat) diet and then switched to a MCT diet. Fortunately, the patient's clinical symptoms and nutritional status were improved after the MCT diet therapy was given.

Table 2  
Main biochemical parameters of the 10 patients with PIL (admission/ discharge)

Patient	Total Protein(g/dl)	Albumin (g/dl)	Calcium (mmol/L)	Cuprum (ug/L)	Zinc (ug/L)	IgA (g/L)	IgG (g/L)	IgM (g/L)	Lymphocytes×10 <sup>9</sup> /L
1	31.4/47.9	20.9/31.9	2.05	875	1263	0.71	5.53	1.4	1.05
2	33.6	21.4	2.17	755	418	0.4	2.05	0.38	1.01
3	35.1	23.7	1.99	462	813	0.62	2.48	1.28	2.18
4	30.3	19.7	1.66	/	/	0.38	1.54	0.41	1
5	37.7	26.1	1.93	710	505	0.97	2.98	1.17	3.65
6	28.8	20.6	1.44	/	/	0.43	3.06	0.8	0.85
7	36.1	22.6/34.6	2.14	316	532	0.24	5.59	0.22	2.18
8	46.3/56.0	29.4/34.3	/	/	/	/	/	/	0.42
9	35.4	19.4/32.6	2.18	772	644	0.32	2.11	0.88	1.23
10	58.9	39.9	2.04	952	688	0.66	5.26	0.38	2.18

Table 3  
Imageological examination of 10 patients with PIL

Patient	Gastroscopy	E-colonoscopy	Capsule Endoscopy	Histology
1	Y	Y	Y	Mucosal lymphatic dilatation in the ileocecal valve
2	Y	Y	Y	Intramucosal lymphatic cystic dilatation in the descending part of the duodenum
3	Y	N	N	Partially enlarged chyle duct in the duodenal papilla
4	Y	Y	N	Mucosal lymphatic dilatation in the ileum
5	Y	Y	Y	Lymphoid hyperplasia of the small intestine
6	N	Y	N	Lymphatic dilatation of the intestinal lamina propria
7	Y	Y	N	Intramucosal lymphatic cystic dilatation in the duodenum
8	N	N	Y	Diffuse lymphatic dilatation from the start of duodenum to ileocecal
9	Y	Y	N	Significant hyperplasia and dilation in the duodenal mucosa and terminal ileum
10	Y	Y	N	Dilation in the duodenal mucosa and terminal ileum

Table 4  
The nutritional treatments of 10 patients with PIL

Patient	EN	PN					Human Albumin
		Amino acid g/kg(%)	Fatty acid g/kg(%)	Carbohydrate g/kg(%)	Fluid ml/kg	Energy kcal/(kg.d)	
1	Fat free diet→MCT diet	0.63(13.8)	0.74(40.2)	2.11(46)	33.68	18.32	N
2	Fat free diet→MCT diet	2(19.4)	1.67(40.3)	4.17(40.3)	83.3	41.33	Y
3	Fat free diet	1.71(27)	0.86(33.7)	2.5(39.3)	60.71	25.43	N
4	Regular diet			N			N
5	Fat free diet→MCT diet			N			N
6	Low fat diet→MCT diet	1.47(16.2)	1.38(38.1)	4.14(45.7)	65.52	36.21	Y
7	Fat free diet→MCT diet	1.15(21)	1.00(45.7)	1.82(33.3)	46.82	21.85	Y
8	Rice Congee→MCT diet	0.67(19.1)	0.51(36)	1.58(44.9)	26.35	14.13	Y
9	MCT diet			N			Y
10	Low fat diet→MCT diet			N			N

Table 5  
The follow-up results of patient 1

Follow-up time	DEI kcal/d	Frequency of PN	Lymphocytes $\times 10^9/L$	TP (g/L)	Alb (g/L)	Weight (kg)	Height (cm)	Percentile (%)
hospital admission	800	one time a day	0.73	31.4	20.9	17	102.8	<P3
hospital discharge	1200	three times a week	0.84	47.9	31.9	18.1	103.5	P3-10
3 months after discharge	1600	one time a week	0.9	46.3	28.8	19	106.2	P10-25
6 months after discharge	1900	one time two weeks	1.1	45.3	27.5	21.2	108	P25-50
2 years after discharge	2200	one time a month	1.2–1.5	44 ~ 47	26 ~ 32	24.8	120	P25-50
9 years after discharge	2400	once in a while	1.1	44	28.8	55	169	P50

From the follow-up result of patient 1 in Table 5, we found that the energy intake was gradually increasing, the frequency of the use of PN was gradually decreasing, and the nutritional status was also improving. And the Fig. 1 was the diagnostic and nutrition therapies based on our 12 years of experience.

## Discussion

PIL is caused by a variety of causes of lymphatic flow obstruction, resulting in dilatation and rupture of the lymphatic ducts of the small intestine, and leakage of lymphatic fluid. Lymphatic vessels of the small intestine are distributed in the lamina propria, submucosa, and serosal layer. They return to the blood circulation through the chylomicron and the thoracic ducts. When the lymphatic flow is blocked, the lymphatic pressure rises, expands, and ruptures. As a result, the protein, fat, and lymphocytes contained in the fluid leak into the lumen of the intestine or are lost from the abdominal cavity. Clinical manifestations such as hypoproteinemia, steatorrhea, and reduction in lymphocyte count may occur with it. In addition, PIL may present with a broad spectrum of clinical manifestations, including edema, ascites, moderate diarrhea, pleural effusion, lymphedema, abdominal pain, weight loss and fat-soluble vitamin deficiencies [6].

PIL is largely responsible for lymphatic leakage into the intestinal lumen, which leads to edema, lymphopenia and hypoalbuminemia [15]. Edema and diarrhea are usually the main clinical manifestations. Edema is of pitting type, and usually bilateral and symmetrical in distribution involving the upper and lower limb, face, scrotum or vagina [6-7]. Lymphedema is a rare disorder which may be associated with intestinal lymphangiectasia [8], and is not easy to regress as the abnormality may be persistent [9-10]. And also there may be hypogammaglobulinemia with low levels of IgA, IgM and IgG, low counts of CD4 and lymphocytes [12].

To date, the pathogenesis of PIL is not yet clear. Therefore, it has brought serious difficulties for our diagnosis. Because clinical manifestations of PIL are similar to many diseases, it is often misdiagnosed as other diseases. At present, there is no uniform standard for diagnosing PIL in children. The diagnosis of small intestine lymphatic ectasia is mainly based on clinical manifestations, biochemical indicators, imaging examinations, and biopsy, of which the biopsy is considered as the gold standard of the disease.

When children have edema, diarrhea, hypoproteinemia and other clinical manifestations, and the general treatment is invalid, then PIL should be considered. In order to confirm the hypothesis, we usually use endoscopy to obtain tissue biopsy to further confirm the diagnosis. For the diagnosis of PIL in children, endoscopic methods including gastroscopy, duodenoscopy, double-balloon enteroscopy, and capsule endoscopy are commonly used. It is usually determined by the condition of the hospital and the wishes of the patient for which endoscopy method is chosen. In our previous study, we found that the diagnostic rate of gastroscopy in PIL can be as high as 86% [8]. The mucosa of the small intestine of duodenal proximal segment is often swollen and hypertrophied, with yellow or snow-like protrusions on the surface, and even intestinal stenosis through the gastroscopy. In our study, gastroscopy was used in 8/10 of the patients. When the lesion occurs in the small intestine, capsule endoscopy can be used to observe changes in the intestinal mucosa [16]. In recent years, the prevalence of PIL has increased with the development of capsule endoscopy. The clear image of the lesioned bowel surface and complete examination shown by capsule endoscopy has a good diagnostic value for PIL, which is the extent that general endoscopy cannot achieve [17-19]. Unfortunately, the disadvantage of capsule endoscopy is that it cannot obtain biopsy for pathological diagnosis. If possible, capsule endoscopes can be used in combination with double-balloon enteroscopy, which can obtain biopsy for pathological diagnosis [17,20]. Due to limited conditions, only 40% of children in this study used capsule endoscopy to observe changes in the intestinal mucosa.

At present, in addition to endoscopy, there are many other non-invasive methods, including 24 h stool alfa-1-antitrypsin clearance, 99Tc-HSA, lymphoscintigraphy, ultrasonography (USG), computed tomography (CT) scan, and magnetic resonance imaging (MRI) for diagnosing PIL. Although these inspection methods all have non-invasive advantages, they also have various disadvantages, such as high cost, complicated operation, infections risk and so on [21].

Come so far, there is still a lack of uniform and standardized treatment methods for PIL. Medical conservative treatment and surgical treatment are currently two commonly used methods. In general, the therapeutic goals are to improve the clinical symptoms of children, increase serum protein levels, promote weight gain through nutrition interventions, and ensure children's growth and development.

Once diagnosed with PIL, the MCT diet therapy (low in long chain fatty acids, high in protein and medium chain triglycerides) is usually given first<sup>[22–24]</sup>. The fat in the natural diet consists mainly of LCT, and is absorbed in the form of chylomicrons through the lymphatic circulation. In contrast, MCT can be directly absorbed into the blood through the hepatic portal vein. As MCT does not enter the lymphatic circulation, it can reduce the production of lymph, which can relieve the pressure of the lymphatic lumen of the capillaries, and ultimately prevent the leakage of the lymph to reduce the intestinal protein loss<sup>[25–26]</sup>. For patients who have not yet added complementary food, formulas which are rich in MCT should be used. In our study, formulas with medium chain fatty acids accounting for 60% of total fat were given to the patients. For older children (> 6 months), MCT oil can be used to cook food on the basis of formula being rich in MCT.

When the clinical symptoms are severe and dietary therapy is restricted, parenteral nutrition (PN), infusion of albumin and diuretics can be used in combination with MCT diet, which will achieve good results. In our study, most patients received parenteral nutrition and fat free (or low fat) diet at the beginning of treatment. After a positive symptomatic treatment, the gastrointestinal symptoms improved and the MCT diet was given. The clinical symptoms of the children were all significantly less than before. Patient 4 was given the regular diet because of no gastrointestinal manifestations.

When the child is insensitive to those treatments, other options can be considered or in conjunction with the MCT diet. These are corticosteroids, octreotide, and antiplasmin (tranexamic acid) <sup>[27–28]</sup>, which play important roles in Anti-inflammation <sup>[27, 29]</sup>, decreasing absorption of triglycerides and reduces clinical manifestations <sup>[27, 30]</sup>, and improving lymphatic permeability to proteins respectively <sup>[31–32]</sup>.

When medical treatment is not satisfactory, and serious complications, such as uncontrolled bleeding from gastrointestinal ulcers or refractory mechanical obstruction resulting from severe focal bowel wall edema occur, surgical treatment may be considered <sup>[33–34]</sup>. However, since the lymphatic dilatation of the small intestine is diffuse, surgical treatment is often not the preferred method. Surgical resection of segmental or locally expanding bowel is the recommended surgical procedure <sup>[35]</sup>. The key to success in surgery is not to cause short bowel syndrome, but also to completely remove the diseased bowel. Most of them still need to adhere to MCT dietary therapy and/or PN after surgery.

## Conclusions

IL should be considered when there are clinical manifestations of chronic diarrhea, edema, abdominal distention, hypoproteinemia and hypoimmunoglobulinia, and the general treatment is invalid. Endoscopic examination and biopsy are the preferred diagnostic methods for IL. As to which type of endoscopy is chosen, the hospital's conditions, and the severity and willingness of the patient should be taken as the reference standard. Diet intervention (MCT diet) is the cornerstone and longtime medical treatment, which can improve the nutritional status and promote the recovery process of patients with IL. Long-term follow-up and regular examination or supplementation of serum albumin cannot be ignored. Figure 1 can be referred for the diagnosis and treatment procedures. In the future, more studies and larger samples should be required to conduct more in-depth research on IL.

## Abbreviations

Primary Intestinal Lymphangiectasia (PIL)

long-chain triglycerides (LCT)

medium-chain triglycerides (MCT)

## Declarations

### 1. Ethics approval and consent to participate

This study was reviewed and approved by the Research Ethics Committee of Xinhua Hospital, School of Medicine, Shanghai Jiao Tong University.

## **2. Consent for publication**

Not applicable.

## **3. Availability of data and material**

The data and materials in this article are real and available. Please contact author for data requests.

## **4. Competing interests**

The authors declare that they have no competing interests.

## **5. Funding**

Not applicable.

## **6. Authors' contributions**

YN and QW contributed to the conception and design of the research; QT contributed to the design of the research; LL contributed to the acquisition and analysis of the data; YW and WC contributed to the interpretation of the data; and YN, QW and QT drafted the manuscript. All authors critically revised the manuscript, agree to be fully accountable for ensuring the integrity and accuracy of the work, and read and approved the final manuscript.

## **7. Acknowledgements**

We express our sincere gratitude to all the workers and participants who participated in this project.

# **References**

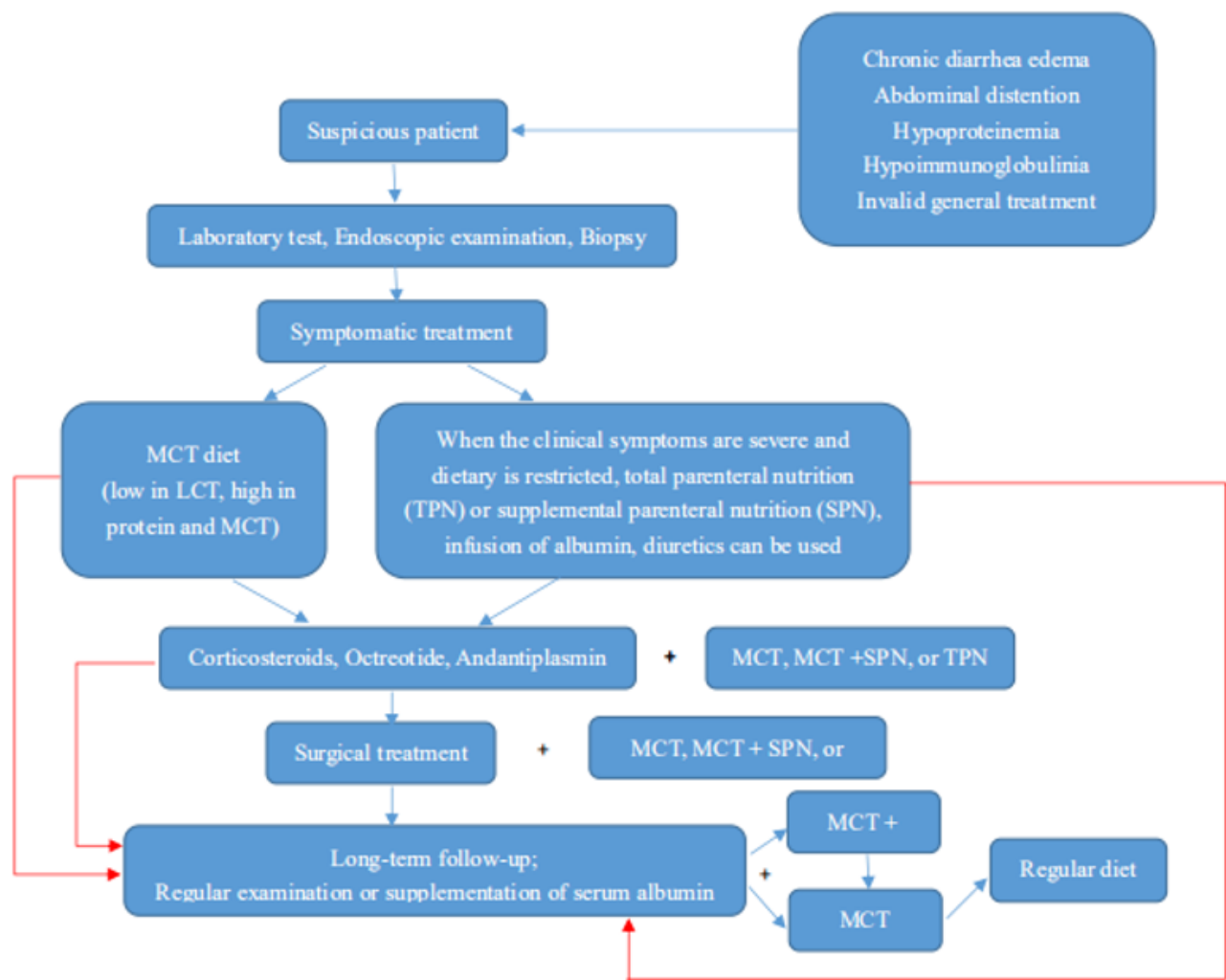
1. Waldmann T, Steinfeld J, Dutcher T, et al. The role of the gastrointestinal system in idiopathic hypoproteinemia. *Gastroenterology*. 1961;41:197–207.
2. Aniruddha Ghosh J, Choudhury. Arunaloke Bhattacharya, niruddha Ghosh. Waldmann's Disease: A Rare Form of Protein Losing Enteropathy, *JMSCR*,2016,4(12):14548–14550.
3. Vignes S, Bellanger J. Primary intestinal lymphangiectasia (Waldmann's disease). *Orphanet J Rare Dis*. 2008;3:5.
4. Lai Y, Yu T, Qiao XY, Zhao LN, Chen QK. Primary intestinal lymphangiectasia diagnosed by double-balloon enteroscopy and treated by medium-chain triglycerides: a case report. *J Med Case Rep*. 2013;7:19.
5. Freeman HJ, Nimmo M. Intestinal lymphangiectasia in adults. *World J Gastrointest Oncol*. 2011;3:19–23.
6. Sachin B, Ingle CR, Hinge (Ingle). Primary intestinal lymphangiectasia: Minireview. *World J Clin Cases* 2014 October 16; 2(10): 528–533.
7. Xuefeng Wang MD, Hong Jin MD, PhD, Wu W. MD. Primary Intestinal Lymphangiectasia Manifested as Unusual Edemas and Effusions: A Case Report. *Medicine*,2016, 95 (10) : e2849.
8. Wen J, Tang Q, Wu J, Wang Y, Cai W. Primary intestinal lymphangiectasia: four case reports and a review of the literature. *Dig Dis Sci*. 2010;55:3466–72.
9. Karg E, Bereczki C, Kovacs J, et al. Primary lymphedema associated with xanthomatosis, vaginal lymphorrhoea and intestinal lymphangiectasia. *Br J Dermatol*. 2002;146(1):134–7.
10. Persic M, Browse NL, Prpic I. Intestinal lymphangiectasia and protein losing enteropathy responding to small bowel restriction. *Arch Dis Child*. 1998;78(2):194.



11. Sanaa Hammi H, Berrani T, Benouchen, et al. A primary intestinal lymphangiectasia hiding the diagnosis of pleural and pericardial tuberculosis: a clinical observation. *Pan African Medical Journal*. 2017;26:89.
12. Jabeen S, Murthy A, Kandadai R, Meena A, Borgohain R, Uppin M. Cryptococcal meningitis as a primary manifestation in a patient with intestinal lymphangiectasia. *Ann Indian Acad Neurol*. 2012;15:218–20.
13. Surampall V, Ramaswamy S, Surendran D, et al. Primary Intestinal Lymphangiectasia (Waldmann's Disease) Presenting with Chylous Effusions in a 15-Year-Old. *Journal of Clinical Diagnostic Research*. 2017;11(8):OD17–8.
14. Suresh N, Ganesh R, Sankar J, et al. Primary intestinal lymphangiectasia. *Indian Pediatr*. 2009;46:903–6.
15. Aniruddha Ghosh J, Choudhury A, Bhattacharya. Waldmann's Disease: A Rare Form of Protein Losing Enteropathy. *Journal of Medical Science Clinical Research*. 2016;4(12):14548–50.
16. Chamouard P, Nehme-Schuster H, Simler JM, Finck G, Baumann R, Pasquali JL. Videocapsule endoscopy is useful for the diagnosis of intestinal lymphangiectasia[J]. *Digestive & Liver Disease Official Journal of the Italian Society of Gastroenterology & the Italian Association for the Study of the Liver*. 2006;38(9):699–703.
17. Oh TG, Chung JW, Kim HM, et al. Primary intestinal lymphangiectasia diagnosed by capsule endoscopy and double balloon enteroscopy. *World J Gastrointest Endosc* 2011 November 16; 3(11): 235–240.
18. Gay G, Delvaux M, Frederic M. Capsule endoscopy in nonsteroidal anti-inflammatory drugs-enteropathy and miscellaneous, rare intestinal diseases. *World J Gastroenterol*. 2008;14:5237–44.
19. Chamouard P, Nehme-Schuster H, Simler JM, Finck G, Baumann R, Pasquali JL. Videocapsule endoscopy is useful for the diagnosis of intestinal lymphangiectasia. *Dig Liver Dis*. 2006;38:699–703.
20. Lee SJ, Song HJ, Boo SJ, Na SY, Kim HU, Hyun CL. Primary intestinal lymphangiectasia with generalized warts[J]. *World journal of gastroenterology*. 2015;21(27):8467–72.
21. Sachin B, Ingle CR, Hinge (Ingle). Primary intestinal lymphangiectasia: Minireview. *World J Clin Cases* 2014 October 16; 2(10): 528–533.
22. Aroor S, Mundkur S, S Kanaparthi, S Kumar. Waldmann's Disease (Primary Intestinal Lymphangiectasia) with Atrial Septal Defect. *Journal of Clinical & Diagnostic Research Jcdr*, 2017, 11 (4) :SD03.
23. Marjet JB, Koert MD, Merit MT. Protein-losing enteropathy in children. *Eur J Pediatr*. 2010;169:1179–85.
24. Li S, Liu X, He Y, et al. Waldmann's Disease (Primary Intestinal Lymphangiectasia) with Atrial Septal Defect. *Medicine*, 2017, 96:51(e9240).
25. Biselli M, Andreone P, Gramenzi A, et al. Acquired intestinal lymphangiectasia successfully treated with a low-fat and medium-chain triacylglycerol-enriched diet in a patient with liver transplantation. *Eur J Gastroenterol Hepatol*. 2006;18:561–4.
26. Munoz Conde J, Gomez de Terreros I, Sanchez Ruiz F, et al. Idiopathic intestinal lymphangiectasis. Evolution with M.C.T[author's transl]. *An Esp Pediatr*. 1976;9:438–46.
27. Troskot R, Jurčić D, Bilic A, et al. How to treat an extensive form of primary intestinal lymphangiectasia? *World J Gastroenterol*. 2015;21:7320–5.
28. Vignes S, Bellanger J. Primary intestinal lymphangiectasia (Waldmann's disease). *Orphanet J Rare Dis*. 2008;3:5.
29. Fleisher TA, Strober W, Muchmore AV, et al. Corticosteroid-responsive intestinal lymphangiectasia secondary to an inflammatory process. *N Engl J Med*. 1979;300:605–6.
30. Suehiro K, Morikage N, Murakami M, et al. Late-onset primary intestinal lymphangiectasia successfully managed with octreotide: a case report. *Ann Vasc Dis*. 2012;5:96–9.
31. Mine K, Matsubayashi S, Nakai Y, et al. Intestinal lymphangiectasia markedly improved with antiplasmin therapy. *Gastroenterology*. 1989;96:1596–9.
32. MacLean JE, Cohen E, Weinstein M. Primary intestinal and thoracic lymphangiectasia: a response to antiplasmin therapy. *Pediatrics*. 2002;109:1177–80.
33. Zhu LH, Cai XJ, Mou YP, et al. Partial enterectomy: treatment for primary intestinal lymphangiectasia in four cases. *Chin Med J*. 2010;123:760–4.

34. Kneist W, Drescher DG, Hansen T, Kreitner KF, Lang H.[Surgical therapy of segmental jejunal, primary intestinal lymphangiectasia][J]. Zeitschrift Für Gastroenterologie.2013,51(6):576–9.
35. Ingle SB, Hinge CR.Primary intestinal lymphangiectasia: Minireview[J].World Journal of Clinical Cases.2014,2(10):528–33.

# Figures



**Figure 1**

The flow diagram demonstrating the recommended diagnostic and nutrition therapies based on our 12 years of experience