

Effects of cranioplasty in cerebral blood perfusion using quantification with ^{99m}Tc-HMPAO SPECT-CT

Álvaro Galiana (✉ agalianam@gmail.com)

Hospital Universitario 12 de Octubre <https://orcid.org/0000-0002-0763-9857>

Igor Paredes

Hospital Universitario 12 de Octubre

Sebastián Ruiz

Hospital Universitario 12 de Octubre

José Antonio Fernández Alén

Hospital Universitario 12 de Octubre

Adolfo Gómez Grande

Hospital Universitario 12 de Octubre

Irene Panero

Hospital Universitario 12 de Octubre

Diana Vega

Hospital Universitario 12 de Octubre

Daniel García

Hospital Universitario 12 de Octubre

Elena Gutiérrez

Hospital Universitario 12 de Octubre

Carmen Romero

Hospital Universitario 12 de Octubre

Alfonso Lagares

Hospital Universitario 12 de Octubre

María José Tabuena

Hospital Universitario 12 de Octubre

Research Article

Keywords: Cerebral Blood Perfusion, Craniectomy, Cranioplasty, Syndrome of the trephined, HMPAO, SPECT-CT

Posted Date: May 27th, 2021

DOI: <https://doi.org/10.21203/rs.3.rs-539070/v1>

Abstract

PURPOSE: SSFS is an underdiagnosed complication of craniectomized patients, which mainly presents with headache, motor weakness, and cognitive impairments. In these patients, cranioplasty improves these symptoms. Furthermore, patients without a classical SSFS have been shown to improve their neurological functions after reconstructive surgery. Amongst the many different pathophysiological theories proposed, the changes of CBP caused by the cranial defect might have a role in the neurological deficiencies. We have studied CBP in twelve cortical areas of both hemispheres, using 99mTc-HMPAO SPECT-CT before and after cranioplasty.

METHODS: Twenty-eight craniectomized patients subject to reconstructive surgery were studied with 99mTc- HMPAO in three different times, before cranioplasty, a week after, and three months later. The images were processed with quantification software comparing CBP of 24 cortical areas with a reference area , and with a database of normal individuals. A mixed effects model was used to determine the signification of CBP changes in the cortex regions of both the damaged and undamaged brain hemispheres.

RESULTS: CBP increased significantly in both hemispheres after cranioplasty both in ratio ($\beta=0.019$ p-value=0,030 first post-surgical SPECT-CT and $\beta=0.021$ p-value=0,015 in the second study, vs. pre-surgical) and Z-score ($\beta=0.220$ p-value=0,026 and $\beta=0.279$ p-value=0,005 respectively). Nine of twelve areas of the damaged side had a significant lower CBP ratio and Z-score than the undamaged. Posterior cingulate showed an increased CBP ratio (p-value=0,034) and Z-score(p-value0,028) in the first post-surgical SPECT-CT.

CONCLUSION: CBP changes significantly in specific cortical areas after cranioplasty, which might explain the clinical improvements observed. Posterior cingulate changes might explain some improvements in attention impairments described. 99mTc-HMPAO SPECT-CT might be a valid tool to assess CBP changes in these patients and could have a role in the management of craniectomized individuals.

CLINICAL TRIAL REGISTRATION

Not applicable

Introduction

Sinking skin flap syndrome (SSFS) or syndrome of the trephined (SoT) is a difficult-to-diagnose complication of decompressive craniectomy performed for any cause. SSFS has variable clinical presentation with signs and symptoms, such as sunken skin flap in the site of the craniectomy, headache, motor weakness, and language deficits, which can begin in the days or months following craniectomy, in some cases after full or partial recovery [1]. One of the most important characteristics of this syndrome is neurological improvement of many of these patients after the cranial defect is reconstructed with cranioplasty. Although the previously mentioned signs and symptoms constitute the classical definition

of the syndrome, studies published in recent years have shown improvement in clinical and physiological parameters after cranioplasty, even in patients without symptoms of SSFS [2]. Such findings have changed the management of craniectomized patients and the use of cranioplasty has been implemented not only for aesthetic or protective reasons but also to improve patient functionality and prognosis.

The pathophysiology of SSFS is unknown, although different hypotheses have been published, most of them considering the main variable that seems to affect these patients, which is the influence of atmospheric pressure in the encephalus. Whether it directly harms the brain parenchyma, changes brain metabolism, alters brain blood perfusion, or affects cerebrospinal fluid (CSF) flow (or a combination of the aforementioned factors), the mechanisms underlying SSFS have not been elucidated to date [2, 3].

Several imaging techniques have been used to examine cerebral blood perfusion (CBP) changes in these patients using different protocols, although most of them use computed tomography (CT) or perfusion magnetic resonance imaging to assess these changes [4]. In recent years, positron emission tomography (PET) has evolved to become the gold standard method for analysing brain-blood haemodynamics, although measuring glucose metabolism is not exactly the same as measuring CBP. Moreover, quantification of those changes has typically been limited to brain hemispheres or lobes at most with no evaluation of different cortical regions.

In our study, we aimed to analyse changes in CBP) in craniectomized patients before and after cranioplasty using Technetium-99 m HMPAO and SPECT-CT to assess changes in CBP in different cortical areas. This radiotracer is a specific tool to measure CBP, not only cerebral blood flow or metabolism, as in previous imaging studies.

Material And Methods

A total of 28 patients were selected for this study, all of whom had a craniectomy performed to control refractory high intracranial pressure and were due to cranioplasty between October 2016 and November 2019. Patients were scheduled to receive cranioplasty regardless of whether they had classical symptoms of SSFS as a procedure to improve their clinical situation. We recorded the demographic data of each patient, pathology leading to the craniectomy, date of cranioplasty and any brain hemisphere damage.

Surgeries were scheduled a variable period of time after DC, depending on the primary cause for decompression, reduction of brain swelling, and patient and surgeon preferences. As a general rule, procedures were performed after some patient rehabilitation. Autologous bone flaps were the first choice to reconstruct the cranial defects, and when not available, computer-designed polyetheretherketone (PEEK) or methacrylate implants were used.

To evaluate CBP, we used a hybrid imaging technique, single photon emission tomography with computed tomography (SPECT-CT), for morphological imaging, as well as for attenuation correction. We employed Technetium-99 m hexamethylpropyleneamineoxime (Tc-99 m HMPAO) as a

radiopharmaceutical because it diffuses into neurons based on blood perfusion of the area. Ten to 20 minutes after injection, the radiopharmaceutical fixes to the neuron, and there is no intracerebral redistribution, resulting in a fixed representation of CBP. Each patient was scheduled for three separate studies performed at different time points, including before cranioplasty, one week after the surgery and finally three months after surgery. Imaging studies were performed following the recommendations of the European Society of Nuclear Medicine guidelines. Patients were injected with a 925 MBq dose of Technetium-99 m HMPAO at rest and in decubitus in a quiet room 30 to 60 minutes before the scan was conducted. Images were acquired in a dual head gamma camera and CT scan (model NM/CT 640, General Electric Healthcare, USA). Images were obtained in a 128 x 128 matrix using high-resolution collimators. Processing was performed in Xeleris 4.0 Functional Imaging Workstation (General Electric Healthcare, USA) using filtered back projection reconstruction and Butterworth filtering (critical frequency 0.51, order 10).

Quantification was performed using QBrain software (General Electric Healthcare, U.S.A.), which was added to the Xeleris 4.0 Workstation. A ratio was calculated, comparing 12 different cortical regions to one reference area, the pons. This reference area was selected due to its location far from the cortical defects observed in these patients which, in turn, is important to guarantee an adequate quantification of blood perfusion in the different studies. CBP in each cortical region was compared to a database of normal individuals included in the QBrain software. A Z-score was obtained for each brain region that indicated the differences between the patient and normal CBP in each region (Fig. 1).

Statistical analyses were performed using SAS software (version 9.4, SAS Institute Inc., 2012). Descriptive data are presented as the mean \pm standard deviation for continuous variables, and categorical variables are expressed as absolute or relative frequencies. Analysis of CBP in each of the cortical areas was performed using a mixed effects model. For assessment of CBF changes in the different cortical regions, each patient was considered a random effect, while the brain hemisphere (damaged or undamaged) where the region studied was located and the moment in which the SPECT-CT was performed (presurgical, postsurgical one week and three months) were considered fixed effects. The interaction between the moment and the brain hemisphere was evaluated.

Results

A total of 28 patients were included in this study (Table 1): 17 male (60,71%) and 11 female (39,29%). The age of the patients ranged from 16 to 81 years with a mean age of $39,81 \pm 15,93$ years. Sixteen patients (57,14%) suffered head trauma as the primary brain injury leading to craniectomy, 5 (17,86%) had a stroke, 5 (17,86%) had intraparenchymal haemorrhage, 1 had subarachnoid haemorrhage (3,57%) and 1 had encephalitis (3,57%). All patients had a unilateral cranial defect, 16 (57,14%) on the right side of the skull and 12 (42,86%) on the left side. The average interval between craniectomy and cranioplasty was 43,66 weeks ($\pm 30,73$).

Table 1
Characteristics of the participants

Variable	
Age	39,89 ± 15,93
Sex (male)	17(60,71%)
Cause of the craniectomy	5(17,86%)
Intraparenchymal Hemorrhage	5(17,86%)
Malignant Stroke	16(57,14%)
Trauma	1(3,57%)
Encefalitis	1(3,57%)
Subarachnoid Hemorrhage	
Damaged Side	12(42,86%)
Left	16(57,14%)
Right	
Interval between surgeries in weeks	43,66 ± 30,73
Ventriculoperitoneal shunt	3 (10,71%)
Complications	3(10,71%)
Infections (total)	2(7,14%)
Infection of the site of craniectomy	1(3,57%)
Post-cranioplasty infection	

Results are shown for both the ratio and Z-score for each hemisphere as a whole, as well as for the 12 regions in each hemisphere. We referred to the damaged side as the hemisphere where the cranioplasty was performed, and we referred to the undamaged side as the other hemisphere. Regarding both hemispheres as a whole, our results showed a statistically significant increase in cerebral blood perfusion in both hemispheres after cranioplasty, both in ratio ($\beta = 0.019$ p-value = 0,030 in the SPECT-CT a week after surgery and $\beta = 0.021$ p-value = 0,015 in the one performed three months after, vs. presurgical) and Z-score ($\beta = 0.220$ p-value = 0,026 and $\beta = 0.279$ p-value = 0,005, respectively). The damaged hemisphere exhibited a decreased blood perfusion ratio compared to the undamaged side before and after the reconstruction surgery ($\beta = -0.073$ p-value < 0,0001) (Fig. 2).

In the analysis for each of the twelve areas, nine of the damaged hemispheres (prefrontal lateral and medial, sensorimotor, occipital lateral, primary visual, precuneus, and both temporal lateral and mesial)

presented a significantly lower ratio (Table 2 and Fig. 3) and Z-score (Table 3 and Fig. 3) for CBP compared to the undamaged side.

Table 2

Results of mixed models. Significant cerebral blood perfusion ratios variations by areas, compared with the Pons (reference area).

Brain Area		Beta	Std. Error	P-Value
Prefrontal lateral	Intercept	1.015	0.024	0.0000
	*SECOND SPECT-CT	0.027	0.011	0.0201
	THIRD SPECT-CT	0.019	0.016	0.2401
	DAMAGED SIDE vs. UNDAMAGED SIDE	-0.081	0.028	0.0049
Prefrontal medial	Intercept	1.014	0.022	0.0000
	SECOND SPECT-CT	0.020	0.011	0.0824
	THIRD SPECT-CT	0.020	0.016	0.2138
	DAMAGED SIDE	-0.034	0.009	0.0003
Sensorimotor	Intercept	1.074	0.029	0.0000
	SECOND SPECT-CT	0.021	0.015	0.1528
	THIRD SPECT-CT	0.029	0.017	0.0897
	DAMAGED SIDE vs. UNDAMAGED SIDE	-0.093	0.035	0.0084
Occipital lateral	Intercept	1.117	0.025	0.0000
	SECOND SPECT-CT	0.029	0.014	0.0535
	THIRD SPECT-CT	0.018	0.020	0.3592
	DAMAGED SIDE vs. UNDAMAGED SIDE	-0.059	0.027	0.0329
Primary visual	Intercept	1.284	0.029	0.0000
	SECOND SPECT-CT	-0.005	0.014	0.7183
	THIRD SPECT-CT			
* First SPECT-CT as reference for second and third SPECT-CT				
** The results of the interactions between the moment and the brain hemisphere are only included in the areas of the brain where they were significant.				

Brain Area		Beta	Std. Error	P-Value
Parietal inferior		0.021	0.023	0.3671
	DAMAGED SIDE vs. UNDAMAGED SIDE	-0.069	0.021	0.0023
	Intercept	1.104	0.039	0.0000
	SECOND SPECT-CT	0.009	0.016	0.5686
	THIRD SPECT-CT	-0.003	0.018	0.8486
Parietal superior	DAMAGED SIDE vs. UNDAMAGED SIDE	-0.094	0.065	0.1504
	Intercept	1.082	0.025	0.0000
	SECOND SPECT-CT	0.019	0.015	0.2070
	THIRD SPECT-CT	0.028	0.016	0.0918
	DAMAGED SIDE vs. UNDAMAGED SIDE	-0.090	0.029	0.0025
Anterior cingulate	Intercept	1.030	0.023	0.0000
	SECOND SPECT-CT	0.035	0.016	0.0319
	THIRD SPECT-CT	0.024	0.018	0.1901
	DAMAGED SIDE vs. UNDAMAGED SIDE	0.002	0.010	0.8061
Posterior cingulate	Intercept	1.215	0.023	0.0000
	SECOND SPECT-CT	0.016	0.023	0.4935
	THIRD SPECT-CT	0.050	0.031	0.1111
	DAMAGED SIDE vs. UNDAMAGED SIDE	-0.016	0.017	0.3550
	SECOND SPECT-CT: DAMAGED SIDE**	0.042	0.019	0.0341
	THIRD SPECT-CT: DAMAGED SIDE**	0.017	0.017	0.3515
Precuneus				
* First SPECT-CT as reference for second and third SPECT-CT				
** The results of the interactions between the moment and the brain hemisphere are only included in the areas of the brain where they were significant.				

Brain Area		Beta	Std. Error	P-Value
	Intercept	1.271	0.022	0.0000
	SECOND SPECT-CT	0.018	0.017	0.2800
	THIRD SPECT-CT	0.052	0.024	0.0310
	DAMAGED SIDE vs. UNDAMAGED SIDE	-0.063	0.016	0.0002
Temporal lateral				
	Intercept	1.038	0.026	0.0000
	SECOND SPECT-CT	0.017	0.013	0.1929
	THIRD SPECT-CT	0.018	0.018	0.3191
	DAMAGED SIDE vs. UNDAMAGED SIDE	-0.101	0.031	0.0015
Temporal mesial				
	Intercept	1.034	0.028	0.0000
	SECOND SPECT-CT	0.024	0.024	0.3512
	THIRD SPECT-CT	0.000	0.029	0.9958
	DAMAGED SIDE vs. UNDAMAGED SIDE	-0.093	0.032	0.0043
* First SPECT-CT as reference for second and third SPECT-CT				
** The results of the interactions between the moment and the brain hemisphere are only included in the areas of the brain where they were significant.				

Table 3

Results of mixed models. Significant cerebral blood perfusion variations by areas, comparing patients and normal population (Z-Score).

Brain Area		Beta	Std. Error	P-Value
Prefrontal lateral	Intercept	-1.065	0.325	0.0013
	*SECOND SPECT-CT	0.303	0.161	0.0618
	THIRD SPECT-CT	0.265	0.222	0.2331
	DAMAGED SIDE vs. UNDAMAGED SIDE	-1.118	0.361	0.0023
Prefrontal medial	Intercept	-0.832	0.228	0.0004
	SECOND SPECT-CT	0.293	0.152	0.0557
	THIRD SPECT-CT	0.246	0.218	0.2613
	DAMAGED SIDE vs. UNDAMAGED SIDE	-0.450	0.113	0.0001
Sensorimotor	Intercept	-0.832	0.228	0.0004
	SECOND SPECT-CT	0.293	0.152	0.0557
	THIRD SPECT-CT	0.246	0.218	0.2613
	DAMAGED SIDE vs. UNDAMAGED SIDE	-0.450	0.113	0.0001
Occipital lateral	Intercept	0.945	0.370	0.0116
	SECOND SPECT-CT	0.340	0.197	0.0857
	THIRD SPECT-CT	0.660	0.360	0.0684
	DAMAGED SIDE vs. UNDAMAGED SIDE	-0.832	0.394	0.0363
	SECOND SPECT-CT:DAMAGED SIDE**	-0.460	0.269	0.0897
	THIRD SPECT-CT:DAMAGED SIDE**	-0.687	0.334	0.0413
Primary visual				
* First SPECT-CT as reference for second and third SPECT-CT				
** The results of the interactions between the moment and the brain hemisphere are only included in the areas of the brain where they were significant.				

Brain Area		Beta	Std. Error	P-Value
	Intercept	1.390	0.323	0.0000
	SECOND SPECT-CT	0.048	0.154	0.7519
	THIRD SPECT-CT	0.294	0.253	0.2472
	DAMAGED SIDE vs. UNDAMAGED SIDE	-0.760	0.252	0.0030
Parietal inferior				
	Intercept	1.104	0.039	0.0000
	SECOND SPECT-CT	0.009	0.016	0.5686
	THIRD SPECT-CT	-0.003	0.018	0.8486
	DAMAGED SIDE vs. UNDAMAGED SIDE	-0.094	0.065	0.1504
Parietal superior				
	Intercept	0.788	0.349	0.0254
	SECOND SPECT-CT	0.093	0.246	0.7047
	THIRD SPECT-CT	0.292	0.247	0.2397
	DAMAGED SIDE vs. UNDAMAGED SIDE	-1.107	0.347	0.0017
Anterior cingulate				
	Intercept	-0.452	0.245	0.0670
	SECOND SPECT-CT	0.378	0.173	0.0310
	THIRD SPECT-CT	0.241	0.204	0.2394
	DAMAGED SIDE vs. UNDAMAGED SIDE	0.028	0.119	0.8101
Posterior cingulate				
	Intercept	0.780	0.226	0.0007
	SECOND SPECT-CT	0.131	0.220	0.5524
	THIRD SPECT-CT	0.460	0.291	0.1167
	DAMAGED SIDE vs. UNDAMAGED SIDE	-0.176	0.164	0.2852
	SECOND SPECT-CT: DAMAGED SIDE**	0.416	0.188	0.0280
	THIRD SPECT-CT: DAMAGED SIDE**			
* First SPECT-CT as reference for second and third SPECT-CT				
** The results of the interactions between the moment and the brain hemisphere are only included in the areas of the brain where they were significant.				

Brain Area		Beta	Std. Error	P-Value
		0.189	0.169	0.2644
Precuneus				
	Intercept	1.511	0.265	0.0000
	SECOND SPECT-CT	0.429	0.168	0.0117
	THIRD SPECT-CT	0.821	0.272	0.0030
	DAMAGED SIDE vs. UNDAMAGED SIDE	-0.758	0.192	0.0001
Temporal lateral				
	Intercept	-0.418	0.326	0.2019
	SECOND SPECT-CT	0.179	0.172	0.2995
	THIRD SPECT-CT	0.255	0.224	0.2571
	DAMAGED SIDE vs. UNDAMAGED SIDE	-1.221	0.391	0.0021
Temporal mesial				
	Intercept	0.532	0.277	0.0573
	SECOND SPECT-CT	0.468	0.235	0.0479
	THIRD SPECT-CT	0.110	0.286	0.6991
	DAMAGED SIDE vs. UNDAMAGED SIDE	-1.228	0.327	0.0002
* Fist SPECT-CT as reference for second and third SPECT-CT				
** The results of the interactions between the moment and the brain hemisphere are only included in the areas of the brain where they were significant.				

Regarding measurement of CBF ratios, prefrontal lateral and anterior cingulate in both hemispheres exhibited an increase in CBP of 0,027 and 0.035 units of ratio, respectively, in the second SPECT-CT compared to the presurgical study in the second SPECT-CT (p-values 0,020 and 0,031). The precuneus only presented increased perfusion by 0,052 units in the imaging study performed three months after cranioplasty (p-value 0,031). The posterior cingulate of the damaged hemisphere increased by 0,042 units (interaction p-value 0,034) in the second SPECT-CT.

In the assessment of Z-score in the 12 brain regions studied, the precuneus showed a significant increase in both hemispheres of 0,429 and 0,821 in the second and third SPECT-CT, respectively vs. presurgical measurements (p-values 0,011 and 0,003, respectively). The occipital lateral decreased by 0.687 units in only the damaged hemisphere in the third SPECT-CT (interaction p-value = 0,041), while the posterior cingulate increased by 0.416 units in only the damaged hemisphere in the second SPECT-CT (interaction

p-value = 0,028). Notably, the posterior cingulate was the only area where the interaction of the damaged side and the second SPECT-CT had significant results for both the ratio and Z-score.

Discussion

The Grant and Norcross article from 1939 is usually cited as the first known reference of the “Syndrome of the Trephined”, describing a deterioration of craniectomized patients suffering from a combination of headache, dizziness, undue fatigability, vague discomfort at the site of the cranial defect, a feeling of apprehension and insecurity, mental depression and intolerance to vibration [5]. In this study, the authors stated the difficulties in detecting and identifying SoT for those symptoms, where it is not always possible to differentiate them from a possible deterioration of the primary brain injury. Notably, this paper references previous works from the late 19th and early 20th centuries, which suggests the possibility that the first definition of this syndrome was made decades earlier. The citation of Tremier’s work *“Indication et suites éloignées de la cranioplastie”* from the French Congress of Surgery from 1928 is especially significant, where he describes an improvement in the majority of the 63 patients followed after cranioplasty [5].

Another classic paper that is frequently cited is the work of Yamaura and colleagues from Chiba University of Japan in 1977. In this work, 33 craniectomized patients were classified according to the exterior appearance of the cranial defect (sinking, flat, full or bulging) and the severity of their neurological deterioration [6]. Nine patients presented neurological improvement after cranioplasty, especially in the group classified as having moderate neurological deficits. This study was also one of the first to assess cranial fluid dynamics, which in this case examined the CSF opening pressure using a lumbar puncture before and after cranioplasty. In the patients studied, the opening pressure measured prior to surgery was low ($< 80 \text{ mmH}_2\text{O}$) in sinking and flat skin patients, and more significantly, in all patients who had an improved neurological condition, CSF pressure increased to normal while remaining low in cases with no clinical improvement. This work concluded that atmospheric pressure and subsequent damage to the brain parenchyma are the most plausible causes of the “syndrome of the sinking flap” rather than the “syndrome of the trephine” referred to in earlier works.

In 2016, Ashayeri published an extensive review of 58 patients with SoT in which different imaging techniques were employed to evaluate CSF flow and CBF using MRI and CT [7]. In the cases presented, there was an increase in CBF after cranioplasty, although no clear conclusions about the possible utility of such techniques in diagnosing or evaluating the prognosis were established. Moreover, this paper clearly explains and recompiles the four primary pathophysiological theories that have been postulated to date: the effect of atmospheric pressure in the brain parenchyma and local blood and CSF flow; changes in CBF both at the site of the defect and in distant regions; CSF dynamics and pressure; and altered cerebral metabolism.

To the best of our knowledge, in 2017, Halani and colleagues published the most extensive review to date of CBP changes before and after cranioplasty using CT (dynamic CT, Xenon CT), transcranial Doppler

(TCD), perfusion magnetic resonance imaging, SPECT and positron emission tomography [4]. Two hundred and three patients were included and examined before and after cranioplasty, showing increased CBP after cranioplasty in the damaged hemisphere, and 9 out of the 21 studies included also reported increased CBP or glucose metabolism activity (PET) on the side not affected by cranioplasty. This review included a work by Erdogan et al. [8] that assessed cerebral blood flow changes in three major cerebral arteries and compared the data to 24 control individuals [4]. The results showed a bilateral increase in blood velocity through the arteries after cranioplasty, reaching speeds comparable to those of control subjects.

Stiver et al. [9] performed perfusion CT scans on patients with precranioplasty monoparesia, which showed hypoperfusion in the area adjacent to the cranial defect that was resolved after cranioplasty. In 2006, Sakamoto et al. [10] described a patient with symptoms compatible with SoT who was evaluated before and after cranioplasty with a CT perfusion scan, which showed an increase in CBF after the procedure. Sarubbo et al. [11] studied changes in CBF before and after cranioplasty (7 days and 3 months, respectively), showing an increase in CBF, although less important at the 3-month study, suggesting that the changes observed begin soon after cranioplasty and may even be temporary. In our centre, Paredes et al. [2] assessed CBF in 49 patients, demonstrating an increase in CBF from 101.86 to 117.17 mL/min/100 g/min and from 128.14 to 145.73 mL/100 g/min on the damaged and undamaged sides, respectively. CBF improvement was observed in all craniectomized patients, regardless of whether they presented with SoT symptoms. In the same study, no statistically significant clinical relationship was observed between those results and clinical improvement, although a greater increase in CBF was identified in patients with a better clinical outcome.

Shahid and colleagues studied CBP in brain lobes and basal ganglia one week before and 3 months after cranioplasty. CBP assessment was obtained with SPECT-CT using technetium-99 m ethyl cysteinate dimer (99 mTc-ECD) [12], whose pharmacokinetics differ slightly from 99 mTc-HMPAO. They found that CBP increased after cranioplasty in the frontal and occipital lobes and decreased in the other lobes, although statistically significant changes were only found in occipital and basal ganglia regions. The decrease in blood flow in the parietal, temporal and basal ganglia was attributed to redistribution of the CBP after cranioplasty. Matsumura presented a case in 1996 of a young child with a cranial defect in the right parietofrontal region [13]. The young patient was studied before and after reconstructive surgery using 99 mTc-HMPAO, which showed a decrease in CBF in the damaged area that subsequently normalized.

To the best of our knowledge, we present the first series of patients whose CBP was evaluated using 99 mTc HMPAO SPECT-CT. Moreover, we did not find other studies analysing blood perfusion changes at the regional level or comparing those variations to a normal population, as we have done using the normal brain database in our quantification software.

First, we have to consider that we are not measuring absolute variations in blood flow but rather changes in the ratios between the different brain regions using the pons as a reference, which is located in a

relatively “safe area” away from typically damaged regions of the brain in these patients. Quantification using ratios has one major advantage: general blood perfusion alterations in the whole brain also alter the reference area used to compare the cortex; as such, we consider those values to be more accurate than absolute values. Another aspect of the study worth considering is that the damaged side of the brain is prone to possible quantification errors by the software due to the anatomical damage that these patients suffer, which is especially significant in parietal and frontal lobes, where parenchymal damage is more frequent. Finally, we should note that we are evaluating cerebral blood perfusion in decubitus, since the patients are injected and left at rest in the same position for at least 30 minutes, leaving enough time for the radiopharmaceutical to enter the neurons and stay inside the cells throughout the procedure.

We identified an increase in CBP on both sides of the brain after cranioplasty, and the ratios increased bilaterally in 8 of 12 regions examined in the second study and in 3 regions in the third SPECT-CT, which was more significant in the evaluation performed 3 months after surgery (Table 4). This difference was observed both in the ratios of CBP and Z-score (Table 5), which is consistent with published evidence using other imaging techniques, which adds more evidence indicating that CBP increases in both hemispheres after cranioplasty [2–4, 8–14], and that CBP changes seem to play a key role in the pathophysiology of SoT.

Table 4
Average ratios by cerebral cortex area.

	SPECT-CT	Damaged	Undamaged
Prefrontal Lateral			
	1	0.970	1.045
	2	0.995	1.055
	3	1.010	1.045
Prefrontal medial			
	1	1.005	1.017
	2	1.030	1.061
	3	1.017	1.067
Sensorimotor			
	1	0.988	1.067
	2	0.994	1.107
	3	1.011	1.100
Occipital lateral			
	1	1.063	1.122
	2	1.062	1.162
	3	1.061	1.169
Primary visual			
	1	1.196	1.272
	2	1.196	1.283
	3	1.217	1.321
Parietal inferior			
	1	1.003	1.115
	2	1.007	1.132

SPECT-CT: Column with all SPECT-CT studies, before cranioplasty (1), a week after the surgery (2) and three months after (3)

Colors represent the tendency in regard to the previous study, increase (green), stability (orange) or decrease (red).

	SPECT-CT	Damaged	Undamaged
	3	1.011	1.088
Parietal superior			
	1	0.986	1.085
	2	1.028	1.075
	3	0.998	1.109
Anterior cingulate			
	1	1.040	1.049
	2	1.081	1.070
	3	1.054	1.065
Posterior cingulate			
	1	1.199	1.215
	2	1.257	1.231
	3	1.266	1.265
Precuneus			
	1	1.199	1.278
	2	1.228	1.281
	3	1.238	1.318
Temporal lateral			
	1	0.940	1.055
	2	0.932	1.077
	3	0.929	1.078
Temporal mesial			
	1	0.937	1.038
	2	0.963	1.043
	3	0.935	1.043
SPECT-CT: Column with all SPECT-CT studies, before cranioplasty (1), a week after the surgery (2) and three months after (3)			
Colors represent the tendency in regard to the previous study, increase (green), stability (orange) or decrease (red).			

Table 5
Average Z-Scores by cerebral cortex area.

	SPECT-CT	Damaged	Undamaged
Prefrontal Lateral			
	1	-1.695	-0.665
	2	-1.475	-0.5
	3	-1.220	-0.72
Prefrontal medial			
	1	-1.092	-0.492
	2	-0.747	-0.352
	3	-0.92	-0.296
Sensorimotor			
	1	-1.377	-0.264
	2	-1.331	0.310
	3	-1.070	0.213
Occipital lateral			
	1	0.112	0.945
	2	-0.006	1.286
	3	0.086	1.606
Primary visual			
	1	0.424	1.268
	2	0.508	1.396
	3	0.703	1.746
Parietal inferior			
	1	-1.291	0.137
	2	-1.247	0.381

SPECT-CT: Column with all SPECT-CT studies, before cranioplasty (1), a week after the surgery (2) and three months after (3)

Colors represent the tendency in regard to the previous study, increase (green), stability (orange) or decrease (red).

	SPECT-CT	Damaged	Undamaged
	3	-1.048	0.383
Parietal superior			
	1	-0.451	1.057
	2	-0.186	0.975
	3	-0.331	1.327
Anterior cingulate			
	1	-0.346	-0.316
	2	0.049	-0.050
	3	-0.21	-0.129
Posterior cingulate			
	1	0.603	0.780
	2	1.152	0.911
	3	1.253	1.240
Precuneus			
	1	0.713	1.696
	2	1.154	1.723
	3	1.200	2.163
Temporal lateral			
	1	-1.569	-0.11
	2	-1.688	0.122
	3	-1.726	0.210
Temporal mesial			
	1	-0.641	0.642
	2	-0.302	1.207
	3	-0.705	0.987
SPECT-CT: Column with all SPECT-CT studies, before cranioplasty (1), a week after the surgery (2) and three months after (3)			
Colors represent the tendency in regard to the previous study, increase (green), stability (orange) or decrease (red).			

Regarding specific regions, the general pattern evidenced an increase in CBP after surgery, especially in the second study, while the tendencies in the third study were more variable. For example, temporal regions exhibited a decrease in cerebral blood perfusion, even lower than in the presurgical examination which, according to Shahid, might indicate redistribution of CBP from the temporal lobes to other areas of the brain that are typically damaged. In our case, we did not observe the same results in the parietal lobes [10].

The cingulate cortex demonstrated a particular pattern on the damaged side, since both anterior and posterior regions of this cortical area are the only regions where the blood perfusion ratio in the week after cranioplasty reaches higher ratios than the undamaged side of the brain both in ratios and Z-scores. The posterior cingulate of the damaged side is the only area of the brain that exhibited a statistically significant increase in blood perfusion ratio in the second study, both in ratios and Z-score assessment. To our knowledge, this is the first time that significant changes in CBF have been identified in a specific region of the brain in this patient population.

In a review article by Leech and Sharp [15] in 2014, the authors describe theories that might explain the functionality of the posterior cingulate, as well as its implications in different diseases [13]. In functional studies, the posterior cingulate exhibits an increased metabolism of approximately 40% greater than the surrounding parenchyma in the basal state, and its metabolic activity seems to fluctuate significantly less than other areas in different cognitive states. The functions of this area are mostly related to attention and spatial memory, being an important node in the default mode network that activates during internal tasks, such as memory retrieval, planning or autobiographical memories. Different diseases and circumstances have been shown to produce changes in posterior cingulate function, such as ageing, Alzheimer's disease, autism and depression. Traumatic brain injury induces a reduction in metabolism and blood perfusion in the damaged area, which is related to attention deficits with difficulties sustaining attention, producing attentional lapses and decreased cognitive performance. Although we did not perform any clinical evaluation in this study, dysfunction of this area was related to similar symptoms in craniectomized patients and could serve as evidence for further studies of the function of this brain region.

We are aware of several limitations in our study, with the most relevant likely being the previously mentioned possible miscalculation of regional CBP due to anatomical anomalies. Other relevant problems are related to the heterogeneous patient population in our study, with different causes leading to DC, a wide range of time intervals between surgeries, and different materials used to reconstruct the cranial defect. Another limitation of this study is that we only evaluated patients in decubitus and not in a standing or sitting position, which induces changes in cerebral blood and cerebrospinal fluid flows. The possibility of evaluating CBP changes in different positions is a clear advantage of this technique, which might be a good follow-up study. Finally, we are aware that the most interesting way forward in this line of study is to correlate these findings with changes in the clinical evolution of these patients.

Conclusions

CBP suffers significant changes after cranioplasty in patients with a decompressive craniectomy, regardless of whether they have clear signs and symptoms of SoT. As a significant and unique finding in our research, we observed a relevant change in CBP in the posterior cingulate, which might explain at least some of the symptoms, especially the attentional impairment observed in craniectomized patients. Our results indicate that use of 99 m-Tc HMPAO SPECT-CT and quantification of cortical regions might be useful in these patients as a tool to assess their CBP. Moreover, the evaluation of posterior cingulate perfusion could be useful in clinical management as a possible sign of prognosis to help the surgical team decide on the convenience of reconstructive surgery, although further clinical studies are needed to demonstrate such findings.

Declarations

ORCID

Not applicable

ACKNOWLEDGMENTS

Authors would like to thank all the staff of the departments involved in this study. Special mention to the secretary of the Nuclear Medicine Department, María Soledad Labanda, whose dedication and consistence in keeping the patients records and studies has been essential to the development of this study.

Funding

This project was funded by a research grant from the Carlos III Institute of Health, Ministry of Economy and Competitiveness (Spain), awarded on the 2016 call under the Health Strategy Action 2013-2016, within the National Research Programme oriented to Societal Challenges, within the Technical, Scientific and Innovation Research National Plan 2013-2016, with reference PI16/01939, co-funded with European Union ERDF funds (European Regional Development Fund).

Conflicts of interests/competing interests

The authors have no conflicts of interest to declare.

Availability of data and material

The datasets generated during and/or analysed during the current study are available from the corresponding author on reasonable request.

Code availability

Not applicable.

Authors' contributions

AG and IP collected, analysed the data and wrote the manuscript. SR, AGG and DV participated in the analysis of the images and data, and the review and editing of the article. Jafa was key in the conceptualization of the study, as well as analysis of the data. EG participated in the collection and analysis of the images. CR elaborated the statistical analysis of the study. Finally, AL and MJT as heads of the respective departments were key in coordinating both groups, as well as reviewing the manuscript.

Ethics approval

This study was revised and approved by the ethical committee of the Hospital Universitario 12 de Octubre (Reference: CEIC no: 16/361).

Consent to participate

Informed consent was obtained from all participants in this study.

Consent for publication

Informed consent was obtained from all participants in this study.

References

1. Annan M, De Toffol B, Hommet C, Mondon K. Sinking skin flap syndrome (or Syndrome of the trephined): a review. *Br J Neurosurg*. 2015;29:314–8. <https://doi.org/10.3109/02688697.2015.1012047>
2. Paredes I, Castaño AM, Cepeda S, Alén JA, Salvador E, Millán JM, Lagares A. The effect of cranioplasty on cerebral hemodynamics as measured by perfusion computed tomography and doppler ultrasonography. *J Neurotrauma*. 2016;33:1586–97. <https://doi.org/10.1089/neu.2015.4261>
3. Di Rienzo A, Colasanti R, Gladi M, Pompucci A, Della Costanza M, Paracino R, Esposito D, Iacoangeli M. Sinking flap syndrome revisited: the who, when and why. *Neurosurg Rev*. 2020;43:323–35. <https://doi.org/10.1007/s10143-019-01148-7>
4. Halani SH, Chu JK, Malcolm JG, Rindler RS, Allen JW, Grossberg JA, Pradilla G, Ahmad FU. Effects of cranioplasty on cerebral blood flow following decompressive craniectomy: a systematic review of the literature. *Neurosurgery*. 2017;81:204–16. <https://doi.org/10.1093/neuros/nyx054>
5. Grant FC, Norcross NC. Repair of cranial defects by cranioplasty. *Ann Surg*. 1939;110:488–512. <https://doi.org/10.1097/00000658-193910000-00002>
6. Yamaura A, Makino H. Neurological deficits in the presence of the sinking skin flap following decompressive craniectomy. *Neurol Med Chir (Tokyo)*. 1977;17:43–53. <https://doi.org/10.2176/nmc.17pt1.43>

7. Ashayeri K, Jackson EM, Huang J, Brem H, Gordon CR. Syndrome of the trephined: a systematic review. *Neurosurgery*. 2016;79:525–34. <https://doi.org/10.1227/neu.0000000000001366>
8. Erdogan E, Düz B, Kocaoglu M, Izci Y, Sirin S, Timurkaynak E. The effect of cranioplasty on cerebral hemodynamics: evaluation with transcranial Doppler sonography. *Neurol India*. 2003;51:479–81.
9. Stiver SI, Wintermark M, Manley GT. Reversible monoparesis following decompressive hemicraniectomy for traumatic brain injury. *J Neurosurg*. 2008;109:245–54. <https://doi.org/10.3171/jns/2008/109/8/0245>
10. Sakamoto S, Eguchi K, Kiura Y, Arita K, Kurisu K. CT perfusion imaging in the syndrome of the sinking skin flap before and after cranioplasty. *Clin Neurol Neurosurg*. 2006;108:583–5. <https://doi.org/10.1016/j.clineuro.2005.03.012>
11. Sarubbo S, Latini F, Ceruti S, Chieragato A, D'Esterre C, Lee TY, Cavallo M, Fainardi E. Temporal changes in CT perfusion values before and after cranioplasty in patients without symptoms related to external decompression: a pilot study. *Neuroradiology*. 2014;56:237–43. <https://doi.org/10.1007/s00234-014-1318-2>
12. Shahid AH, Mohanty M, Singla N, Mittal BR, Gupta SK. The effect of cranioplasty following decompressive craniectomy on cerebral blood perfusion, neurological, and cognitive outcome. *J Neurosurg*. 2018;128:229–35. <https://doi.org/10.3171/2016.10.jns16678>
13. Matsumura H, Shigehara K, Ueno T, Harunari N, Yoshizawa N, Ito H, Watanabe K. Cranial defect and decrease in cerebral blood flow resulting from deep contact burn of the scalp in the neonatal period. *Burns*. 1996;22:560–5. [https://doi.org/10.1016/0305-4179\(96\)00016-2](https://doi.org/10.1016/0305-4179(96)00016-2)
14. Isago T, Nozaki M, Kikuchi Y, Honda T, Nakazawa H. Sinking skin flap syndrome: a case of improved cerebral blood flow after cranioplasty. *Ann Plast Surg*. 2004;53:288–92. <https://doi.org/10.1097/01.sap.0000106433.89983.72>
15. Leech R, Sharp DJ. The role of the posterior cingulate cortex in cognition and disease. *Brain*. 2014;137:12–32. <https://doi.org/10.1093/brain/awt162>

Figures

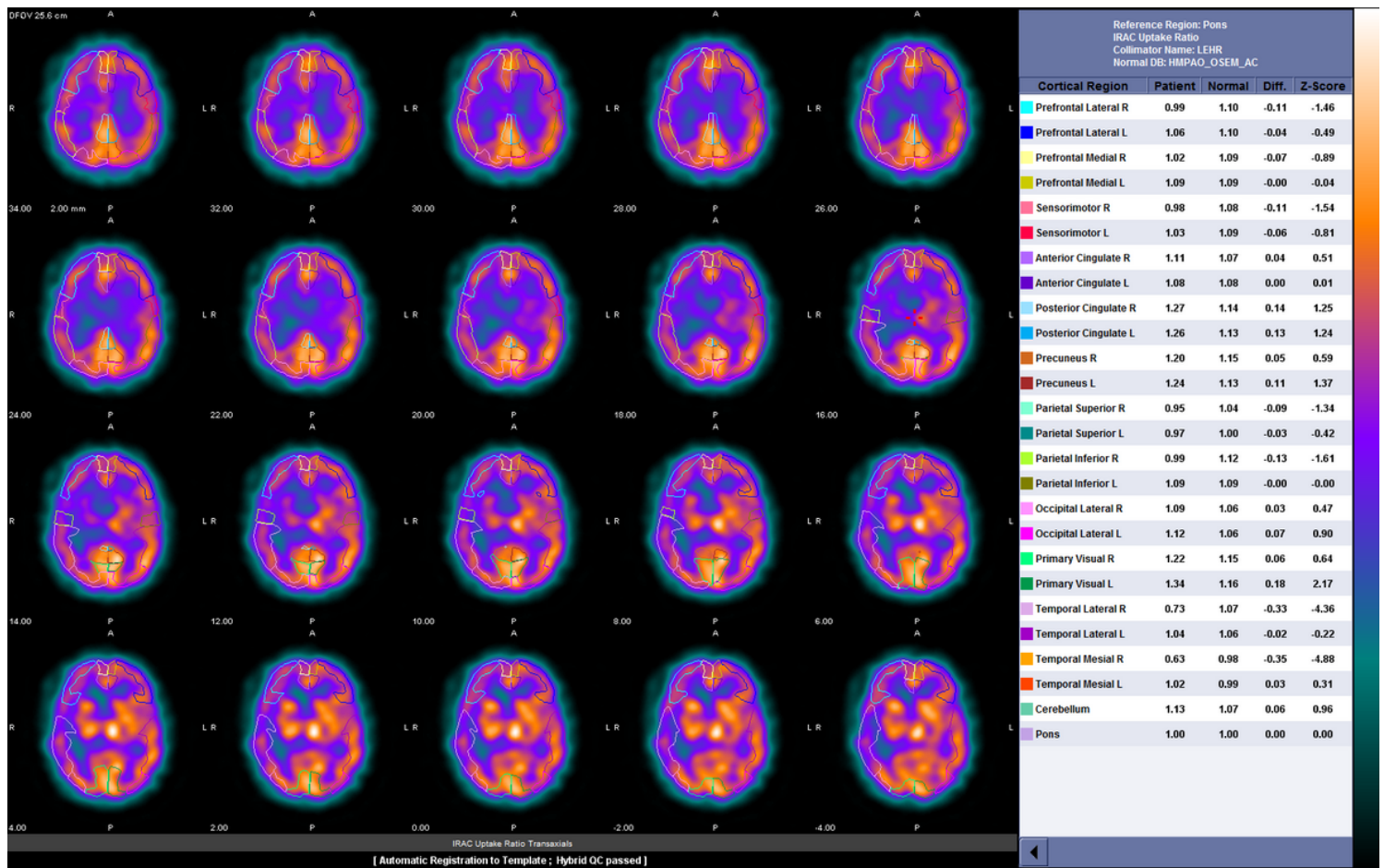


Figure 1

Segmentation of the cerebral cortex in transverse slices of the brain by postsurgical SPEC-CT. The lines in colours represent the cortical areas studied and quantified afterwards using ratio and Z-score

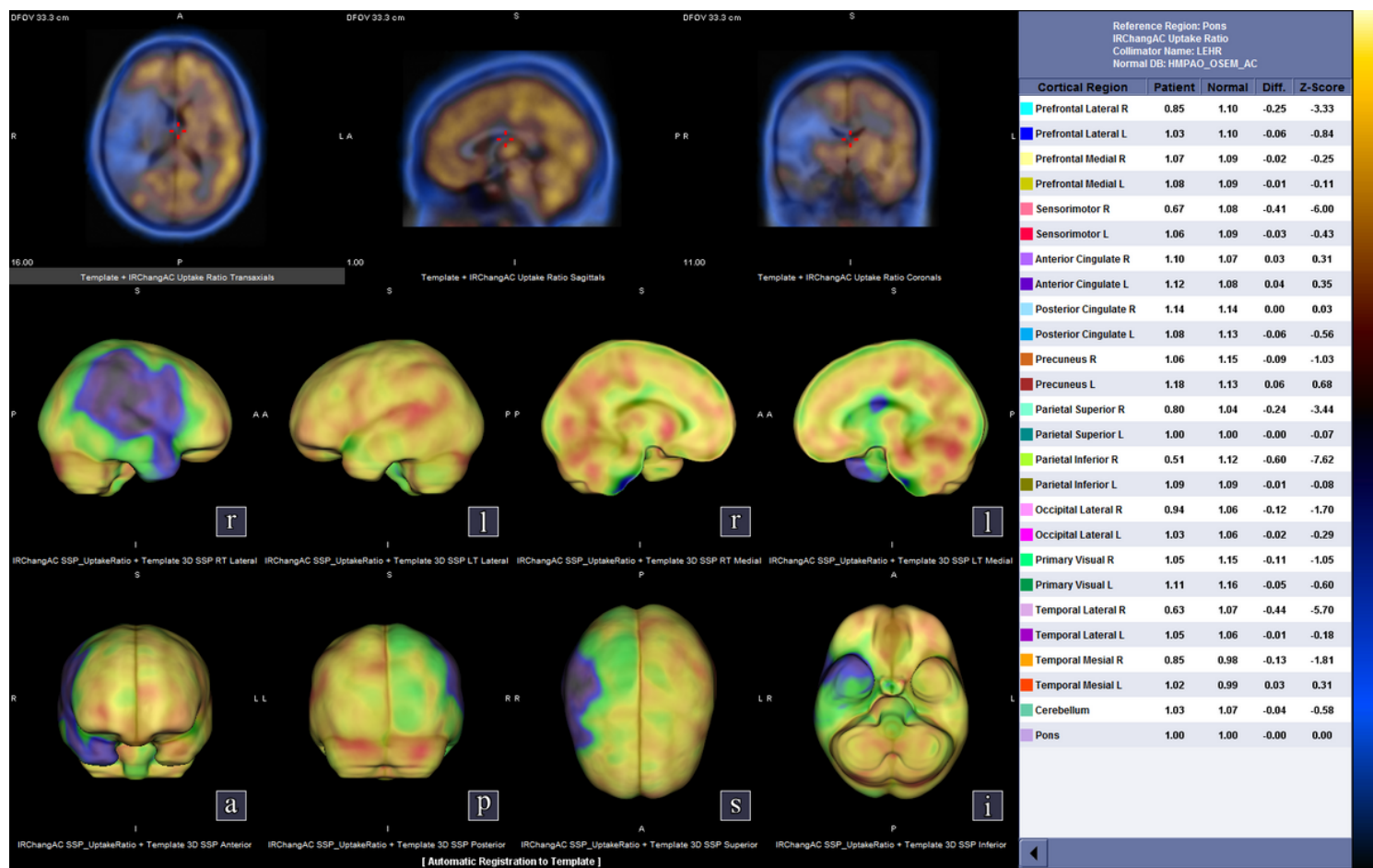


Figure 2

Visualization of the CBF on a presurgical SPECT-CT where the functional images are presented on a template of the normal brain. Defects and reduced perfusion in the frontal, parietal and parietal lobes of the right hemisphere are evident in the images and consequently provoke reduced CBF ratios (patient column) and Z-scores

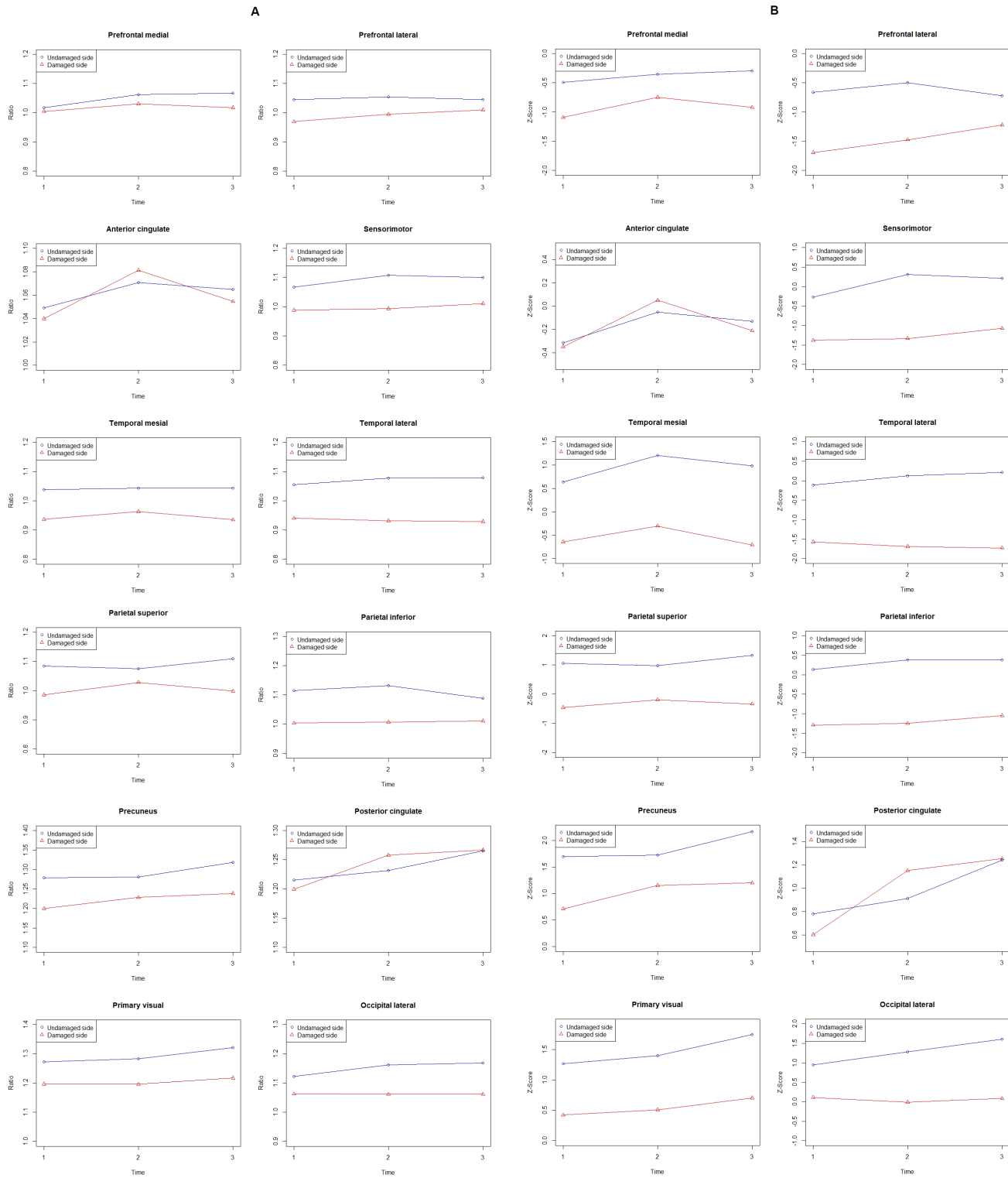


Figure 3

Graphics representing average variations in ratios (a) and Z-scores (b) in each of the 12 different cortical areas studied