

# Usefulness of Positron Emission Tomography-Guided Surgery with $^{64}\text{Cu}$ -Labeled Cetuximab for Resection of Intrapancreatic Primary and Residual Tumors in a Xenograft Mouse Model of Resectable Pancreatic Cancer

**Chika Igarashi**

National Institute of Radiological Sciences, National Institutes for Quantum and Radiological Science and Technology

**Yukie Yoshii** (✉ [yoshii.yukie@qst.go.jp](mailto:yoshii.yukie@qst.go.jp))

Kokuritsu Kenkyu Kaihatsu Hojin Ryoshi Kagaku Gijutsu Kenkyu Kaihatsu Kiko Hoshasen Igaku Sogo Kenkyujo <https://orcid.org/0000-0002-1773-5957>

**Hideaki Tashima**

National Institute of Radiological Sciences, National Institutes for Quantum and Radiological Science and Technology

**Yuma Iwao**

National Institute of Radiological Sciences, National Institutes for Quantum and Radiological Science and Technology

**Kohei Sakurai**

National Institute of Radiological Sciences, National Institutes for Quantum and Radiological Science and Technology

**Fukiko Hihara**

National Institute of Radiological Sciences, National Institutes for Quantum and Radiological Science and Technology

**Tomoko Tachibana**

National Institute of Radiological Sciences, National Institutes for Quantum and Radiological Science and Technology

**Eiji Yoshida**

National Institute of Radiological Sciences, National Institutes for Quantum and Radiological Science and Technology

**Hidekatsu Wakizaka**

National Institute of Radiological Sciences, National Institutes for Quantum and Radiological Science and Technology

**Go Akamatsu**

National Institute of Radiological Sciences, National Institutes for Quantum and Radiological Science and Technology

**Taiga Yamaya**

National Institute of Radiological Sciences, National Institutes for Quantum and Radiological Science and Technology

**Mitsuyoshi Yoshimoto**

Division of Functional Imaging, Exploratory Oncology Research & Clinical Trial Center, National Cancer Center

**Hiroki Matsumoto**

Nihon Medi-Physics Co., Ltd.

**Ming-Rong Zhang**

National Institute of Radiological Sciences, National Institutes for Quantum and Radiological Science and Technology

**Kotaro Nagatsu**

National Institute of Radiological Sciences, National Institutes for Quantum and Radiological Science and Technology

**Aya Sugyo**

National institute of Radiological Sciences, National Institutes for Quantum and Radiological Science and Technology

**Atsushi B Tsuji**

National Institute of Radiological Sciences, National Institutes for Quantum and Radiological Science and Technology

**Tatsuya Higashi**

National Institute of Radiological Sciences, National Institutes for Quantum and Radiological Science and Technology

---

**Original research**

**Keywords:** pancreatic cancer, PET-guided surgery, OpenPET, 64Cu-labeled cetuximab

**Posted Date:** August 10th, 2020

**DOI:** <https://doi.org/10.21203/rs.3.rs-53324/v1>

**License:**  This work is licensed under a Creative Commons Attribution 4.0 International License.

[Read Full License](#)

---

# Abstract

**Background:** Pancreatic cancer (PC) has a very poor prognosis. Surgery is the standard treatment for resectable PC but the accurate intraoperative identification and resection of intrapancreatic tumors remain challenging and tumor residuals frequently cause local recurrence. We have developed a novel open-type positron emission tomography (PET) system (called “OpenPET”) that enables high-resolution PET-guided surgery in real-time. Furthermore, we have demonstrated that OpenPET-guided surgery with ip-administered  $^{64}\text{Cu}$ -labeled anti-epidermal growth factor receptor antibody cetuximab can image and remove primary small (< 1 cm) resectable PC tumors in an orthotopic xenograft mouse model. Here, we further investigated the usefulness of OpenPET-guided surgery for the intraoperative identification and resection of not only primary but also unexpected residual intrapancreatic tumors using an orthotopic xenograft mouse model with large (> 1 cm) resectable PC and examined its survival benefit over conventional surgery.

**Methods:** To establish the model, human PC xPA-1-DC cells expressing red fluorescent protein (RFP) were slowly inoculated into the mouse pancreas. To investigate its usefulness, OpenPET-guided surgery was conducted 24 h after intraperitoneal administration of  $^{64}\text{Cu}$ -labeled cetuximab (7.4 MBq/mouse). For comparison, similar surgical procedures were conducted, and conventional tumor resection was attempted using only the naked eye (control). The survival rate after OpenPET-guided surgery was compared to that after control operations.

**Results:** The intraoperative OpenPET guidance enabled the detection and resection of both primary and small residual tumors. In this study, 10 residual tumor specimens were intraoperatively isolated with OpenPET guidance (n=7 mice); three and seven tumors were 5–10 mm and 3–5 mm in diameter, respectively. In all isolated specimens, tumor RFP signals were detected. By contrast, no tumor tissue was resected in control group because in this model, the locations and boundaries of primary tumors within the pancreas were not clearly detectable by the naked eye alone. Mice after OpenPET-guided surgery showed significantly longer survival rates than those in control group.

**Conclusions:** OpenPET-guided surgery with  $^{64}\text{Cu}$ -labeled-cetuximab enabled the intraoperative identification and resection of intrapancreatic primary and residual tumors *in vivo*. This technology could be useful to prevent tumor residuals during surgery and improve PC survival.

## Background

Patients with pancreatic cancer (PC) have a very poor prognosis, with an overall 5-year survival rate below 10% [1-4]. Surgical resection is the standard treatment for these patients who have resectable tumors at early stages; however, the efficacy of surgery is limited, leading to poor prognosis [5-7]. The majority of patients with PC who undergo surgery show local recurrence due to tumor residuals after surgery [8-10] since the accurate intraoperative identification and isolation of intrapancreatic tumors remains difficult. Hence, methods for the intraoperative detection and additional resection of unexpected

residual tumors within the pancreas are needed to address this problem, and the development of these methods is a significant aim.

Recently, we have developed a novel open-type positron emission tomography (PET) system (called "OpenPET"), which enables high-resolution PET-guided surgery in real-time [11-13]. This system is equipped with depth-of-interaction detectors providing high-resolution imaging (approximately 2 mm spatial resolution). This OpenPET arranges the detectors to provide sufficient space for conducting surgery with PET guidance. The OpenPET also includes a rapid image reconstruction system with graphics processing units that can provide continual images for surgeons in real-time by updating images in less than 1 s while accumulating data. Previously, we have shown that OpenPET-guided surgery with intraperitoneal (ip) administration of the anti-epidermal growth factor receptor (EGFR) antibody cetuximab labeled with  $^{64}\text{Cu}$  ( $\beta^+$  decay, 0.653 MeV, 17.4%;  $\beta^-$  decay, 0.574 MeV, 40%; electron capture, 42.6%) [14-16] is useful to detect and remove primary small (< 1 cm) resectable PC tumors in an orthotopic xenograft mouse model [17]. By contrast, the OpenPET with iv-administered  $^{64}\text{Cu}$ -cetuximab or ip- or iv-administered  $^{18}\text{F}$ -FDG (a traditional PET probe) did not detect the PC tissue [17]. Considering that EGFR (the target of cetuximab) is overexpressed in up to 90% of patients with PC [18, 19] and that EGFR overexpression is related to poor prognosis in PC [20], the OpenPET-guided surgery with ip-administered  $^{64}\text{Cu}$ -cetuximab might be a promising tool to assist in PC surgery. In this study, to explore the further potential application of this system, we investigated the usefulness of OpenPET-guided surgery for the identification and resection of not only primary but residual tumors during the surgical operation using an orthotopic xenograft mouse model with large (> 1 cm) resectable PC. Additionally, we examined the survival benefit of OpenPET-guided surgery over conventional surgery in this model.

## Materials And Methods

### Preparation of $^{64}\text{Cu}$ -labeled cetuximab

Production of  $^{64}\text{Cu}$  was performed as previously described [21]. Cetuximab obtained from Merck Serono (Darmstadt, Germany) was  $^{64}\text{Cu}$ -labeled with 3,6,9,15-tetraazabicyclo[9.3.1]pentadeca-1(15),11,13-triene-3,6,9-triacetic acid (PCTA; Macrocylics, Plano, TX, USA) as the chelator, which had previously been found to result in high radiolabeling yield and *in vitro* serum stability [22, 23].  $^{64}\text{Cu}$ -PCTA-cetuximab was synthesized using previously reported methods [22] with a specific activity of 1.7 GBq/mg. The injected protein dose of  $^{64}\text{Cu}$ -PCTA-cetuximab was adjusted to 20  $\mu\text{g}$  per mouse by adding an unlabeled antibody as reported previously [22].

### Cell culture and mouse model

Human pancreatic cancer xPA-1 cells expressing red fluorescent protein (RFP) in the cytoplasm and green fluorescent protein in the nucleus (xPA-1-dual-color [xPA-1-DC]; AntiCancer, San Diego, CA, USA) with

EGFR overexpression [24] were used in this study. xPA-1-DC cells were cultured in RPMI-1640 medium (Wako, Osaka, Japan) supplemented with 10% fetal bovine serum in a humidified atmosphere of 95% air and 5% CO<sub>2</sub> at 37°C.

All animal experimental procedures were approved by the Animal Ethics Committee of the National Institutes for Quantum and Radiological Science and Technology (QST, Chiba, Japan) and conducted in accordance with the institutional guidelines. Six-week-old female BALB/c nude mice were obtained from Japan SLC (Shizuoka, Japan) and used in this study. Before the experiments, the mice were acclimated for at least 1 week. This study used a mouse model with intrapancreatic cancer xenografts generated by inoculating xPA-1-DC cells into the pancreas. After an abdominal incision,  $5 \times 10^6$  xPA-1-DC cells in 25  $\mu$ L RPMI-1640 medium mixed with 25  $\mu$ L ice-cold Matrigel (BD Biosciences, Franklin Lakes, NJ, USA) were slowly injected into the pancreas. One week later, the model mice were used for the experiments. Prior to surgery experiments, the tumor location in the established model was confirmed using a stereoscopic fluorescence microscope (MZ16F; Leica, Wentzler, Germany).

## OpenPET-guided surgery and its efficacy

The model mice were randomized into two groups: OpenPET-guided surgery group and control group (n = 7 per group). For the OpenPET-guided surgery group, <sup>64</sup>Cu-PCTA-cetuximab (7.4 MBq) were ip administered 24 h before surgery. The OpenPET-guided surgery (i.e., day 0) was performed according to previously reported procedures and settings [17]. Briefly, this study used a prototype of the OpenPET system, which was developed previously for use in small animal experiments [11, 12], containing 32 detector blocks (4-layer depth-of-interaction detectors with 16 × 16 × 4 crystals each) in a cylinder with a diameter of 25 cm. The detectors are axially shifted incrementally to form an accessible open space (14-cm wide) for surgical procedures in mice. In this system, the field of view with its cylindrical shape defined by two parallel planes slanted at 45° relative to the axial direction was 11.4 cm in diameter with a 10.2-cm axial length, and a spatial resolution is approximately 2 mm [11, 12]. This system used a 1-pass list-mode dynamic row-action maximum-likelihood algorithm with a graphics processing unit for high-speed reconstruction that enabled image updating in cycles of < 1 s while accumulating list-mode data. Reconstructed OpenPET images were represented as sliced images of the transaxial, coronal, and sagittal planes on the screen in front of the surgeon. These images were displayed as radioactivity-density values (kBq/mL) based on the calibration with standards having known radioactivities. During surgery, the mice remained under 2% isoflurane anesthesia, and their body temperatures were maintained with a heater. Real-time OpenPET images were acquired to identify the tumor location before surgery. The laparotomy was conducted by cutting the abdominal wall and skin, and the pancreas with the primary tumor was exteriorized and observed with OpenPET. While monitoring the position of the tumor within the pancreas in real-time using the OpenPET, detected tumors were resected after ligation with a clamp to prevent bleeding. The presence or absence of remaining signals was intraoperatively checked using real-time OpenPET imaging. If signals were detected, additional resections for residual tumor tissue were reconducted until the signals disappeared. After confirming the absence of signals from residual tumors,

the pancreas was returned to the abdomen, and the peritoneum and skin were closed using surgical sutures. After the OpenPET-guided surgery, resected tissues were examined with a stereoscopic fluorescence microscope to verify tumor RFP signals. In the control group (on day 0), similar surgical procedures with incisions and anesthesia were conducted to exclude any effects of the operation itself. To examine the benefits of OpenPET guidance over the conventional surgical method, tumor resection without OpenPET guidance, i.e., with the naked eye alone, was also attempted. Mice of both groups were weighed and observed for 50 days after the surgery. Mice were also sacrificed when reaching a humane endpoint defined as a noticeable extension of the abdomen, development of ascites, or body weight loss (> 20%). On day 7 after the surgery, tumor growth was observed using *in vivo* fluorescent imaging with an IVIS Lumina imaging system (PerkinElmer, MA, US) to detect tumor RFP signals.

## **Uptake of $^{64}\text{Cu}$ -PCTA-cetuximab into resected tumor specimens**

The accumulation of  $^{64}\text{Cu}$ -PCTA-cetuximab into the resected specimens was evaluated after the surgery. The resected tumor specimens were weighed, and radioactivity levels were measured with a  $\gamma$ -counter (1480 Automatic gamma counter Wizard 3; PerkinElmer). The values of the percentage of injected dose per gram (%ID/g) were calculated.

## **Statistical analysis**

Data are expressed as the mean and standard deviation. Differences in survival were evaluated using the log-rank test. *P* values < 0.05 were considered statistically significant.

## **Results**

### **Assessment of the orthotopic xenograft mouse model with large resectable PC**

In this study, the model mice with orthotopic xenograft of large resectable PC were assessed on day 7 after xPA-1-DC cell inoculation. The laparoscopy with a stereoscopic fluorescence microscope confirmed in this model intrapancreatic PC xenografted tumors (> 1 cm). Their locations and boundaries were not clearly identifiable with the naked eye (Fig. 1). At this time point, the model mice had no visible metastases.

### **Usefulness of OpenPET-guided surgery to resect primary and residual tumors**

Fig. 2 shows an overview of the OpenPET-guided surgery for the mouse model with orthotopic xenograft of large resectable PC. The observations during and after the OpenPET-guided surgery are shown in Figs. 3–4 and Fig. 5, respectively, and in Video S1. The OpenPET clearly detected primary tumor lesions before and during surgery in all examined mice (Fig. 3 and Fig. 5). The detected tumor lesions were resected while monitoring their location using OpenPET for guidance; these tumors could not be identified with the naked eye alone (Figs. 3–5). After the first or second resection containing large primary tumor specimens (> 5 mm in size), mice in 3 of the 7 cases showed the absence of OpenPET signals (Fig. 5), whereas in the remaining 4 mice, signals were still detected by real-time OpenPET (Fig. 4 and Fig. 5). In these cases, small residual tumor specimens (approximately 3 mm) not visible to the naked eye were resected with OpenPET guidance (Fig. 4 and Fig. 5). An approximately 10–30-s data acquisition was sufficient to identify the primary and residual tumors during surgical procedures. The tumor-containing specimens resected by OpenPET-guided surgery showed high uptake of  $^{64}\text{Cu}$ -PCTA-cetuximab; the average was  $15.8 \pm 4.9$  %ID/g (Fig. 5a). The uptake values were not significantly different between large specimens (first and second resections) and small residual tumor specimens (Fig. 5a). Tumor RFP signals were detected in all isolated specimens resected by OpenPET-guided surgery (Fig. 5b, c). By contrast, no tumor tissue was resected in the control group because in this model, the locations and boundaries of primary tumors within the pancreas were not clearly detectable by the naked eye alone.

## Survival benefit of OpenPET-guided surgery

Survival was significantly extended in the OpenPET-guided surgery group compared to that in the control group ( $P = 0.0003$ , Fig. 6). The values for median survival time were 8 and 31 days in the control and OpenPET-guided surgery groups, respectively. All mice in the control group had died by day 14 due to primary PC growth. By contrast, 29% of the mice in the OpenPET-guided surgery group (2 of 7 mice, mouse number 5 and 7 in Fig. 5) survived until day 50 after surgery, whereas the remaining 71% mice (5 of 7 mice) died of local recurrence and peritoneal metastasis between day 29 and day 41. In the two surviving mice, no tumor lesions were detected at day 50. No mouse in any group showed a decrease in body weight over 20% relative to the initial body weight up to the experimental endpoint. *In vivo* fluorescence imaging at day 7 detected strong tumor fluorescence signals from the primary tumor site in all mice of the control group (Fig. 6b). On the other hand, in the OpenPET-guided surgery group, no or weak tumor fluorescence signals were detected at the primary tumor site (Fig. 6b).

## Discussion

In this study, we demonstrated that OpenPET-guided surgery was useful for the intraoperative identification and resection of residual tumors using an orthotopic xenograft mouse model with large (> 1 cm) resectable PC. During the surgical procedure, the OpenPET-guided surgery was able to detect and resect not only primary tumors but also small residual tumors (approximately 3 mm), which were invisible to the naked eye. OpenPET-guided surgery resulted in significantly prolonged survival compared to control operations without OpenPET guidance. These data indicate that OpenPET-guided surgery may serve as a

useful tool to improve survival following PC surgery by facilitating intraoperatively the accurate resection of intrapancreatic primary and residual tumors.

Surgical excision is the standard mode of treatment for resectable PC at early stages [5-7]. Due to difficulties in identifying residual tumors of the pancreas with the naked eye alone during surgical procedures, the majority of patients show local recurrence, leading to poor outcomes [8-10]. In the present study, the conventional surgery approach could not detect intrapancreatic tumors in the mouse model, which seems to be consistent with the difficult intraoperative identification of residual pancreas tumors in clinical practice. Since the use of the OpenPET approach enabled the resection of primary and residual tumors in this model, OpenPET-guided surgery may be beneficial in clinical settings to detect residual pancreas tumors invisible to the naked eye in conventional surgery approaches.

In recent decades, many studies on fluorescence-guided surgery have been conducted to explore methods for the intraoperative identification of residual tumors in PC [25]. Cetuximab-IRDye800 is one of the successful fluorescent agents for fluorescence-guided PC surgery, and a phase 1–2 clinical trial has been conducted [26]. This clinical trial has demonstrated that this dye-coupled antibody can intraoperatively identify PC tumors in patients with high sensitivity. Based on previous studies, fluorescence-guided surgery is a very powerful tool to intraoperatively detect PC tumors; however, detecting tumor lesions in deeper tissue layers inside the pancreas is challenging due to the limited penetration depth of this method reaching only a few millimeters [27-29]. However, OpenPET is good at measuring objects located in deeper regions of the pancreas by detecting photons from electron-positron annihilation as demonstrated in the present study by OpenPET-guided surgery with  $^{64}\text{Cu}$ -PCTA-cetuximab. Using mouse models of gastrointestinal cancer, our previous study has also shown that this system can detect tumors located deep in the peritoneal cavity and behind other organs [22]. Based on this evidence, OpenPET-guided surgery may be helpful to identify PC tumors located inside the pancreas in humans, and the combined use of fluorescence- and OpenPET-guided surgery could be a promising option to compensate for the weaknesses of the former. In this study, we used a small-size OpenPET system to verify the feasibility of PET-guided surgery in mice. Recently, a corresponding large-size system for human use with a similar spatial resolution to that of the small-size system was developed in our institute [30], and the feasibility of OpenPET-guided surgery in clinical settings will be investigated in the near future.

The OpenPET has a limited spatial resolution of 2 mm [11, 12]. Our previous study has demonstrated that this system could not detect tumors smaller than 3 mm [17]. In the present study, residual tumors smaller than 3 mm were not isolated from animals of the OpenPET-guided surgery group. Although OpenPET-guided surgery improved survival compared to control operation without this guidance, 71% of mice in the OpenPET-guided surgery group ultimately presented local tumor recurrence and peritoneal metastases. These recurrences might have been caused by microscopic residual tumors that had not been detected by OpenPET. Adjuvant chemotherapy or ip-administered  $^{64}\text{Cu}$ -PCTA-cetuximab therapy [24] would be reasonable options to prevent these recurrences.



This study has several limitations. In this study, we demonstrated that OpenPET-guided surgery was an effective method to detect and remove residual PC tumors and prolonged survival in comparison to control mice. However, the safety and benefit of OpenPET-guided surgery over conventional surgical procedures should be assessed by further studies in humans. It is also worth considering the benefits of a preoperative OpenPET diagnosis for the planning of conventional surgical procedures. Besides, although this study demonstrated the usefulness of OpenPET-guided surgery, increased radiation exposure to surgeons may pose a problem for its clinical application. Since this system provides open space to approach the patient, other surgical methods such as endoscopic or robotic surgery may also be applicable. In recent decades, endoscopic and robotic surgery have already been used in clinical practice for patients with PC to safely perform the surgical resection and reduce postoperative complication rates [31]. Therefore, the use of those surgical systems under OpenPET guidance should be studied to minimize radiation exposure of surgeons in the future.

## Conclusion

We demonstrated that OpenPET-guided surgery enabled the intraoperative identification and resection of primary and residual tumors in a mouse model of large (> 1 cm) resectable PC orthotopic xenografts. We also showed that OpenPET-guided surgery improved the efficacy compared to control surgery without PET guidance. Our findings suggest that OpenPET-guided surgery can serve as a novel technology to identify intraoperatively tumor residuals, thus improving the prognosis in PC.

## Abbreviations

EGFR: epidermal growth factor receptor; ip: intraperitoneal; OpenPET: open-type PET system; PC: pancreatic cancer; PCTA: 3,6,9,15-tetraazabicyclo[9.3.1]pentadeca-1(15),11,13-triene-3,6,9-triacetic acid; PET: positron emission tomography; RFP: red fluorescent protein; xPA-1-DC: dual-color xPA-1 cells

## Declarations

## Ethics approval and consent to participate

All animal experimental procedures were approved by the Animal Ethics Committee of the National Institutes for Quantum and Radiological Science and Technology (QST, Chiba, Japan) and conducted in accordance with the institutional guidelines.

## Consent for publication

Not applicable.

## Availability of data and material

The datasets used and/or analyzed during the current study are available from the corresponding author on reasonable request.

## Competing interests

Hiroki Matsumoto is an employee of Nihon Medi-Physics Co., Ltd. None of the other authors declare any conflict of interest.

## Funding

This work was supported by a Kakenhi grant (No. 19H03609) of the Japan Society for the Promotion of Science.

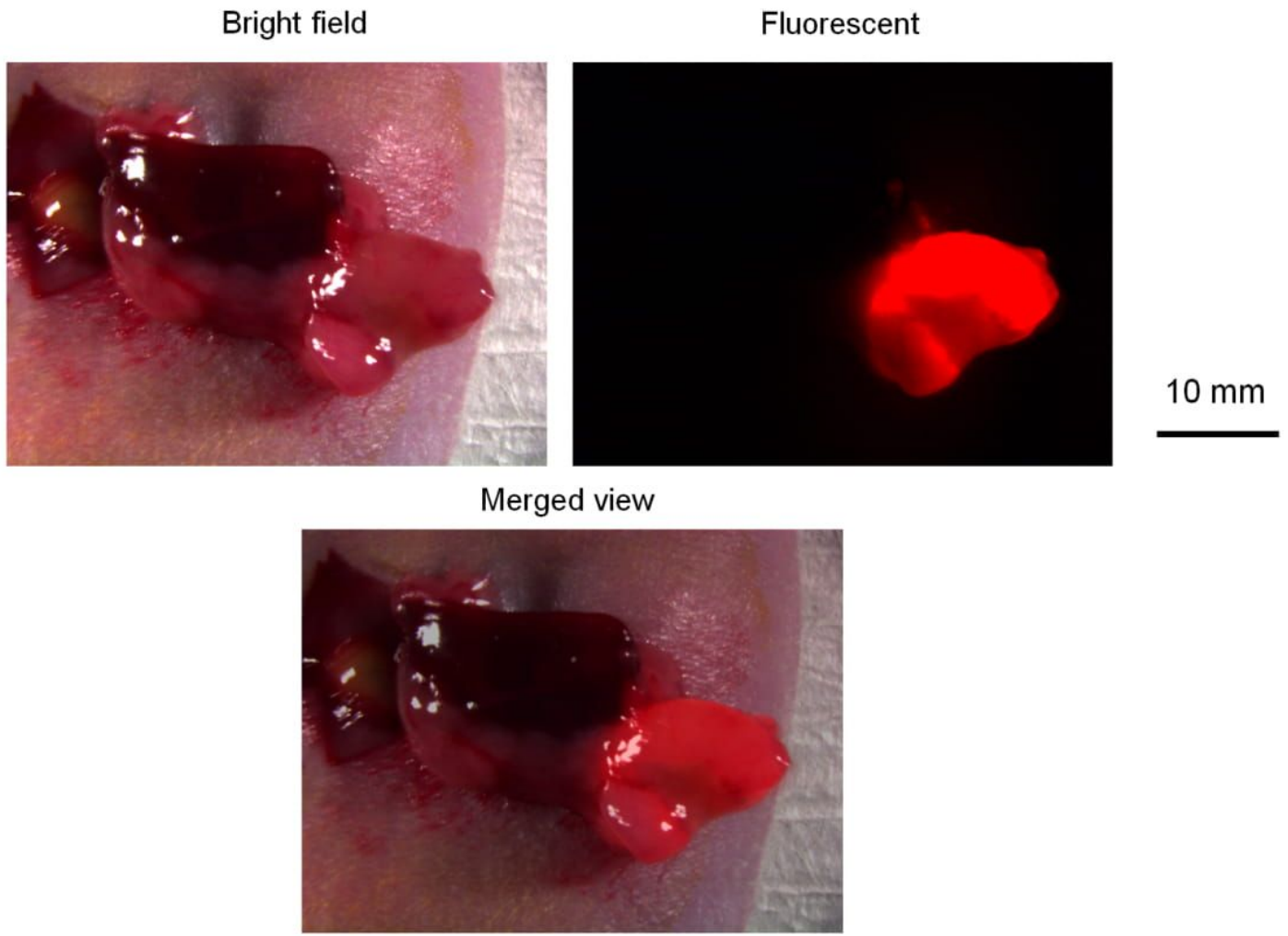
## Authors' contributions

All authors contributed to the design of the study. C.I., Y.Y., H.T., Y.I., K.S., F.H., T.T., E.Y., H.W., G.A., T.Y., M.Y., H.M., M.R.Z., K.N., and A.S. performed the experiments. Y.Y., H.T., T.Y., H.M., A.B.T., and T.H. wrote the manuscript. All authors also made significant contributions by discussing the results, enhancing the manuscript, and contributing intellectual content. All authors approved the final version submitted for publication.

## Acknowledgments

We thank Mr. Hisashi Suzuki (QST) for providing the radiopharmaceuticals. We thank Editage for English language editing.


## Figures



**Figure 1**

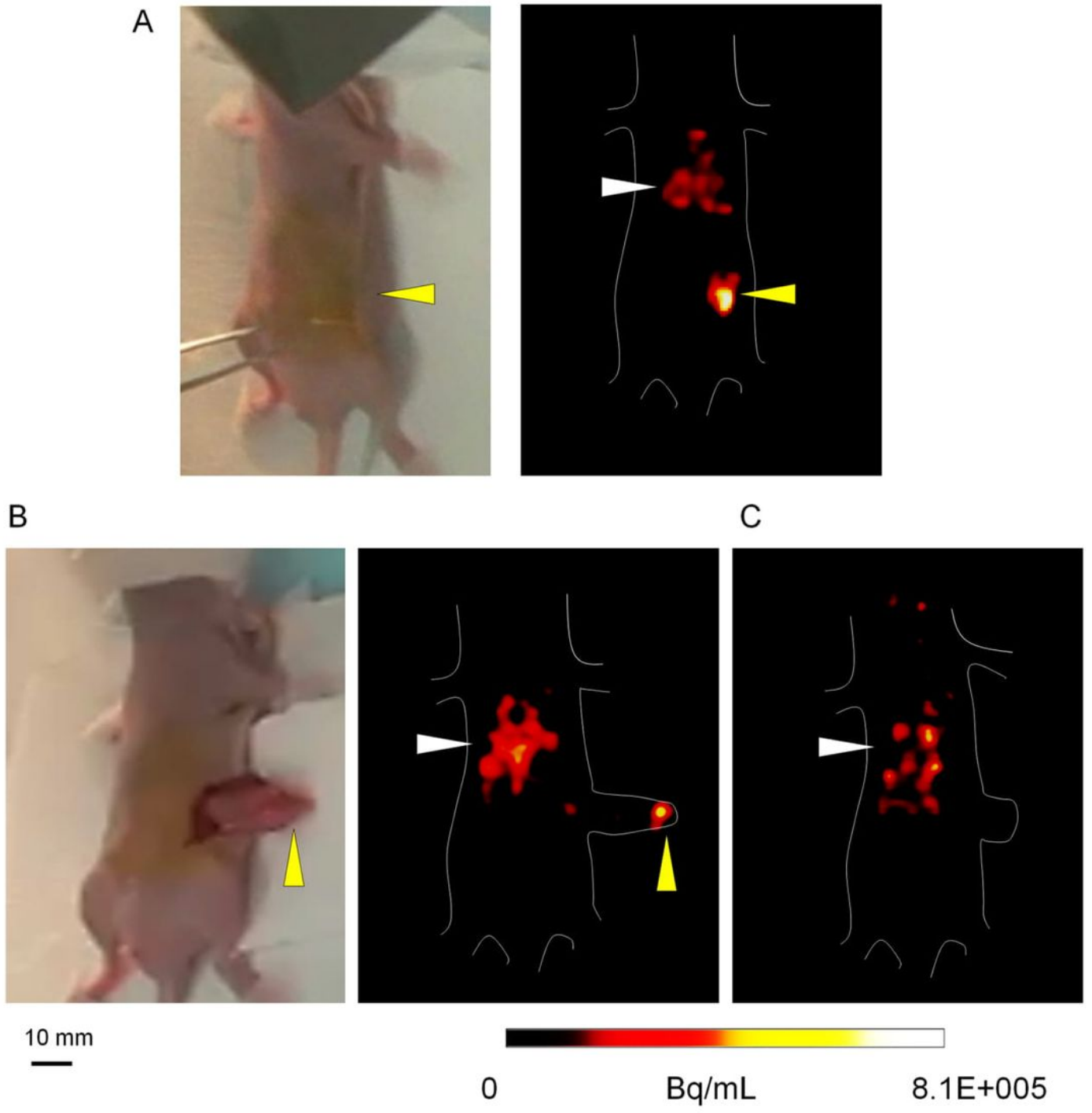
Mouse model with orthotopic xenograft of large resectable PC using xPA-1-DC cells used in this study. Representative images of the exteriorized pancreas including the primary tumor, obtained using a stereoscopic fluorescence microscope. Bright-field (upper, left), red fluorescence (upper, right), and merged (lower) views are shown.

## OpenPET-guided surgery for pancreatic cancer



**Figure 2**

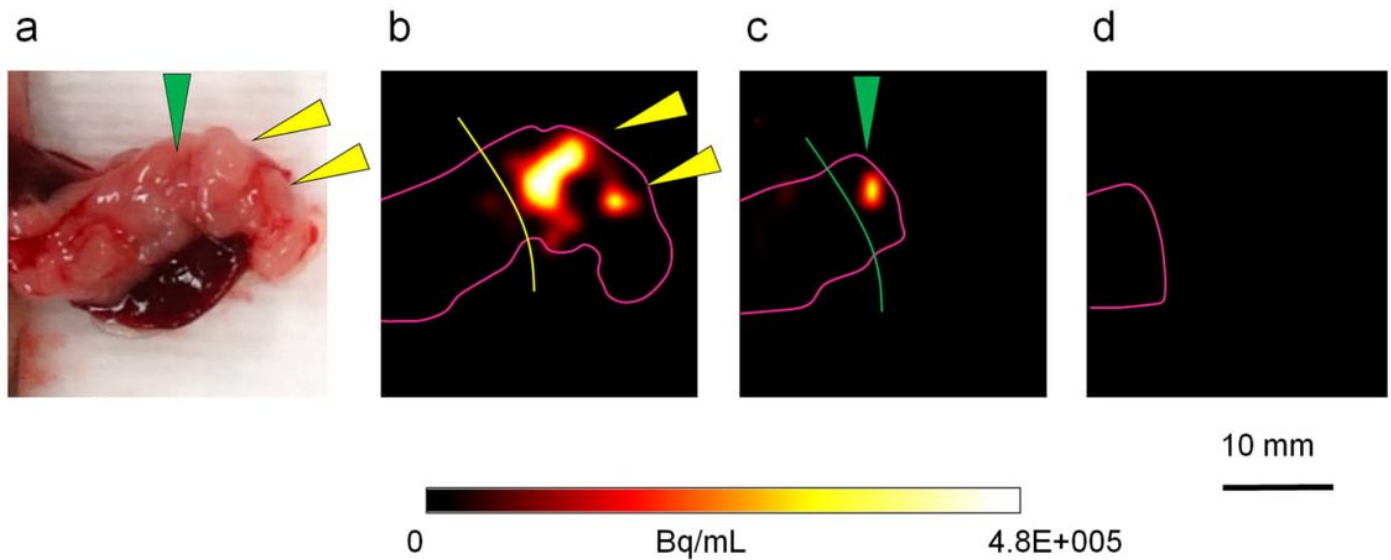
Overview of the OpenPET-guided surgery approach used to resect PC tumors in mice. Appearance of the OpenPET system during the surgical procedure. In the OpenPET, detectors were slantingly arranged to allow the surgeon access to the mouse. The operation was performed while monitoring real-time OpenPET images using the screen in front of the surgeon.



**Figure 3**

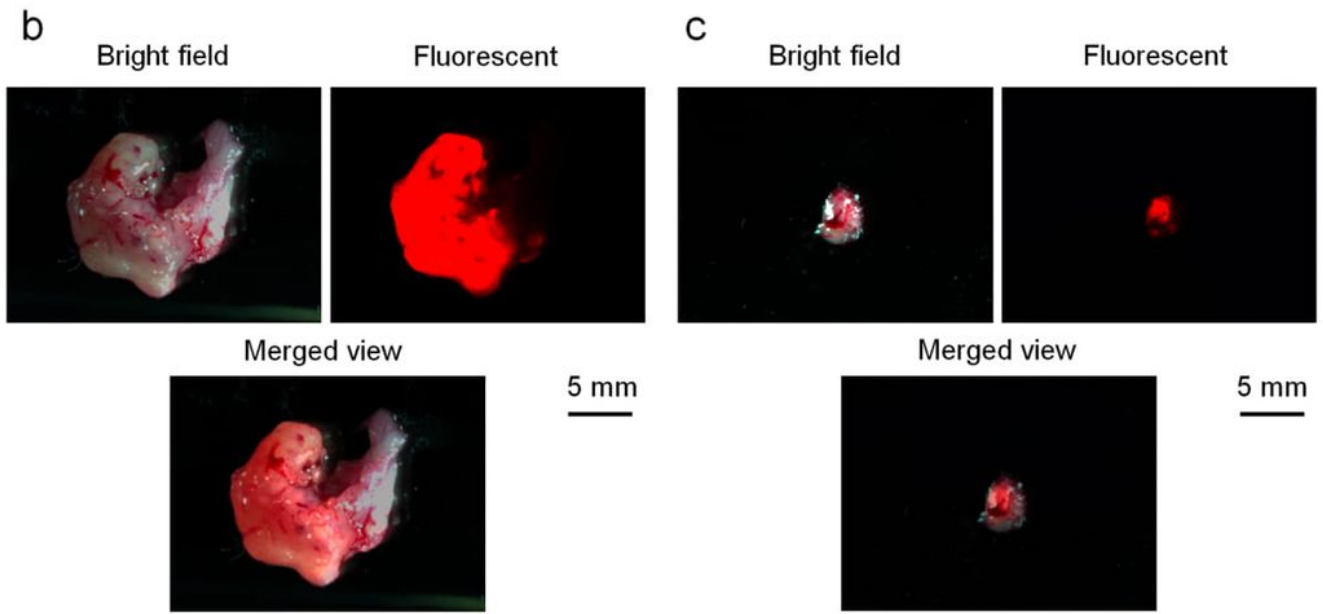
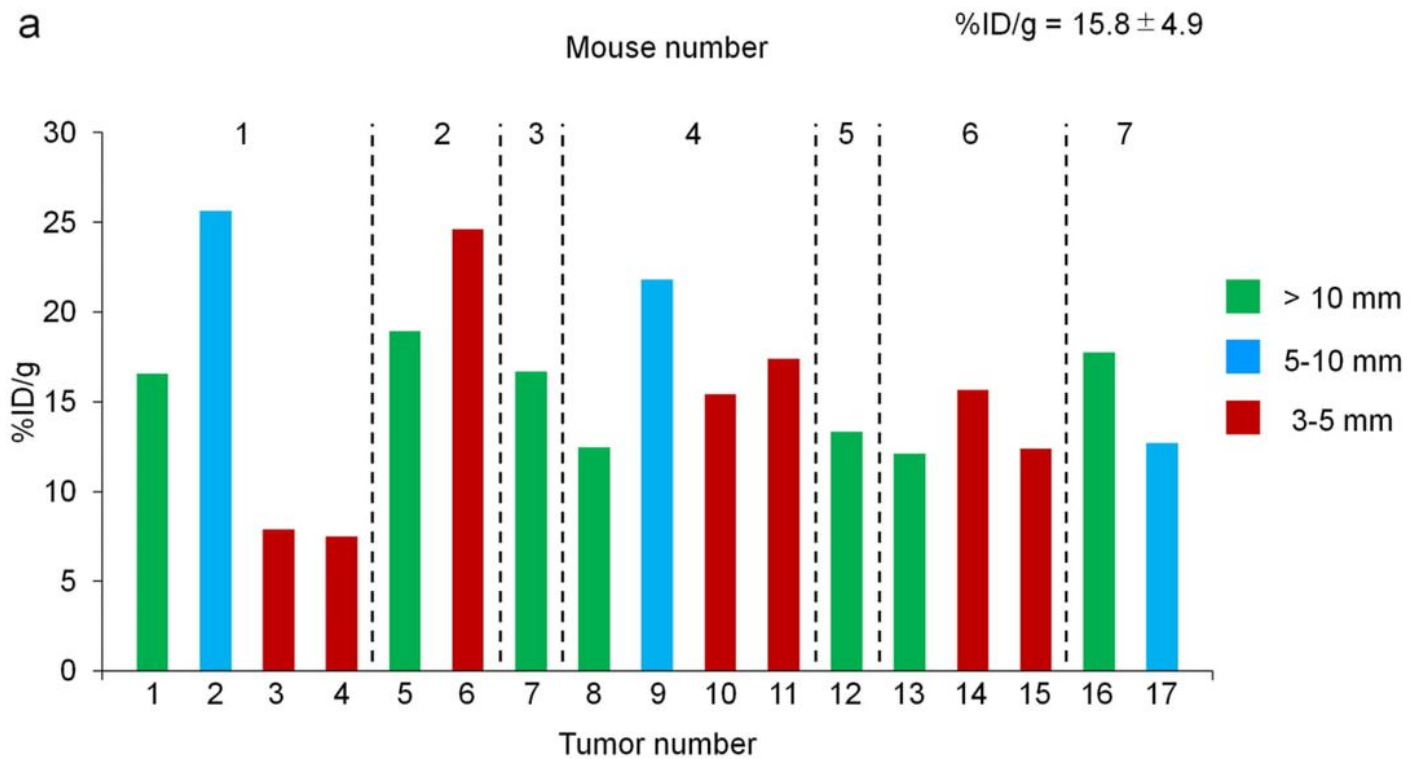
OpenPET-guided surgery to detect and resect xPA-1-DC primary tumors within the pancreas. a Images before surgery. Bright-field (left) and OpenPET (right) images. b Images during surgery. A mouse with the exteriorized pancreas containing xPA-1-DC tumors is shown. Bright-field (left) and OpenPET (right) images. c OpenPET image after tumor resection. Tumor-associated OpenPET signals have disappeared.

Tumor and liver are indicated by yellow and white arrowheads, respectively. Scales at the bottom apply to a-c. This animal is also shown as mouse no. 5 in Fig. 5.



**Figure 4**

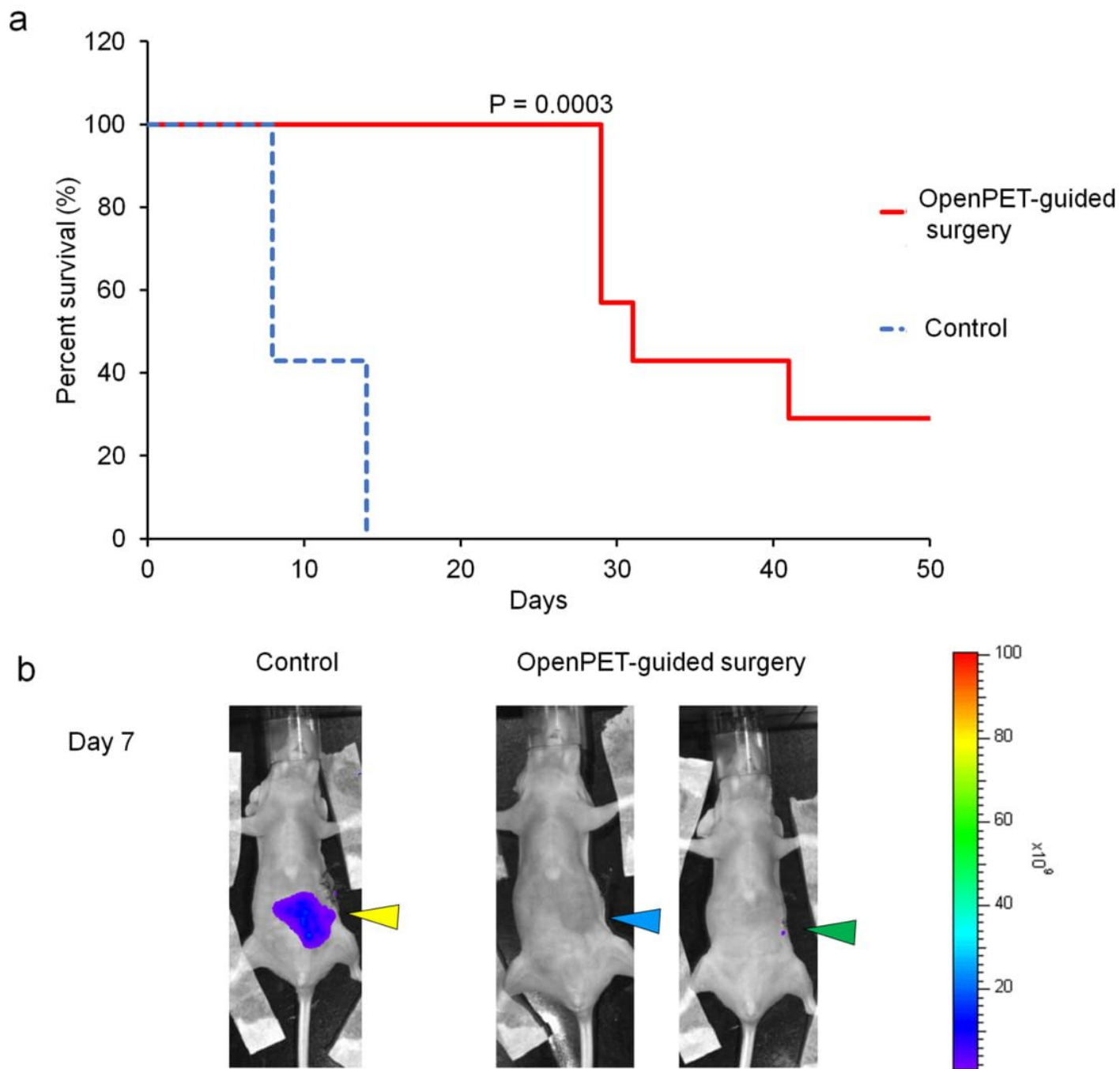
OpenPET-guided surgery to detect and resect primary and small residual xPA-1-DC tumors within the pancreas. a, b Bright-field (a) and OpenPET (b) images of the exteriorized pancreas containing xPA-1-DC tumors. Two primary tumor lesions (yellow arrowheads, also in a) were detected, and both were resected (yellow line, b). c OpenPET image after the first resection. A small residual tumor was detected (green arrowhead, also in a) and resected with OpenPET guidance (green line, c). d OpenPET image after the additional resection. The OpenPET signal of the residual tumor has disappeared.



**Figure 5**

Analysis of the resected tumor specimens after OpenPET-guided surgery. a Summary of the tumor specimens resected during OpenPET-guided surgery. Bars indicate the size (> 10 mm, green; 5–10 mm, blue; 3–5 mm, red) and accumulation of  $^{64}\text{Cu}$ -PCTA-cetuximab (%ID/g) of each tumor specimen. For more details, see the text. b, c Representative images of resected primary (b) and residual (c) tumor

specimens. Bright-field (upper, left), red fluorescence (upper, right), and merged (lower) views are shown, respectively.



**Figure 6**

Efficacy of OpenPET-guided surgery vs control operation without this guidance. a Survival curves of the OpenPET-guided surgery and control groups (n = 7 per group). b In vivo fluorescence imaging at day 7 in representative mice. In the control group (left), strong tumor fluorescence signals were detected at the primary tumor site (yellow arrowhead). In the OpenPET-guided surgery group, no or weak tumor



fluorescence signals were detected at the primary tumor site (middle and right, respectively; blue and green arrowheads, respectively). There was a significant difference in survival between the two groups.

## Supplementary Files

This is a list of supplementary files associated with this preprint. Click to download.

- [OpenPETguidedSurgeryVideo1.mp4](#)
- [IgarashiSupplementPETguidedSurgeryPancreaticCancer1.docx](#)