

Cancer cells invasion to the gastric bare area adipose tissue: a poor prognostic predictor for gastric cancer

Yongming Chen (✉ chenyongm@sysucc.org.cn)

Sun Yat-sen University Cancer Center <https://orcid.org/0000-0001-9308-8213>

Shuhang Xu

Third Affiliated Hospital of Sun Yat-Sen University

Chunyu Huang

Sun Yat-sen University Cancer Center

Yihong Ling

Sun Yat-sen University Cancer Center

Chengcai Liang

Sun Yat-sen University Cancer Center

Yuhua Miao

Sun Yat-sen University Cancer Center

Xiaowei Sun

Sun Yat-sen University Cancer Center

Yuanfang Li

Sun Yat-sen University Cancer Center



Zhiwei Zhou

Sun Yat-sen University Cancer Center

Research

Keywords: gastric cancer; GBA; GBAI; retroperitoneal infiltration; TDs

DOI: <https://doi.org/10.21203/rs.3.rs-52811/v1>

License:   This work is licensed under a Creative Commons Attribution 4.0 International License. [Read Full License](#)

Abstract

Background: The relationship between gastric bare area adipose tissues invasion (GBAI) confirmed pathologically and the prognosis of gastric cancer (GC) patients is undefined. Till present, there hasn't been literature investigating this phenomenon. Here, we aimed at analyzing the implication of GBAI in GC.

Methods: The data of 1822 patients who underwent radical surgery between January 2000 and December 2013 at the Sun Yat-sen University Cancer Center were retrieved. Pathologically, tumor deposits (TDs) located >5mm from the leading edge of the primary tumor and the lymph nodes (LNs) station number 1, 2, 7, and 9 were considered as GBAI. Kaplan-Meier method, log-rank test and Cox's proportional hazards model were employed to analyze.

Results: 205 (11.3%) patients were pathologically diagnosed with GBAI, which was more commonly found in proximal or linitis plastica than distal GC ($P<0.001$). There was significant difference in 5-year survival between patients with and without GBAI for stages IIB, IIIA, IIIB, IIIC, respectively ($P<0.009$ for IIB, IIIA and IIIB, $P=0.021$ for IIIC). Among the 205 GBAI patients, 61 had detailed radiological follow-up data in which 26 (34.7%) were found to have retroperitoneal infiltration, 27 (36.0%) had peritoneal metastasis, 10 (13.3%) had hematogenous metastasis, 16 (21.3%) had lymphatic metastasis, and 16 (21.3%) had others.

Conclusions: GBAI was identified as a predictor of unfavourable prognosis for GC and was more commonly found in the proximal or linitis plastica of the stomach than in distal stomach. Retroperitoneal infiltration was one of the most commonly identified metastatic route for GC associated with GBAI after radical surgery.

Introduction

The latest global cancer statistics showed that GC is now the sixth most common cancer affecting the global population but still rank third as the leading cause of cancer mortality¹. In mainland China², GC remains third as the most prevalent cancer and leading cause of cancer-related death; illustrating a much higher incidence and mortality than in any other country, and most importantly, China also comprise nearly one-half of the total global GC incidence²⁻⁴.

Recurrences and metastases following radical surgery are major challenges to tackle for improving the survival outcomes of GC as these are the main factors associated with GC-related death. Currently, the most effective prognostic factors for GC are the depth of the primary tumor invasion (T), the number of metastatic regional lymph nodes (N), and status of distant metastasis (M), which are merged into known commonly used TNM staging system for GC survival prognostication. However, solely considering the TNM staging system for optimal prognostication may not be reliable as it has been showed that GC patients despite being classified within the same TNM subgroup may still have different survival outcomes; possibly related to tumor heterogeneity⁵. As such, abundant researches have tried to identify other prognostic factors such as vascular invasion, nerve invasion, adipose connective tissue invasion, ratio of lymph node metastasis, and more, but their global acceptance and application has been limited⁶⁻⁹ as their clinical applicability are controversial and yet to be widely validated. Thus, more researches are still warranted.

The gastric bare area (GBA) is a special location in the stomach without any visceral peritoneum coverage and is located at a small posterosuperior area of the gastric surface, near the cardiac orifice. Specifically, it is the place where the stomach liaise with the diaphragm at the reflexions of the gastrophrenic and left gastropancreatic folds, surrounded by the dorsal mesogastrum¹⁰. From an anatomical point of view, the GBA can be considered as a bridge from abdominal organ to retroperitoneal space, saturating with areolar tissue. Till present, there has been only one radiologic study regarding the invasion of the GBA by cancer, termed as the GBA invasion, and was found as a poor prognosis factor for survival¹¹. Nevertheless, this study was limited due to considering swollen lymph nodes as one kind of GBA invasion and the absence of pathological evidence. To date, there has been no research regarding the pathological confirmation of GBAI and the relationship between GBAI and GC prognosis is yet to be elucidated.

In this present study, we aimed to identify the incidence of GBAI in a large cohort of GC and to evaluate its association with the clinicopathological characteristics and prognosis of GC.

Materials And Methods

Patients

Between January 2000 and December 2013, the data of 1822 patients who underwent radical surgery at the Department of Gastric Surgery, Sun Yat-sen University Cancer Center were retrieved. Eligibility criteria for patient inclusion comprised of: (1) histologically confirmed diagnosis of gastric adenocarcinoma and R0 gastrectomy; (2) no other synchronous malignancy; (3) no preoperative chemotherapy or perioperative radiotherapy; (4) gastrectomy and lymphadenectomy based on the Japanese Gastric Cancer treatment guidelines¹²; (5) more than 15 post-operative pathologically reported lymph nodes, and; (6) a postoperative survival time of more than 1 month; considered as the non-surgical relative death. Patients with carcinoma of the gastric stump after gastric resection for benign disease were excluded from this study. Retrieved data included the patient gender, tumor size, histological grade, status of vascular invasion, nerve invasion, adipose connective tissue invasion, GBA invasion, depth of invasion (pT), nodal status (pN), distant metastasis (pM), and the number of retrieved lymph nodes. Pathological staging was performed according to the 8th edition of the AJCC cancer staging manual.

Follow-up protocol

Follow-ups were performed by telephone, email, or outpatient department visits. The last follow-up date was December 2018. The postoperative follow-ups included clinical and laboratory examinations every 3 months for the first 2 years at our outpatient department, every 6 months from the third to fifth postoperative years, and then annually thereafter or until the patient died. Overall survival (OS) was defined as the time from the operation to death or the last follow-up.

Range of GBAI

Three important ligaments compose the boundary of the GBA, namely the medial gastrodiaphragmatic ligament (MGDL), lateral gastrodiaphragmatic ligament (LGDL) and gastropancreatic ligament (GPL), as shown in **Figure 1**. The hepatogastric ligament contains two layers, the anterior layer and posterior layer. The

rightward extension of anterior layer becomes the peritoneum of the anterior gastric wall at the lesser curvature. The posterior layer turns posteriorly and right laterally at the lesser curvature, connecting with the right diaphragmatic crura. This peritoneum reflex from the lesser curvature to the right diaphragmatic crura is the so called MGDL which is the right boundary of the GBA. The right posterior extension of the peritoneum of the posterior gastric wall from the fundus and the great curvature to the left diaphragmatic crura becomes the LGDL, which is the left boundary of the GBA. The inferior extensions of MGDL and LGDL becomes the GPL at the superior border of the pancreas which is the inferior boundary of GBA. The left gastric artery and vein pass through the GPL. Based on the 3rd English edition of Japanese classification of gastric carcinoma, the definition of the station number 1, 2, 7, and 9 LNs stations are: the right paracardial LNs including those along the first branch of the ascending limb of the left gastric artery; the left paracardial LNs include those along the esophagocardiac branch of the left subphrenic artery; LNs along the trunk of the left gastric artery between its root and the origin of its ascending branch; and the LNs along the celiac artery, respectively¹³. Thence, we consider the adipose tissues invasion in the area of LNs station number 1, 2, 7, and 9 or attached to the primary tumor involving the proximal of stomach as GBAI.

Histologic Evaluation of GBAI

For each patient, all postoperative pathological slides were reviewed to evaluate the presence of GBAI. Existence of GBAI was examined by reviewing the adipose tissues attached to the primary tumor involving the proximal stomach, and the LNs station number 1, 2, 7, and 9. For pathologic examination of these adipose tissues, tumor deposits (TDs) located >5mm from the leading edge of primary tumors and LNs were considered as the GBAI, irrespective of their shape, contour, and size.

In this study, adipose tissue invasion was defined as TDs residing in the adipose tissues neighboring the stomach. These TDs were identified using these three primary characteristics: (1). they were located in the adipose tissues and were separated from the primary tumor or lymph nodes; (2). there were no structures of blood or lymphatic vessel, lymphatic nodes, nerves around them; (3). they were enveloped by a proper fascia and could be clearly discriminated from peritoneal seeding.

Imaging assessment

One radiologist performed all imaging reassessment. She was blinded to the clinical and survival data of the patients. CT images were evaluated independently at the workstation using transverse CT (images were reconstructed with a 5-mm section thickness). Metastasis were categorized into five types, namely as retroperitoneal infiltration, peritoneal, hematogenous, lymphatic, and others. The radiological manifestations including posterior-pancreas infiltration, para-aortic infiltration, mesenterium roots thickening, and thickening of the rectal lining were considered as retroperitoneal infiltration, as shown in **Figure 2**; peritoneal nodules/thickening, Douglas pouch nodules and abdominal mass were considered as peritoneal metastasis; liver, lung, and bone were considered as hematogenous metastasis; para-aortic, left supraclavicular, mediastinum, porta hepatis LNs were considered as lymphatic metastasis; umbilical region, ovary mass, anastomotic astium were considered as others. It was difficult to classify ascites as retroperitoneal infiltration or peritoneal metastasis, so ascites was considered as others.

Statistical analysis

The 5-year overall survival rate was estimated using the Kaplan-Meier method and univariate comparisons between groups was performed using the log-rank test. In the multivariate analyses, the Cox's proportional hazards model was carried to estimate the relative risks and to identify corresponding prognostic factors. All data analyses were performed using the SSPS software (version 22.0, Stata Corporation, Texas, USA). A P value less than 0.05 (two-sided) was considered as statistically significant.

Results

Clinic-pathological characteristics

Of the 1822 patients, 1220 (67.0%) were male. The mean age of the entire study cohort was 58.0 ± 12.0 years old. The mean number of lymph nodes retrieved was 27.0 ± 10.8 . The median follow-up was 92 months (range 3-214 months). The 5-year OS rate for all the patients was 60.9%, and 1109 patients were alive at last follow-up.

Eight parameters were significantly associated with the OS on univariate analyses, namely, age, tumor size, tumor site, vascular invasion, adipose tissues invasion, GBAI, depth of invasion (pT), and nodal status (pN) (**Table 1**). In the multivariate analyses for OS, age, tumor site, adipose tissues invasion, GBAI, depth of invasion (pT) and nodal status (pN) were identified as independent prognostic factors (**Table 1**). The 5-year survival rates for all the stages were as follows: IA: 96.0%, IB: 92.4%, IIA: 86.2%, IIB: 66.3%, IIIA: 61.1%, IIIB: 43.6%, IIIC: 25.5% (**Figure 3**).

Table 1. Clinic-pathological characteristics and the univariate, multivariate survival analysis in gastric cancer patients and in patients with GBAI or not.

Variables	n (%)	5-year survival rate (%)	P	HR (95% CI)	P	Non-GBAI (%)	GBAI	P	HR (95% CI)	P
Gender			0.580					0.883		
Female	602 (33.0)	60.0				534 (33.0)	68 (33.2)			
Male	1220 (67.0)	61.3				1083 (67.0)	137 (66.8)			
Age (y)			0.004					0.176		
<50	478 (26.2)	66.3		ref.		432 (26.7)	46 (22.4)			
≥50	1244 (73.8)	58.9		1.02 (1.01-1.03)	<0.001	1185 (73.3)	159 (77.6)			
Tumor size (cm)			<0.001					<0.001		
≤5.0	1210 (66.4)	66.5		ref.		1112 (68.8)	98 (47.8)		ref.	
>5.0	612 (33.6)	49.7		1.03 (0.89-1.20)	0.668	505 (31.2)	107 (52.2)		1.08 (0.87-1.33)	0.304
Tumor site			<0.001					<0.001		
Distal	1006 (55.2)	70.3		ref.		954 (59.0)	52 (25.4)		ref.	
Proximal/limitis lastica	816 (44.8)	49.3		1.43 (1.23-1.68)	<0.001	663 (41.0)	153 (74.6)		1.63 (1.40-1.90)	<0.001
Histological grade			0.234					0.009		
Well/moderately differentiated	262 (14.4)	69.5				247 (15.3)	15 (7.3)		ref.	
Poorly differentiated	1197 (65.7)	58.3				1054 (65.2)	143 (69.8)		1.18 (0.93-1.51)	0.174
Undifferentiated/signet ring cell carcinoma	363 (19.9)	63.1				316 (19.5)	47 (22.9)		1.16 (0.87-1.54)	0.309
Vascular invasion			<0.001					<0.001		
No	1529 (83.9)	62.9		ref.		1396 (86.3)	133 (64.9)		ref.	
Yes	293 (16.1)	50.5		0.883 (0.72-1.08)	0.217	221 (13.7)	72 (35.1)		1.07 (0.87-1.33)	0.506
Nerve invasion			0.932					<0.001		
No	1465 (80.4)	60.8				1348 (83.4)	117 (57.1)		ref.	
Yes	357 (19.6)	61.1				269 (16.6)	88 (42.9)		0.86 (0.69-1.06)	0.152
Adipose tissues invasion			<0.001							
No	1437 (78.9)	67.6		ref.						
Yes	385 (21.1)	35.6		1.31 (1.05-1.65)	0.019					
GBAI			<0.001							
No	1617 (88.7)	63.1		ref.						
Yes	205 (11.3)	19.6		1.45 (1.12-1.89)	0.005					
Depth of invasion			<0.001					<0.001		
T1	235 (12.9)	96.2		ref.		235 (14.5)	0 (0.0)		ref.	
T2	217 (11.9)	83.4		3.35 (1.61-7.98)	0.001	215 (13.3)	2 (1.0)		3.36 (1.61-7.00)	0.001
T3	421 (23.1)	64.4		5.94 (2.99-11.80)	<0.001	377 (23.3)	44 (21.5)		6.66 (3.35-13.25)	<0.001
T4a	892 (49.0)	45.9		8.46 (4.30-	<0.001	744 (46.0)	148 (72.2)		9.33 (4.75-	<0.001

T4b	57 (3.1)	38.6		16.63) 10.49 (4.95- 22.22)	<0.001	46 (2.8)	11 (5.4)	18.31) 10.97 (5.18- 23.24)	<0.001
Nodal status			<0.001						<0.001
N0	561 (30.8)	80.6		ref.		551 (34.0)	10 (4.9)	ref.	
N1	289 (15.9)	74.7		1.08 (0.80- 1.46)	0.612	272 (16.8)	17 (8.3)	1.14 (0.84- 1.53)	0.400
N2	306 (16.8)	61.1		1.54 (1.18- 2.01)	0.001	273 (16.9)	33 (16.1)	1.61 (1.23- 2.10)	<0.001
N3a	402 (22.1)	46.8		2.41 (1.89- 3.01)	<0.001	336 (20.8)	66 (32.2)	2.49 (1.96- 3.17)	<0.001
N3b	264 (14.5)	25.0		3.95 (3.04- 5.14)	<0.001	185 (11.4)	79 (38.5)	4.23 (3.27- 5.47)	<0.001

Association of GBAI with GC clinicopathological characteristics

205 (11.3%) of the 1822 investigated cases were diagnosed with GBAI on pathology, mainly observed in stage IIB, IIIA, IIIB and IIIC (**Table 1**). Seven parameters were significantly associated with GBAI on univariate analysis, namely, tumor size, tumor site, histological grade, vascular invasion, nerve invasion, depth of invasion (pT) and nodal status (pN) (**Table 1**). In multivariate analyses, tumor site, depth of invasion (pT) and nodal status (pN) remained as independent prognostic factors for GBAI (**Table 1**).

Statistically significant differences in survival were found between all the TNM stage groupings as shown in **Figure 3** ($P < 0.01$). However, no statistically significant difference in survival between GBAI patients in stage IIB to IIIC ($P = 0.159$) (**Figure 4**). Interestingly, the difference in 5-year OS between all the patients with GBAI and without GBAI in stages IIB to IIIC was statistically significant (24.4% vs. 54.8%, $P < 0.01$) (**Figure 5**). The 5-year OS for patients with GBAI were as follows: IIB: 35.3%, IIIA: 26.3%, IIIB: 23.9%, IIIC: 21.7%. Further, statistically significant differences between patients with GBAI and without GBAI in stages IIB, IIIA, IIIB, IIIC were also found ($P < 0.01$ for IIB, IIIA, and IIIB, $P = 0.021$ for IIIC) (**Figure 6**). For the purpose of confirming the predictive value of adipose tissues invasion in GBA rather than in other place, we compared the 5-year overall survival rate between these two groups (**Figure 7**). The 5-year OS for the patients with adipose tissues invasion outside GBA were as follows: IIB (n=28): 50.0%, IIIA (n=41): 63.4%, IIIB (n=56): 48.3%, IIIC (n=47): 34.0%. The result showed statistically significant differences in 5-year OS between patients with GBAI and adipose tissues invasion outside GBA in stage IIIA, IIIB, IIIC, respectively ($P < 0.01$ for IIIA, IIIB and $P = 0.050$ for IIIC); apart for stage IIB ($P = 0.117$).

Metastasis status of GBAI patients

In the 205 GBAI patients, only 61 had medical records with detail data of radiological examinations during follow-up (**Table 2**). Of them, 26 (34.7%) had retroperitoneal infiltration, 27 (36.0%) had peritoneal metastasis, 10 (13.3%) had hematogenous metastasis, 16 (21.3%) had lymphatic metastasis, and 16 (21.3%) had other types of metastasis.

Table 2: the detail of metastasis status of GBAI patients.

Metastasis paths	N
Retroperitoneal infiltration	26
Mesenterium roots thickening	17
para-aortic infiltration	4
posterior-pancreas infiltration	6
rectum circled thickening	7
Peritoneal metastasis	27
peritoneal nodules/thickening	18
douglas pouch nodules	12
abdominal mass	5
Hematogenous metastasis	10
liver	7
lung	4
bone	1
Lymphatic metastasis	16
para-aortic	14
left supraclavicular	3
mediastinum	3
porta hepatis	2
Others	16
umbilical region	3
ovary mass	6
anastomotic astium	3
ascites	4

Discussion

Adipose tissues invasion, also known as TDs, is defined as the satellite peritumoral lesion in peritumoral adipose tissue of a primary carcinoma without any histological evidence of any residual lymph node or

vessels structure. It was firstly recognized in rectal cancer by Gabriel in 1935¹⁴. Quantity of researches confirmed that TDs was not only limited to colorectal cancer but also common to different tumor types, including gastric, biliary duct, and pancreatic cancers¹⁵⁻¹⁸. The impact of TDs on GC outcomes had been investigated by many researchers and was associated with poor prognosis. In the 8th edition of AJCC gastric cancer staging manual¹⁹, TDs without identifiable lymph node tissue or identifiable vascular or neural structure, regardless of their shape, contour and size, are considered as regional LN metastases for the purposes of gastric cancer staging. However, some research suggested that TDs in GC should be incorporated into the T category and treated as a form of serosal invasion^{20,21}. Nevertheless, the prognostic impact of TDs is undeniable, the algorithm of staging with TDs is controversial.

Our research showed that 205 (11.3%) of 1822 patients were pathologically diagnoses as GBAI and were commonly found in stage IIB, IIIA, IIIB and IIIC. GBAI status was related to T staging, N staging and tumor site in multivariate analysis; signifying that deeper gastric wall infiltration and larger number of LNs metastasis could relate to greater risk of identifying GBAI. There are similar survival curves among stage IIB, IIIA, IIIB and IIIC with GBAI ($P=0.159$, **Figure 4**), and Kaplan-Meier plot showed some overlapping survival curves among each other, implying there is no significant difference in prognosis for patients with GBAI. Upon further analysis, the distance between 5-year survival curves of the patients staged IIB with GBAI and without GBAI, staged IIIA with GBAI and without GBAI, staged IIIB with GBAI and without GBAI, staged IIIC with GBAI and without GBAI become widely, respectively, reflecting higher mortality risks of the patients with GBAI than without GBAI in the same stage ($P<0.009$ for IIB, IIIA, IIIB and $P=0.021$ for IIIC, **Figure 6**). Significant differences in the 5-year survival rates were also observed between patients with GBAI and with TDs outside GBA in patients staged as IIIA, IIIB and IIIC ($P<0.009$ for IIIA, IIIB and $P=0.050$ for IIIC, **Figure 7**). Although, P value of stage IIB is 0.117, with no statistically significant differences, we noted that the distance between two curves spread increasingly wide interval; possibly caused due to the small sample size of stage IIB ($n=28$ vs. $n=16$).

The 5-year survival rates for the patients with GBAI were as follows: IIB: 35.3%; IIIA: 26.3%; IIIB: 23.9%; IIIC: 21.7%. Also, the 5-year survival rates for all patients staged as IIIB and IIIC were 43.6% and 25.5%. The 5-year survival rate of the patients staged as IIB with GBAI was similar to all patients staged as IIIB, and the 5-year survival rates of patients staged as IIIA, IIIB, IIIC were similar to all patients staged as IIIC. These results demonstrated that GBAI was associated with poorer prognosis than others in the same stage.

GBA is the place where the stomach contacts the diaphragm at the reflexions of the gastrophrenic and left gastropancreatic folds, surrounded by dorsal mesogastrum¹⁰. From the anatomic point of view these parts of the stomach are located retroperitoneally, once tumor invade GBA, it will spread to the retroperitoneal space subsequently²². A mass of researches regarding severe acute pancreatitis²³⁻³¹ suggested that there are contiguous spaces in the retroperitoneal spaces which are directly or indirectly related with each other, for instance the peripancreatic region, perirenal and posterior pararenal space, the root of the small bowel mesentery, as well as pelvic retroperitoneal space. These contiguous spaces in the retroperitoneum are the anatomy basic for retroperitoneal infiltration.

Researches showed that adipocytes which were found in the close proximity to tumors, along tumor margins, or within the tumor body, exhibited both short- and long-range interactions with cancer cells³²⁻³⁴. These

adipocytes, the so called cancer-associated adipocytes (CAAs), also referred to as tumor-infiltrating adipocytes, influence tumor biology in a number of ways, including by promoting angiogenesis and inflammation. The CAAs are the molecular biological basic for retroperitoneal infiltration. Hence, cancer cells of patients with GBAI will go through GBA, like a bridge, diffusing to retroperitoneal space under the interactions with CAAs, causing retroperitoneal infiltration which was different from peritoneal metastasis; as shown in **Figure 2**. This can be the possible reason of the poor prognosis when cancer invade the GBA. Our follow-up data showed there were 26 (42.6%) cases occurred retroperitoneal infiltration, which were in accordance with this perspective.

In our research, we found that GBAI in the proximal or linitis plastica GC was more common than distal GC. The GBA is locate at the posterior of proximal gastric wall, when the proximal primal tumor penetrates serosa or lymph node metastasis at this area, the cancer cells will invade adipose tissues in GBA easier; being one of the cause for the poor prognosis of proximal GC as compared to of distal GC of the same TNM subgroup. This perspective resonates with that of a study by Wu et al.²².

Despite the important findings described, there are still some limitations worth acknowledging in this present study. First, our population cohort was from a single institution, based on relatively limited retrospective data on GBAI, of which only 61 patients had medical records detailing the radiological finding on metastatic route. Second, the basis of the scientific hypothesis of the present study was from clinical observation of retroperitoneal infiltration which is believed to be one of the most commonly identified metastatic route for GC. Nevertheless, future multicenter prospective studies are necessary to validate our findings.

Conclusions

GBAI was identified as a predictor of unfavourable prognosis for GC and was more commonly found in the proximal or linitis plastica of the stomach than in distal stomach. Retroperitoneal infiltration was one of the most commonly identified metastatic route for GC associated with GBAI after radical surgery.

Abbreviations

GC: Gastric cancer; AJCC: American Joint Committee on Cancer; TNM: tumor-node-metastasis; TDs: tumor deposits; GBA: gastric bare area; GBAI: gastric bare area tissues adipose invasion; MGDL: medial gastroduaphragmatic ligament; LGDL: lateral gastroduaphragmatic ligament; GPL: gastropancreatic ligament; CAAs: cancer-associated adipocytes.

Declarations

Ethics approval and consent to participate

The study protocol was approved by the Research Ethics Committee of Sun Yat-Sen University Cancer Center.

Consent for publication

We obtained the patients' or legal representative's consent for publication of this study.

Availability of data and materials

The key raw data have been deposited into the Research Data Deposit (<http://www.researchdata.org.cn>).

Competing interests

The authors declare that they have no competing interests.

Funding

Not applicable.

Author contributions

All authors contributed toward data analysis, drafting, and revising the paper and agree to be accountable for all aspects of the work.

Acknowledgements

Not applicable.

References

1. Bray F, Ferlay J, Soerjomataram I, Siegel RL, Torre LA, Jemal A. Global cancer statistics 2018: GLOBOCAN estimates of incidence and mortality worldwide for 36 cancers in 185 countries. *CA: a cancer journal for clinicians* 2018;**68**(6): 394-424.
2. Chen W, Zheng R, Zeng H, Zhang S, He J. Annual report on status of cancer in China, 2011. *Chinese journal of cancer research = Chung-kuo yen cheng yen chiu* 2015;**27**(1): 2-12.
3. Ferlay J, Soerjomataram I, Dikshit R, Eser S, Mathers C, Rebelo M, Parkin DM, Forman D, Bray F. Cancer incidence and mortality worldwide: sources, methods and major patterns in GLOBOCAN 2012. *International journal of cancer* 2015;**136**(5): E359-386.
4. Wang FH, Shen L, Li J, Zhou ZW, Liang H, Zhang XT, Tang L, Xin Y, Jin J, Zhang YJ, Yuan XL, Liu TS, Li GX, Wu Q, Xu HM, Ji JF, Li YF, Wang X, Yu S, Liu H, Guan WL, Xu RH. The Chinese Society of Clinical Oncology (CSCO): clinical guidelines for the diagnosis and treatment of gastric cancer. *Cancer communications* 2019;**39**(1): 10.
5. Seeruttun SR, Xu L, Wang F, Yi X, Fang C, Liu Z, Wang W, Zhou Z. A homogenized approach to classify advanced gastric cancer patients with limited and adequate number of pathologically examined lymph nodes. *Cancer communications* 2019;**39**(1): 32.
6. Nishibeppu K, Komatsu S, Ichikawa D, Imamura T, Kosuga T, Okamoto K, Konishi H, Shiozaki A, Fujiwara H, Otsuji E. Venous invasion as a risk factor for recurrence after gastrectomy followed by chemotherapy for stage III gastric cancer. *BMC cancer* 2018;**18**(1): 108.
7. Wang YX, Shao QS, Yang Q, Wang YY, Yang J, Zhao ZK, Xu J, Ye ZY. Clinicopathological characteristics and prognosis of early gastric cancer after gastrectomy. *Chinese medical journal* 2012;**125**(5): 770-774.

8. Graham Martinez C, Knijn N, Verheij M, Nagtegaal ID, van der Post RS. Tumour deposits are a significant prognostic factor in gastric cancer - a systematic review and meta-analysis. *Histopathology* 2019;**74**(6): 809-816.
9. Kim Y, Squires MH, Poultsides GA, Fields RC, Weber SM, Votanopoulos KI, Kooby DA, Worhunsky DJ, Jin LX, Hawkins WG, Acher AW, Cho CS, Saunders N, Levine EA, Schmidt CR, Maithel SK, Pawlik TM. Impact of lymph node ratio in selecting patients with resected gastric cancer for adjuvant therapy. *Surgery* 2017;**162**(2): 285-294.
10. Bannister LH BM, Collins P. Gray's anatomy. 38th edn. *London: Longman Group* 1995: 1754–1755.
11. Sun RJ, Tang L, Li XT, Li ZY, Sun YS. CT findings in diagnosis of gastric bare area invasion: potential prognostic factors for proximal gastric carcinoma. *Japanese journal of radiology* 2019;**37**(7): 518-525.
12. Japanese Gastric Cancer A. Japanese gastric cancer treatment guidelines 2010 (ver. 3). *Gastric cancer : official journal of the International Gastric Cancer Association and the Japanese Gastric Cancer Association* 2011;**14**(2): 113-123.
13. Japanese Gastric Cancer A. Japanese classification of gastric carcinoma: 3rd English edition. *Gastric cancer : official journal of the International Gastric Cancer Association and the Japanese Gastric Cancer Association* 2011;**14**(2): 101-112.
14. Gabriel WB DC, Bussey HJR. Lymphatic spread in cancer of the rectum. *The British journal of surgery* 1935;**23**: 395-413.
15. Kim JH, Park SS, Park SH, Kim SJ, Mok YJ, Kim CS, Lee JH, Kim YS. Clinical significance of immunohistochemically-identified lymphatic and/or blood vessel tumor invasion in gastric cancer. *The Journal of surgical research* 2010;**162**(2): 177-183.
16. Gresta LT, Rodrigues-Junior IA, de Castro LP, Cassali GD, Cabral MM. Assessment of vascular invasion in gastric cancer: a comparative study. *World journal of gastroenterology* 2013;**19**(24): 3761-3769.
17. Puppa G, Ueno H, Kayahara M, Capelli P, Canzonieri V, Colombari R, Maisonneuve P, Pelosi G. Tumor deposits are encountered in advanced colorectal cancer and other adenocarcinomas: an expanded classification with implications for colorectal cancer staging system including a unifying concept of in-transit metastases. *Modern pathology : an official journal of the United States and Canadian Academy of Pathology, Inc* 2009;**22**(3): 410-415.
18. Sun Z, Wang ZN, Xu YY, Zhu GL, Huang BJ, Xu Y, Liu FN, Zhu Z, Xu HM. Prognostic significance of tumor deposits in gastric cancer patients who underwent radical surgery. *Surgery* 2012;**151**(6): 871-881.
19. Brierley JD GM, Wittekind C, Amin MB. TNM classification of malignant tumours. 8th ed. *Oxford: Wiley Blackwell* 2017.
20. Anup S, Lu J, Zheng CH, Li P, Xie JW, Wang JB, Lin JX, Chen QY, Cao LL, Lin M, Yu Q, Yang YH, Huang CM. Prognostic significance of perigastric tumor deposits in patients with primary gastric cancer. *BMC surgery* 2017;**17**(1): 84.
21. Sun Z, Wang ZN, Xu YY, Zhu GL, Huang BJ, Xu Y, Liu FN, Zhu Z, Xu HM. Prognostic significance of tumor deposits in gastric cancer patients who underwent radical surgery. *Surgery* 2012;**151**(6): 871-881.
22. Wu B, Min PQ, Yang K. Utility of multidetector CT in the diagnosis of gastric bare area invasion by proximal gastric carcinoma. *Abdominal imaging* 2007;**32**(3): 284-289.

23. Chatzicostas C, Roussomoustakaki M, Vardas E, Romanos J, Kouroumalis EA. Balthazar computed tomography severity index is superior to Ranson criteria and APACHE II and III scoring systems in predicting acute pancreatitis outcome. *Journal of clinical gastroenterology* 2003;**36**(3): 253-260.
24. Garcea G, Jackson B, Pattenden CJ, Sutton CD, Neal CP, Dennison AR, Berry DP. Early warning scores predict outcome in acute pancreatitis. *Journal of gastrointestinal surgery : official journal of the Society for Surgery of the Alimentary Tract* 2006;**10**(7): 1008-1015.
25. Mortele KJ, Mergo PJ, Taylor HM, Wiesner W, Cantisani V, Ernst MD, Kalantari BN, Ros PR. Peripancreatic vascular abnormalities complicating acute pancreatitis: contrast-enhanced helical CT findings. *European journal of radiology* 2004;**52**(1): 67-72.
26. Ishikawa K, Idoguchi K, Tanaka H, Tohma Y, Ukai I, Watanabe H, Matsuoka T, Yokota J, Sugimoto T. Classification of acute pancreatitis based on retroperitoneal extension: application of the concept of interfascial planes. *European journal of radiology* 2006;**60**(3): 445-452.
27. De Waele JJ, Delrue L, Hoste EA, De Vos M, Duyck P, Colardyn FA. Extrapancreatic inflammation on abdominal computed tomography as an early predictor of disease severity in acute pancreatitis: evaluation of a new scoring system. *Pancreas* 2007;**34**(2): 185-190.
28. Korobkin M, Silverman PM, Quint LE, Francis IR. CT of the extraperitoneal space: normal anatomy and fluid collections. *AJR American journal of roentgenology* 1992;**159**(5): 933-942.
29. O'Connell AM, Duddy L, Lee C, Lee MJ. CT of pelvic extraperitoneal spaces: an anatomical study in cadavers. *Clinical radiology* 2007;**62**(5): 432-438.
30. Mindell HJ, Mastromatteo JF, Dickey KW, Sturtevant NV, Shuman WP, Oliver CL, Leister KL, Barth RA. Anatomic communications between the three retroperitoneal spaces: determination by CT-guided injections of contrast material in cadavers. *AJR American journal of roentgenology* 1995;**164**(5): 1173-1178.
31. Thornton FJ, Kandiah SS, Monkhouse WS, Lee MJ. Helical CT evaluation of the perirenal space and its boundaries: a cadaveric study. *Radiology* 2001;**218**(3): 659-663.
32. Nieman KM, Romero IL, Van Houten B, Lengyel E. Adipose tissue and adipocytes support tumorigenesis and metastasis. *Biochimica et biophysica acta* 2013;**1831**(10): 1533-1541.
33. Wagner M, Dudley AC. A three-party alliance in solid tumors: Adipocytes, macrophages and vascular endothelial cells. *Adipocyte* 2013;**2**(2): 67-73.
34. Wang YY, Lehuede C, Laurent V, Dirat B, Dauvillier S, Bochet L, Le Gonidec S, Escourrou G, Valet P, Muller C. Adipose tissue and breast epithelial cells: a dangerous dynamic duo in breast cancer. *Cancer letters* 2012;**324**(2): 142-151.

Figures

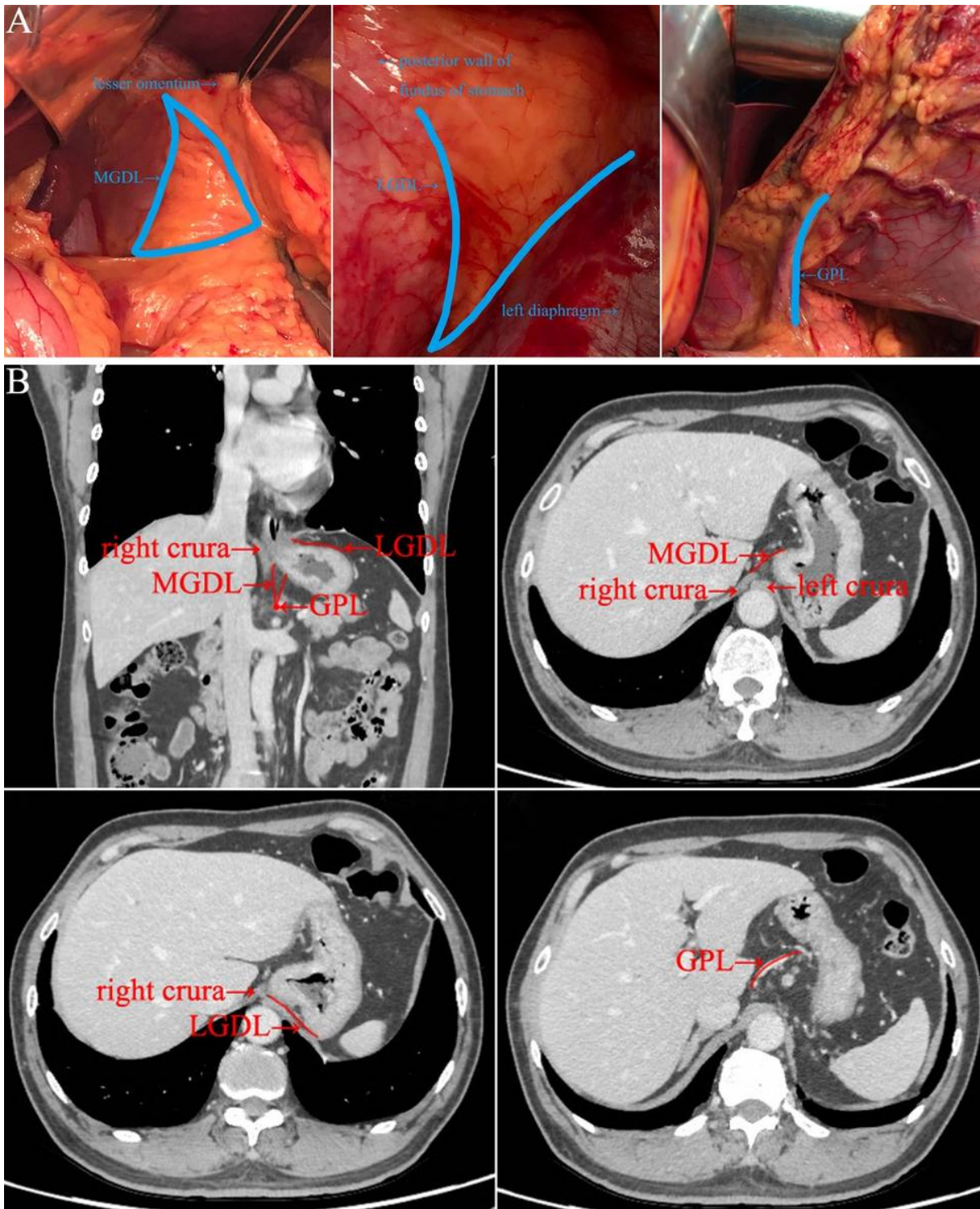


Figure 1

A: Illustration of MGDL, LGDL and GPL in living body during operation. B: Illustration of MGDL, LGDL and GPL in imaging of computer tomography.

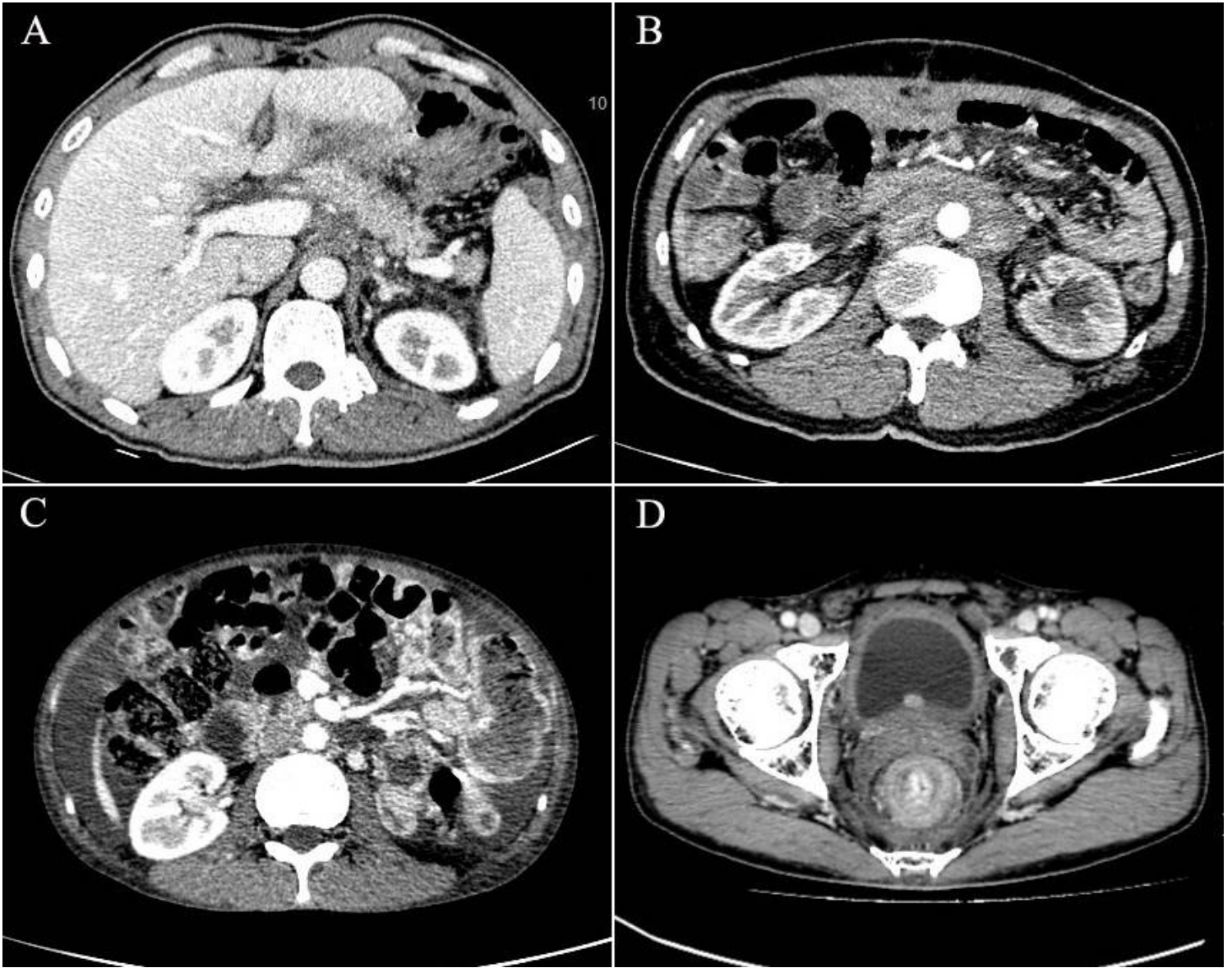


Figure 2

A. posterior-pancreas infiltration, B. para-aortic infiltration, C. mesenterium roots thickening, D. thickening of the rectal lining.

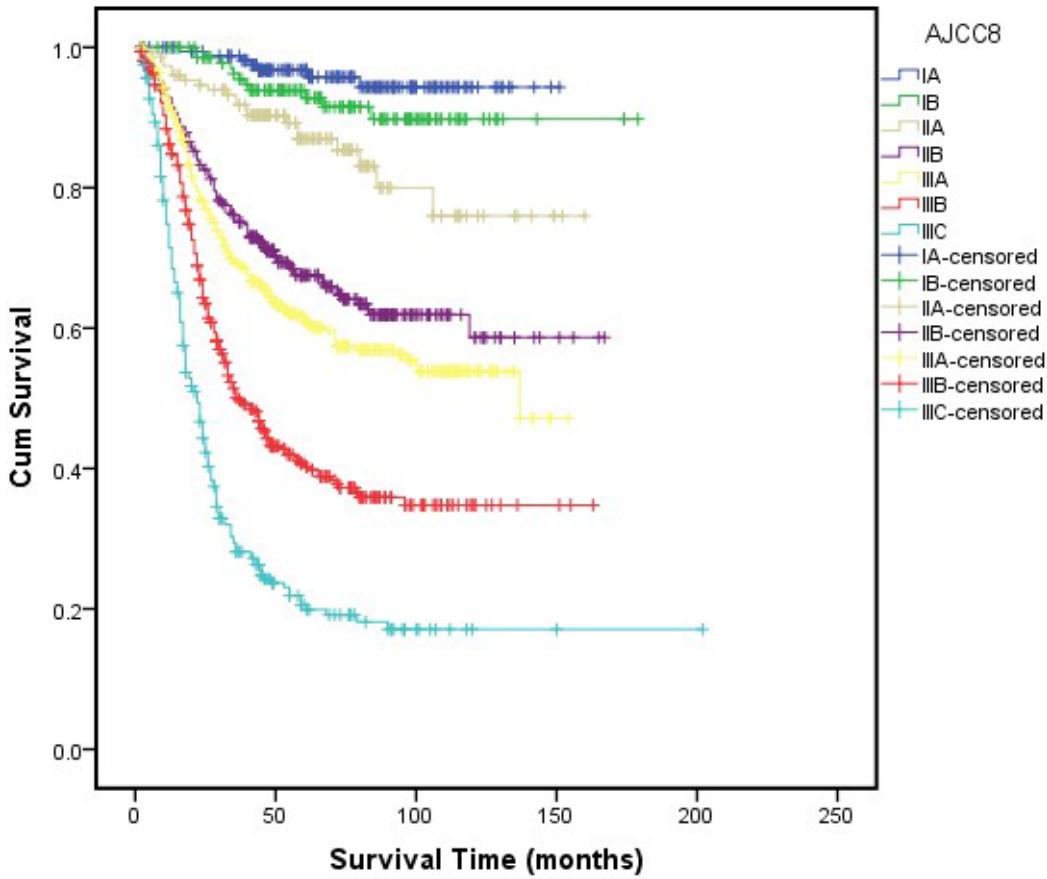


Figure 3

The 5-year survival analysis for all the stages according to the AJCC 8th edition staging system.

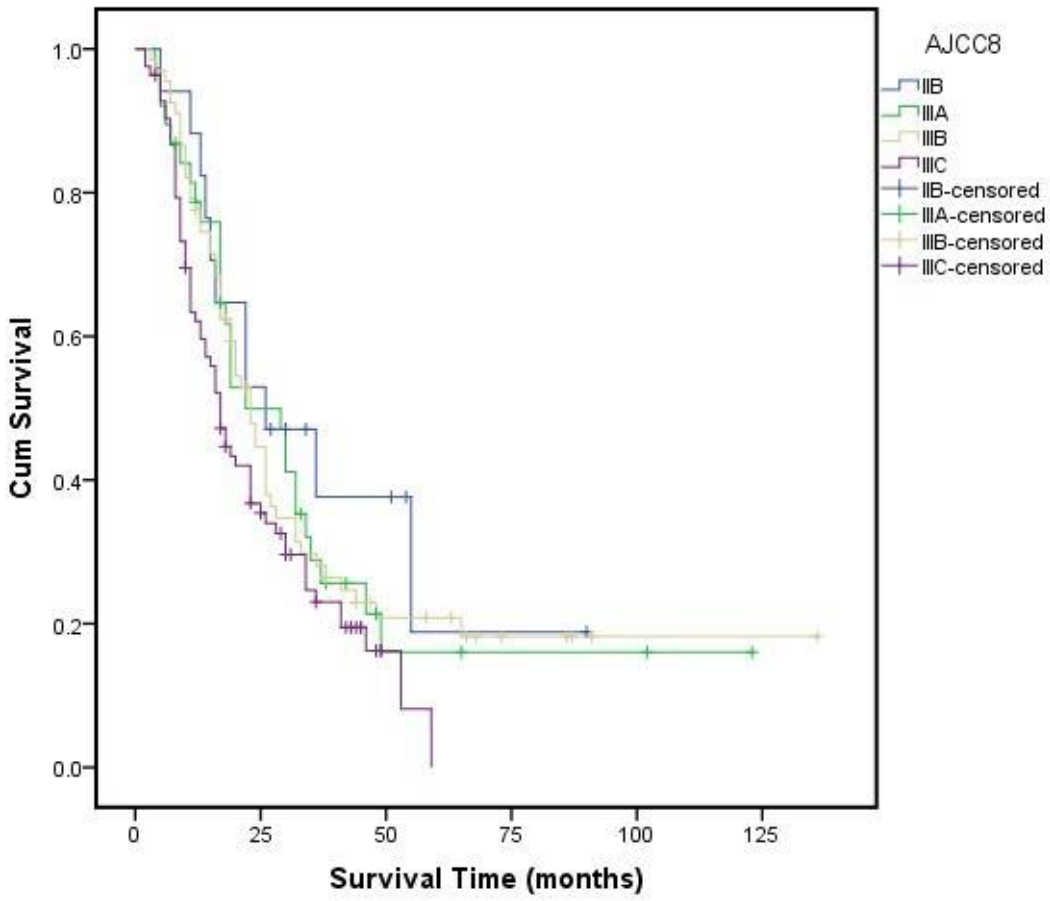


Figure 4

The 5-year survival analysis for GBAI cases.

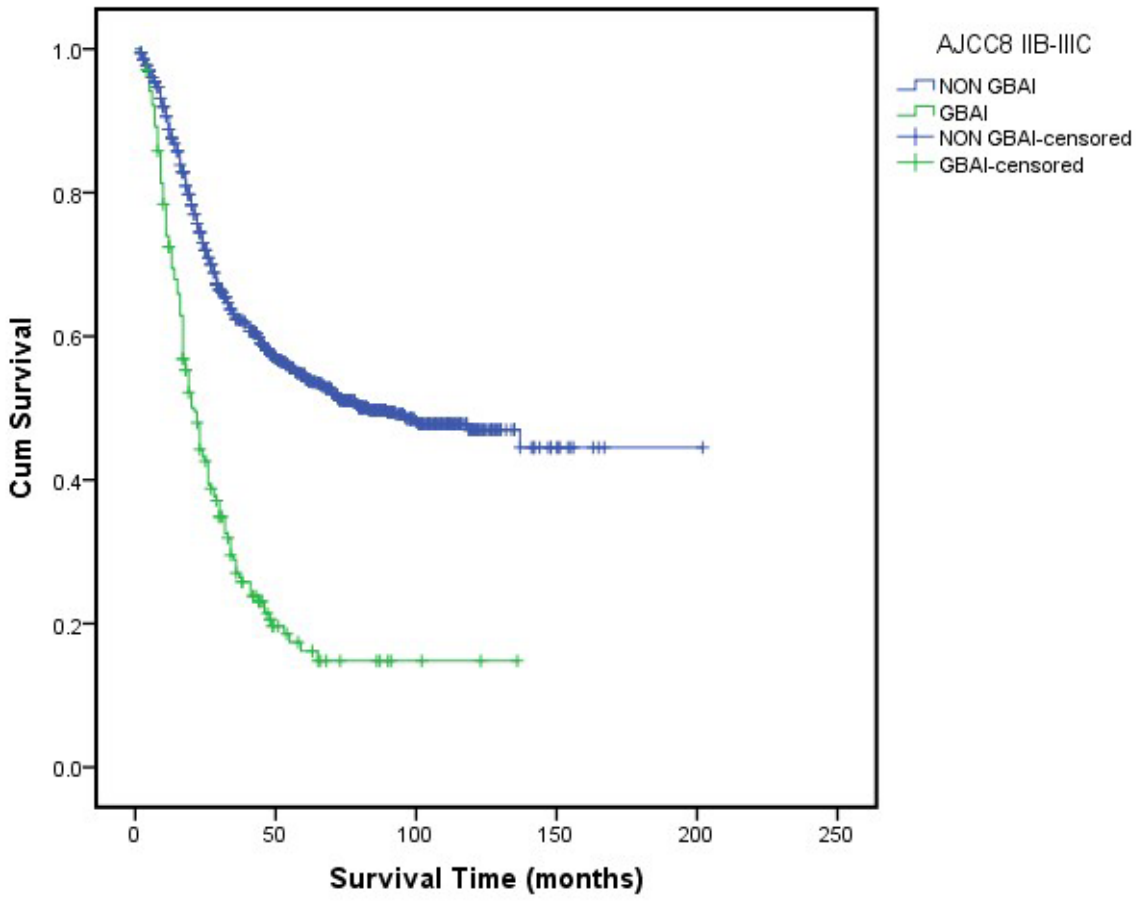


Figure 5

The 5-year survival analysis for GBAI cases and non-GBAI cases in stages IIB, IIIA, IIIB and IIIC.

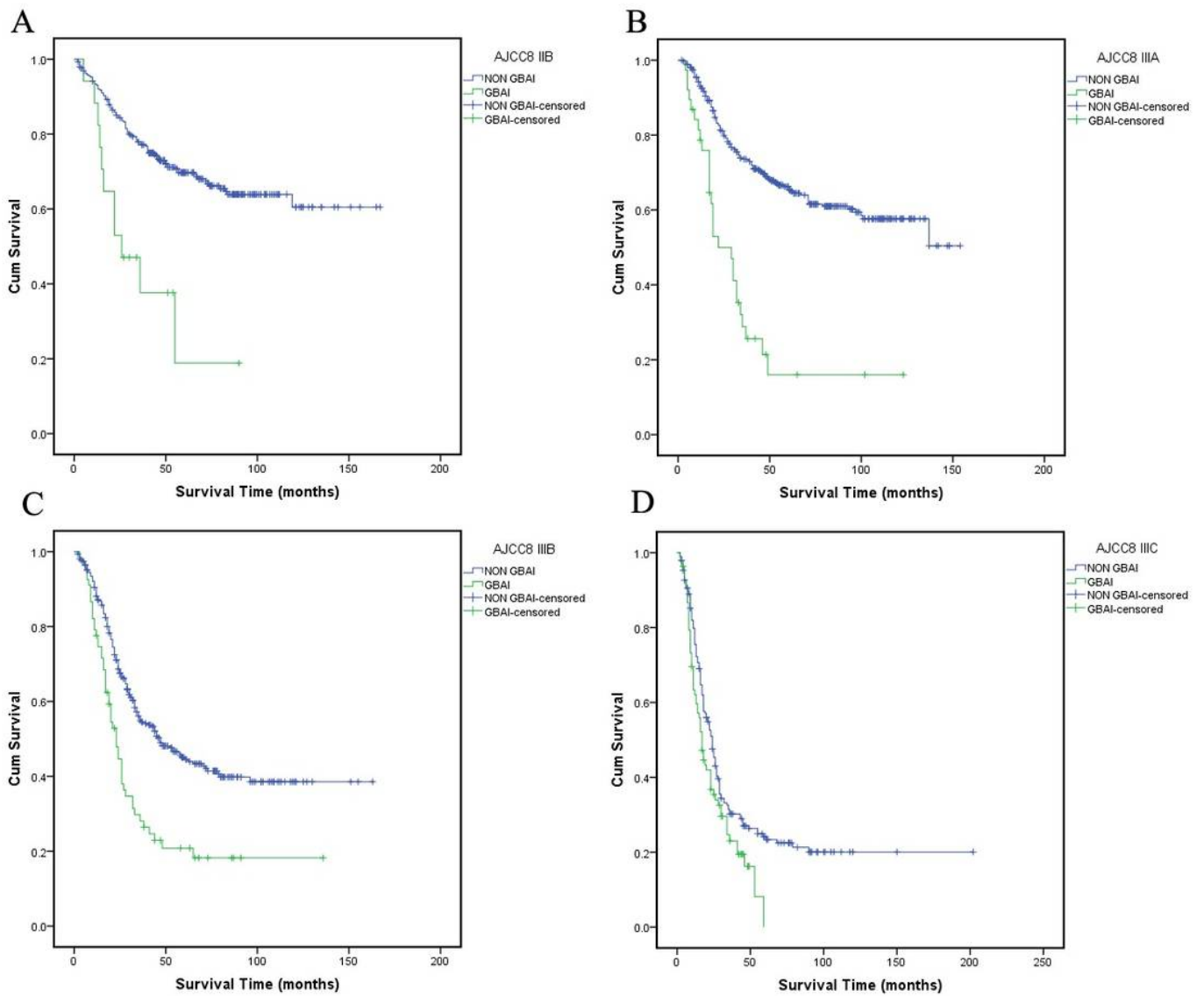


Figure 6

The 5-year survival analysis for patients with GBAI or not in stages IIB, IIIA, IIIB, IIIC, respectively.

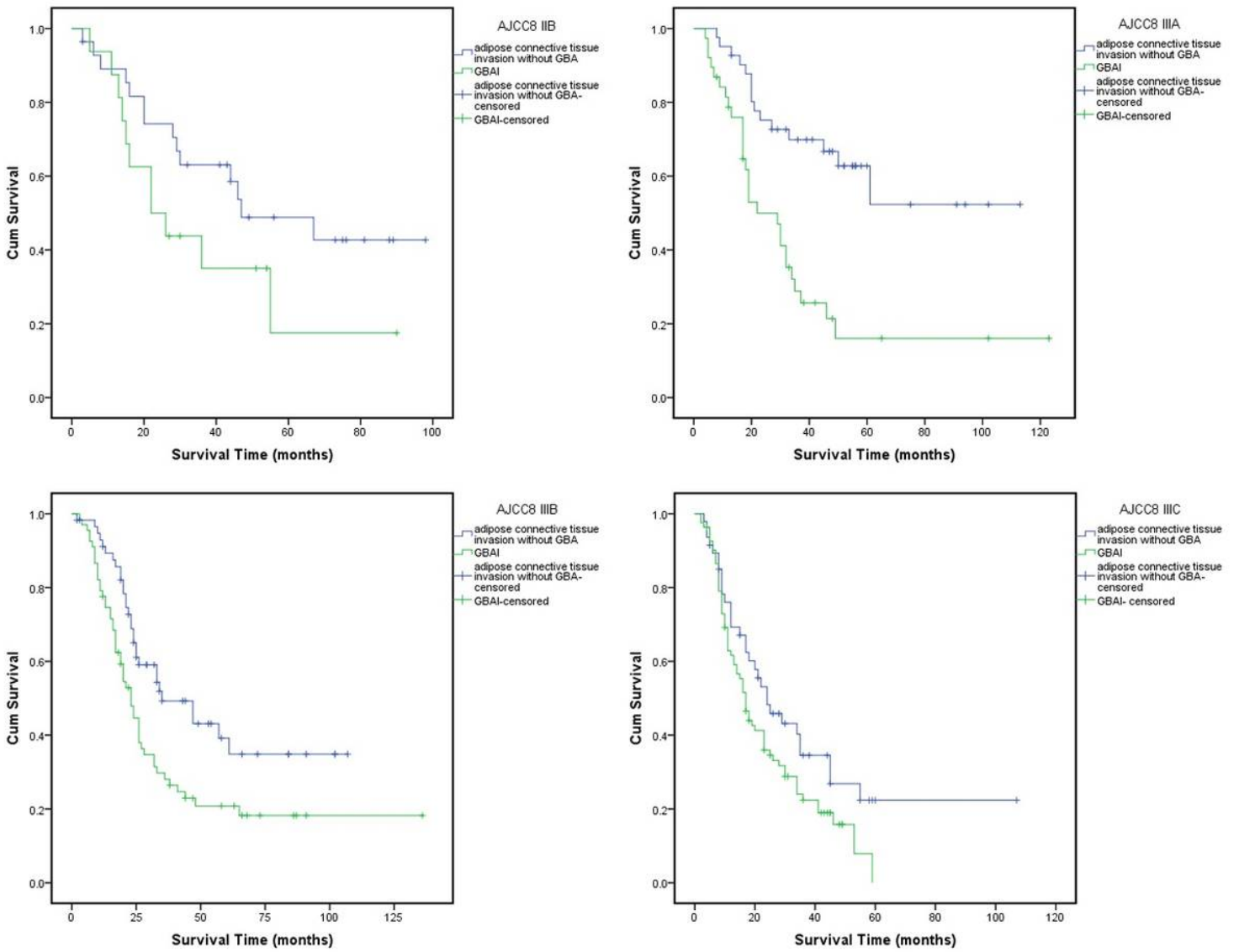


Figure 7

The 5-year survival analysis for patients with GBAI or adipose tissues invasion outside GBA in stages IIB, IIIA, IIIB, IIIC, respectively.