

Prenatal Diagnosis of Corpus Callosum Agenesis in Four Fetuses

Jiao Zheng

Xijing Hospital

Tingting Song

Xijing Hospital

Jia Li

Xijing Hospital

Ying Xu

Xijing Hospital

Pengfei Liu

Xi'an Tangdu Hospital of No4 Military Medical University

Jianfang Zhang

Xijing Hospital

Yang Hong (✉ yanghongfck@163.com)


Xijing Hospital <https://orcid.org/0000-0002-6017-5350>

Case Report

Keywords: corpus callosum agenesis, prenatal diagnosis, chromosomal microarray analysis, Chromosomal microdeletions and microduplications, genetic

Posted Date: September 1st, 2020

DOI: <https://doi.org/10.21203/rs.3.rs-51748/v1>

License:  This work is licensed under a Creative Commons Attribution 4.0 International License. [Read Full License](#)

Abstract

Background: The corpus callosum is the main pathway connect the interhemispheric communication. Corpus callosum agenesis from asymptomatic to mild or severe neurodevelopmental disorders. However, few cases have been previously reported in the literature on prenatal diagnosis between corpus callosum agenesis and chromosomes abnormality. The study included prenatal diagnosis of 4 fetuses in whom prenatal ultrasound showed corpus callosum abnormality, isolated or associated with other central nervous lesions.

Case presentation: Prenatal diagnoses of four children were summarized in our case. The routine prenatal ultrasound examination showed abnormal morphology of corpus callosum in fetus 1, dysplasia of the corpus callosum in fetus 3, the corpus callosum absence in fetus 2 and fetus 4, and fetus 4 also had cardiac abnormalities. Chromosomal microarray and G-band karyotype analysis were performed to provide genetic analysis of amniotic fluid. The results revealed 4.8M deletion at 1p36.33p36.31 in fetus 1, 3.1M deletion at Xq26.3q27.1 in fetus 2, 6.5M deletion at distal 1q43q44 and a duplication of 8.8M at 7q36.1q36.3 in fetus 3, fetus 4 had a deletion of 9.51M at 1p36.33p36.22 and 14.3M duplication at 6q25.3q27.

Conclusion: The genetic mechanism of corpus callosum agenesis is variably complex, and its clinical phenotype may occur either alone or in association with other abnormalities. This study revealed the microabnormalities of multiple chromosomes are related to the corpus callosum abnormality. Combined with ultrasound examination, the application of chromosome microarray analysis will effectively improve the diagnosis of congenital submicroscopic chromosomal abnormalities in fetuses.

Introduction

Genesis of corpus callosum agenesis (CCA) is complicated, which is related to many factors of heredity, infection, poisoning and environment. Anomalies in this structure of the brain have been associated with characteristics of certain neurodevelopmental disorders and impairments in child development[1]. About 20% of CCA are due to single or multiple genes mutations or chromosomal aberrations[2–4]. Numerous cases are apparently sporadic, and autosomal dominant, autosomal recessive, X-linked causes and monogenic of CCA have been described[5, 6]. In recent years, the application of chromosome microarray analysis (CMA), genetic variations associated with CCA has been detected progressively.

CCA occurs partially or totally either in isolation, or together with other cerebral malformations[7]. It has been reported that an insufficient haploinsufficiency of ZNF462, a zinc finger protein, is associated with corpus callosum dysgenesis, who also have overlapping phenotypes that include ptosis, metopic ridging, craniosynostosis, and developmental delay[8]. A deleterious homozygous mutation in CDK10 is associated with agenesis of corpus callosum, growth retardation, global developmental delay with absent speech acquisition, sensorineural deafness, retinitis pigmentosa, vertebral anomalies, patent ductus arteriole, and facial dysmorphism[9]. It's reported that de novo mutations in MAST1 cause MCC-CH-CM, a disease characterized by a striking enlargement of the corpus callosum, cerebellar hypoplasia, and cortical malformations[10]. As far as agenesis of corpus callosum genetic etiology is concerned, more than 200 different congenital syndromes have been described so far, often associated with specific chromosomal rearrangements[11–13].

To provide a better understanding of the chromosomal variation and the corpus callosum agenesis in prenatal diagnosis, we present our study on prenatal diagnosis of four corpus callosum structural abnormal fetuses by CMA.

Case Presentation

Case 1 was a 33-year-old gravida 2 para 1 abortion 0 (G2P1A0) pregnant woman, denied history of adverse pregnancy, adverse contact, family history of genetic history and inbreeding. At 22+5 week of this pregnancy, Obstetric sonography showed the posterior horn of the left lateral cerebral ventricle was 8mm wide, the anterior horn was 6mm, and the morphologically abnormal septum width was 7mm. The shape of the corpus callosum was abnormal slender. After genetic counseling, amniocentesis was performed at 23 weeks of gestation.

Case 2 was a 31 years old gravida 2 para 1 abortion 1 (G2P1A1) woman had an adverse history of induced labor in a fetus with a missing corpus callosum. B ultrasound at 24+2 weeks of this pregnancy showed the fetal lateral ventricle was 11mm wider, no transparent septum was detected, loss of corpus callosum and strong echo of the left ventricle were considered. Subsequently, MR examination showed absence of corpus callosum and bilateral lateral posterior ventricle horn widened to 15mm. After genetic counseling, amniotic fluid sample was obtained at 31 weeks of gestation.

Case 3 was a 30 years old gravida 2 para 1 abortion 0 (G2P1A0) pregnant woman with a history of adverse pregnancy had given birth to a boy with a corpus callosum dysplasia and the genetic analysis revealed a microdeletion of chromosome 1q43q44 and microduplication of chromosome 7q36. B ultrasound results showed that most of the corpus callosum was not shown, only the knee of the corpus callosum seemed to see arc-shaped signal shadow, lateral ventricle morphological changes, considering the dysplasia of the corpus callosum at this pregnancy. Amniocentesis was performed in our hospital at the 31st week of pregnancy.

Case 4 was a 40 years old G6P1A4 pregnant woman, who has a healthy child with her ex-husband, got pregnant 5 times after remarriage. Three embryos were aborted, and another fetus induced labor due to tetralogy of fallot. No family history, no history of adverse exposure, bleeding in the early stages of this pregnancy, progesterone to protect the fetus. At the 23rd week of this pregnancy, B-ultrasonography showed the absence of corpus callosum and bilateral lateral ventricles widened like "horns", with 10.5mm on the left and 12.4mm on the right. Hydramnios; Cardiac ultrasound during pregnancy of 27w+6d showed abnormal venous catheter spectrum: a wave was low and reached baseline; Congenital heart disease: severe tricuspid insufficiency with mild stenosis. During pregnancy of 30+1w, cephalic nuclear magnetic resonance showed irregular morphology of bilateral lateral ventricles, and high signal image of left lateral ventricle small cyst, then an amniocentesis was performed.

Clinical data of four fetuses are listed in Table 1.

Materials And Methods

G-banding karyotype was performed on cultured amniotic fluid cells samples after informed consent. Karyotype analysis using GTG-banding was performed following standard procedures and nomenclature was used according to the ISCN 2016[14].

Genomic DNA from amniotic fluid (10 ml) was extracted using a QIAamp DNA Blood Mini Kit (Qiagen, Venlo, The Netherlands). Analysis of the concentration and quality of genomic DNA was performed using a Nanodrop 2000 (Thermo Fisher Scientific, Waltham, MA, USA). An Affymetrix Cytoscan 750 k array (Affymetrix, Santa Clara, CA, USA) was utilized according to the manufacturer's protocol. Data analysis was carried out using Chromosome Analysis Suite (ChAS) software (v3.1, r8004). To analyze the data and interpret the results, the following public databases were utilized: UCSC, DECIPHER, DGV, OMIM, ISCA, and PubMed[15, 16].

Discussion And Conclusions

In this study, we report four prenatal cases of chromosomal with corpus callosum agenesis. The results of CMA revealed two deletions of 4.8M at 1p36.33p36.31 and 3.1M at Xq26.3q27.1 in Fetus 1 and Fetus 2, a inherited deletions of 6.5M at 1q43q44 and duplication of 8.8M at 7q36.1q36.3 in Fetus 3, a paternal 9.52M deletions at 1p36.33p36.22 and 14.3M duplication at 6q25.3q27 in Fetus 4. To our knowledge, Fetus 3 and Fetus 4 results are both due to the unbalanced translocation of parental inheritance resulting in the formation of derived karyotypes 46, XX, der(1) t(1;7) (q43;q36.1) and 46, XY, der(1) t(1;6) (p36.22;q25.3) (Fig. 1;Fig. 2).

Deletion of about 4.8 M in chromosome 1 1p36.33p36.31 region in Fetus 1, which contains 44 OMIM genes such as PRKCZ, SKI, GNB1, and Clinvar, Decipher, OMIM and other databases have been reports cases of disease in this region. The clinical manifestations of patients with missing regions are not completely consistent, and may have clinical manifestations such as brain dysplasia, stunting, hypotonia, epilepsy, congenital heart disease, and hearing disorders[17, 18]. The X chromosome Xq26.3q27.1 region of fetus 2 has a deletion of about 3.1 M, the deletion region contains five OMIM genes: ZIC3, FGF13, F9, MCF2, and ATP11C. The mutation of ZIC3 gene is related to the visceral inversion, the FGF13 gene is in the nerve, which plays a critical role in the phylogenetic process, and the F9 gene mutations are associated with hemophilia. However, the absence of this region is rarely reported, and its clinical significance is not completely clear[19]. The CMA results of Fetus 3 showed there were 8.8M duplication in the 7q36.1q36.3, which contains 51 OMIM genes including SHH, LMBR1, RBM33, etc. The patients with duplication in this area can be pathogenic, including intellectual disability, growth retardation, dysplasia of corpus callosum, special facial features, congenital heart disease and other clinical manifestations[20]. It also have about 6.5M deletions of chromosome 1 q43q44 region contains 21 OMIM genes including AKT3, HNRNPU, ZBTB18, etc in Fetus, which is pathogenic, there may be intellectual disability, microcephaly, epilepsy, craniofacial abnormalities and other clinical manifestations[21]. In Fetus 4, who has a 1p36 deletion syndrome that has a 9.52 Mb deletion at the 1p36.33p36.22. Patients with loss of this region may have clinical manifestations such as abnormal brain development, developmental delay, hypotonia, epilepsy, congenital heart disease, and abnormal hearing[17, 18], and there is also about 14.3 Mb duplication in region 6q25.3q27, and patients with duplication in this region may have clinical manifestations such as stunted growth, low intelligence and intellectual disability[22–24].

Numerous studies have described hypoplasia of the corpus callosum patients. Notably, the reported case did not completely reveal genes and chromosomes based corpus callosum abnormalities. Agenesis of the corpus callosum is frequently associated with other hereditary syndrome, at the same time, it is often accompanied by other abnormal phenotypes. It reported that genomic aberration at chromosome 16p13.11 involves in the formation polydactyly, bilateral ventriculomegaly and corpus callosum agenesis[25]. Ratna Tripathy et al.(2018) reported that de novo mutations in MAST1 cause mega-corpus-callosum syndrome with cerebellar hypoplasia and cortical malformations, a disease characterized by a striking enlargement of the corpus callosum, cerebellar hypoplasia, and cortical malformations[10]. Suresh Chandran et al described two cases of agenesis of the corpus callosum with interhemispheric cyst[7]. In our study, in addition to the corpus callosum agenesis, the fetal 4 had also venous catheter spectrum abnormalities, cardiac abnormalities with severe tricuspid insufficiency and mild stenosis, compared with dysplasia of white matter.

In this report, after comprehensive genetic counseling, the couples of Fetus 2, Fetus 3 and Fetus 4 ultimately chose to put an end to the pregnancies. Fetus 1 was given by cesarean section due to polyhydramnios in late pregnancy and hypoxia at birth. Postnatal MRI showed patchy long T long T2 signal shadows in bilateral parietal ventricles, and FLAIR sequence lesions with low signal on the left, considering softening lesions or vascular space enlargement; Echocardiography suggested patent ductus arteriosus and patent foramen ovale. The child was born with developmental delay, epilepsy, low muscle tone, poor hearing, poor health, susceptible to colds and fever, and died after several hospitalizations.

Most patients with corpus callosum agenesis have intellectual disability, epilepsy, Asperger's syndrome, learning problems, depression, schizophrenia, delusional disorder, conduct disorder, conversion symptoms and other clinical symptoms from asymptomatic forms to mild or severe neurodevelopment disorders, and also syndromic agenesis of corpus callosum plus patients showed the most severe clinical features while isolated complete agenesis of corpus callosum patients had the mildest symptoms[13, 26]. Although corpus callosum dysplasia is a relatively rare brain malformation, due to its high non-specificity, the corpus callosum dysplasia is the result of multiple factors and genes interacting. And on the other hand, its clinical manifestations are equally unpredictable and very complicated. This makes prenatal genetic counselling more challenging. Therefore, pregnant women should be provided with detailed information on the range of possible phenotypic outcomes of the syndrome during prenatal genetic counseling.

In summary, we reported the prenatal diagnosis of chromosomal microdeletion and microduplication syndrome by CMA testing in four fetuses with agenesis of corpus callosum. CMA should be an active participant in prenatal diagnostic testing after a positive finding of fetal ultrasound anomaly. The results of this study can provide a clinical basis for prenatal diagnostic and genetic counseling of corpus callosum dysplasia.

Declarations

Ethics approval and consent to participate

The research was approved by the ethics committee at Xijing Hospital of the Fourth Military Medical University and informed consent was obtained from the parents for invasive prenatal diagnosis.

Consent for publication

Informed written consent was obtained from parents for publication for images and other clinical information relating to this case to be reported for academic purpose.

Availability of data and materials

The datasets used and/or analysed during the current study are available from the corresponding author on reasonable request.

Competing interests

The authors declare that they have no competing interest.

Funding

This work was supported by National Key Research and Development Program of China (Grant No. 2016YFC1000701), Key Research and Development Program of Shaanxi (2019ZDLSF01-06) and scientific and technological projects for social development of Shaanxi Province (2016SF-254), University Joint Project-General Project of Shaanxi Province (2020GXLH-Y-009).

Authors' contributions

JZ summarized data and wrote the paper. TS carried out the molecular genetic studies. JZ, HY and PL helped to draft the manuscript. JZ and JL conducted the genetic counseling. YX carried out the laboratory work. All authors read and approved the final manuscript.

Acknowledgements

We would like to thank the pregnant women and their family members who contributed in this study.

References

1. Dupont C, Castellanos-Ryan N, Seguin JR, et al. The Predictive Value of Head Circumference Growth during the First Year of Life on Early Child Traits. *Sci Rep*. 2018;8(1):9828.
2. Paul LK, Brown WS, Adolphs R, et al. Agenesis of the corpus callosum: genetic, developmental and functional aspects of connectivity. *Nat Rev Neurosci*. 2007;8(4):287–99.
3. Edwards TJ, Sherr EH, Barkovich AJ, Richards LJ. Clinical, genetic and imaging findings identify new causes for corpus callosum development syndromes. *Brain*. 2014;137(Pt 6):1579–613.
4. Margari L, Palumbi R, Campa MG, et al. Clinical manifestations in children and adolescents with corpus callosum abnormalities. *J Neurol*. 2016;263(10):1939–45.
5. Yao G, Chen XN, Flores-Sarnat L, et al. Deletion of chromosome 21 disturbs human brain morphogenesis. *Genet Med*. 2006;8(1):1–7.
6. Graham JM Jr, Superneau D, Rogers RC, et al. Clinical and behavioral characteristics in FG syndrome. *Am J Med Genet*. 1999;85(5):470–5.
7. Revanna KG, Rajadurai VS, Chandran S. Agenesis of the corpus callosum with interhemispheric cyst: clinical implications and outcome. *BMJ Case Rep*, 2018, 11(1).
8. Weiss K, Wigby K, Fannemel M, et al. Haploinsufficiency of ZNF462 is associated with craniofacial anomalies, corpus callosum dysgenesis, ptosis, and developmental delay. *Eur J Hum Genet*. 2017;25(8):946–51.
9. Guen VJ, Edvardson S, Fraenkel ND, et al. A homozygous deleterious CDK10 mutation in a patient with agenesis of corpus callosum, retinopathy, and deafness. *Am J Med Genet A*. 2018;176(1):92–8.
10. Tripathy R, Leca I, van Dijk T, et al. Mutations in MAST1 Cause Mega-Corpus-Callosum Syndrome with Cerebellar Hypoplasia and Cortical Malformations. *Neuron*. 2018;100(6):1354–68 e1355.
11. O'Driscoll MC, Black GC, Clayton-Smith J, Sherr EH, Dobyns WB. Identification of genomic loci contributing to agenesis of the corpus callosum. *Am J Med Genet A*. 2010;152A(9):2145–59.
12. Palmer EE, Mowat D. Agenesis of the corpus callosum: a clinical approach to diagnosis. *Am J Med Genet C Semin Med Genet*. 2014;166C(2):184–97.
13. Romaniello R, Marelli S, Giorda R, et al. Clinical Characterization, Genetics, and Long-Term Follow-up of a Large Cohort of Patients With Agenesis of the Corpus Callosum. *J Child Neurol*. 2017;32(1):60–71.
14. Stevens-Kroef M, Simons A, Rack K, Hastings RJ. Cytogenetic Nomenclature and Reporting. *Methods Mol Biol*. 2017;1541:303–9.
15. Wan S, Zheng Y, Dang Y, et al. Prenatal diagnosis of 17q12 microdeletion and microduplication syndrome in fetuses with congenital renal abnormalities. *Mol Cytogenet*. 2019;12:19.
16. Song T, Wan S, Li Y, et al. Detection of copy number variants using chromosomal microarray analysis for the prenatal diagnosis of congenital heart defects with normal karyotype. *J Clin Lab Anal*. 2019;33(1):e22630.

17. Shimada S, Shimojima K, Okamoto N, et al. Microarray analysis of 50 patients reveals the critical chromosomal regions responsible for 1p36 deletion syndrome-related complications. *Brain Dev.* 2015;37(5):515–26.
18. Rocha CF, Vasques RB, Santos SR, Paiva CL, Mini-Review. Monosomy 1p36 syndrome: reviewing the correlation between deletion sizes and phenotypes. *Genet Mol Res*, 2016, 15(1).
19. Martinez-Juarez A, Uribe-Figueroa L, Quintana-Palma M, Razo-Aguilera G, Sevilla-Montoya R. Pure trisomy 2p syndrome in two siblings with an unbalanced translocation and minimal terminal 12q monosomy characterized by high-density microarray. *Cytogenet Genome Res.* 2014;142(4):249–54.
20. Wong K, Moldrich R, Hunter M, et al. A familial 7q36.3 duplication associated with agenesis of the corpus callosum. *Am J Med Genet A.* 2015;167A(9):2201–8.
21. Depienne C, Nava C, Keren B, et al. Genetic and phenotypic dissection of 1q43q44 microdeletion syndrome and neurodevelopmental phenotypes associated with mutations in ZBTB18 and HNRNPU. *Hum Genet.* 2017;136(4):463–79.
22. Peddibhotla S, Nagamani SC, Erez A, et al. Delineation of candidate genes responsible for structural brain abnormalities in patients with terminal deletions of chromosome 6q27. *Eur J Hum Genet.* 2015;23(1):54–60.
23. Pace NP, Maggouta F, Twigden M, Borg I. Molecular cytogenetic characterisation of a novel de novo ring chromosome 6 involving a terminal 6p deletion and terminal 6q duplication in the different arms of the same chromosome. *Mol Cytogenet.* 2017;10:9.
24. Conti V, Carabalona A, Pallesi-Pocachard E, et al. Periventricular heterotopia in 6q terminal deletion syndrome: role of the C6orf70 gene. *Brain.* 2013;136(Pt 11):3378–94.
25. Sung PL, Chang CM, Chen CY, et al. Prenatal diagnosis of microdeletion 16p13.11 combination with partial monosomy of 2q37.1-qter and partial trisomy of 7p15.3-pter in a fetus with bilateral ventriculomegaly, agenesis of corpus callosum, and polydactyly. *Taiwan J Obstet Gynecol.* 2012;51(2):260–5.
26. Bhatia MS, Saha R, Doval N. Delusional Disorder in a Patient with Corpus Callosum Agenesis. *J Clin Diagn Res.* 2016;10(12):VD01–2.

Tables

TABLE 1. Summary of clinical data and genomic information on four fetuses.

	Fetus 1	Fetus 2	Fetus3	Fetus4
Gestational week	23+	26+	31+	30+
Age of mother	33	31	30	40
Gravida and para	G2P1	G2P0	G2P1	G6P1
Ultrasound manifestation	Widened transparent septum; slender corpus callosum; ependymal cyst	agenesis of the corpus callosum; widened lateral ventricle	agenesis of corpus callosum; Morphological changes of lateral ventricle	Congenital heart c corpus callosum
Karyotype	46XXdel(1)(p36)	46,XX	46XXder(1)t(1;7)(q43;q36.1)	46,XY,der(1)t(1;6)
Results of CMA	arr[hg19] 1p36.33p36.31(1,028,553-5,851,366)x1	arr[GRCh37] Xq26.3q27.1(136,388,326_139,518,268)x1	arr[GRCh37] 7q36.1q36.3(150,301,319_159,119,707)x3 arr[GRCh37] 1q43q44(242,702,622_249,224,684)x1;	arr[GRCh37] 1p36.33p36.22(8- arr[GRCh37] 6q25.3q27(156,60
Size(M)	4.8 Mb	3.1 Mb	6.5 Mb, 8.8 Mb	14.3 Mb, 9.51 Mb
Pregnancy outcome	Born, Die	odinopoeia	odinopoeia	odinopoeia

Figures

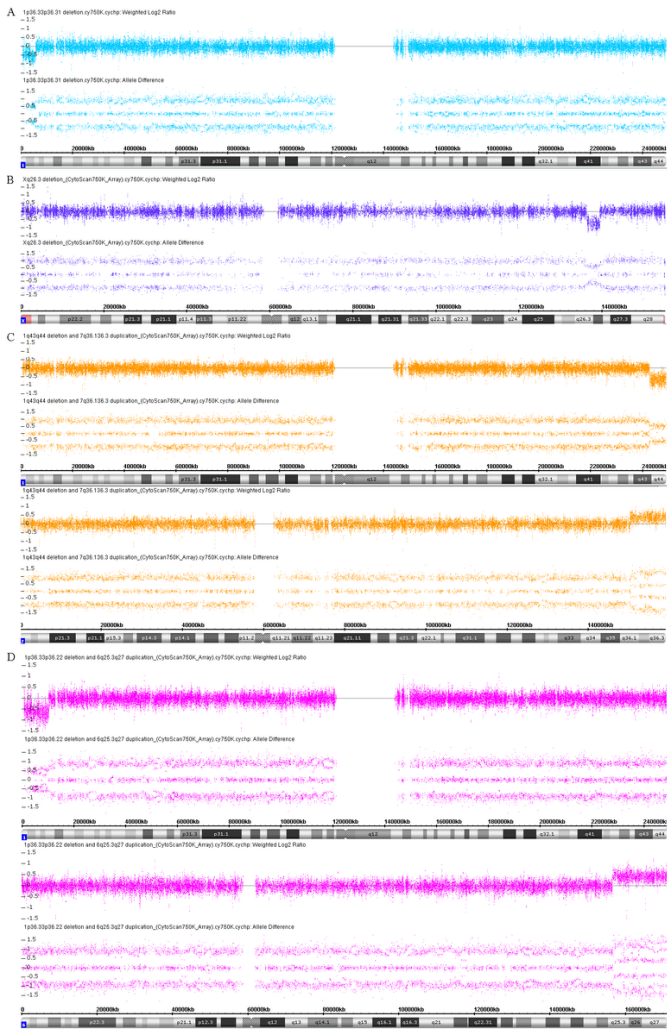


Figure 1
 Results of CMA in four fetuses with dysgenesis of the corpus callosum. (A) The result in fetus 1 showed the 1p36.33p36.31 region was deleted. (B) Fetus 2 has a deletion at Xq26.3q27.1 region. (C) The results indicated that there were a deletion at 1q43q44 and duplication at 7q36.1q36.3 in fetus 3. (D) The results in fetus 4 suggest a deletion at 1p36.33p36.22 and a duplication at 6q25.3q27.

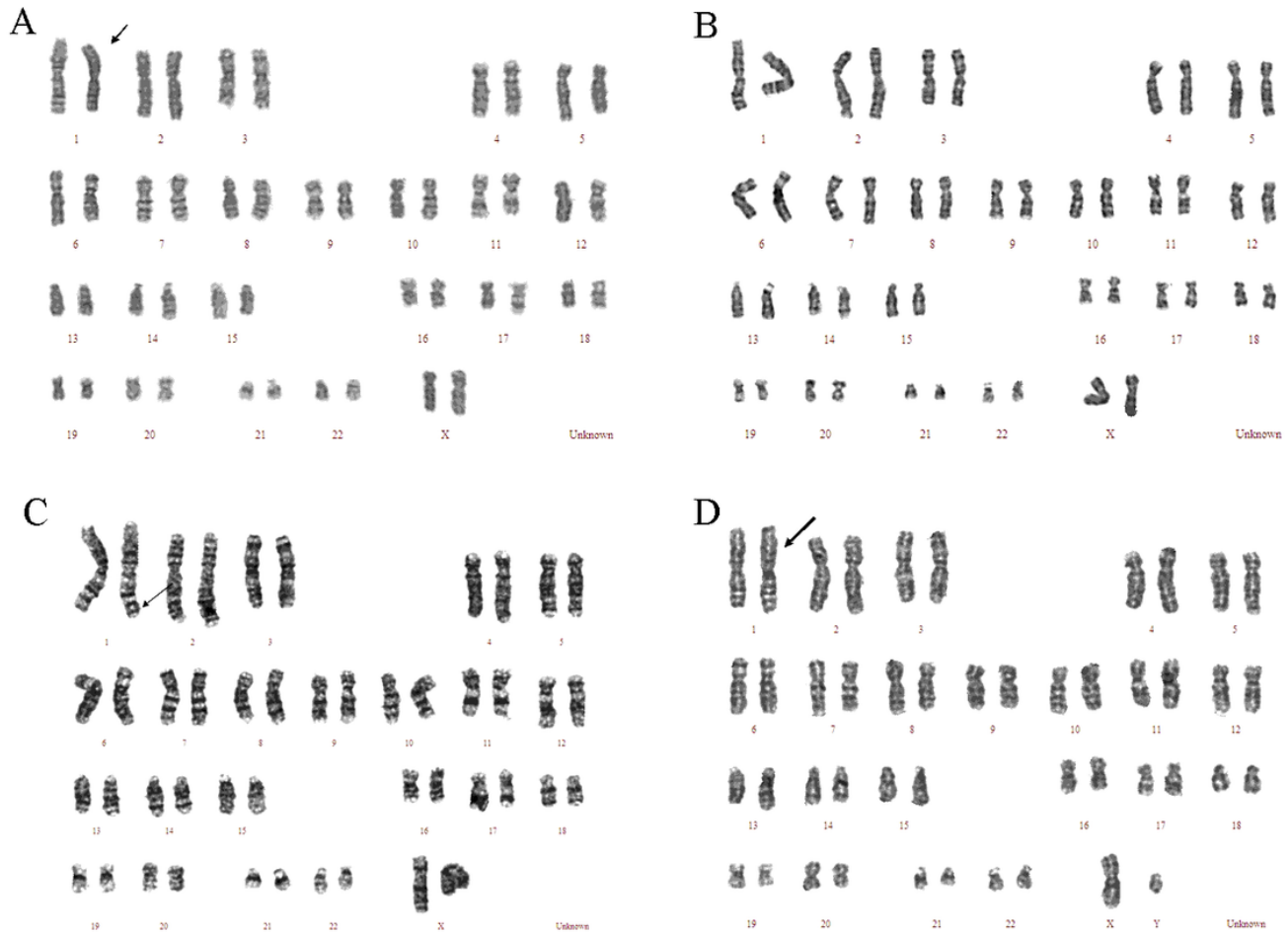


Figure 2

Fetal G-banded karyotypes. The arrows indicate the abnormal chromosome. (A) Karyotype of 46, XX, del(1)(p36) in Fetus 1. (B) The fetus 2 have a normal karyotype 46, XX. (C) The karyotype of fetus 3 is 46, XX, der(1)t(1;7)(q43;q36.1). (D) The karyotype of fetus 3 is 46, XY, der(1)t(1;6)(p36.22;q25.3).