Diagnostic Performance of Cortactin in the Diagnosis of Oral Squamous Cell Carcinoma

Lili Wang
Chinese PLA General Hospital
Hongguang Song
Beijing DCN Orthopaedic Hospital
Shiming Yang (sdf3vds@126.com)
Chinese PLA General Hospital https://orcid.org/0000-0002-1502-6532

Primary research

Keywords: Oral squamous cell carcinoma, Cortactin, Diagnosis

DOI: https://doi.org/10.21203/rs.3.rs-51195/v1

Abstract

Background: *Cortactin* gene was up-regulated in various human cancers. However, the role of *cortactin* in the diagnosis of oral squamous cell carcinoma (OSCC) remained unclear. The aim of this study was to investigate the diagnostic value of *cortactin* in OSCC patients.

Methods: The relative mRNA expression levels of *cortactin* in OSCC tissues and adjacent normal oral mucosal tissues were detected by quantitative real-time polymerase chain reaction (qRT-PCR). Chi-square test was used to analyze the correlation between *cortactin* expression and clinical characteristics of patients. The diagnostic value of *cortactin* in OSCC patients was estimated via receiver operating characteristic (ROC) curve analysis.

Results: Compared with the normal controls, *cortactin* mRNA expression was significantly increased in OSCC tissues (P<0.001). Importantly, notable correlations were found between *cortactin* expression and tumor size (P=0.040), TNM stage (P=0.018), lymph node metastasis (P=0.013) as well as recurrence (P=0.031). Furthermore, the result of ROC curve analysis showed that the area under the curve (AUC) was 0.867 with a sensitivity of 76.2% and a specificity of 86.9%. It revealed that the diagnostic value of *cortactin* was high in OSCC patients.

Conclusions: Our data reveal that *cortactin* expression is up-regulated in OSCC and correlated with tumor progression. *Cortactin* may be a potential bio-marker for early diagnosis of OSCC.

Background

Oral squamous cell carcinoma (OSCC), a most common form of head and neck cancer worldwide, is originated from oral mucosal epithelial cells [1]. The incidence rate of OSCC is high and it becomes a health problem of human [2]. The potential risk factors including alcohol consumption and smoking, are involved in the initiation and development of OSCC [3]. The survival rate of OSCC patients is still low because of high metastasis, unfavorable prognosis and frequent relapse [4]. Early and effect diagnosis may reduce the death rate of OSCC patients [5]. The screening procedures and therapeutic strategies of OSCC patients mainly relied on standard histological evaluation, which focuses on the phenotypic alterations of cells and tissues [6]. Therefore, finding novel bio-markers for the diagnosis and prognosis of OSCC is an urgent need and may improve the therapeutic effect.

Cortactin gene, locating on human chromosome 11q13, encodes a cortical actin-binding protein, which belongs to activators of Arp2/3 complex and filamentous actin-binding proteins [7]. Cortactin protein also plays crucial roles in various cellular processes, such as cell invasion, migration and axon guidance [8]. It revealed that increased expression of *cortactin* was related to the amplification of 11q13, which participated in the development and prognosis of cancers [9]. A growing body of evidences had demonstrated that the aberrant expression of *cortactin* was confirmed in a variety types of human tumors [10, 11]. In addition, knockdown of *cortactin* could inhibit tumor cell migration and invasion [12]. Recently, *cortactin* was found to be associated with the pathogenesis as well as progression, and served as a potential bio-marker for the prognosis of cancers [13]. Previous study had reported that protein expression level of cortactin was significantly higher in OSCC tissues than that in normal oral mucosal, and its over-expression could promote OSCC cell invasion [14]. However, the mRNA expression level and the diagnostic value of *cortactin* in OSCC remains poorly known.

In this study, we expected to detect the relative mRNA expression levels of *cortactin* in OSCC tissues and adjacent normal oral mucosal tissues, and analyze the correlation between *cortactin* expression and clinical characteristics of patients. We also estimated the diagnostic value of *cortactin* in OSCC patients.

Methods

Patients and samples

In this study, a total of 122 OSCC patients were enrolled from Chinese PLA General Hospital. Before this study, none patients had received any radio- or chemo-therapy treatment. This study was approved by the Ethical Committee of Chinese PLA General Hospital and the written informed consents were obtained from all patients.

OSCC tissues and adjacent normal oral mucosal tissues were collected from all patients by biopsy. These specimens were immediately frozen in liquid nitrogen and stored at -80℃ for use. The histopathological diagnosis of all tissue samples were confirmed by the pathologists with extensive experience. The detailed clinicopathologic characteristics of patients were listed in **Table 1**.

RNA extraction and qRT-PCR

Total RNA was isolated from tissue samples using Trizol reagent (Invitrogen, USA) according to the protocols of manufacturers. PrimeScript® 1st strand cDNA synthesis kit (Takara, China) was used to synthesize the first-strand of cDNA. The relative mRNA expression of *cortactin* was detected by SYBR Green PCR kit (Takara, China). The primer sequences for *cortactin* and *GAPDH* were as follows: *cortactin*, forward- 5'-GGATGGATAAGAATGCGTCAAC-3', and reverse-5'-GTTACTTGTTTTGCTG- GTCACAG-3'; *GAPDH*, forward-5'-AGAAGGCTGGGGCTCATTTG-3', and reverse-5'-AGGGGCCATCCACAGTCTTC-3'. *GAPDH* served as internal control and the relative mRNA quantification of *cortactin* was calculated by $2^{-\Delta\Delta Ct}$ method. Each sample was examined in triplicate.

Statistical analysis

Statistical analyses were performed with SPSS 18.0 software and GraphPad Prism 5.0 software. The data were expressed as mean ± standard deviation (SD). Student's t-test was used to evaluate the difference between two groups. The relationship between *cortactin* expression and clinical characteristics of patients was analyzed via Chi-square test. Receiver operating characteristic (ROC) curve analysis was applied to estimate the diagnostic value of *cortactin* in OSCC. The difference was considered statistically significant when $P<0.05$.

Results

Demographic information of the study subjects

In this study, we enrolled 44 female and 78 male patients with a mean age of 56.47±15.28 years (range, 46-77 years). There were 73 OSCC patients with smoking and 66 patients with alcohol consumption. 72 cases had T1-T2 tumor size and 50 cases had T3-T4 tumor size. 51 patients were checked in poor histological grade and 58 patients were diagnosed with ▯-▯ TNM stage. There were 46 cases of lymph node metastasis and 42 patients with recurrence. The detailed clinical information was listed in **Table 1**.

Cortactin expression was up-regulated in OSCC patients

The relative mRNA expression of *cortactin* in OSCC tissues and adjacent normal tissues was detected by qRT-PCR. The results showed that *cortactin* expression was significantly higher in OSCC tissues than that in adjacent normal tissues at mRNA level (P<0.001, **Figure 1**).

Relationship between *cortactin* expression and clinical features of OSCC patients

According to the mean value of *cortactin* expression, 122 OSCC patients were divided into high *cortactin* expression group and low *cortactin* expression group. We analyzed the correlation of *cortactin* expression with clinical characteristics of patients. As shown in **Table 1**, elevated expression of *cortactin* was closely associated with tumor size (P=0.040), TNM stage (P=0.018), lymph node metastasis (P=0.013) and recurrence (P=0.031). However, there was no obvious correlation between *cortactin* expression and age, gender, smoking, alcohol consumption or histological grade (P>0.05, **Table 1**).

The diagnostic value of *cortactin* in OSCC patients

The ROC curve was established to assess the diagnostic value of *cortactin* in OSCC patients. The results indicated that the area under the curve (AUC) was 0.867 (95%CI=0.823-0.912, P<0.001) with a sensitivity of 76.2% and a specificity of 86.9% (**Figure 2**). The optimal cutoff value of *cortactin* expression was 1.65. *Cortactin* expression could be an effective bio-marker for the diagnosis of OSCC patients.

Discussion

OSCC is a common oral cancer and metastasis and recurrence are two characteristics of OSCC. Despite advances in treatment and diagnostics the incidence and mortality in patients with OSCC are increasing. The tumorigenesis of OSCC is a complex multi-step process which associated with the dysregulation of oncogenes and tumor suppressor genes [15]. In addition, most OSCC patients are diagnosed at advanced stages, and the routine therapeutic methods are not effective for them [16]. Early diagnosis may improve the prognosis and treatments of OSCC. Therefore, there is an urgent requirement to identify novel bio-markers for the diagnosis, therapy and prognosis of OSCC.

Cortactin protein possess a multi-domain structure consisting of an acidic domain at the amino terminus, a proline-rich helical region and an Src homology SH3 domain located at the carboxyl terminus [17, 18]. Cortactin protein was initially considered as a substrate of Src protein kinase and a cytoskeletal protein that plays a potential role in the regulation of the actin cytoskeleton, actin assembly and adhesion [19]. Besides, cortactin protein was involved in the pathogenesis and development of some human tumors. In the study of Zhao et al., increased expression of *cortactin* was observed in hepatoma carcinoma (HCC) cells, and it regulated the invasion and migration of HCC cells [20]. Ni et al. mentioned that *cortactin* was higher in colon cancer tissues than that in adjacent non-tumor tissues, and over-expression of *cortactin* enhanced cell colony formation and tumor growth [21].

In the present study, the qRT-PCR results showed that the relative expression of *cortactin* in OSCC tissues was significantly up-regulated compared with that in adjacent normal tissues at mRNA level, which was similar to previous studies [20, 21]. It revealed that *cortactin* gene might play an oncogenic role and exhibit tissue-specific in OSCC. Moreover, increased expression of *cortactin* was more frequently occurred in patients with larger tumor size, advanced TNM stage, positive lymph node metastasis and recurrence. According to these results, we hypothesized that *cortactin* expression might be involved in the development of OSCC. Our findings were consistent with the previous studies, for example, Lu et al. reported that the mRNA expression level of *cortactin* gene was over-expressed in esophageal squamous cell carcinoma and associated with tumor stage as well as lymph node metastasis of patients [22]. In head and neck squamous cell carcinoma, patients with positive *cortactin* expression tended to have recurrence or metastasis [23]. Nevertheless, a study carried out by Tsai et al. showed that the immunostaining scores of *cortactin* was obviously linked with histological grade of pancreatic and ampulla of Vater adenocarcinoma patients, which was inconsistent with our result [24]. The functions of *cortactin* in different cancers might be varied, and the sample size, its source as well as expression pattern might also cause the difference.

A large number of researches had demonstrated that *cortactin* was correlated with the prognosis of various tumors, including OSCC [25-27]. In the study of Li et al., they reported that the negative expression of *cortactin* was an independent prognostic factor and had a survival advantage in epithelial ovarian cancer [28]. *Cortactin* was demonstrated to be an important indicator of the malignancy and metastasis of liver cancer and might have predictive value in the prognosis of HCC [27, 29]. However, little is known about the diagnostic value of *cortactin* in OSCC. In this study, the result of ROC curve analysis indicated that *cortactin* mRNA expression could be a potential bio-marker for the diagnosis of OSCC patients with high values of AUC, sensitivity and specificity.

Conclusions

In summary, *cortactin* is up-regulated in OSCC and correlated with the progression of this tumor. What's more, *cortactin* may be a potential bio-marker for the diagnosis of OSCC. However, the precise molecular mechanism of *cortactin* in OSCC remains poorly studied, further researches are required.

Abbreviations

oral squamous cell carcinoma (OSCC)

quantitative real-time polymerase chain reaction (qRT-PCR).

receiver operating characteristic (ROC)

area under the curve (AUC)

Declarations

Ethics approval and consent to participate

This study was supported by the Ethics Committee of Chinese PLA General Hospital and also has been carried out in accordance with the World Medical Association Declaration of Helsinki.

The subjects had been informed the objective. Certainly, written consents were signed by every subject in this study.

Consent for publication

We obtaining permission from participants to publish their data.

Availability of data and materials The datasets used and/or analysed during the current study are available from the corresponding author on reasonable request.**Competing interests**The authors declare that they have no competing interests.**Authors' contributions** L.W. design of the work; H.S. the acquisition, analysis, S.Y. interpretation of data; L.W. the creation of new software used in the work; H.S., S.Y. have drafted the work or substantively revised it. All authors read and approved the final manuscript.**Acknowledgements** Not applicable.

Reference

1. Feng X, Jiang Y, Xie L, Jiang L, Li J, Sun C, Xu H, Wang R, Zhou M, Zhou Y *et al*: **Overexpression of proteasomal activator PA28alpha serves as a prognostic factor in oral squamous cell carcinoma**. *Journal of experimental & clinical cancer research : CR* 2016, **35**:35.
2. Gandhi R, Bhowate R, Nayyar AS, Gandhi S, Dongarwar G: **Color Doppler-ultrasonography in oral squamous cell carcinoma: Making ultrasonography more meaningful**. *Advanced biomedical research* 2016, **5**:29.
3. Chuerduangphui J, Pientong C, Chaiyarit P, Patarapadungkit N, Chotiyano A, Kongyingyoes B, Promthet S, Swangphon P, Wongjampa W, Ekalaksananan T: **Effect of human papillomavirus 16 oncoproteins on oncostatin M upregulation in oral squamous cell carcinoma**. *Med Oncol* 2016, **33**(8):83.

4. Jiang T, Xie P, Liu H: **Circulating Anti-Matrix Metalloproteinase-7 Antibodies May Be a Potential Biomarker for Oral Squamous Cell Carcinoma**. *Journal of oral and maxillofacial surgery : official journal of the American Association of Oral and Maxillofacial Surgeons* 2016, **74**(3):650-657.
5. Kelgandre DC, Pathak J, Patel S, Ingale P, Swain N: **Adenosine Deaminase - a Novel Diagnostic and Prognostic Biomarker for Oral Squamous Cell Carcinoma**. *Asian Pacific journal of cancer prevention : APJCP* 2016, **17**(4):1865-1868.
6. Xu H, Yang Y, Zhao H, Yang X, Luo Y, Ren Y, Liu W, Li N: **Serum miR-483-5p: a novel diagnostic and prognostic biomarker for patients with oral squamous cell carcinoma**. *Tumour biology : the journal of the International Society for Oncodevelopmental Biology and Medicine* 2016, **37**(1):447-453.
7. Chang H, Chen D, Ni B, Zuo Q, Wang C, Han R, Lan C: **Cortactin Mediates Apoptosis of Gastric Epithelial Cells Induced by VacA Protein of Helicobacter pylori**. *Digestive diseases and sciences* 2016, **61**(1):80-90.
8. Wang L, Zhao K, Ren B, Zhu M, Zhang C, Zhao P, Zhou H, Chen L, Yu S, Yang X: **Expression of cortactin in human gliomas and its effect on migration and invasion of glioma cells**. *Oncology reports* 2015, **34**(4):1815-1824.
9. Noh SJ, Baek HA, Park HS, Jang KY, Moon WS, Kang MJ, Lee DG, Kim MH, Lee JH, Chung MJ: **Expression of SIRT1 and cortactin is associated with progression of non-small cell lung cancer**. *Pathology, research and practice* 2013, **209**(6):365-370.
10. Gang Z, Ya-Lin K, Dong-Qing W, Yu L, Li R, Hong-Yi Z: **Combining cortactin and CTTN detection with clinicopathologic features increases effectiveness of survival predictions for patients with resectable hepatocellular carcinoma**. *Clinical laboratory* 2013, **59**(11-12):1343-1352.
11. Sheen-Chen SM, Huang CY, Liu YY, Huang CC, Tang RP: **Cortactin in breast cancer: analysis with tissue microarray**. *Anticancer research* 2011, **31**(1):293-297.
12. Nakane K, Fujita Y, Terazawa R, Atsumi Y, Kato T, Nozawa Y, Deguchi T, Ito M: **Inhibition of cortactin and SIRT1 expression attenuates migration and invasion of prostate cancer DU145 cells**. *International journal of urology : official journal of the Japanese Urological Association* 2012, **19**(1):71-79.
13. Hou H, Chen W, Zhao L, Zuo Q, Zhang G, Zhang X, Wang H, Gong H, Li X, Wang M *et al*: **Cortactin is associated with tumour progression and poor prognosis in prostate cancer and SIRT2 other than HADC6 may work as facilitator in situ**. *Journal of clinical pathology* 2012, **65**(12):1088-1096.
14. Yamada S, Yanamoto S, Kawasaki G, Mizuno A, Nemoto TK: **Overexpression of cortactin increases invasion potential in oral squamous cell carcinoma**. *Pathology oncology research : POR* 2010, **16**(4):523-531.
15. Jelovac DB, Tepavcevic Z, Nikolic N, Ilic B, Eljabo N, Popovic B, Carkic J, Konstantinovic V, Vukadinovic M, Milicic B *et al*: **The amplification of c-erb-B2 in cancer-free surgical margins is a predictor of poor outcome in oral squamous cell carcinoma**. *International journal of oral and maxillofacial surgery* 2016, **45**(6):700-705.

16. Ghallab NA, Shaker OG: **Serum and salivary levels of chemerin and MMP-9 in oral squamous cell carcinoma and oral premalignant lesions**. *Clinical oral investigations* 2016.
17. Croucher DR, Rickwood D, Tactacan CM, Musgrove EA, Daly RJ: **Cortactin modulates RhoA activation and expression of Cip/Kip cyclin-dependent kinase inhibitors to promote cell cycle progression in 11q13-amplified head and neck squamous cell carcinoma cells**. *Molecular and cellular biology* 2010, **30**(21):5057-5070.
18. MacGrath SM, Koleske AJ: **Cortactin in cell migration and cancer at a glance**. *Journal of cell science* 2012, **125**(Pt 7):1621-1626.
19. Kirkbride KC, Sung BH, Sinha S, Weaver AM: **Cortactin: a multifunctional regulator of cellular invasiveness**. *Cell adhesion & migration* 2011, **5**(2):187-198.
20. Zhao G, Zhang H, Huang Z, Lv L, Yan F: **Cortactin and Exo70 mediated invasion of hepatoma carcinoma cells by MMP-9 secretion**. *Molecular biology reports* 2016, **43**(5):407-414.
21. Ni QF, Yu JW, Qian F, Sun NZ, Xiao JJ, Zhu JW: **Cortactin promotes colon cancer progression by regulating ERK pathway**. *International journal of oncology* 2015, **47**(3):1034-1042.
22. Lu P, Qiao J, He W, Wang J, Jia Y, Sun Y, Tang S, Fu L, Qin Y: **Genome-wide gene expression profile analyses identify CTTN as a potential prognostic marker in esophageal cancer**. *PloS one* 2014, **9**(2):e88918.
23. You TK, Kim KM, Noh SJ, Bae JS, Jang KY, Chung MJ, Moon WS, Kang MJ, Lee DG, Park HS: **Expressions of E-cadherin, Cortactin and MMP-9 in Pseudoepitheliomatous Hyperplasia and Squamous Cell Carcinoma of the Head and Neck: Their Relationships with Clinicopathologic Factors and Prognostic Implication**. *Korean journal of pathology* 2012, **46**(4):331-340.
24. Tsai WC, Lin CK, Lee HS, Gao HW, Nieh S, Chan DC, Jin JS: **The correlation of cortactin and fascin-1 expression with clinicopathological parameters in pancreatic and ampulla of Vater adenocarcinoma**. *APMIS : acta pathologica, microbiologica, et immunologica Scandinavica* 2013, **121**(3):171-181.
25. Hou H, Zhao L, Chen W, Li J, Zuo Q, Zhang G, Zhang X, Li X: **Expression and significance of cortactin and HDAC6 in human prostatic foamy gland carcinoma**. *International journal of experimental pathology* 2015, **96**(4):248-254.
26. Liu YC, Ho HC, Lee MR, Yeh CM, Tseng HC, Lin YC, Chung JG: **Cortactin is a prognostic marker for oral squamous cell carcinoma and its overexpression is involved in oral carcinogenesis**. *Environmental toxicology* 2016.
27. Zhao G, Huang ZM, Kong YL, Wen DQ, Li Y, Ren L, Zhang HY: **Cortactin is a sensitive biomarker relative to the poor prognosis of human hepatocellular carcinoma**. *World journal of surgical oncology* 2013, **11**:74.
28. Li A, Zhang L, Zhang X, Jin W, Ren Y: **Expression and clinical significance of cortactin protein in ovarian neoplasms**. *Clinical & translational oncology : official publication of the Federation of Spanish Oncology Societies and of the National Cancer Institute of Mexico* 2016, **18**(2):220-227.
29. Huang X, Ji J, Xue H, Zhang F, Han X, Cai Y, Zhang J, Ji G: **Fascin and cortactin expression is correlated with a poor prognosis in hepatocellular carcinoma**. *European journal of gastroenterology*

& hepatology 2012, **24**(6):633-639.

Tables

Table 1. Relationship between *cortactin* expression and clinical characteristics of OSCC patients

Clinical Features	Cases (n=122)	*Cortactin* expression		c^2	*P*
		High (n=62)	Low (n=60)		
Age (years)				1.195	0.274
≤56	63	29	34		
>56	59	33	26		
Gender				0.793	0.373
Male	78	42	36		
Female	44	20	24		
Smoking				1.149	0.284
No	49	22	27		
Yes	73	40	33		
Alcohol consumption				1.580	0.209
No	56	25	31		
Yes	66	37	29		
Tumor size				4.237	0.040
T1-T2	72	31	41		
T3-T4	50	31	19		
Histological grade				0.584	0.445
Well/Moderate	71	34	37		
Poor	51	28	23		
TNM stage				5.598	0.018
□-□	64	26	38		
□-□	58	36	22		
Lymph node metastasis				6.124	0.013
Negative	76	32	44		
Positive	46	30	16		
Recurrence				4.647	0.031
No	80	35	45		
Yes	42	27	15		

Figures

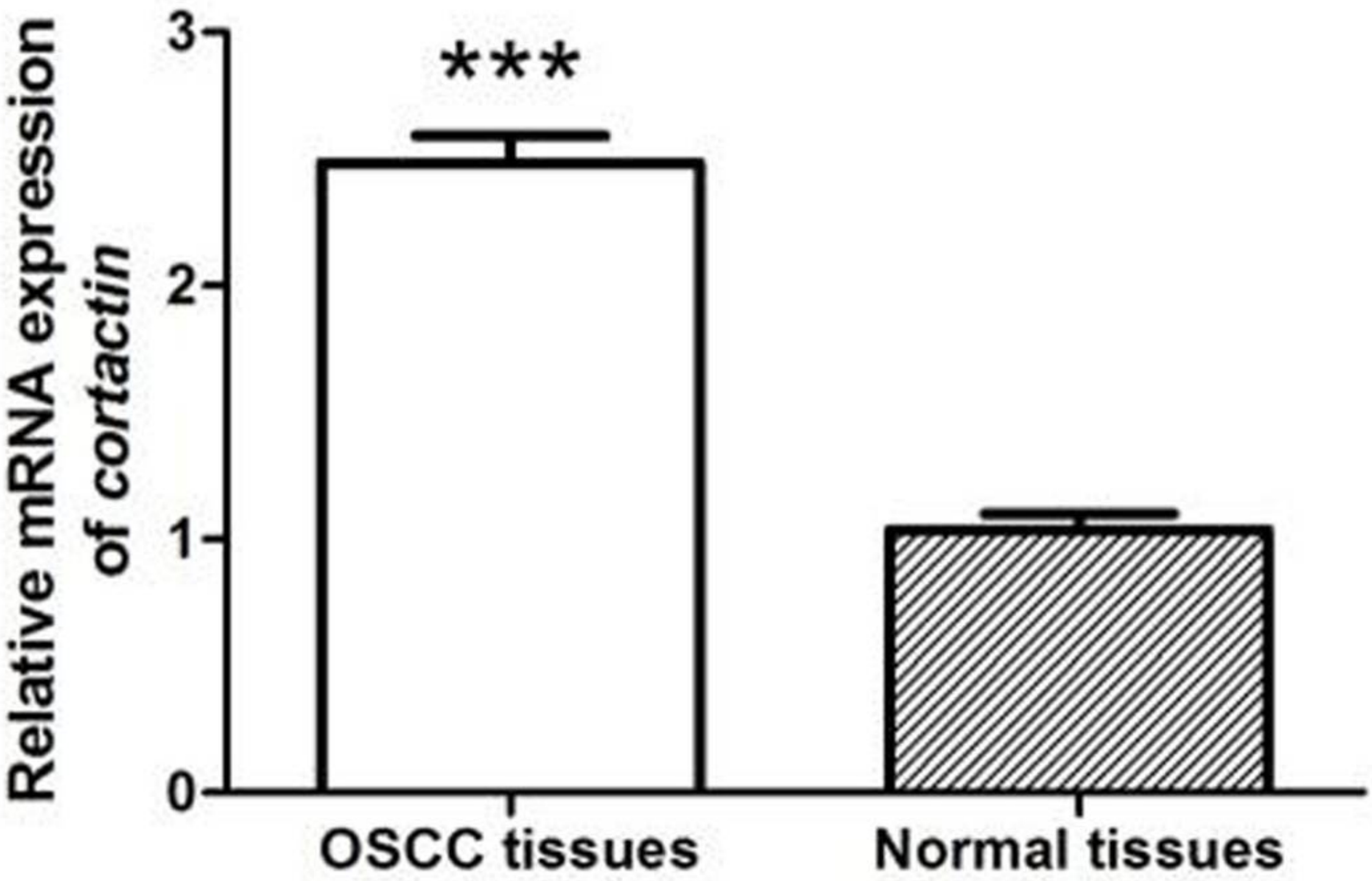

Figure 1

The relative mRNA expression of cortactin in OSCC tissues and adjacent normal oral mucosal tissues. Compared with normal tissues, cortactin mRNA expression was obviously up-regulated in OSCC tissues (***, P<0.001).

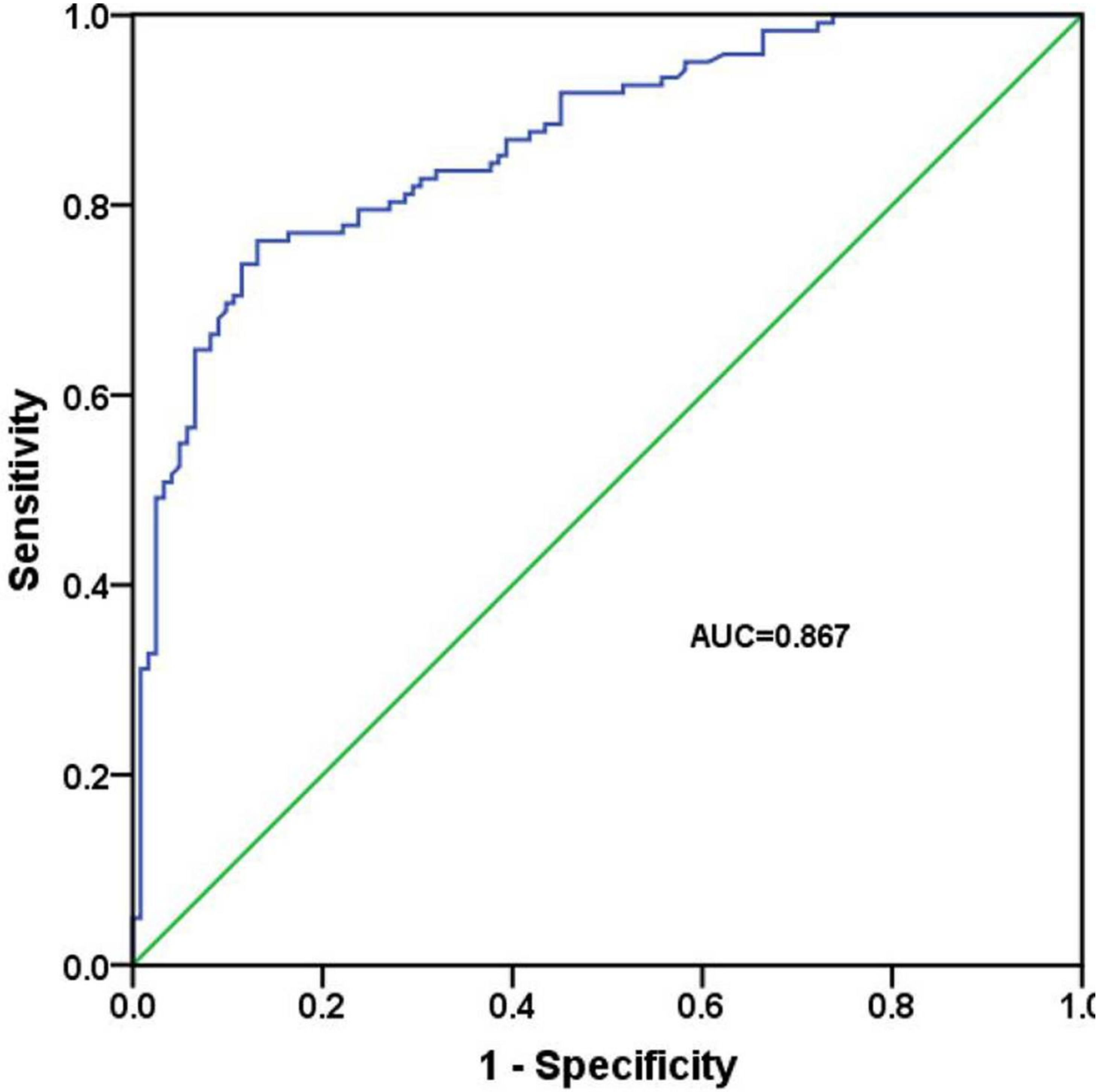

Figure 2

The ROC curve analysis of cortactin in the diagnosis of OSCC patients. The AUC was 0.867 with a sensitivity of 76.2% and a specificity of 86.9%.