

The radiomics features could be used to predict the distinct metastases in nasopharyngeal carcinoma patients

Meige Li

the first people's hospital of foshan

Ziyou Feng

yangjiang People's Hospital

Fang Yang

First People's Hospital of Foshan

ZeJiang Zhan

Guangzhou Medical University Affiliated Cancer Hospital

Haiwen Ye

First People's Hospital of Foshan

Guoyi Zhang (✉ guoyizhff@163.com)

Research article

Keywords: Nasopharyngeal carcinoma, MRI, Radiomics, Distinct metastases, PyRadiomics

Posted Date: January 5th, 2021

DOI: <https://doi.org/10.21203/rs.3.rs-51072/v2>

License:  This work is licensed under a Creative Commons Attribution 4.0 International License.

[Read Full License](#)

Abstract

Background For NPC patients, distant metastasis is now the main reason for treatment failure. The patients with distinct metastases need different therapeutic regimen and have distinct prognosis. Radiomics might help us predict the type of metastases effectively.

Methods The MRI data of seventy non-metastatic NPC patients who develop distant metastasis within five years after treatment were collected and 4410 radiomics features for each patient were extracted by PyRadiomics. Every radiomics feature were compared among patients with distinct metastases and tested by the receiver operating characteristic curve.

Results Twenty features have significant differences between the bone metastases cohort and lung metastases cohort, two features have significant differences between the bone metastases cohort and liver metastases cohort, one feature has significant differences between the bone metastases cohort and multiple metastases cohort and sixty-seven features have significant differences between the lung metastases cohort and liver metastases cohort. Six T2WI features could identified lung metastases from bone metastases and liver metastases effectively (AUC=0.851~0.896), two T1WI features and one CE T1WI feature could respectively identified bone metastases from liver metastases and multiple metastases effectively (AUC=0.779~0.821).

Conclusion The results indicate that the radiomics features could reflect some of the characteristics of distinct metastases and have potential to be used as predictor of distinct metastases.

Background

Nasopharyngeal carcinoma (NPC) has a unique geographical distribution, with the highest incidence in Southeast Asia. More than 70% of NPC patients are diagnosed as locoregionally advanced disease due to its hidden pathogenic site [1-4]. Currently the standard treatment for advanced NPC patients is radiotherapy combined with chemotherapy. Locoregional control has been improved substantially due to the use of intensitymodulated radiotherapy and combined chemoradiotherapy [5]. Moreover, approximately 30% to 40% of advanced NPC patients eventually develop distant metastasis after treatment and distant metastasis is now the main reason for treatment failure [6]. For advanced NPC patients, the common metastases were bone metastases, lung metastases, liver metastases, mediastina metastases and multiple metastases[6]. The patients with distinct metastases need different therapeutic regimen and have distinct prognosis.

The tumor–node–metastasis (TNM) staging system is the key determinant for prognostic prediction and risk stratification for treatment decisions. Even though NPC patients with the same TNM stage receive similar treatments, their clinical outcomes vary greatly. Hence, the current anatomical-based staging system is not sufficient to predict the site of metastases. If we could predict the site of the metastases and prevent before the occurrence of metastases, the patients would benefit from it and the survival time of the advanced NPC patients would be prolonged.

Recently, the radiomics emerged and it enabled image features to be extracted from standard-of-care medical imaging and applied within clinical-decision support systems and has significantly improved the diagnostic, prognostic, and predictive accuracy of various tumors[7-17]. Therefore, we wanted to see if radiomics could help us predict the site of the metastases in patients with advanced nasopharyngeal carcinoma.

Methods

Patients

This study included 70 non-metastatic NPC patients who were treated at the Affiliated Foshan Hospital of Sun Yat-Sen University from January 2009 to December 2012 and finally developed distant metastasis during the 5-year follow-up. The Inclusion & exclusion criteria were as follows: (a) pathological diagnosis of NPC; (b) without evidence of distant metastasis; (c) underwent radical IMRT according to the standard guidelines; (d) without a primary tumor in other parts of the body; (e) complete clinical and detailed MRI report data were available; (f) developed distant metastasis after treatment during the 5-year follow-up. This study was approved by the ethics committee of the Affiliated Foshan Hospital of Sun Yat-Sen University. All the participants provided written informed consent. The research protocol complied with the guidelines outlined in the Declaration of Helsinki. The 8th AJCC staging system was used as a standard manual for tumor staging and the related clinical characteristics were collected including age, gender, T stage, N stage, Epstein-Barr virus (EBV) DNA copy number before treatment, lactate dehydrogenase (LDH), VCA-IgA, EA-IgA, C-reactive protein, white blood cell (WBC), platelet (PLT), lymphocyte (LYM), monocyte (MONO), hepatitis B surface antigen (HBsAg) and Treatment regimen.

Follow-up and clinical endpoint

After completion of radiation and chemotherapy, all patients were followed up every 3 months in the first 2 years, every 6 months from year 3 to year 5, and annually thereafter. Follow-up was performed with endoscopy, head and neck computed tomography, or MRI. The follow-up period was defined as the time from the date of diagnosis to the date of the last follow-up or death.

MRI acquisition and Image assessment

All patients underwent MRI with a 1.5 T system (Signa CV/i; General Electric Healthcare, Chalfont St. Giles, United Kingdom) or 3.0 T system (Siemens Magnetom Tim Trio, Erlangen, Germany), employing the fast spin-echo (FSE) technique. Axial T1-weighted images (T1WI), contrast-enhanced T1-weighted images (CE T1WI), and T2-weighted images (T2WI) were retrieved from the picture archiving and communication system (PACS) and loaded in AnalyzePro (<https://analyzedirect.com/analyzepro/>) for semi-manual segmentation, without any preprocessing or normalization. The MRI scans were evaluated by two independent radiologists with over 10 years' experience in assessing MRI scans of patients with NPC. Differences were resolved by consensus.

Radiomics features extraction

Radiomics features extraction was performed using PyRadiomics, which is a flexible open-source platform capable of extracting a large number of engineering features from medical images (<http://www.radiomics.io/pyradiomics.html>)[18, 19]. In total, we extracted 4410 (1470×3) radiomics features for each patient from axial T1WI, T2WI, and CE T1WI scans.

Statistical analysis

The clinical characteristics of the cohorts were compared using the Mann-Whitney U test for continuous variables and Chi-square test for categorical variables and two-sided *P* values <0.05 were considered to be statistically significant. The receiver operating characteristic (ROC) curve was used to illustrate the diagnostic ability of a binary classifier system. The area under the curve (AUC) was calculated by the Hanley and McNeil method. These analyses were performed using Graphpad Prism software (version 5.1) and SPSS (version 20.0).

Result

Clinical Characteristics

The clinical and pathological features are listed in Table 1. The median follow-up period was 40.5 months (range: 6.2-72.2 months) for all patients. All patients finally developed distant metastasis during the 5-year follow-up, twelve of them developed bone metastases, sixteen of them developed lung metastases, thirteen of them developed liver metastases, three of them developed mediastina metastases and the other developed multiple metastases.

Table 1. The clinical characteristic of the NPC patients in this study.

Characteristic	bone metastases (n=12)	other metastases (n=58)	P value
Age			0.751
<50	7	37	
≥50	5	21	
Sex			1.0
Male	9	43	
Female	3	15	
T stage			0.166
T1	4	6	
T2	1	8	
T3	2	21	
T4	5	23	
N stage			0.796
N0	1	6	
N1	5	28	
N2	5	16	
N3	1	8	
TNM stage			0.134
I	1	0	
II	2	7	
III	3	23	
IV	6	28	
VCA-IgA			1
<1:80	1	9	
≥1:80	11	49	
EA-IgA			1
<1:10	3	14	
≥1:10	9	44	
EBV DNA copy number			0.485
<1000	4	11	
1000-9999	2	22	
10000-99999	4	18	
100000-999999	2	7	
≥ 1000000	0	0	
LDH concentration (U/L)			1
<245	11	54	
≥245	1	4	
C-reactive protein concentration (mg/L)			0.436
<8.2	11	45	
≥8.20	1	13	
WBC, 10⁹/L			0.299
<4	0	2	
4-10	12	48	
≥10	0	8	
PLT, 10⁹/L			0.851

<100	0	1	
100-300	10	46	
≥300	3	11	
LYM			1
<0.8	0	0	
0.8-4, 109/L	12	58	
≥4	0	0	
MONO, 109/L			1
<0.12	0	0	
0.12-0.8	10	49	
≥0.8	2	9	
HBsAg			1
0	10	47	
1	2	11	
Treatment			1
IMRT alone	1	2	
IC+IMRT	2	8	
CC+ IMRT	2	26	
AC+IMRT	1	0	
IC+CC+IMRT	6	22	

IC, induction chemotherapy; CC, concurrent chemoradiotherapy; AC, adjuvant chemotherapy.

Radiomics features have significant differences among the patients with distinct metastases.

Radiomics features (1470×3) for each patient were extracted from MRI scan (T1WI, T2WI, and CE T1WI). We compared these radiomics features among patients with distinct metastases and found that twenty features have significant differences between the bone metastases cohort and lung metastases cohort (Figure 1B), two features have significant differences between the bone metastases cohort and liver metastases cohort (Figure 1C), one feature has significant differences between the bone metastases cohort and multiple metastases cohort (Figure 1D) and sixty-seven features have significant differences between the lung metastases cohort and liver metastases cohort (Figure 1A). Moreover, one feature called “T2_log-sigma-5-0-mm-3D_glcm_ClusterShade” was higher in bone metastases cohort than other metastases cohort significantly (Figure 1E). These results indicated that MRI features could reflect some of the characteristics of distinct metastases and they might classify distinct metastases effectively.

Radiomics features could be used to classify distinct metastases

In order to explore which radiomics feature could classify distinct metastases, we performed ROC curve analysis and found that radiomics features could be used to classify distinct metastases effectively. As shown in Table 2 and Figure 2, six T2WI features could identified lung metastases from bone metastases and liver metastases effectively (AUC=0.851~0.896), two T1WI features and one CE T1WI feature could respectively identified bone metastases from liver metastases and multiple metastases effectively (AUC=0.779~0.821). Moreover, one T2WI feature could identified bone metastases from other

metastases (AUC=0.739). Then we created 1,000 different datasets by bootstrapping (80% resampling) and validated these selected features and we found that most of them were robust (Table 2). These results indicate that the radiomics features have potential to be used as predictor of distinct metastases and help to the interfere treatment before metastases in NPC patients.

The Radiomics features which could classify the metastases effectively.

Comparison	Sig. (2- tailed)	AUC	1000×Bootstrapping AUC (Mean±SD)
metastases vs Bone metastases			
j-sigma-5-0-mm-3D_firstorder_Minimum	<0.001	0.896	0.898±0.033
j-sigma-5-0-mm- szm_HighGrayLevelZoneEmphasis	0.001	0.865	0.867±0.039
j-sigma-5-0-mm- szm_LowGrayLevelZoneEmphasis	0.001	0.865	0.865±0.038
metastases vs Liver metastases			
ponential_firstorder_Mean	0.001	0.851	0.849±0.039
ponential_firstorder_RootMeanSquared	0.001	0.851	0.849±0.039
uare_glrIm_GrayLevelNonUniformityNormalized	0.001	0.851	0.851±0.039
metastases vs Liver metastases			
j-sigma-3-0-mm-3D_glszm_SmallAreaEmphasis	0.007	0.821	0.820±0.045
velet-HHH_firstorder_Median	0.007	0.821	0.820±0.052
metastases vs Multiple metastases			
ogarithm_glcm_MaximumProbability	0.006	0.779	0.779±0.041
metastases vs Other metastases			
j-sigma-5-0-mm-3D_glcm_ClusterShade	0.0097	0.739	0.739±0.038

ray Level size zone matrix; glcm, gray level co-occurrence matrix;

Discussion

We undertook this study to explore the value of radiomics in predicting the site of distant metastasis in NPC patients. We collected the MRI data of seventy non-metastatic NPC patients who develop distant metastasis within five years after treatment and 4410 radiomics features were extracted from each MRI patient by PyRadiomics. We compared the radiomics features among patients with distinct metastases and found that radiomics features have significant differences among these groups and some features could be used to predict the type of metastases effectively. These results indicate that the radiomics features have potential to be used as predictor of distinct metastases in NPC patients.

Currently, several studies have assessed the performance of radiomics signature in clinical staging, prognostic prediction, response to treatment, and discrimination of phenotype for several types of tumors [8-12, 14-16]. For Nasopharyngeal carcinoma patients, distant metastasis after treatment is one of the

most pressing issues and predicting the site of distant metastasis could be benefit to scheme of treatment. In 2018, a study reported a gene expression-based signature to predict distant metastasis in locoregionally advanced nasopharyngeal carcinoma [5] and they develop a nomogram to predict an individual's risk of distant metastasis. In that study they focused on the risk of distant metastasis and didn't group the patients according to the site of metastasis. Our study indicated that radiomics signature might be a good choice for predicting the site of metastasis because it allowed noninvasive and quantitative characterization of the tumor.

At present, the treatment is similar before the metastasis is diagnosed but the patients with bone metastasis have better outcome than liver and lung metastases. If the site of distant metastasis could be predicted, we could provide aggressive treatment regimen for the patients who have high risk of liver or lung metastasis to reduce the risk. The treatment might be different before the metastasis is diagnosed in the future to improve the prognosis of patients.

We collected the MRI data of 778 NPC patients who were treated at Sun Yat-Sen University Cancer Center from January 2009 to December 2012. Seventy patients developed distant metastasis during the 5-year follow-up. Limited by the number of patients, we couldn't validated the selected features in independent cohorts. We didn't know whether the features have the similar efficiency in distinct hospitals. We are trying our best to build cooperation with other radiologists and looked forward to getting diverse data to calibrate the findings in this study.

Conclusions

In this study we focus on the radiomics features of distinct metastases and found significant differences. They even could be used to predict the type of metastases effectively. These results indicate that the radiomics features have potential to be used as predictor of distinct metastases in NPC patients.

Abbreviations

NPC: Nasopharyngeal carcinoma

TNM: tumor node metastasis

EBV: Epstein-Barr virus

LDH: lactate dehydrogenase

WBC: white blood cell

PLT: platelet

LYM: lymphocyte

MONO: monocyte

HBsAg: hepatitis B surface antigen

T1WI: T1-weighted images

CE T1WI: contrast-enhanced T1-weighted images

T2WI: T2-weighted images

ROIs: regions of interest

ROC: The receiver operating characteristic

AUC: The area under the curve

Declarations

Ethics approval and consent to participate

This study was approved by the ethics committee of the Affiliated Foshan Hospital of Sun Yat-Sen University. All the participants provided written informed consent. The research protocol complied with the guidelines outlined in the Declaration of Helsinki.

Consent for publication

Not applicable

Availability of data and materials

The data that support the findings of this study are available from the corresponding author upon reasonable request.

Competing interests

The authors declare that they have no competing interests.

Funding

This work was supported by the Science and Technology Planning Program of Guangdong Province (No. 2017A020215128), Foshan city climbing peak plan (No. 2019A009).

Authors' contributions

GYZ designed and supervised the study. MGL and HWY collected follow-up data. ZYF and ZJZ performed the statistical analysis. MGL, ZYF and GYZ wrote the manuscript. GYZ carried out an extensive revision.

All authors participated in the writing and approval of the manuscript.

Acknowledgments

The authors thank all the medical staff who contributed to the maintenance of the medical record database.

References

1. Bray F, Ferlay J, Soerjomataram I, Siegel RL, Torre LA and Jemal A. Global cancer statistics 2018: GLOBOCAN estimates of incidence and mortality worldwide for 36 cancers in 185 countries. *CA: a cancer journal for clinicians*. 2018; 68(6):394-424.
2. Torre LA, Bray F, Siegel RL, Ferlay J, Lortet-Tieulent J and Jemal A. Global cancer statistics, 2012. *CA: a cancer journal for clinicians*. 2015; 65(2):87-108.
3. Jemal A, Bray F, Center MM, Ferlay J, Ward E and Forman D. Global cancer statistics. *CA: a cancer journal for clinicians*. 2011; 61(2):69-90.
4. Pan JJ, Ng WT, Zong JF, Lee SW, Choi HC, Chan LL, Lin SJ, Guo QJ, Sze HC, Chen YB, Xiao YP, Kan WK, O'Sullivan B, Xu W, Le QT, Glastonbury CM, et al. Prognostic nomogram for refining the prognostication of the proposed 8th edition of the AJCC/UICC staging system for nasopharyngeal cancer in the era of intensity-modulated radiotherapy. *Cancer*. 2016; 122(21):3307-3315.
5. Tang XR, Li YQ, Liang SB, Jiang W, Liu F, Ge WX, Tang LL, Mao YP, He QM, Yang XJ, Zhang Y, Wen X, Zhang J, Wang YQ, Zhang PP, Sun Y, et al. Development and validation of a gene expression-based signature to predict distant metastasis in locoregionally advanced nasopharyngeal carcinoma: a retrospective, multicentre, cohort study. *The Lancet Oncology*. 2018; 19(3):382-393.
6. Lai SZ, Li WF, Chen L, Luo W, Chen YY, Liu LZ, Sun Y, Lin AH, Liu MZ and Ma J. How does intensity-modulated radiotherapy versus conventional two-dimensional radiotherapy influence the treatment results in nasopharyngeal carcinoma patients? *International journal of radiation oncology, biology, physics*. 2011; 80(3):661-668.
7. Lambin P, Leijenaar RTH, Deist TM, Peerlings J, de Jong EEC, van Timmeren J, Sanduleanu S, Larue R, Even AJG, Jochems A, van Wijk Y, Woodruff H, van Soest J, Lustberg T, Roelofs E, van Elmpt W, et al. Radiomics: the bridge between medical imaging and personalized medicine. *Nature reviews Clinical oncology*. 2017; 14(12):749-762.
8. Nie K, Shi L, Chen Q, Hu X, Jabbour SK, Yue N, Niu T and Sun X. Rectal Cancer: Assessment of Neoadjuvant Chemoradiation Outcome based on Radiomics of Multiparametric MRI. *Clinical cancer research : an official journal of the American Association for Cancer Research*. 2016; 22(21):5256-5264.
9. Huang Y, Liu Z, He L, Chen X, Pan D, Ma Z, Liang C, Tian J and Liang C. Radiomics Signature: A Potential Biomarker for the Prediction of Disease-Free Survival in Early-Stage (I or II) Non-Small Cell Lung Cancer. *Radiology*. 2016; 281(3):947-957.

10. Zhang B, Tian J, Dong D, Gu D, Dong Y, Zhang L, Lian Z, Liu J, Luo X, Pei S, Mo X, Huang W, Ouyang F, Guo B, Liang L, Chen W, et al. Radiomics Features of Multiparametric MRI as Novel Prognostic Factors in Advanced Nasopharyngeal Carcinoma. *Clinical cancer research : an official journal of the American Association for Cancer Research*. 2017; 23(15):4259-4269.
11. Huang YQ, Liang CH, He L, Tian J, Liang CS, Chen X, Ma ZL and Liu ZY. Development and Validation of a Radiomics Nomogram for Preoperative Prediction of Lymph Node Metastasis in Colorectal Cancer. *Journal of clinical oncology : official journal of the American Society of Clinical Oncology*. 2016; 34(18):2157-2164.
12. Li H, Zhu Y, Burnside ES, Drukker K, Hoadley KA, Fan C, Conzen SD, Whitman GJ, Sutton EJ, Net JM, Ganott M, Huang E, Morris EA, Perou CM, Ji Y and Giger ML. MR Imaging Radiomics Signatures for Predicting the Risk of Breast Cancer Recurrence as Given by Research Versions of MammaPrint, Oncotype DX, and PAM50 Gene Assays. *Radiology*. 2016; 281(2):382-391.
13. O'Connor JP, Rose CJ, Waterton JC, Carano RA, Parker GJ and Jackson A. Imaging intratumor heterogeneity: role in therapy response, resistance, and clinical outcome. *Clinical cancer research : an official journal of the American Association for Cancer Research*. 2015; 21(2):249-257.
14. Zhou M, Scott J, Chaudhury B, Hall L, Goldgof D, Yeom KW, Iv M, Ou Y, Kalpathy-Cramer J, Napel S, Gillies R, Gevaert O and Gatenby R. Radiomics in Brain Tumor: Image Assessment, Quantitative Feature Descriptors, and Machine-Learning Approaches. *AJNR American journal of neuroradiology*. 2018; 39(2):208-216.
15. Kickingereder P, Burth S, Wick A, Gotz M, Eidel O, Schlemmer HP, Maier-Hein KH, Wick W, Bendszus M, Radbruch A and Bonekamp D. Radiomic Profiling of Glioblastoma: Identifying an Imaging Predictor of Patient Survival with Improved Performance over Established Clinical and Radiologic Risk Models. *Radiology*. 2016; 280(3):880-889.
16. Kickingereder P, Gotz M, Muschelli J, Wick A, Neuberger U, Shinohara RT, Sill M, Nowosielski M, Schlemmer HP, Radbruch A, Wick W, Bendszus M, Maier-Hein KH and Bonekamp D. Large-scale Radiomic Profiling of Recurrent Glioblastoma Identifies an Imaging Predictor for Stratifying Anti-Angiogenic Treatment Response. *Clinical cancer research : an official journal of the American Association for Cancer Research*. 2016; 22(23):5765-5771.
17. Kong DS, Kim J, Ryu G, You HJ, Sung JK, Han YH, Shin HM, Lee IH, Kim ST, Park CK, Choi SH, Choi JW, Seol HJ, Lee JI and Nam DH. Quantitative radiomic profiling of glioblastoma represents transcriptomic expression. *Oncotarget*. 2018; 9(5):6336-6345.
18. Liu Q, Jiang P, Jiang Y, Ge H, Li S, Jin H and Li Y. Prediction of Aneurysm Stability Using a Machine Learning Model Based on PyRadiomics-Derived Morphological Features. *Stroke*. 2019; 50(9):2314-2321.
19. Aerts HJ, Velazquez ER, Leijenaar RT, Parmar C, Grossmann P, Carvalho S, Bussink J, Monshouwer R, Haibe-Kains B, Rietveld D, Hoebers F, Rietbergen MM, Leemans CR, Dekker A, Quackenbush J, Gillies RJ, et al. Decoding tumour phenotype by noninvasive imaging using a quantitative radiomics approach. *Nature communications*. 2014; 5:4006.

Figures

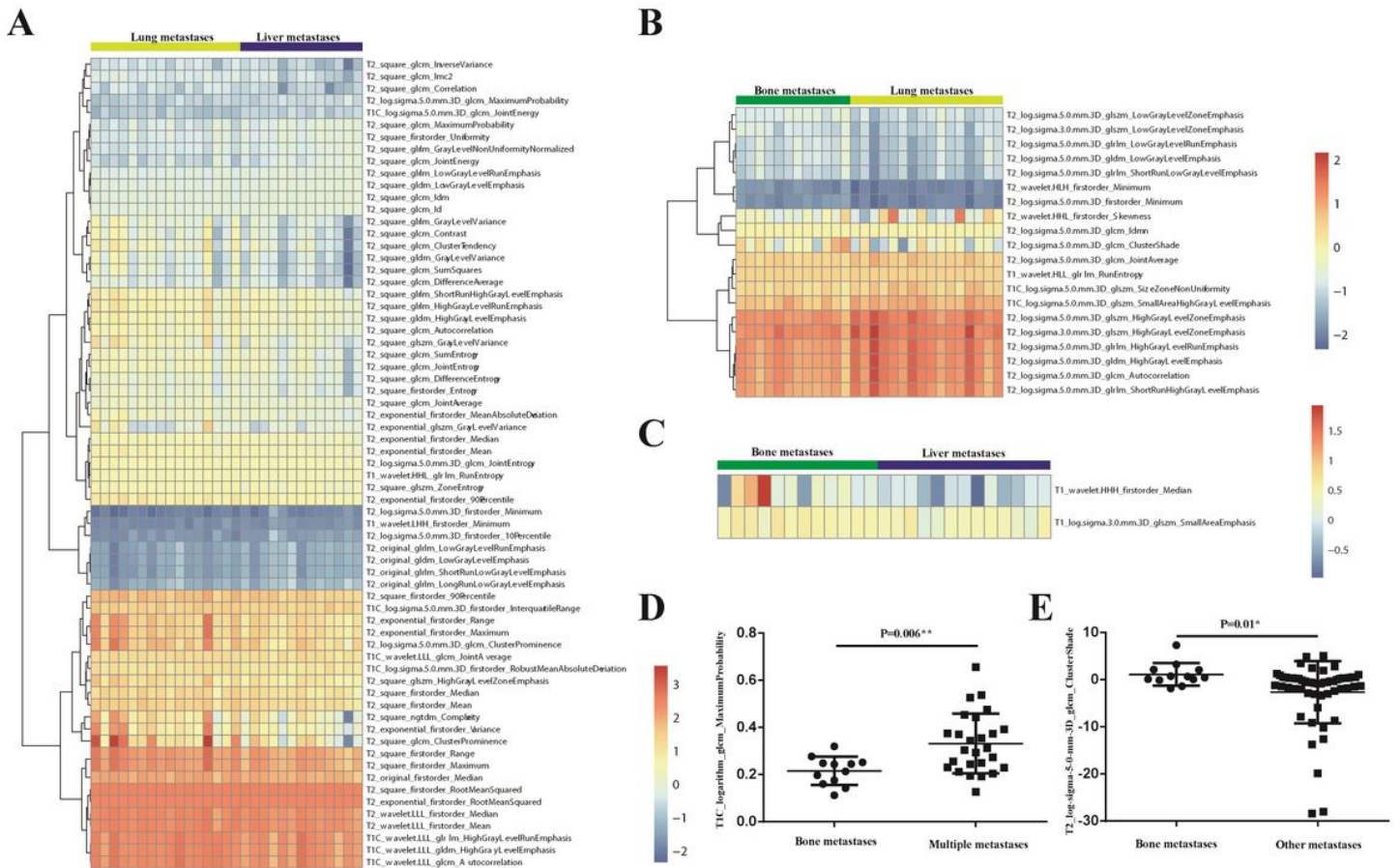


Figure 1

The radiomics features which have significant differences between (A) the lung metastases cohort and liver metastases cohort, (B) the bone metastases cohort and lung metastases cohort, (C) the bone metastases cohort and liver metastases cohort, (D) the bone metastases cohort and multiple metastases cohort, (E) bone metastases cohort and other metastases cohort.

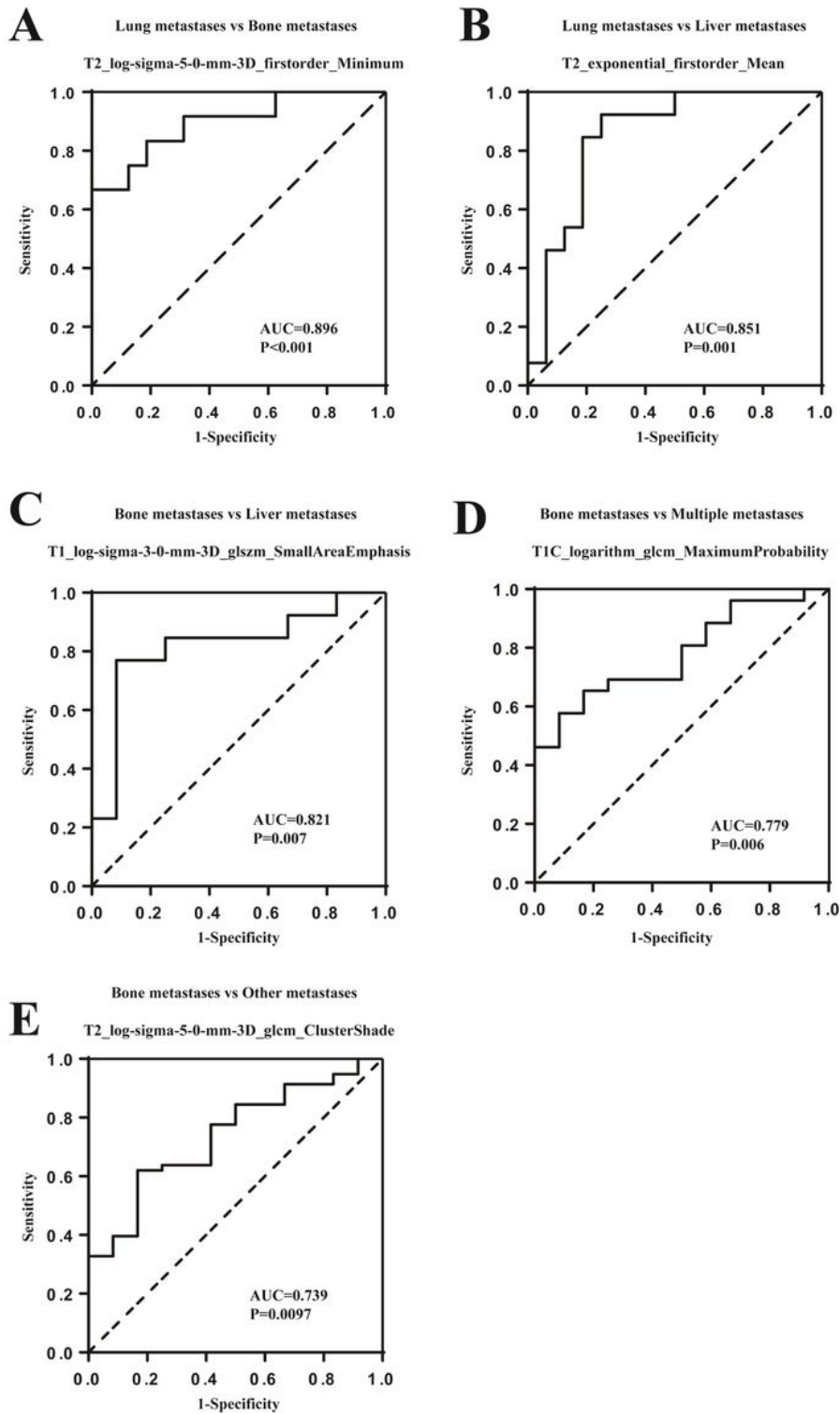


Figure 2

The ROC curves of the radiomics features which could be used to classify distinct metastases effectively. (A) the bone metastases cohort and lung metastases cohort, (B) the lung metastases cohort and liver metastases cohort, (C) the bone metastases cohort and liver metastases cohort, (D) the bone metastases cohort and multiple metastases cohort, (E) bone metastases cohort and other metastases cohort.