

Utility of Oxygen Insufflation Through Working Channel During Fiberoptic Intubation: a Prospective Randomized Controlled Study

Go Un Roh

CHA Bundang Medical Center CHA University School of Medicine <https://orcid.org/0000-0003-0375-8004>

Joon Gwon Kang

CHA Bundang Medical Center

Jung Youn Han

CHA Bundang Medical Center

Chul Ho Chang (✉ anezzang@yuhs.ac)

Research article

Keywords: fiberoptic intubation, apneic oxygenation, oxygenation during intubation

Posted Date: August 7th, 2020

DOI: <https://doi.org/10.21203/rs.3.rs-50531/v1>

License:  This work is licensed under a Creative Commons Attribution 4.0 International License.

[Read Full License](#)

Version of Record: A version of this preprint was published on November 10th, 2020. See the published version at <https://doi.org/10.1186/s12871-020-01201-9>.

Abstract

Background: Airway management is a part of routine anesthetic procedures; however, serious complications, including hypoxia and death, are known to occur in cases of difficult airways. Therefore, alternative techniques such as fiberoptic bronchoscope-assisted intubation (FOBI) should be considered, although this method requires more time and offers a limited visual field than does intubation with a direct laryngoscope. Oxygen insufflation through the working channel during FOBI could minimize the risk of desaturation and improve the visual field. Therefore, the aim of this prospective randomized controlled study was to evaluate the utility and safety of oxygen insufflation through the working channel during FOBI.

Methods: Thirty-six patients were randomly allocated to an N group (no oxygen insufflation) or an O group (oxygen insufflation). After preoxygenation, FOBI was performed with (O group) or without (N group) oxygen insufflation. The primary outcome was the velocity of decrease in the partial pressure of oxygen during FOBI (V_{PaO_2}), while secondary outcomes included the success rate for FOBI, time to intubation, visual field during FOBI, findings of arterial blood gas analysis, and occurrence of FOBI-related complications.

Results: We found that V_{PaO_2} was significantly greater in the N group than in the O group (1.01 ± 0.39 vs. 0.42 ± 0.42 ; $p < 0.001$), while the visual field was similar between groups. There were no significant intergroup differences in the secondary outcomes.

Conclusions: These findings suggest that oxygen insufflation through the working channel during FOBI aids in extending the apneic window during the procedure.

Trial registration: ClinicalTrials.gov, NCT02625194, registered at December 9, 2015

Background

Airway management is a part of essential anesthetic procedures. However, it becomes challenging in cases of difficult airways and can cause several complications, including airway trauma, hypoxia, and even death.(1, 2) Therefore, intubation techniques involving the use of fiberoptic bronchoscopes (FOBs) and videolaryngoscopes should be considered as alternative options.(3, 4) During FOB-assisted intubation (FOBI), superior visualization of anatomical structures is the key for successful intubation, and suction through the working channel of FOB is commonly performed for the clearance of secretions and blood and improvement of the visual field. Oxygen insufflation through this working channel during the procedure is also possible and recommended by some physicians.(5–7) Oxygen insufflation through the working channel during FOBI, which requires a longer time than does direct laryngoscopic intubation, can minimize the risk of desaturation in apneic patients.(8) In addition, oxygen flow at the end of FOB could help in the clearance of secretions and small structural barriers, resulting in improved visualization during the procedure.(5, 9) However, a few reports have documented rare but critical complications such as gastric rupture and pneumothorax.(10–12) Moreover, this technique is not recommended for pediatric

patients or patients with significant airway edema. [11] Thus, oxygen insufflation through the working channel during FOBI has certain advantages and limitations. However, few studies have evaluated its utility and safety in clinical practice. Therefore, the aim of the present study was to evaluate the utility and safety of oxygen insufflation through the working channel during FOBI via measurement of the velocity of decrease in the partial pressure of oxygen (PaO_2) during the procedure (V_{PaO_2}). In addition, the time to intubation, visual field, and occurrence of FOBI-related complications were investigated.

Materials And Methods

Patients

This prospective randomized controlled study was approved by the Institutional Review Board of Yonsei University Gangnam Severance Hospital (IRB No 3-2015-0218, NCT02625194, <https://clinicaltrials.gov/ct2/show/NCT02625194?term=NCT02625194&rank=1>). After the acquisition of written informed consent, 36 patients aged 20–60 years (American Society of Anesthesiologists class I to III) who were scheduled for elective surgery under general endotracheal anesthesia with arterial cannulation at Yonsei University Gangnam Severance Hospital were included. The exclusion criteria included lung disease, anticipated difficult airway, inability to read or write, and pregnancy. The randomization table at www.random.org was used to allocate patients to an N group (no oxygen insufflation) or an O group (oxygen insufflation) at ratio of 1:1.

Study design and procedure

After premedication with 0.02 mg/kg of midazolam and 0.004 mg/kg of glycopyrrolate in the preanesthesia care unit, patients were transferred to the operating room, where standard monitoring procedures, including electrocardiography, pulse oximetry, and noninvasive blood pressure measurement, were initiated. Vital signs, including the heart rate, systolic blood pressure, diastolic blood pressure, and peripheral oxygen saturation, were recorded before anesthesia induction. Preoxygenation with 100% oxygen using a facemask was performed for 5 min, following which anesthesia was induced with propofol 1.5 mg/kg, remifentanyl 0.1 mcg/kg/min, and rocuronium 0.8 mg/kg. The radial artery was cannulated during manual ventilation. After 2 min of manual ventilation, arterial blood was collected and the facemask was removed for intubation (T1). The airway was opened by the jaw thrust maneuver, and endotracheal intubation was performed using a flexible FOB (Intubation fiberscope, 5.2 × 65 mm, Karl Storz GmbH & CO, Germany) with a preloaded endotracheal tube. In the O group, 100% oxygen was administered at 5 L/min through the working channel. The N group did not receive oxygen insufflation. Intubation success was confirmed by bronchoscopy, following which arterial blood was collected before the initiation of ventilation (T2). The first end-tidal carbon dioxide value after the resumption of ventilation following intubation was recorded.

Study endpoints

The primary endpoint was V_{PaO_2} . Secondary endpoints included the FOBI success rate, time to intubation (from facemask removal until resumption of ventilation), visual field during FOBI (excellent, clear view of anatomical structures and no limitation; good, < 50% limitation in the view but no difficulty in intubation; poor, > 50% limitation in the view, resulting in significant difficulty in intubation; and impossible, inability to identify the anatomical structures and intubate), and occurrence of FOBI-related complications, including mucosal injury, abdominal distension, postoperative nausea and/or vomiting, and desaturation [peripheral capillary oxygen saturation (SpO_2) < 90%]. In addition, vital signs and pH, partial pressure of carbon dioxide ($PaCO_2$), and PaO_2 values were recorded for all patients.

Statistical analysis

Considering the findings of Rosenstock, who reported a mean V_{PaO_2} of 0.9 mmHg/s with a standard deviation of 0.17, we found that 16 patients per group were required for detection of a 0.25 mmHg/s decrease in V_{PaO_2} with a type 1 error and power of 0.05 and 80%, respectively(13). Accordingly, a total of 18 patients per group were included after accounting for the withdrawal rate during study. All statistical analyses were performed using SPSS, version 18.0 (SPSS Inc., Chicago, IL, USA). Continuous variables were assessed using Student's t-tests or the Mann–Whitney U-test, while categorical variables were assessed using the chi-square test or Fisher's exact test. The Bonferroni method was used to compensate the error of multiple comparisons. A P-value of < 0.05 was considered statistically significant.

Results

In total, 36 patients were enrolled, 35 of whom completed the study. One patient in the N group was excluded because of malfunction of the arterial blood gas analysis machine (Fig. 1). The patients' baseline characteristics were not different between the two groups (Table 1). All patients were successfully intubated. Vital signs (Table 2) and pH, $PaCO_2$, PaO_2 and SaO_2 values (Table 3) also showed no significant intergroup differences throughout the procedure. The time to intubation was approximately 150 s in both groups. Although PaO_2 showed no significant intergroup differences at T1 and T2, the decrease in PaO_2 during FOBI was significantly greater in the N group than in the O group (139.38 ± 74.34 vs. 71.98 ± 67.72 , $p = 0.012$). In addition, V_{PaO_2} was significantly greater in the N group than in the O group (1.01 ± 0.39 vs. 0.42 ± 0.42 , $p < 0.001$). An excellent visual field was obtained for 12 and 7 patients in the O and N groups, respectively, with no significant intergroup difference. None of the patients presented mucosal injury, abdominal distension, and desaturation. One patient in the O group exhibited postoperative nausea (Table 4).

Table 1
Patients' Characteristics

	No Oxygen (n = 17)	Oxygen (n = 18)	P-value
Age (year)	53.06 ± 15.66	59.06 ± 9.64	0.330
Sex (male, number)	5	6	0.803
Height (cm)	161.59 ± 10.71	162.44 ± 9.141	0.655
Weight (kg)	63.88 ± 12.51	66.11 ± 13.97	0.741
ASA Class			0.391
I	8	4	
II	8	12	
III	1	2	
Values are expressed as mean ± standard deviation or number			

ASA, American Society of Anesthesiologist.

Table 2
Vital signs during procedures

	No Oxygen (n = 17)	Oxygen (n = 18)	P-value
Heart rate (bpm)			
T1	75.06 ± 15.49	67.94 ± 10.43	0.291
T2	93.41 ± 15.85	87.17 ± 14.94	0.261
SBP (mmHg)			
T1	105.24 ± 21.68	106.06 ± 17.44	0.428
T2	142.35 ± 33.08	132.11 ± 27.51	0.391
DBP (mmHg)			
T1	57.82 ± 11.96	61.89 ± 14.51	0.437
T2	79.88 ± 19.62	77.83 ± 18.19	0.656
SpO ₂ (%)			
T1	99.41 ± 0.71	99.39 ± 0.92	0.809
T2	99.00 ± 1.32	98.72 ± 1.23	0.376
Values are expressed as mean standard ± deviation.			
T1, 2 min after manual ventilation with 100% oxygen; T2, after intubation confirmed with bronchoscopy, before ventilation resumed; SBP, systolic blood pressure; DBP, diastolic blood pressure; SpO ₂ , peripheral oxygen saturation.			

Table 3
Arterial blood gas analysis during procedures

	No Oxygen (n = 17)	Oxygen (n = 18)	P-value
pH			
T1	7.39 ± 0.05	7.38 ± 0.03	0.106
T2	7.33 ± 0.04	7.32 ± 0.04	0.373
PaCO ₂			
T1	37.62 ± 6.43	38.32 ± 6.13	0.552
T2	46.65 ± 6.55	47.54 ± 6.08	0.632
PaO ₂ (mmHg)			
T1	414.97 ± 90.41	379.73 ± 72.32	0.137
T2	275.58 ± 94.91	307.76 ± 97.20	0.322
SaO ₂			
T1	99.86 ± 0.15	99.88 ± 0.07	0.929
T2	99.44 ± 1.16	99.56 ± 1.39	0.335
Values are expressed as mean standard ± deviation.			

T1, 2 min after manual ventilation with 100% oxygen; T2, after intubation confirmed with bronchoscopy, before ventilation resumed; PaCO₂, arterial partial pressure of carbon dioxide; PaO₂, arterial partial pressure of oxygen; SaO₂, arterial oxygen saturation.

Table 4
Fiberoptic bronchoscope-assisted intubation related data

	No Oxygen (n = 17)	Oxygen (n = 18)	P-value
Intubation time (sec)	145.47 ± 74.77	155.89 ± 70.06	0.632
PaO ₂ difference	139.38 ± 74.34	71.98 ± 67.72	0.012
VPaO ₂ (mmHg/s)	1.01 ± 0.39	0.42 ± 0.42	0.000
Visual field			0.183
Excellent	7	12	
Good	8	3	
Poor	2	3	
Complication			
PONV (N)	0	1	1.000
Values are expressed as mean standard ± deviation or number.			
PaO ₂ difference, difference of arterial partial pressure of oxygen between 2 min after manual ventilation with 100% oxygen and after intubation confirmed with bronchoscopy, before ventilation resumed; VPaO ₂ , velocity of decrease in arterial partial pressure of oxygen; PONV, postoperative nausea and vomiting.			

Discussion

In the present study assessing the utility of oxygen insufflation during FOBI, V_{PaO₂} was significantly reduced when oxygen was insufflated through the working channel. However, patients with and without oxygen insufflation showed no significant differences in the intubation success rate, time to intubation, visual field, and occurrence of complications.

Despite recent advances in airway management devices such as videolaryngoscopes and supraglottic airways, FOBI is still considered the gold standard for difficult airway management(14, 15) However, it requires a longer time than does intubation with a direct laryngoscope. In addition, secretions and bleeding in the airway obscure the airway anatomy and complicate intubation.(3) Therefore, methods to improve patient oxygenation after the induction of anesthesia can facilitate faster and safer FOBI.

Several studies have attempted to overcome the limitations of FOBI. A direct laryngoscope or GlideScope can assist the placement of FOB near the glottis and facilitate easy intubation.(16–18) In addition, supraglottic airways such as I-gel or LMA can be used as conduits for FOBI, providing a better route to the glottic inlet and, at the same time, ventilating the lungs during the procedure.(19, 20) However, these techniques require the use of additional devices and result in an increased time to intubation. Especially,

they are inappropriate in patients with limited mouth opening.(21) Oxygen insufflation through the working channel during FOBI does not require extra time and devices. Oxygen insufflation through the working channel of FOB could alleviate both hypoxia and visual field impairment in children.(5) In our study, V_{PaO_2} was 1.01 ± 0.39 mmHg/s in the N group, which was more than twice the value for the O group (0.42 ± 0.42 mmHg/s). If the hypoxia-free apnea time during FOBI is defined as the time from the discontinuation of mask ventilation at a PaO_2 of 500 mmHg to the achievement of 90% SpO_2 at a PaO_2 of 60 mmHg, under the assumption that PaO_2 exhibits a linear decrease during apnea, the hypoxia-free apnea duration could be approximately 10 min longer in the O group than in the N group (1047.62 s vs. 435.64 s, respectively).

This calculation is based on a ventilatory mass flow, also known as apneic oxygenation. During regular breathing in an adult, oxygen and carbon dioxide are exchanged between the lungs and blood at a flow rate of 250 ml/min. During apnea, the carbon dioxide flow returning to the lungs is significantly reduced to 8–20 ml/min while the oxygen flow to the blood is maintained. Therefore, negative pressure is generated in the lungs according to the volume difference during oxygen and carbon dioxide exchange; this facilitates the movement of oxygen from the pharynx to the lungs.(8, 22)

Apneic oxygenation could be applied in various clinical situations involving different types of devices, including nasal prongs, nasopharyngeal catheters, and tracheal or bronchial catheters. The first two are commonly used because they are practical.(8) Oxygenation with nasal prongs at 5 l/min during FOBI could lower the decrease in PaO_2 at 3 min during apnea.(23) In Teller's crossover study evaluating the influence of oxygen delivery via a nasopharyngeal catheter at 3 l/min, apnea was continued for 10 min or until SpO_2 decreased to 92%. None of the patients in the apneic oxygenation group showed an SpO_2 of < 97% until 10 min. On the other hand, the mean apnea time in the control group was 6.8 min and the lowest SpO_2 value was 91%.(24) In present study, we used the working channel of FOB to continuously deliver oxygen as FOB moved toward the trachea. This increases the efficiency of oxygen delivery to the lungs and could be particularly useful for patients prone to desaturation during apnea, such as obese patients.(25)

One limitation of apneic oxygenation is that it cannot efficiently remove carbon dioxide from the blood, resulting in an increase in the carbon dioxide level at a rate of 1.1–3.4 mmHg/min and, eventually, hypercarbia and acidosis.(8) Therefore, it should not be used in patients with a risk of hypercarbia-related complications. Of late, the use of a high flow nasal cannula has garnered attention in various clinical situations, and it can be effectively used for apneic oxygenation during intubation as well. Studies found that it could deliver a high concentration of oxygen, generate a positive airway pressure of approximately 7 cmH₂O, and slow down the increase in the carbon dioxide level during apneic oxygenation.(22, 26) In the present study, the increase in $PaCO_2$ during the apneic period was similar in the O and N groups.

With regard to the visual field, the number of patients with an excellent visual field was not significantly different between groups, although the number was higher in the O group. This result was inconsistent with those of previous reports, and there are a few possible explanations for the discrepancy. Unlike

Rosen's study, which included pediatric patients with difficult airways and involved the use of smaller FOBs,(5) the present study included adult patients without anticipated difficult airways and involved the use of FOBs with a larger diameter. Moreover, all patients were premedicated with glycopyrrolate in order to minimize secretions.(3) The visual field can be easily disrupted during awake FOBI because of patient movement and lens fogginess caused by spontaneous breathing.(7) However, we performed the study under anesthesia with complete muscle relaxation, so there were no disturbances during FOBI. Therefore, the intubation conditions were quite good, and the actual effect of oxygen insufflation may not have been as significant as expected.

The two groups in our study showed a comparable intubation success rate and time to intubation; this could be attributed to the lack of differences in the visual field quality. The optimal intubation conditions may be another factor that repressed the influence of oxygen on the intubation-related parameters. We believe that different results may be derived if the measurements were recorded in emergency situations involving patients with unanticipated difficult airways. Further studies should take this aspect into consideration and assess the usefulness of oxygen insufflation during FOBI in different clinical scenarios.

From our results, it is evident that oxygen insufflation through the working channel of FOB can reduce $VPaO_2$ during FOBI. Oxygen insufflation through the working channel of FOB can cause rare but serious complications such as gastric rupture and pneumothorax.(10, 11, 27) Oxygen can enter the trachea or esophagus during the procedure. If oxygen is delivered to the esophagus and stomach, it could cause nausea, vomiting.(10, 12) If FOB with oxygen insufflation enters the stomach, it could cause significant distension of the stomach and even rupture, because the maximal capacity of the stomach is approximately 1 l, and FOB could deliver approximately 2.5 l of oxygen in just 30 s, theoretically.(10, 28) However, according to Wong's review of several studies on nasal or nasopharyngeal apneic oxygenation, no complications related to pressure effects have been reported till date.(8) The esophagus is closed by a sphincter, and approximately 20 cmH_2O of pressure is required to open it.(29) According to a previous report using nasal high flow oxygen insufflation, the mean airway pressure was approximately 7 cmH_2O , (26) which is considerably lower than the pressure required to open the esophageal sphincter. In the present study, none of the patients complained of vomiting or abdominal distension, and only one patient in group O developed postoperative nausea. Furthermore, there was no case of mucosal injury or desaturation during the procedure. This was probably due to the optimal intubation conditions and the completion of intubation within 5 min, which is considered safe if the patient is preoxygenated.(26)

This study has some limitations. First, FOBI was conducted under optimal conditions as described earlier. Therefore, the results cannot be applied to other clinical situations such as emergency difficult airway management. Second, our sample size was enough for $VPaO_2$ measurement but not adequate to assess the occurrence of complications, which are anyways rare.

Conclusions

In conclusion, our findings suggest that oxygen insufflation through the working channel of FOB can help in extending the apneic window after the induction of general anesthesia during FOBI, with minimal complications.

Abbreviations

FOBI	
fiberoptic bronchoscope-assisted intubation	
FOB	
fiberoptic bronchoscope	
PaO ₂	
partial pressure of oxygen	
V _{PaO2}	
velocity of decrease in the partial pressure of oxygen	
PaCO ₂	
partial pressure of carbon dioxide	
SpO ₂	
peripheral capillary oxygen saturation	

Declarations

• Ethics approval and consent to participate

This study was approved by the Institutional Review Board of Yonsei University Gangnam Severance Hospital (IRB No 3-2015-0218).

• Consent for publication

Not applicable

• Availability of data and materials

The datasets used or analysed during the current study are available from the corresponding author on reasonable request.

• Competing interests

The authors declare that they have no competing interests.

• Funding

The authors have nothing to declare.

• Acknowledgements

Not applicable

References

1. Caplan RA, Posner KL, Ward RJ, Cheney FW. Adverse respiratory events in anesthesia: a closed claims analysis. *Anesthesiology*. 1990;72(5):828-33.
2. Hove LD, Steinmetz J, Christoffersen JK, Moller A, Nielsen J, Schmidt H. Analysis of deaths related to anesthesia in the period 1996-2004 from closed claims registered by the Danish Patient Insurance Association. *Anesthesiology*. 2007;106(4):675-80.
3. Collins SR, Blank RS. Fiberoptic intubation: an overview and update. *Respiratory care*. 2014;59(6):865-78; discussion 78-80.
4. Xue FS, Cheng Y, Li RP. Awake intubation with video laryngoscope and fiberoptic bronchoscope in difficult airway patients. *Anesthesiology*. 2013;118(2):462-3.
5. Rosen DA, Rosen KR, Nahrwold ML. Another use for the suction port on the pediatric flexible bronchoscope. *Anesthesiology*. 1986;65(1):116.
6. Roberts JT. Preparing to use the flexible fiber-optic laryngoscope. *J Clin Anesth*. 1991;3(1):64-75.
7. Benumof JL. Management of the difficult adult airway. With special emphasis on awake tracheal intubation. *Anesthesiology*. 1991;75(6):1087-110.
8. Wong DT, Yee AJ, Leong SM, Chung F. The effectiveness of apneic oxygenation during tracheal intubation in various clinical settings: a narrative review. *Canadian journal of anaesthesia = Journal canadien d'anesthesie*. 2017;64(4):416-27.
9. Bennett-Guerrero E, Stolp BW. Fiberoptic intubation. *The New England journal of medicine*. 2011;365(6):574; author reply 5-6.
10. Chapman N. Gastric rupture and pneumoperitoneum caused by oxygen insufflation via a fiberoptic bronchoscope. *Anesthesia and analgesia*. 2008;106(5):1592.
11. Khan RM, Sharma PK, Kaul N. Barotrauma: a life-threatening complication of fiberoptic endotracheal intubation in a neonate. *Paediatr Anaesth*. 2010;20(8):782-4.
12. Ho CM, Yin IW, Tsou KF, Chow LH, Tsai SK. Gastric rupture after awake fiberoptic intubation in a patient with laryngeal carcinoma. *British journal of anaesthesia*. 2005;94(6):856-8.
13. Rosenstock CV, Thogersen B, Afshari A, Christensen AL, Eriksen C, Gatke MR. Awake fiberoptic or awake video laryngoscopic tracheal intubation in patients with anticipated difficult airway management: a randomized clinical trial. *Anesthesiology*. 2012;116(6):1210-6.
14. Lohse J, Noppens R. [Awake video laryngoscopy - an alternative to awake fiberoptic intubation?]. *Anesthesiol Intensivmed Notfallmed Schmerzther*. 2016;51(11-12):656-63.

15. Law JA, Morris IR, Brousseau PA, de la Ronde S, Milne AD. The incidence, success rate, and complications of awake tracheal intubation in 1,554 patients over 12 years: an historical cohort study. *Canadian journal of anaesthesia = Journal canadien d'anesthesie*. 2015;62(7):736-44.
16. Ara T, Mori G, Adachi E, Asai T, Okuda Y. [Combined use of the GlideScope and fiberoptic bronchoscope for tracheal intubation in a patient with difficult airway]. *Masui The Japanese journal of anesthesiology*. 2014;63(6):647-9.
17. Gu J, Xu K, Ning J, Yi B, Lu K. GlideScope-assisted fiberoptic bronchoscope intubation in a patient with severe rheumatoid arthritis. *Acta Anaesthesiol Taiwan*. 2014;52(2):85-7.
18. Sharma D, Kim LJ, Ghodke B. Successful airway management with combined use of Glidescope videolaryngoscope and fiberoptic bronchoscope in a patient with Cowden syndrome. *Anesthesiology*. 2010;113(1):253-5.
19. Kanda T, Kasai H, Sanefuji Y. [Fiberoptic tracheal intubation through the supraglottic airway device air-Q in a patient with Shprintzen-Goldberg syndrome]. *Masui The Japanese journal of anesthesiology*. 2013;62(8):942-5.
20. Arevalo-Ludena J, Arcas-Bellas JJ, Alvarez-Rementeria R, Alameda LE. Fiberoptic-guided intubation after insertion of the i-gel airway device in spontaneously breathing patients with difficult airway predicted: a prospective observational study. *J Clin Anesth*. 2016;35:287-92.
21. Moore A, Gregoire-Bertrand F, Massicotte N, Gauthier A, Lallo A, Ruel M, et al. I-gel Versus LMA-Fastrach Supraglottic Airway for Flexible Bronchoscope-Guided Tracheal Intubation Using a Parker (GlideRite) Endotracheal Tube: A Randomized Controlled Trial. *Anesthesia and analgesia*. 2015;121(2):430-6.
22. Patel A, Nouraei SA. Transnasal Humidified Rapid-Insufflation Ventilatory Exchange (THRIVE): a physiological method of increasing apnoea time in patients with difficult airways. *Anaesthesia*. 2015;70(3):323-9.
23. Lee SC. Improvement of gas exchange by apneic oxygenation with nasal prong during fiberoptic intubation in fully relaxed patients. *Journal of Korean medical science*. 1998;13(6):582-6.
24. Teller LE, Alexander CM, Frumin MJ, Gross JB. Pharyngeal insufflation of oxygen prevents arterial desaturation during apnea. *Anesthesiology*. 1988;69(6):980-2.
25. Ramachandran SK, Cosnowski A, Shanks A, Turner CR. Apneic oxygenation during prolonged laryngoscopy in obese patients: a randomized, controlled trial of nasal oxygen administration. *J Clin Anesth*. 2010;22(3):164-8.
26. Ritchie JE, Williams AB, Gerard C, Hockey H. Evaluation of a humidified nasal high-flow oxygen system, using oxygraphy, capnography and measurement of upper airway pressures. *Anaesthesia and intensive care*. 2011;39(6):1103-10.
27. Ovassapian A, Mesnick PS. Oxygen insufflation through the fiberscope to assist intubation is not recommended. *Anesthesiology*. 1997;87(1):183-4.
28. Geliebter A, Hashim SA. Gastric capacity in normal, obese, and bulimic women. *Physiol Behav*. 2001;74(4-5):743-6.

29. Lawes EG, Campbell I, Mercer D. Inflation pressure, gastric insufflation and rapid sequence induction. British journal of anaesthesia. 1987;59(3):315-8.

Figures

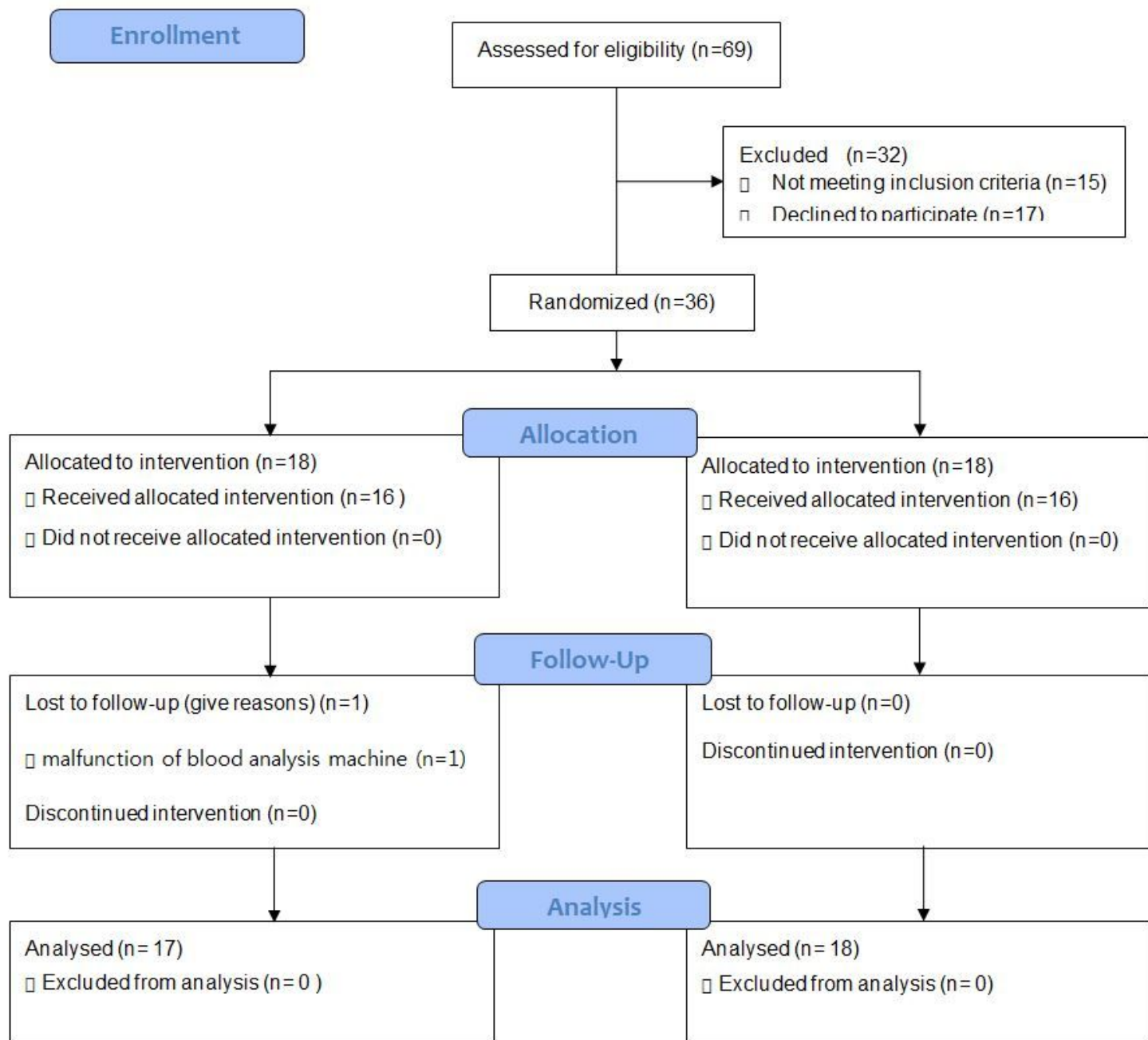


Figure 1

CONSORT diagram showing the flow of participants.