

Diagnosis, Treatment of Type I Autoimmune Pancreatitis and Management of Relapse and Side Effects After Steroid Treatment

Neng Tang

Xiangya Hospital Central South University

Xiaolin Dou

Xiangya Hospital Central South University

Guodong Liu

Xiangya Hospital Central South University

Xing You

Xiangya Hospital Central South University

Zhenglin Ou

Xiangya Hospital Central South University

Mujing Ke

Xiangya Hospital Central South University

Xiaoping Yi

Xiangya Hospital Central South University

Liandong Ji (✉ ja19841043@163.com)

Xiangya Hospital Central South University

Research

Keywords: Autoimmune Pancreatitis (AIP), Immunoglobulin G4 (IgG4), Other Organ Involvement (OOI), Relapse Rates (RRs), side effects

Posted Date: May 13th, 2021

DOI: <https://doi.org/10.21203/rs.3.rs-490501/v1>

License: © ⓘ This work is licensed under a Creative Commons Attribution 4.0 International License.

[Read Full License](#)

Abstract

Background: Autoimmune pancreatitis (AIP) is a rare disease, have a dramatic response to steroid therapy, but the relapse rates(RRs) is very high, and the side effects of steroid therapy are inevitable. The aim of this study is to focus on the management of relapse and side effects.

Methods: A single-centre, retrospective, cohort study of the type 1 AIP patients admitted to Xiangya Hospital Central South University from September 2008 to September 2019 conducted. Collection and retrospectively analyzed the clinicopathologic data and outcomes of these patients.

Results: 82 patients were included, 73.2% were histologically confirmed. 78.0% treated by medications: 62.5% prednisolone, 37.5% prednisolone plus cyclophosphamide. The RRs of the two group have no significant difference (35.0% vs 29.2%, $P = 0.630$). Increasing the dosage of prednisolone, the effective rate of the prednisolone treatment and prednisolone plus cyclophosphamide treatment relapsed patients were 78.57% and 71.43%, respectively. The side effects were DM in 12.5%; central obesity in 15.6%; hyperlipidemia in 18.8%; gastric ulcer in 6.3%; osteoporosis in 9.4%; bone fracture in 1.6%. For those side effects patients performed low dose prednisolone and expectant treatment have a ideal results.

Conclusions: Increasing the dose of prednisolone can effectively treat relapsed patients. Low dose steroid and expectant treatment should be performed when side effects arised.

Introduction

Autoimmune pancreatitis (AIP) is mediated by autoimmunity and is characterized by obstructive jaundice, pancreatic enlargement, irregular stenosis of the pancreatic duct, lymphoplasmacytic infiltration and fibrosis, and other organ involvement (OOI). AIP is a particular type of chronic pancreatitis which was first described by Sarles in 1961 [1] and Yoshida et al proposed the concept of AIP in 1995 [2]. Japanese scholars have reported that AIP accounts for 5%-6% of chronic pancreatitis [3]. Atsushi Masamune et al reported that the overall prevalence rate of 10.1 per 100,000 persons and annual incidence rate of 3.1 per 100,000 persons in Japan [4].

In recent years, AIP is increasingly recognized as a new clinical entity with its protean pancreatic obiliary and systemic presentations [5]. Its unique pathology and overlap of clinical and radiological features foster the disease's unique position. Two histological subtypes in AIP have been recognized, type I and type II [6, 7]. Over the past decade, many national case studies of AIP have been published [8, 9], but rare reported from China which suffering from a high prevalence of type 1 AIP.

Because of the similarities between clinical manifestations and imaging findings of AIP and pancreatic cancer, clinicians and radiologists do not have enough knowledge about it, so that some patients with AIP experienced unnecessary surgical treatment due to misdiagnosis as pancreatic cancer. AIP is a particular type of chronic pancreatitis which are dramatic response to steroids [10–18]. But various RRs, ranging

from 24–63%, have been reported for type I AIP [19–22]. Furthermore, several studies have reported steroid side effects related to AIP and other autoimmune diseases [23–29]. The aims of this study were to analyze the data of AIP patients and summarize the diagnosis and treatment experience of type I AIP in China. Due to the RRs of AIP is very high, and the side effects of steroid therapy are inevitable. Therefore this study also focus on the management of relapse and side effects.

Methods

Patients

The study was conducted in Xiangya Hospital Central South University. Collection and retrospectively analyzed the clinicopathologic data and outcomes of these patients who was hospitalized in our center during September 2008 to September 2019. According to International Consensus of Diagnostic Criteria (ICDC) [10], all patients were diagnosed as AIP. Excluded the patients with incomplete information collection and the patients with type II AIP. A total of 82 cases were included.

Observation indicators

Collect clinical data of patients included, including gender, age, symptoms, bilirubin (BIL), alanine aminotransferase (ALT), aspartate aminotransferase (AST), blood amylase, carbohydrate antigen 19-9 (CA19-9), Immunoglobulin G (IgG), Immunoglobulin G4 (IgG4), Antinuclear Antibody (ANA), and imaging (abdominal CT, MRI/magnetic resonance cholangiopancreatography (MRCP)), and pathological findings. Focal or mass-forming lesion was defined as focal-type AIP, and the swollen pancreas extending from the pancreatic head to tail as diffuse-type AIP [14]. OOI was the presence of extra-pancreatic disease (this did not include the intra-pancreatic biliary tract involvement or distal biliary stenosis [15].

Follow-up

Follow-up period was the time from AIP diagnosis until death or the last visit. During follow-up, patients underwent CT or MRI/MRCP at 3-month intervals during the first year, 6-month intervals during the second year and then once a year to monitor relapse and OOI. Serum IgG4 levels and biochemical blood tests were performed at every visit to the outpatient clinic. For the steroid therapy patients we also asked if there were any side effects.

Statistical analysis

Continuous variables were presented as means \pm standard deviation (SD), and were compared using Student's *t* test. Categorical variables were compared using the Chi square test, and *P*-value < 0.05 was considered to indicate statistically significant differences. All the statistical analyses were performed using the Statistical Product and Service Solutions (SPSS) 22.0 statistical software package (IBM Analytics, Armonk, NY) in this study.

Results

Eighty-two patients with type Ⅱ AIP were included in this study, the ratio of male with female was 2.73: 1 with mean ages at diagnosis were 53.4 ± 11.2 years. Patients' characteristics are summarized in Table 1. Serological results and radiographic results are summarized in Table 2.

CT examination

80 patients underwent CT examination, 58 patients (72.5%) considered AIP, 22 patients (27.5%) considered pancreatic biliary tract tumors, 52 cases (65.0%) showed focal pancreatic enlargement, 28 cases (35.0%) showed diffuse enlargement, pancreatic head enlargement in 23 cases (28.8%). The diffuse AIP CT scan showed typical pancreas diffuse enlargement was "sausage-like", pancreatic parenchymal density decreased, dynamic enhancement was homogeneous and delayed intensification; some patients had clearly defined low density envelope-like margins around the pancreas, which was characteristic of AIP (Fig. 1a, b). After the treatment with steroid, the pancreatic parenchyma was reduced and evenly strengthened. The clearance around the pancreas was clear and the feather-like structure was restored (Fig. 1c, d). The focal manifestation of focal AIP is a low-density mass. After dynamic enhancement, delayed and homogenous enhancement of the mass can be seen (Fig. 2a). After treatment, the mass disappears, and the parenchymal mass of the pancreas is evenly enhanced and the structure is clear (Fig. 2b).

MRCP examination

MRCP was performed in 50 patients (71.0%), 25 cases (50.0%) of them considered AIP, the other 25 (50%) considered bile duct or pancreatic head tumors; There were 31 (62.0%) cases of pancreatic duct stricture and 30 cases of bile duct dilatation (60.0%), The typical MRCP showed pancreatic duct stricture with a stenosis length $> 1/3$ of the whole pancreatic duct (Fig 3a, b).

Histological examination

16 patients(19.5%) underwent surgical treatment due to misdiagnosed pancreatic cancer, and postoperative pathological diagnosed as AIP. 44 cases (53.7%) of OOI patients have underwent the involvement organ biopsies. 18 cases (40.9%) of them underwent salivary gland biopsy and, 6 cases (13.6%) underwent ultrasound-guided renal biopsy, 4 cases (9.1%) of lymph node biopsy, 16 case (36.4%) of duodenal papillary biopsy. Pathological examination of pancreatic showed acinar atrophy, massive plasma cells and lymphocytes infiltration, fibrous tissue hyperplasia (Fig 4a). The results of pathological examination of salivary gland showed partial acinar atrophy, a large number of plasma cells and lymphocytes infiltration (Fig 4b). Pathological examination results of lymph nodes showed lymphoid tissue hyperplasia, structural disorder, massive plasma cell proliferation, a large number of dendritic cell proliferation in follicles, immunohistochemistry Kappa (+), Lamda (+), IgG (-), IgG4 (+) (Fig 4c).

Treatment and outcomes

The initial dose of prednisolone is at least 30 mg/d, the dose of cyclophosphamide was 100 mg/d, 2-4 weeks later to review if the effect is well, start to reduce the prednisolone dose 5 mg/d every 1-2 weeks, according to the results of clinical manifestations, abdominal CT and IgG4 to adjust the dose. Reexamine abdominal CT and IgG4 every 4-6 weeks; maintain the dose of 5mg/d for at least 6 months after the clinical manifestations, abdominal CT and IgG4 results are normal. For those relapsed patients, we increasing the dose of prednisolone to initial dose. For those patients, who have side effects due to high dose of prednisolone treatment, we reduce the dose of prednisolone to 5mg/d, and reviewed very two week, until the clinical manifestations, abdominal CT and IgG4 results are normal, also continued maintain treatment for 6 months.

All of the 82 patients were followed up for 12-142 months, with a median follow-up time of 92 months. 64 patients (78.0%) underwent treatment with different medications: 40 cases (62.5%) prednisolone, 24 cases (37.5%) prednisolone plus cyclophosphamide. The effective rate of prednisolone and prednisolone plus cyclophosphamide was no significant difference [37/40(92.5%) vs 22/24(91.7%), $P=0.904$]. And the RRs of prednisolone and prednisolone plus cyclophosphamide also have no significant difference (35.0% vs 29.2%, $P=0.630$). 14 cases (35.0%) of the prednisolone treatment patients relapsed after remission, 8 (20.0%) of them had more than two relapse events. 5 (12.5%) of them had twice relapse events, 2 patients (5.0%) no longer treated and relapsed three times; One patient (2.5%) had four relapse events, and died due to intolerance to prednisolone therapy. 11 of the 14 prednisolone treatment relapsed patients have remission by increasing the dose of prednisolone to initial dose and gradually decreased the dose, finally withdrawal the prednisolone after 6 months maintenance treatment. 7 (29.2%) of prednisolone plus cyclophosphamide treatment patients relapsed after remission, 4 (16.7%) of them had more than two relapse events; one of them had three relapse events, and died due to repeated of cholangitis, one case cannot rule out pancreatic cancer after recurrence, and then treated surgically, but died due to postoperative complications. Increase the prednisolone to initial dose and gradually decreased the dose, finally withdrawal the prednisolone after 6 months maintenance treatment, 5 of 7 prednisolone plus cyclophosphamide treatment relapsed patients have remission. Therapeutic effect between prednisolone and prednisolone plus cyclophosphamide in Table 3.

The side effects of the 64 drug treatment patients were DM in 8 patients (12.5%); central obesity or moon face in 10 cases (15.6%); hyperlipidemia in 12 cases (18.8%); gastric ulcer in 4 cases (6.3%); osteoporosis in 6 case (9.4%); bone fracture in 1 case (1.6%). For these patients we reduce the dose of prednisolone, and low dose maintenance treatment was performed, furthermore, for the DM patients oral hypoglycemic drugs, for the central obesity or moon face and hyperlipidemia patients oral statins, for the gastric ulcer patients oral proton pump inhibitor (PPIs) and gastric mucosal protective drugs, osteoporosis patients oral calcium supplements, for the fracture patient we withdraw prednisolone and surgical treatment of fracture, but three months later relapse of AIP, we performed low dose prednisolone maintenance treatment, the effect is also very good.

18 cases (22.0%) were not treated with prednisolone, of which 12 cases (14.6%) were misdiagnosed as cholangiocarcinoma or pancreatic cancer and received surgical treatment, and 2 cases died due to

relapse after cholangiojejunostomy; 4 cases (4.9%) prednisolone experimental therapy patients could not exclude pancreatic cancer, and then underwent surgical treatment, and 2 cases died due to postoperative complications. 4 cases (4.9%) unwillingness prednisolone treatment, and 3 (75.0%) of them died due to recurrent cholangitis. 2 case (3.7%) was found due to physical examination, and had no symptoms all the time, 1 case died for natural causes.

Discussion

To the best of our knowledge, this is the only one retrospective study ever conducted in a tertiary hospital in China that summarize the experience of diagnosis and treatment of AIP, which specifically focus on the management of relapse and side effects. We found the misdiagnosis rates of AIP is very high, so it is very important to improve the accurate diagnosis rate of AIP. There was no significant difference between prednisolone and prednisolone plus cyclophosphamide in the treatment of type I AIP. Increasing the dose of steroid can be effective on therapy relapse patients. Low dose steroid and symptomatic treatment should be performed when side effects arise from a high dose of steroid.

AIP is an enigmatic disease and sometimes difficult to diagnose [30]. The clinical manifestations of AIP are complex, in particular, focal AIP is very similar to pancreatic cancer in imaging manifestation, so it is difficult to distinguish focal AIP from pancreatic cancer. But AIP is sensitive to hormone therapy and does not need surgical treatment, whereas pancreatic cancer requires surgical treatment. Therefore, the differential diagnosis between AIP and pancreatic cancer is great importance. AIP has a variety of diagnostic criteria, and the applicable conditions and methods of each criterion are different, so the AIP diagnosed in different countries may sometimes differ [16]. In 2011, Shimosegawa et al first proposed the International Consensus of Diagnostic Criteria (ICDC) of AIP, and divided the AIP into Type I and Type II, which is the most widely accepted diagnostic criteria [10]. The AIP in China is mainly type I, that is, IgG4-related diseases affect the pancreas, most of them onset in the elderly, and about 70% of cases can be diagnosed in experienced treatment centers without the pathological specimens [17].

Elevated gamma globulinemia and immunoglobulin IgG, especially elevated IgG4, have been considered as characteristic indicator of AIP [18]. As many as 94% of AIP patients have elevated IgG4 levels [31], and IgG4 levels are closely related to disease activity [32]. Van Heerde et al. [33] studied the serum IgG4 and CA19-9 in patients with AIP and pancreatic cancer found that the sensitivity and specificity for diagnosis of AIP was 73% and 74% respectively with CA19-9 < 74 kU/L as the cut-off value. with IgG4 > 2.6 g/L as the threshold, the sensitivity of IgG4 for diagnosis of AIP was 70%, and the specificity was 100%. The sensitivity and specificity of diagnosis of AIP with combined CA19-9 < 74 kU/L and IgG4 > 1.0 g/L was 94% and 100% respectively. Therefore, simultaneous detect IgG4 levels and CA19-9 can improve the differential diagnosis rate between AIP and pancreatic cancer. The results of this study were basically consistent with the report. 72 patients were tested for IgG and 62 patients (86.1%) were elevated; IgG4 was detected in 62 cases, and 56 cases (90.3%) were positive.

Chari et al. [12] reported that 30% of AIP patients needed steroid experimental therapy, needle biopsy and surgical resection to make a definite diagnosis. In this study, 16 cases (19.5%) were misdiagnosed as pancreatic cholangiocarcinoma and were diagnosed as AIP after surgery. Focal mass AIP is difficult to be diagnosed by imaging examination and endoscopic ultrasound biopsy [34], and endoscopic ultrasound biopsy is not available in some hospitals, so biopsy of the involved organs is helpful for diagnosis. In this study, 44 patients (53.7%) underwent tissue biopsy. The results showed that biopsy of involved organs is beneficial to the diagnosis of AIP. If cholangitis is combined, do ERCP and duodenal papillary biopsy can help to exclude pancreatic cancer and cholangiocarcinoma. When the differential diagnosis is not clear, steroid experimental therapy is helpful to diagnose AIP, but in order to avoid delay in the treatment of malignant tumors, imaging examination have performed 2 to 4 weeks after hormone therapy, the mass must be nearly completely relieved, any no relief of the mass must do exploratory surgery [35].

The first goal of therapy in type I AIP is to induce remission. Response to steroid therapy in patients with AIP is dramatic and consistently leads to clinical improvement regardless of the subtypes [19, 36]. As a result, steroids have become the standard therapy for inducing remission in AIP [37, 38]. In the ICDC the starting dose of steroid for remission induction is defined as 0.6–1 mg/kg per day [10]. Hart et al. [39] suggested the usefulness of a step-up approach to treating AIP with azathioprine, 6-mercaptopurine, mycophenolate mofetil, cyclophosphamide or rituximab. Treatment with prednisolone plus cyclophosphamide has not been explored in AIP. In our study we use initial prednisolone fixed-dose (30mg/d) or prednisolone (30mg/d) plus cyclophosphamide (100 mg/d) regimen. We found that the effective rate of prednisolone and prednisolone plus cyclophosphamide was no significant difference [37/40 (92.5%) vs 22/24 (91.7%), $P=0.904$].

Although steroid therapy is effective, but the type I AIP has a high RRs, ranging from 24–63% [19–22]. The Japanese consensus guidelines for AIP recommend re-administration or dose-up of steroid in patients who relapse after successful remission induced by initial steroid therapy [20]. Kazuichi Okazaki et al. [40] reported that most relapsed AIP cases, remission can be achieved with the same prednisolone dose as the initial dose, although it may be necessary to taper more gradually. In our study the relapsed patients achieved the same prednisolone or prednisolone plus cyclophosphamide dose as the initial dose, and most of the patients who relapsed had good results.

Current guidelines recommend low-dose (5 mg/day) maintenance steroid treatment (MST) for 2–3 years to reduce the relapse rate (< 30%) [41]. However, steroid side effects are inevitable, the risk of corticosteroid-associated side effects, as well as the lifetime cumulative steroid dose, must be considered, the short- and long-term corticosteroid treatment may induce side effects, including chronic glycometabolism, obesity, an immunocompromised status against infection, cataracts, glaucoma, osteoporosis, and myopathy [42]. The majority of side effects, including secondary diabetes mellitus and osteoporosis, are treatable and/or preventable. Severe side effects, such as infection, bone fracture, femoral head necrosis and cardiovascular diseases, are life-threatening and should be avoided [41]. In this research the side effects of the 64 medications treatment patients were DM in 8 cases (12.5%); central obesity or moon face in 10 cases (15.6%); hyperlipidemia in 12 cases (18.8%); gastric ulcer in 4

cases (6.3%); osteoporosis in 6 case (9.4%); bone fracture in 1 case (1.6%). For these patients we reduce the dose of prednisolone, and low dose maintenance treatment was performed, furthermore, oral hypoglycemic drugs for DM patients, oral statins for central obesity or moonface and hyperlipidemia patients, oral proton pump inhibitors (PPIs) and gastric mucosal protection drugs for gastric ulcer patients, and oral calcium supplements for osteoporotic patients. For the fracture patient we withdrew prednisolone and operated on fracture, but AIP recurred three months later, and we performed low dose prednisolone maintenance treatment, the effect is also very good.

We acknowledge the study has several limitations. This study is a retrospective study, retrospective analysis may lead to some bias. Additionally, some patients with incomplete information are excluded, which may have some influence on the results. Lastly, China as a high incidence of type Ⅱ AIP countries, the number of cases is not enough, so there may be partial bias. Further multicenter, prospective original studies would provide more precise data to reduce potential confounding results.

Conclusion

In conclusion, the misdiagnosis rate of AIP in china is very high. There was no significant difference between prednisolone and prednisolone plus cyclophosphamide in the treatment of type Ⅱ AIP. RRs is very high, follow-up should be continued after drug withdrawal, and the follow-up time should last more than 3 years. Increasing the dose of prednisolone can be effective on therapy relapse patients. Low dose steroid therapy and expectant treatment are useful when side effects arise from a high dose of steroid.

Declarations

Contributions

Study concepts and design was made by Neng Tang, Liandong Ji; Acquisition of data was made by Xiaolin Dou and Xing You; Quality control of data and algorithms was made by Guodong Liu and Zhenglin Ou; Analysis and interpretation of data was made by Mujing Ke and Xiaoping Yi; Statistical analysis was made by Xiaolin Dou and Guodong Liu; Drafting of the manuscript was made by Neng Tang and Liandong Ji; Critical revision and approval of manuscript was made by Neng Tang and Liandong Ji.

Acknowledgements

None.

Funding

None.

Availability of data and materials

The datasets used or analyzed during the current study are available from the corresponding author on reasonable request.

Informed consent

Written informed consent was obtained from all the patients involved in the study, and all of them consent for publish.

Ethics approval

All procedures performed in studies involving human participants were in accordance with the ethical standards of the institutional and/or national research committee and with the 1964 Helsinki declaration. The study was approved by the Ethics Committee of Xiangya Hospital, Central South University, China (reference: 202011156).

Competing interests

There are no conflicts of interest to report for any of the authors.

References

1. SARLES H, SARLES JC, MURATORE R, GUIEN C: **Chronic inflammatory sclerosis of the pancreas—an autonomous pancreatic disease?** *Am J Dig Dis* 1961, **6**:688-698.
2. Yoshida K, Toki F, Takeuchi T, Watanabe S, Shiratori K, Hayashi N: **Chronic pancreatitis caused by an autoimmune abnormality. Proposal of the concept of autoimmune pancreatitis.** *Dig Dis Sci* 1995, **40**:1561-1568.
3. Nishimori I, Tamakoshi A, Otsuki M: **Prevalence of autoimmune pancreatitis in Japan from a nationwide survey in 2002.** *J Gastroenterol* 2007, **42 Suppl 18**:6-8.
4. Masamune A, Kikuta K, Hamada S, Tsuji I, Takeyama Y, Shimosegawa T, Okazaki K: **Nationwide epidemiological survey of autoimmune pancreatitis in Japan in 2016.** *J Gastroenterol* 2020, **55**:462-470.
5. Allaparthi S, Sageer M, Sterling MJ: **Deciphering autoimmune pancreatitis, a great mimicker: case report and review of the literature.** *Case Rep Gastrointest Med* 2015, **2015**:924532.
6. Chari ST, Kloeppel G, Zhang L, Notohara K, Lerch MM, Shimosegawa T: **Histopathologic and clinical subtypes of autoimmune pancreatitis: the Honolulu consensus document.** *Pancreas* 2010, **39**:549-554.
7. Kloppel G, Detlefsen S, Chari ST, Longnecker DS, Zamboni G: **Autoimmune pancreatitis: the clinicopathological characteristics of the subtype with granulocytic epithelial lesions.** *J Gastroenterol* 2010, **45**:787-793.
8. Ishikawa T, Itoh A, Kawashima H, Ohno E, Itoh Y, Nakamura Y, Hiramatsu T, Miyahara R, Ohmiya N, Haruta J, et al: **Peripancreatic vascular involvements of autoimmune pancreatitis.** *J Gastroenterol*

Hepatol 2012, **27**:1790-1795.

9. Kaji R, Takedatsu H, Okabe Y, Ishida Y, Sugiyama G, Yonemoto K, Mitsuyama K, Tsuruta O, Sata M: **Serum immunoglobulin G4 associated with number and distribution of extrapancreatic lesions in type 1 autoimmune pancreatitis patients.** *J Gastroenterol Hepatol* 2012, **27**:268-272.
10. Shimosegawa T, Chari ST, Frulloni L, Kamisawa T, Kawa S, Mino-Kenudson M, Kim MH, Kloppel G, Lerch MM, Lohr M, et al: **International consensus diagnostic criteria for autoimmune pancreatitis: guidelines of the International Association of Pancreatology.** *Pancreas* 2011, **40**:352-358.
11. Chari ST, Smyrk TC, Levy MJ, Topazian MD, Takahashi N, Zhang L, Clain JE, Pearson RK, Petersen BT, Vege SS, Farnell MB: **Diagnosis of autoimmune pancreatitis: the Mayo Clinic experience.** *Clin Gastroenterol Hepatol* 2006, **4**:1010-1016, 934.
12. Chari ST, Takahashi N, Levy MJ, Smyrk TC, Clain JE, Pearson RK, Petersen BT, Topazian MA, Vege SS: **A diagnostic strategy to distinguish autoimmune pancreatitis from pancreatic cancer.** *Clin Gastroenterol Hepatol* 2009, **7**:1097-1103.
13. Otsuki M, Chung JB, Okazaki K, Kim MH, Kamisawa T, Kawa S, Park SW, Shimosegawa T, Lee K, Ito T, et al: **Asian diagnostic criteria for autoimmune pancreatitis: consensus of the Japan-Korea Symposium on Autoimmune Pancreatitis.** *J Gastroenterol* 2008, **43**:403-408.
14. Frulloni L, Scattolini C, Falconi M, Zamboni G, Capelli P, Manfredi R, Graziani R, D'Onofrio M, Katsotourchi AM, Amodio A, et al: **Autoimmune pancreatitis: differences between the focal and diffuse forms in 87 patients.** *Am J Gastroenterol* 2009, **104**:2288-2294.
15. Lopez-Serrano A, Crespo J, Pascual I, Salord S, Bolado F, Del-Pozo-Garcia AJ, Ilzarbe L, De-Madaria E, Moreno-Osset E: **Diagnosis, treatment and long-term outcomes of autoimmune pancreatitis in Spain based on the International Consensus Diagnostic Criteria: A multi-centre study.** *Pancreatol* 2016, **16**:382-390.
16. Matsubayashi H, Kakushima N, Takizawa K, Tanaka M, Imai K, Hotta K, Ono H: **Diagnosis of autoimmune pancreatitis.** *World J Gastroenterol* 2014, **20**:16559-16569.
17. Sah RP, Chari ST: **Autoimmune pancreatitis: an update on classification, diagnosis, natural history and management.** *Curr Gastroenterol Rep* 2012, **14**:95-105.
18. Ghazale A, Chari ST, Smyrk TC, Levy MJ, Topazian MD, Takahashi N, Clain JE, Pearson RK, Pelaez-Luna M, Petersen BT, et al: **Value of serum IgG4 in the diagnosis of autoimmune pancreatitis and in distinguishing it from pancreatic cancer.** *Am J Gastroenterol* 2007, **102**:1646-1653.
19. Hart PA, Kamisawa T, Brugge WR, Chung JB, Culver EL, Czako L, Frulloni L, Go VL, Gress TM, Kim MH, et al: **Long-term outcomes of autoimmune pancreatitis: a multicentre, international analysis.** *Gut* 2013, **62**:1771-1776.
20. Kamisawa T, Okazaki K, Kawa S, Ito T, Inui K, Irie H, Nishino T, Notohara K, Nishimori I, Tanaka S, et al: **Amendment of the Japanese Consensus Guidelines for Autoimmune Pancreatitis, 2013 III. Treatment and prognosis of autoimmune pancreatitis.** *J Gastroenterol* 2014, **49**:961-970.
21. Maruyama M, Watanabe T, Kanai K, Oguchi T, Asano J, Ito T, Ozaki Y, Muraki T, Hamano H, Arakura N, Kawa S: **Autoimmune pancreatitis can develop into chronic pancreatitis.** *Orphanet J Rare Dis* 2014,

22. Lee HW, Moon SH, Kim MH, Cho DH, Jun JH, Nam K, Song TJ, Park DH, Lee SS, Seo DW, Lee SK: **Relapse rate and predictors of relapse in a large single center cohort of type 1 autoimmune pancreatitis: long-term follow-up results after steroid therapy with short-duration maintenance treatment.** *J Gastroenterol* 2018, **53**:967-977.
23. Shimizu S, Naitoh I, Nakazawa T, Hayashi K, Miyabe K, Kondo H, Nishi Y, Yoshida M, Umemura S, Hori Y, et al: **Correlation between long-term outcome and steroid therapy in type 1 autoimmune pancreatitis: relapse, malignancy and side effect of steroid.** *Scand J Gastroenterol* 2015, **50**:1411-1418.
24. van Staa TP, Leufkens HG, Cooper C: **The epidemiology of corticosteroid-induced osteoporosis: a meta-analysis.** *Osteoporos Int* 2002, **13**:777-787.
25. Suzuki Y, Nawata H, Soen S, Fujiwara S, Nakayama H, Tanaka I, Ozono K, Sagawa A, Takayanagi R, Tanaka H, et al: **Guidelines on the management and treatment of glucocorticoid-induced osteoporosis of the Japanese Society for Bone and Mineral Research: 2014 update.** *J Bone Miner Metab* 2014, **32**:337-350.
26. Weinstein RS: **Glucocorticoid-induced osteonecrosis.** *Endocrine* 2012, **41**:183-190.
27. Wolfe F, Caplan L, Michaud K: **Treatment for rheumatoid arthritis and the risk of hospitalization for pneumonia: associations with prednisone, disease-modifying antirheumatic drugs, and anti-tumor necrosis factor therapy.** *Arthritis Rheum* 2006, **54**:628-634.
28. Kanis JA, Johansson H, Oden A, Johnell O, de Laet C, Melton IL, Tenenhouse A, Reeve J, Silman AJ, Pols HA, et al: **A meta-analysis of prior corticosteroid use and fracture risk.** *J Bone Miner Res* 2004, **19**:893-899.
29. Curtis JR, Xie F, Chen L, Spettell C, McMahan RM, Fernandes J, Delzell E: **The incidence of gastrointestinal perforations among rheumatoid arthritis patients.** *Arthritis Rheum* 2011, **63**:346-351.
30. Vujasinovic M, Valente R, Maier P, von Beckerath V, Haas SL, Arnelo U, Del CM, Kartalis N, Pozzi-Mucelli RM, Fernandez-Moro C, et al: **Diagnosis, treatment and long-term outcome of autoimmune pancreatitis in Sweden.** *Pancreatology* 2018, **18**:900-904.
31. Sahani DV, Kalva SP, Farrell J, Maher MM, Saini S, Mueller PR, Lauwers GY, Fernandez CD, Warshaw AL, Simeone JF: **Autoimmune pancreatitis: imaging features.** *Radiology* 2004, **233**:345-352.
32. Kloppel G, Luttges J, Sipos B, Capelli P, Zamboni G: **Autoimmune pancreatitis: pathological findings.** *JOP* 2005, **6**:97-101.
33. van Heerde MJ, Buijs J, Hansen BE, de Waart M, van Eijck CH, Kazemier G, Pek CJ, Poley JW, Bruno MJ, Kuipers EJ, van Buuren HR: **Serum level of Ca 19-9 increases ability of IgG4 test to distinguish patients with autoimmune pancreatitis from those with pancreatic carcinoma.** *Dig Dis Sci* 2014, **59**:1322-1329.
34. Mauch M, Blank W, Kunze G, Dirks K, Schuler A, Klinggraff VG, Seitz K: **Importance of Abdominal Ultrasound in 17 Patients with Histologically Confirmed Autoimmune Pancreatitis (AIP).** *Ultraschall Med* 2015, **36**:248-254.

35. Finkelberg DL, Sahani D, Deshpande V, Brugge WR: **Autoimmune pancreatitis. *N Engl J Med* 2006, 355:2670-2676.**
36. Kamisawa T, Chari ST, Lerch MM, Kim MH, Gress TM, Shimosegawa T: **Recent advances in autoimmune pancreatitis: type 1 and type 2. *Gut* 2013, 62:1373-1380.**
37. Kamisawa T, Shimosegawa T, Okazaki K, Nishino T, Watanabe H, Kanno A, Okumura F, Nishikawa T, Kobayashi K, Ichiya T, et al: **Standard steroid treatment for autoimmune pancreatitis. *Gut* 2009, 58:1504-1507.**
38. Kamisawa T, Okazaki K, Kawa S, Shimosegawa T, Tanaka M: **Japanese consensus guidelines for management of autoimmune pancreatitis: III. Treatment and prognosis of AIP. *J Gastroenterol* 2010, 45:471-477.**
39. Hart PA, Topazian MD, Witzig TE, Clain JE, Gleeson FC, Klebig RR, Levy MJ, Pearson RK, Petersen BT, Smyrk TC, et al: **Treatment of relapsing autoimmune pancreatitis with immunomodulators and rituximab: the Mayo Clinic experience. *Gut* 2013, 62:1607-1615.**
40. Okazaki K, Chari ST, Frulloni L, Lerch MM, Kamisawa T, Kawa S, Kim MH, Levy P, Masamune A, Webster G, Shimosegawa T: **International consensus for the treatment of autoimmune pancreatitis. *Pancreatology* 2017, 17:1-6.**
41. Kubota K, Kamisawa T, Okazaki K, Kawa S, Hirano K, Hirooka Y, Uchida K, Shiomi H, Ohara H, Shimizu K, et al: **Low-dose maintenance steroid treatment could reduce the relapse rate in patients with type 1 autoimmune pancreatitis: a long-term Japanese multicenter analysis of 510 patients. *J Gastroenterol* 2017, 52:955-964.**
42. Matsubayashi H, Ishiwatari H, Imai K, Kishida Y, Ito S, Hotta K, Yabuuchi Y, Yoshida M, Kakushima N, Takizawa K, et al: **Steroid Therapy and Steroid Response in Autoimmune Pancreatitis. *Int J Mol Sci* 2019, 21.**

Tables

Table 1

Patients' characteristics

Characteristics	Total(n=82)
Age, years (mean \pm SD)	53.4 \pm 11.2
Sex (n,%)	
Female	22 (26.8)
Male	60 (73.2)
Initial presentation (n, %)	
Jaundice	49 (59.8)
Abdominal pain	40 (48.8)
Weight loss	24 (29.3)
No	4 (4.9)
OOI	51 (62.2)
Site of OOI (n, %)	
Proximal bile duct	32 (39.0)
Salivary/lacrimal gland	20 (24.4)
Kidney	12 (14.6)
Lymph gland	8 (9.8)
Diabetes Mellitus (n, %)	
Yes	20 (24.4)
No	62 (75.6)

Table 2

Serological results and radiographic results

Results	Total(n=82)
Serological	
Liver function (n,%)	
Elevated BIL	49 (59.8%)
Elevated ALT	52 (63.4%)
Elevated AST	51 (62.2%)
Elevated blood amylase (n,%)	
Yes	5 (6.1%)
No	36 (43.6%)
Miss	41 (50.0%)
Elevated CA19-9 (n,%)	
Yes	9 (10.9)
No	69 (84.2)
Miss	4 (4.9)
Elevated IgG (n, %)	
Yes	62 (75.6)
No	10 (12.2)
Miss	10 (12.2)
Elevated IgG4 (n,%)	
Yes	56 (68.3)
No	6 (7.3)
Miss	20 (24.4)
Elevated ANA (n,%)	
Yes	18(22.0%)
No	23(28.0%)
Miss	41(50.0%)
Radiographic	
CT (n, %)	

Yes	58 (70.7)
No	22 (26.8)
Miss	2 (2.5)
MRCP (n, %)	
Yes	25 (30.5)
No	25 (30.5)
Miss	32 (39.0)
Pancreatic imaging (n, %)	
Diffuse swelling	28 (34.1)
Focal swelling	52 (63.4)
Miss	2 (2.5)

Table 3

Therapeutic effect between prednisolone and prednisolone plus cyclophosphamide

Characteristics	prednisolone (n=40)	prednisolone plus cyclophosphamide (n=24)	P-value
Therapeutic effect			
Effective(n, %)	34(85.0%)	21(87.5%)	
Ineffective(n, %)	6(15.0%)	3(12.5%)	0.781 ^P
Relapse	14(35.0%)	7(29.2%)	0.630 ^P

P: Pearson chi-square test

Figures

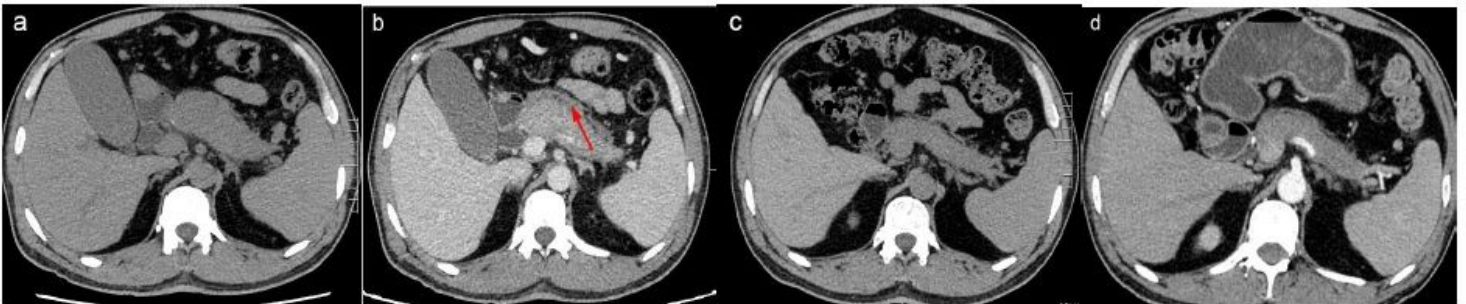


Figure 1

Pancreatic imaging findings of diffuse enlargement AIP. a. Diffuse pancreas enlargement, reduced in parenchymal density, becoming "Sausage-like". b. Uniform pancreas, delayed enhancement, pancreatic pericardium-like margin (as indicated by the arrow). c. After the treatment with steroid, the pancreatic parenchyma was significantly reduced, the pancreatic density was slightly higher than before. d. After the treatment, the pancreatic parenchyma was evenly intensified, and the surrounding clearance was clear, restoring the feather-like structure.

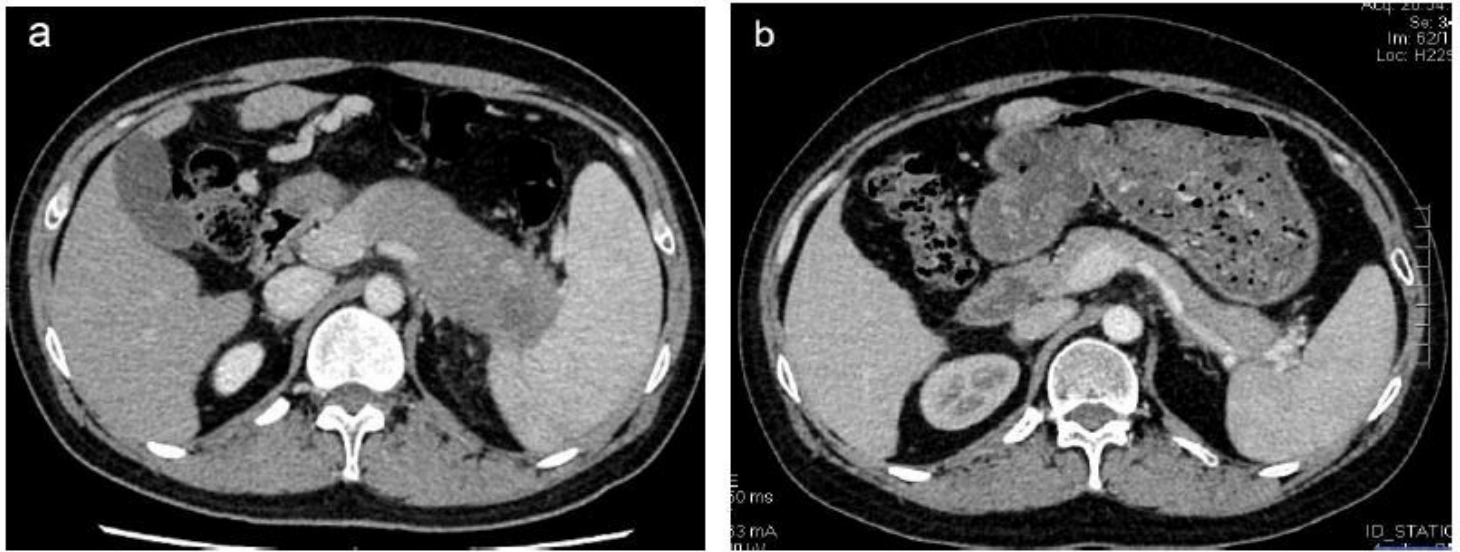


Figure 2

Pancreatic imaging findings of focal pancreatic enlargement AIP. a. Low-density lump in the tail of the pancreas, uniform and delayed strengthening b. The tail of the pancreas is significantly reduced after treatment with steroid, uniformly strengthened, and the surrounding structure is clear.

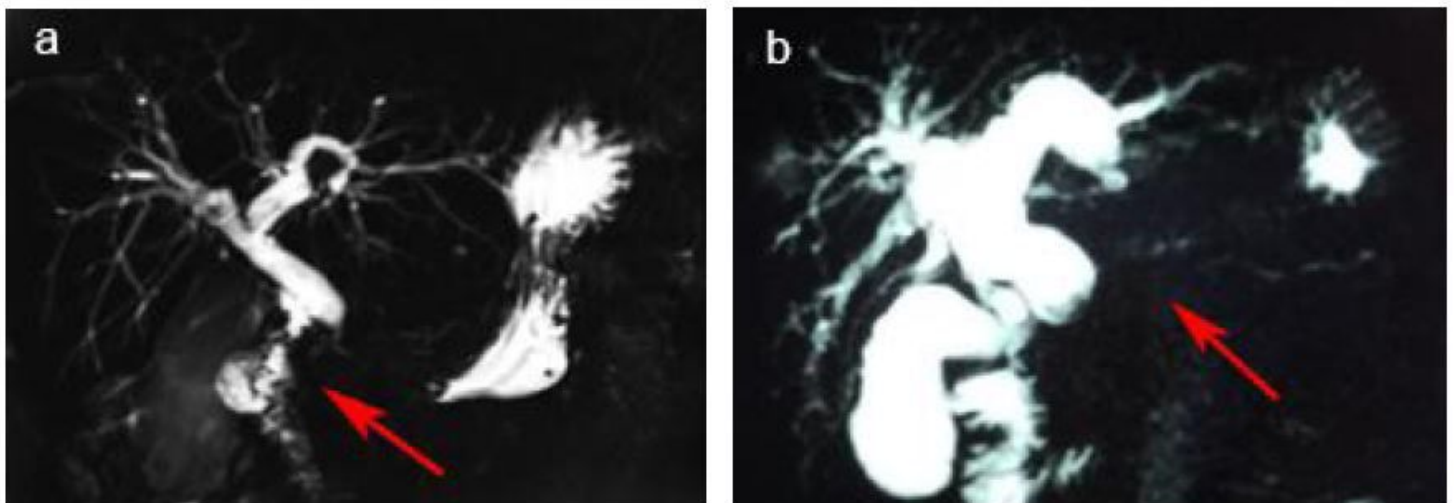


Figure 3

MRCP findings of AIP. a.b. Intrahepatic and extrahepatic bile ducts dilate, the main pancreatic duct is irregularly narrowed (as indicated by the red arrows).

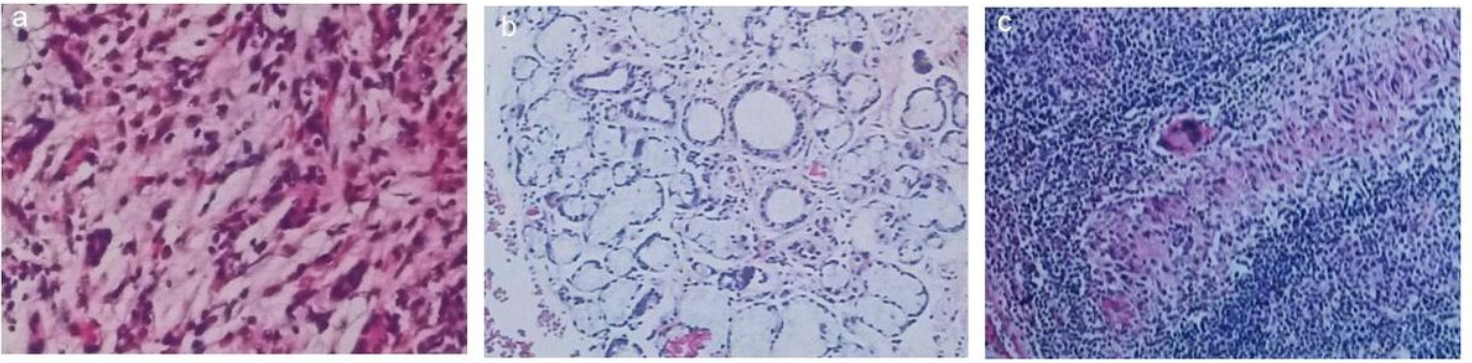


Figure 4

Histological features of AIP and OOIs. a. Pathological examination of pancreatic showed acinar atrophy, massive plasma cells and lymphocytes infiltration, fibrous tissue hyperplasia. b. Pathological examination of salivary gland showed partial acinar atrophy, a large number of plasma cells and lymphocytes infiltration. c. Pathological examination results of lymph nodes showed lymphoid tissue hyperplasia, structural disorder, massive plasma cell proliferation, a large number of dendritic cell proliferation in follicles.