

Early Surgical Intervention for Active Thoracic Spinal Tuberculosis with Paraparesis and Paraplegia

Weiwei Li

Xiangya Hospital Central South University

Zheng Liu

Xiangya Hospital Central South University

Xiao Xiao

Xiangya Hospital Central South University

Zhenchao Xu

Xiangya Hospital Central South University

Zhicheng Sun

Xiangya Hospital Central South University

Zhen Zhang

Xiangya Hospital Central South University

Xiyang Wang (✉ wqlwqwxxy@163.com)

Xiangya Hospital Central South University Department of Spinal Surgery <https://orcid.org/0000-0003-1942-7517>

Research article

Keywords: Spinal tuberculosis, Thoracic, Early; Surgical, Paraparesis, Paraplegia

Posted Date: October 29th, 2020

DOI: <https://doi.org/10.21203/rs.3.rs-48848/v2>

License:  This work is licensed under a Creative Commons Attribution 4.0 International License.

[Read Full License](#)

Version of Record: A version of this preprint was published on February 21st, 2021. See the published version at <https://doi.org/10.1186/s12891-021-04078-y>.

Abstract

Background: To explore the therapeutic effect of early surgical interventions for patients of active thoracic spinal tuberculosis (TB) with paraparesis and paraplegia.

Methods: Data of 118 patients with active thoracic spinal TB and paraparesis and paraplegia who had undergone surgeries at an early stage (within three weeks of paraparesis and paraplegia) from January 2008 to December 2014 were retrospectively analyzed. The operation duration, blood loss, perioperative complication rate, VAS score, ASIA grade of neurological status, Erythrocyte Sedimentation Rate (ESR), C-reactive protein (CRP), kyphotic Cobb's angle, and duration of bone graft fusion were analyzed to evaluate the therapeutic effects.

Results: Mean operation time was 194.2 minutes, mean blood loss was 871.2 ml. The perioperative complication rate was 5.1%. Mean preoperative VAS score was 5.3, significantly decreased to 3.2 after operation, and continued decreasing to 1.1 at the follow up ($P \leq 0.05$). All cases achieved at least one grade elevation after operation, specifically, 2 cases of ASIA grade A rose to grade B, 10 cases of ASIA grade A rose to grade C, 2 cases of ASIA grade A rose to grade E; 9 cases of ASIA grade B rose to grade D, 38 cases of ASIA grade B rose to grade E; all 57 cases of ASIA grade C rose to ASIA grade E. The rate of full neurological recovery for patients with paraplegia was 14.3%, significantly lower than the rate (91.3%) for patients with paraparesis. Mean preoperative ESR and CRP were 73.1 mm /h and 82.4 mg/L, insignificantly increased after operation ($P \leq 0.05$), then gradually decreased to 11.5 ± 1.8 mm /h and 2.6 ± 0.82 mg/L at the final follow up, respectively ($P \leq 0.05$). The mean preoperative kyphotic Cobb's angle was 21.9° , significantly decreased to 6.5° after operation ($P \leq 0.05$) and the kyphotic correction had not lost during the follow up ($P \leq 0.05$). Mean duration of bone graft fusion was 8.6 ± 1.3 months

Conclusion: Early surgical intervention may be beneficial for patients with active thoracic spinal TB and paraparesis or paraplegia, with surgical intervention being more beneficial for paraparesis recovery compared with paraplegia recovery.

Background

Tuberculosis (TB) is an infectious disease caused by mycobacterium TB (MTB), and its prevalence depends on local economic, hygienic and medical conditions. TB is found worldwide, but is mainly prevalent in developing and undeveloped countries, such as India, China and certain African countries. According to the global TB report published in 2019, the incidence of TB in developed countries was 24 to 32 per 100,000 individuals, and 35 to 866 per 100,000 in developing countries [1]. The organ mostly affected by MTB is the lung, and may cause cough, expectoration, thoracalgia, hemoptysis, fever and certain symptoms of exhaustion. If the lung lesion is not well controlled, other organs may be affected. Spinal TB is the one of most common extrapulmonary types of TB and is mainly caused by MTB in the primary lung lesion, which is transmitted through Batson plexus [2].

Spinal TB can destroy the vertebral body, discs and paravertebral soft tissue, which results in the production of caseous necrotic tissue, pus and dead bone, which can enter into the spinal canal and cause spinal cord compression that may result paraparesis and even paraplegia. Kotil et al. reported that most cases of spinal TB can be cured using anti-TB drug chemotherapy [3]. However, the blind pursuit of anti-TB drug chemotherapy while neglecting surgical intervention may easily lead to incurable paraplegia and severe kyphotic deformity. Thus, surgical interventions are recommended for patients with spinal TB complicated by spinal instability, spinal cord compression, sequestration, paravertebral abscess and sinus formation.

According to the report by Velayutham et al., spinal TB is one of the ten most common diseases that cause disability in Indians [4]. In China, the number of new cases of spinal TB is at a constantly high level, which badly damages the physical and mental health of patients, while placing a huge economic burden on their families and society as a whole. Spinal TB can occur in any part of the spine. For children and adolescents, the most affected site is thoracic spine, while for adults, the most affected site is the lumbar spine. Due to the narrow space of thoracic spinal canal and poor blood supply in the thoracic spinal cord, paralysis can easily occur in patients of thoracic spinal TB if treatment is not administered in a timely manner or if incorrect treatment is administered [5]. The purpose of active thoracic spinal TB surgery for patients with paraparesis and paraplegia is the removal of local lesions, relief from spinal cord compression, and reconstruction for normal and durable alignment of spine, while the time taken to decide on the surgical intervention to be used is an important factor for a successful operation, because hasty surgery may cause TB to spread, while a delay may result in paraparesis exacerbation or irreparable paraplegia [6].

Materials And Methods

Inclusion criteria were 1) Case of definite spinal TB, defined as the patients with confirmed positive MTB culture or typical TB caseous necrosis and granuloma; 2) Surgical intervention was carried out within three weeks of onset of paraparesis and paraplegia; 3) Follow-up period were more than 12 months. Exclusion criteria were 1) Cases who have badly injured hepatic function; 2) Cases who can ambulate without the aid of stick; 3) Cases concurrent with other disorders which may impair the motor or sensational function of lower extremities; 4) Cases with systemic TB. From January 2008 to December 2014, a total of 118 consecutive patients with definite spinal TB and concurrent neurological deficit were enrolled in this study. The patients included 75 males and 43 females, with an average age of 32.0 ± 9.9 years (14-63 years). The duration of neurological deficit ranged from 1 to 21 days, with a mean of 6.3 ± 4.9 days. Blood routine (BR), Erythrocyte Sedimentation Rate (ESR), C-reactive protein (CRP) and T-cell spot test for TB infection were used for diagnosis. Pulmonary CT scan, sputum smear and culture were used to exclude active systematic TB patients. X-rays, CT scans and magnetic resonance (MR) of the affected spine area were examined to determine the location, severity and extent of the lesion. The lesion site distribution among the patients was as follows: 24 cases in the upper thoracic (T1-T4), 42 cases in the middle thoracic (T5-T9) and 52 cases in the thoracolumbar (T10-T12). 79 cases involved one diseased function spinal unit (FSU), 25 cases involved two FSUs, and 14 cases involved 3 or more FSUs.

The neurological status distribution among the patients using American Spinal Cord Injury Association (ASIA) evaluation system was as follows: 14 cases of grade A, 47 cases of grade B, and 57 cases of grade C. All patients presented with varying degrees of back pain, which lasted from 1 to 28 months, with an average of 8.1 ± 5.3 months. 73 cases (61.9%) manifested typical TB toxic symptoms, such as low afternoon fever, night sweats and fatigue. All cases presented with paravertebral abscess, vertebral collapse and sequestra formation as observed in the CT scans. Spinal cord compression was observed in all cases and no abnormal signal intensity of the spinal cord was observed through the MRI examination. Confirmation of TB infection depended on postoperative typical histopathological presentation or MTB culture. The mean preoperative Visual Analog Scale (VAS) score was 5.3 ± 1.7 (range, 3-7). The mean preoperative ESR and CRP value were 73.1 ± 12.4 mm/h (range, 30-101 mm/h) and 82.4 ± 15.6 (36-110 mg/L), respectively. The mean preoperative kyphotic Cobb's angle was $21.9^\circ \pm 4.6^\circ$ (range, 8° - 35°). Surgical interventions were all administered within 3 weeks of paralysis. Ethical approval was obtained from the Ethics Committee of Xiangya Hospital affiliated to Central South University, and informed consent was obtained from all patients before undergoing the technique.

Preparation for surgery

All patients received standard quadruple anti-TB drug therapy (0.3 g of Isoniazid per day, 0.45 g of Rifampicin per day, 0.75 g of Pyrazinamide per day, 0.75 g of Ethambutol per day) combined with antibiotics of levofloxacin (0.4 g per day) and streptomycin (0.57 g per day). The duration of the anti-TB drug treatment was at least two weeks if neurological function did not deteriorate. However, if the neurological status was deteriorating, emergency surgery was carried out immediately. Anemia and hypoproteinemia were treated before surgery. Cefuroxime (intravenous drip, 1.5 g) or Cefazolin (intravenous drip, 1.5 g) was administered 30 minutes before surgery.

Procedure

One stage posterior spinal cord decompression, lesion removal, interbody fusion and pedicle fixation, or posterior spinal cord decompression, pedicle fixation combined with two stage anterior debridement and interbody fusion were chosen based on the location of the lesion and size of the paravertebral abscess. The key technical steps for one stage posterior surgery were as follows: pedicle screws were placed in the normal vertebrae, and the fixation range included the diseased area and 1-2 upper and lower normal FSUs; laminectomy and pedicle resection were executed for facilitating spinal cord decompression and removal of necrotic discs, caseous abscess and sequestra. The paravertebral abscesses in the unseen view was flushed and drained using a catheter. An iliac allograft was placed in the intervertebral space, and the autogenous bone fragments from normal spinous processes and laminae were used for interbody fusion of the remaining intervertebral space. The key technical steps for posterior spinal cord decompression, pedicle fixation combined with two stage anterior debridement and interbody fusion were as follows: the key techniques for the posterior approach were similar to that of the single posterior surgery mentioned above, without the pedicle resection and interbody grafts. The two stage anterior approach was implemented one week after the posterior approach. Single lung ventilation was used

during operation, and the lesion was accessed via extrapleural or transthoracic approach. An iliac allograft block was placed in the intervertebral space after complete debridement, and closed chest drainage was conducted at the end of the surgery. Fig.1 and 2

Postoperative care

Temperature and lower extremity movement were closely monitored. The same anti-infection protocol was used for 24-48 hours. The drainage tube was removed after the volume of drainage was less than 20 ml/24 h. Mild activity out of bed was advocated under the protection of a thoracolumbar brace after drainage removal. Physical activity was gradually increased and the brace support was used for at least 3 months. The first 4 postoperative weeks of anti-TB protocol after operation were the same as preoperative anti-TB protocol. The subsequent anti-TB scheme used was standard quadruple anti-TB drugs therapy and the duration was 12 to 18 months.

Follow-ups and efficacy evaluative indexes

Follow-up visits were mainly conducted at outpatient clinics. The follow-up indices included operation duration, intraoperative blood loss, perioperative complication rate, symptoms (TB toxic symptoms and VAS score for back pain), neurological status (ASIA grade), clinical lab index (ESR and CRP), kyphotic Cobb's angle and time of bone graft fusion. The follow-up interval was 3 months within the first year after operation, 6 months within the second year after operation and one year from the second year after operation.

Results

All patients were followed up for at least 12 months, with an average of 28.0 ± 10.0 months (range, 12–60 months). No perioperative TB systematic dissemination and mortality were observed in any of the patients during the hospitalization and subsequent follow-up period. All surgeries were carried out successfully without intraoperative iatrogenic neural and vascular injury. 92 cases underwent one stage posterior surgery and 26 cases underwent posterior decompression and fixation combined with two stage anterior debridement and interbody fusion. Two cases which underwent a revision surgery of anterior debridement because of the long existence of paravertebral abscess after a single posterior approach (2/92, 2.2%), while all other cases healed smoothly during a single stage. The mean duration of surgery was 194.2 ± 48.2 min (range, 120-360 min) and the mean blood loss was 871.2 ± 161.2 ml (range, 600–1500 ml). During the hospitalization period, one case was complicated with pleural rupture, five cases were complicated with dura tear and cerebrospinal fluid leak, while one case was complicated with superficial wound infection, resulting in a perioperative complication rate of 5.9%. All TB toxic symptoms disappeared 3 months after operation. The VAS score of back pain were significantly relieved after operation (3.2 ± 1.3 , range 2-4) ($P < 0.05$), and continued improving gradually, the mean VAS score at final follow-up was 1.1 ± 0.53 (range 0-3), significantly lower than the postoperative score ($P < 0.05$). The neurological status improvement was as follows: 2 cases of ASIA grade A rose to grade B, 10 cases of ASIA grade A rose to grade C, 2 cases of ASIA grade A rose to grade E; 9 cases of ASIA grade B rose to

grade D, 38 cases of ASIA grade B rose to grade E; all cases of ASIA grade C rose to ASIA grade E. The full recovery rate for paraplegia (ASIA grade A) was 14.3%, and the full recovery rate for paraparesis (ASIA grade B, C and D) was 91.3%. The difference of full neurological function recovery rate between patients of paraparesis and paraplegia was significant ($P \leq 0.05$). The value of ESR and CRP was 74.8 ± 10.8 mm/h and 83.6 ± 13.4 mg/L after operation, insignificantly higher than the corresponding preoperative indexes ($P > 0.05$), and decreased gradually to the normal level within 6 months, mean ESR and CRP values at the final follow up were 11.5 ± 1.8 mm/h and 2.6 ± 0.82 mg/L, respectively, significantly lower than the corresponding preoperative indexes ($P \leq 0.05$). Postoperatively, kyphotic Cobb's angle $6.5^\circ \pm 2.1^\circ$ (range, 0° - 12°) was found to have been significantly corrected ($P \leq 0.05$), compared with the preoperative status and correction had not lost during the follow-up period ($P \leq 0.05$). The mean duration of bone graft fusion was 8.6 ± 1.3 months (range, 6-14 months). (Table 1, 2, 3).

Discussion

Paraparesis and paraplegia is the most serious complication of spinal TB, mainly due to direct mechanical spinal cord compression as a result of an expanding abscess, caseous necrotic material, TB granulation tissue and bony elements [7]. Other mechanisms, such as instability, meningitis, infective thrombosis of spinal vessels and some adverse changes in the spinal cord have also been implicated for the worsening of neurological status [8]. The classification for paraparesis and paraplegia in spinal TB includes early onset paraparesis and paraplegia (active spinal TB) and late onset paraparesis and paraplegia (healed spinal TB), as proposed by Hodgson et al. [9]. Early onset paraparesis and paraplegia for spinal TB is mainly caused by soft pressure (pus, caseous necrotic tissue and tuberculous granuloma) of the spinal cord resulting in slow, continuous and gradual compression. Late onset paraparesis and paraplegia for spinal TB is mainly caused by rigid pressure (kyphotic bone ridge, granulomatous scar and contracture) [10]. All cases included in our series are early onset paraparesis and paraplegia patients, as determined through radiological presentation and operation findings, with the materials which caused spinal cord compression in our series mainly being soft materials, such as fluid pus, proliferous granuloma and osteolytic bony destruction. Therefore, this finding is consistent with that of previous literature reports. Due to the short period of spinal cord disturbance, no signals of spinal cord denaturation, necrosis and malacia were detected through MR examination. However, epidural adhesion was identified in most patients, resulting in a higher rate of dural tears and cerebrospinal fluid leak.

Paraparesis and paraplegia as a result of spinal TB can be cured or improved. Some scholars have suggested that early onset paraparesis and paraplegia can be cured through conservative anti-TB drugs management because the spinal cord pressure is soft and is easily absorbed under effective anti-TB drugs treatment [11]. However, many experts deemed that irreparable damage to neurological impairment may occur as a result of long periods of anti-TB drug conservative treatment. Therefore, surgical intervention needs to be administered only when suitable [12, 13]. The principle of surgical intervention is to effectively and safely relieve neural pressure, maximizing the decrease of the infectious burden, and reconstructing spinal stability, while minimizing damage to the physical body. Until now, the timing of surgical intervention suitable for paraparesis and paraplegia of spinal TB has been disputed [14]. Batirel

et al. [15] believed that paraplegia caused by spinal TB is a slowly developing process, and a short delay in surgical decompression may not change the final level of recovery of neurological function. Wang et al. [16] and Chandra et al. [17] considered a period of 2-4 weeks of normal quadruple anti-TB drug treatment before operation is advocated, but stated that emergency operation is needed as neurological impairment progresses. Zhang et al. [18] stated that surgery can be performed after a significant decrease of ESR and CRP has been observed. Jia et al. [19] conducted a study of comparison of early (<4 weeks) and non-early surgery (≥ 4 weeks) for the therapy of spinal TB with neurological deficit, they found early surgical management is recommended because of superior improvement of neurological status in the early surgery group. For our series, early operation was defined as operation carried out within 3 weeks of paraparesis and paraplegia. We found significant neurological function improvement together with other positive indexes after early surgery.

This study sample included 104 cases of paraparesis, of which 95 cases (91.3%) fully recovered, and 14 cases of paraplegia, of which only 2 cases (14.3%) fully recovered. The cure rate of paraparesis was significantly higher than that of paraplegia. Some experts have been concerned that early surgical intervention may lead to systemic TB dissemination. In our series, insignificant elevation of ESR and CRP values were transiently observed after surgery, and no cases of disseminated TB were observed during the hospitalization period and subsequent follow up. Anterior approach is commonly used in spinal TB and has some merit for debridement and interbody fusion; however, it is less accessible for spinal canal decompression according to some authors including us [20]. Li et al. [21] reported that effect of single anterior debridement decompression, autogenous rib grafts, and instrumentation are good for spinal TB. Varatharajah et al. [22] reported that anterior surgery is beneficial for debridement and kyphosis correction, but results in low maintainability of kyphosis correction. A single posterior approach is mainly used for treating spinal degenerative diseases.

In recent years, many scholars have reported of successful results from single posterior surgery for spinal TB. For patients with spinal TB and paraparesis or paraplegia, spinal cord decompression is more accessible through a posterior approach, thus the single posterior approach is a suitable choice for cases of spinal TB and paraparesis or paraplegia with small prevertebral abscesses [23]. Ukunda et al. [24] found that the posterior-only surgical approach is advantageous for kyphosis correction and disability improvement. Zhang et al. [25] reported that posterior debridement, fixation and interbody fusion are safe and effective methods for patients with upper thoracic spinal TB. In our series, most cases (78%) received a single posterior approach and the relapse rate was very low (2.2%). Therefore, the therapeutic effect of the single posterior approach for spinal TB paraparesis and paraplegia was found to be excellent. For cases with large prevertebral abscesses, the procedure of posterior decompression and fixation combined with two stage anterior debridement and interbody fusion was chosen, and no cases of relapse were reported during the follow-up period. Therefore, we believe that a preoperative CT scan or MRI is essential for choosing the appropriate method of surgery. Additionally, we considered that a postoperative CT scan or MRI is also important for deciding whether two stage anterior surgery is necessary or not. If the paravertebral pus has not been cleared and drained well after single posterior surgery, then an additional two-stage anterior debridement was advocated due to decreased probability of TB relapse and faster

healing of TB lesions [26, 27]. Kyphotic correction is also an important index for therapeutic evaluation, and in this study, significant correction of kyphotic Cobb's angle was achieved after operation and good alignment was maintained during the follow-up period. Therefore, early surgical intervention is not only results in faster neurological recovery but can also achieve excellent kyphotic correction and sustainment.

This study has some innate limitations. It is not a prospective study, and therefore did not include a control cases and included only a small number of cases. Therefore, the conclusion need to be verified through further studies.

Conclusions

Early surgical intervention may be beneficial for patients with active thoracic spinal TB and paraparesis or paraplegia, with surgical intervention being more beneficial for paraparesis recovery compared with paraplegia recovery.

Abbreviations

TB: Tuberculosis; MTB: Mycobacterium TB; BR: Blood Routine; ESR: Erythrocyte Sedimentation Rate; CRP: C-reactive protein; MR: Magnetic Resonance; FSU: Function Spinal Unit; ASIA: American Spinal Cord Injury Association; VAS: Visual Analog Scale;

Declarations

Ethics approval and consent to participate

Ethical approval from the Ethics Committee of Xiangya Hospital affiliated to Central South University was obtained for this study. Each author certifies that all investigations were conducted in conformity with ethical principles. Written informed consent was obtained from all participants.

Consent to publish

All patients signed informed consent forms to publish their personal details in this article

Availability of data and materials

The datasets supporting the conclusions of this article are included within the article. The raw data can be requested from the corresponding author on reasonable request.

Competing interests

The authors declare that they have no competing interests.

Funding

This study was funded in part by the National Natural Science Foundation of China (81672191).

Authors' contributions

XW, WL, ZL, XX, ZX, ZS, YZ, QW participated in recruitment, data collection and analysis. All authors contributed to the study design and drafting of the manuscript. All authors read and approved the final manuscript.

Acknowledgements

Not applicable.

References

1. World Health Organization. Global tuberculosis report 2019. Geneva: World Health Organization; 2019.
2. Kumar R. Spinal tuberculosis: with reference to the children of northern India. *Childs Nerv Syst.* 2005; 21(1):19-26.
3. Kotil K, Alan MS, Bilge T. Medical management of Pott disease in the thoracic and lumbar spine: a prospective clinical study. *J Neurosurg Spine.* 2007; 6(3):222-8.
4. Velayutham B, Kangusamy B, Mehendale S. Prevalence of disability in Tamil Nadu, India. *Natl Med J India.* 2017; 30(3):125-130.
5. Jain A K, Kumar J. Tuberculosis of spine: neurological deficit. *Eur Spine J.* 2013; 22(4 Supplement):624-633.
6. Kiran NAS, Vaishya S, Kale SS, et al. Surgical results in patients with tuberculosis of the spine and severe lower-extremity motor deficits: a retrospective study of 48 patients. *J Neurosurg Spine.* 2007; 6(4):320-326.
7. Hristea A, Constantinescu RVM, Exergian F, et al. Paraplegia due to non-osseous spinal tuberculosis: report of three cases and review of the literature. *Int J Infect Dis.* 2008; 12(4):425-429.
8. Gautam MP, Karki P, Rijal S, et al. Pott's spine and paraplegia. *JNMA J Nepal Med Assoc.* 2005; 44(159):106.
9. Hodgson AR, Stock FE. Anterior spinal fusion a preliminary communication on the radical treatment of Pott's disease and Pott's paraplegia. *Br J Surg.* 1956; 44:266-75.
10. Zhang Z. Late onset Pott's paraplegia in patients with upper thoracic sharp kyphosis. *Int Orthop.* 2012; 36(2):381-385.
11. Kalita, J. Prognosis of conservatively treated patients with Pott's paraplegia: logistic regression analysis. *J Neurol Neurosurg Psychiatry.* 2005; 76(6):866-868.
12. Pola E, Rossi B, Nasto LA, et al. Surgical treatment of tuberculous spondylodiscitis. *Eur Rev Med Pharmacol Sci.* 2012; 16 Suppl 2(2):79-85.

13. Liu Z, Wang X, Xu Z, et al. Two approaches for treating upper thoracic spinal tuberculosis with neurological deficits in the elderly: A retrospective case-control study. *Clin Neurol Neurosurg.* 2016; 141:111-116.
14. Wu P, Wang XY, Li XG, et al. One-stage posterior procedure in treating active thoracic spinal tuberculosis: a retrospective study. *Eur J Trauma Emerg Surg.* 2015; 41(2): 189-97.
15. Batirel A, Erdem H, Sengoz G, et al. The course of spinal tuberculosis (Pott disease): results of the multinational, multicentre Backbone-2 study. *Clin Microbiol Infect.* 2015; 21(11):1008.e9-1008.e18.
16. Wang YX, Zhang HQ, Liao W, et al. One-stage posterior focus debridement, interbody graft using titanium mesh cages, posterior instrumentation and fusion in the surgical treatment of lumbo-sacral spinal tuberculosis in the aged. *Int Orthop.* 2016; 40(6):1117-24.
17. Chandra SP, Singh A, Goyal N, et al. Analysis of changing paradigms of management in 179 patients with spinal tuberculosis over a 12-year period and proposal of a new management algorithm. *World Neurosurg.* 2013; 80(1-2):190-203.
18. Zhang HQ, Lin MZ, Shen KY, et al. Surgical management for multilevel noncontiguous thoracic spinal tuberculosis by single-stage posterior transforaminal thoracic debridement, limited decompression, interbody fusion, and posterior instrumentation (modified TTIF). *Arch Orthop Trauma Surg.* 2012; 132(6):751-7.
19. Jia C G, Gao J G, Liu F S, et al. Efficacy, safety and prognosis of treating neurological deficits caused by spinal tuberculosis within 4 weeks' standard anti-tuberculosis treatment: A single medical center's experience. *Exp Ther Med.* 2020;19(1):519-526.
20. Wang L J, Zhang H Q, Tang M X, et al. Comparison of Three Surgical Approaches for Thoracic Spinal Tuberculosis in Adult: Minimum 5-Year Follow Up. *Spine (Phila Pa 1976).* 2017; 42(11):808-817.
21. Li M, Du J, Meng H, et al. One-stage surgical management for thoracic tuberculosis by anterior debridement, decompression and autogenous rib grafts, and instrumentation. *Spine J.* 2011; 11(8):726–733.
22. Varatharajah S, Charles YP, Buy X, et al. Update on the Surgical Management of Pott's Disease. *Orthop Traumatol Surg Res.* 2014; 100 (2), 229-35.
23. Zhang H, Zeng K, Yin X, et al. Debridement, internal fixation, and reconstruction using titanium mesh for the surgical treatment of thoracic and lumbar spinal tuberculosis via a posterior-only approach: a 4-year follow-up of 28 patients. *J Orthop Surg Res.* 2015; 10:150.
24. Ukunda UNF, Lukhele M. The Posterior-Only Surgical Approach in the Treatment of Tuberculosis of the Spine: Outcomes Using Cortical Bone Allografts. *Bone Joint J.* 2018; 100-B (9), 1208-1213.
25. Zhang H. Sheng B. Tang M, et al. One-stage surgical treatment for upper thoracic spinal tuberculosis by internal fixation, debridement, and combined interbody and posterior fusion via posterior-only approach. *Eur Spine J.* 2013; 22(3): 616-23.
26. Jain AK, Dhammi IK, Prashad B, et al. Simultaneous anterior decompression and posterior instrumentation of the tuberculous spine using an anterolateral extrapleural approach. *J Bone Joint Surg Br.* 2008; 90(11):1477-81.

27. Hirakawa A, Miyamoto K, Ohno Y, et al. Two-stage (posterior and anterior) surgical treatment of spinal osteomyelitis due to atypical mycobacteria and associated thoracolumbar kyphoscoliosis in a nonimmunocompromised patient. *Spine (Phila Pa 1976)*. 2008; 33(7): E221-4.

Tables

Table 1: Basic clinical data of patients

Patient Characteristics	Value
Gender (male/female)	75/43
Age (years)	32.0 ± 9.9
Lesion location	
T ₁₋₄	24(20.3%)
T ₅₋₉	42(35.6%)
T ₁₀₋₁₂	52(44.1%)
Number of affected FSUs	
single	79(66.9%)
double	25(21.2%)
Multiple	14(11.9%)
Duration for back pain	8.1±5.3
Paralysis duration (days)	6.3 ± 4.9
Operation time (min)	194.2 ± 48.2
Blood loss	871.2 ± 161.2
Rate of perioperative complication	7 (5.9%)
Mean duration of bone graft fusion	8.6±1.3

Table-2: Preoperative and final follow-up monitoring of VAS ESR, CRP and Kyphotic Cobb's angle

Observational indexes	Preoperation	Postoperation	Final follow up
VAS	5.3 ± 1.7	3.2±1.3*	1.1 ± 0.53*Δ
ESR (mm/h)	73.1±12.4	74.8±10.8*	11.5 ± 1.8*Δ
CRP (mg/L)	82.4±15.6	83.6±13.4*	2.6 ± 0.82*Δ
Kyphotic Cobb's angle (°)	21.9±4.6	6.5±1.5*	6.6±1.9*

*P < 0.05 vs. Preoperation

ΔP < 0.05 vs. Postoperation

Table 3: ASIA grade for neurological status assessment

	Preoperative	Final follow-up				
		A	B	C	D	E
A	14	2		10	2	
B	47			9	38	
C	57				57	
D						
E						

Figures

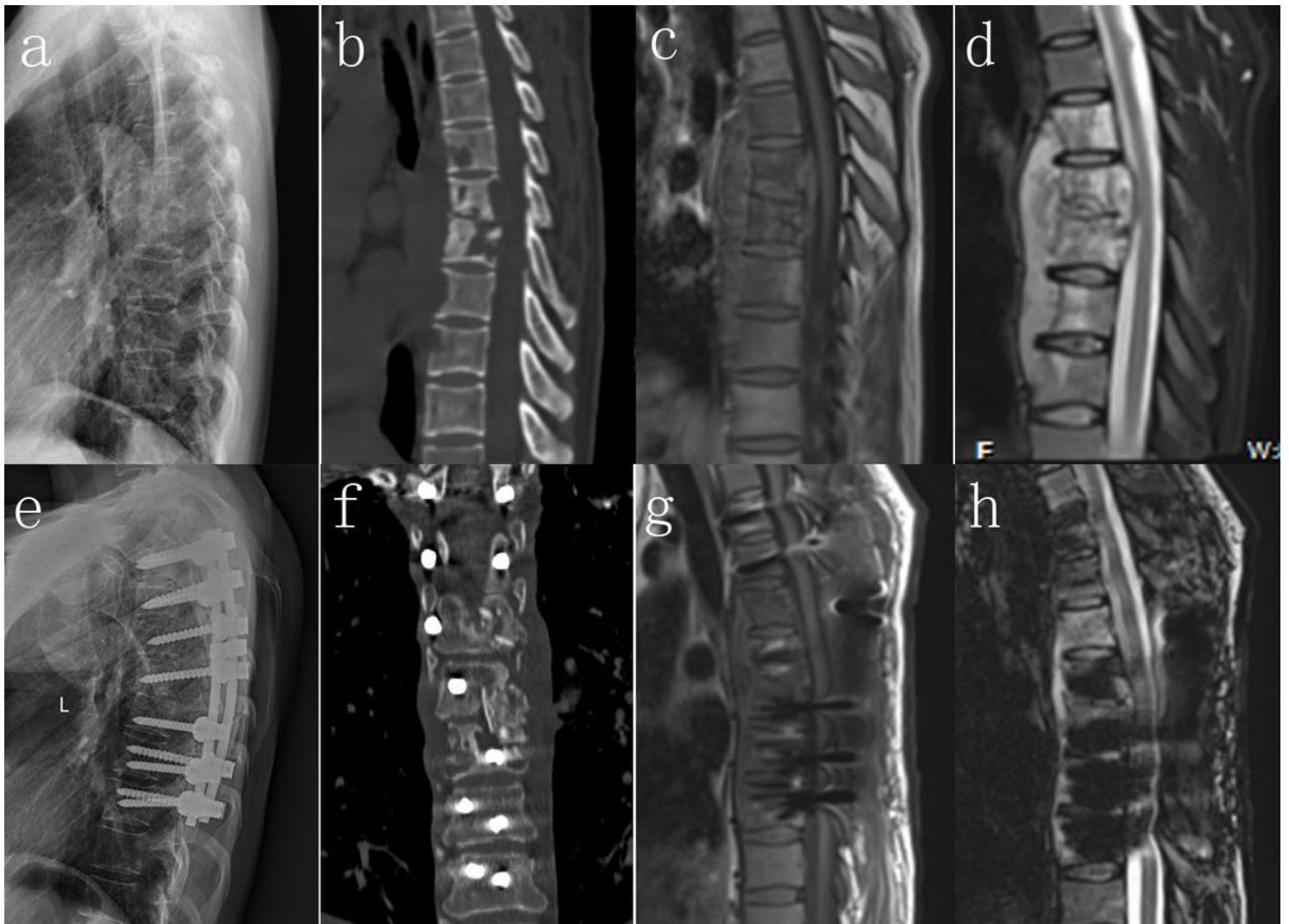

Figure 1

A 33 year old male patient with T6-7 active spinal TB paraparesis received one stage posterior spinal cord decompression, lesion removal, interbody fusion and pedicle fixation. (a-d). Preoperative images show bone destruction, disc necrosis, paraspinal and epidural cold abscess formation. (e) Postoperative image seven days after the operation shows good position of pedicle screw fixation and correction of mild kyphosis deformity. (f) Postoperative image seven days after the operation shows that most paraspinal and epidural cold abscesses were removed through one stage posterior surgery. (g-h) Postoperative image 12 months after the operation showed that abscess disappeared and that kyphosis correction was not significantly lost.

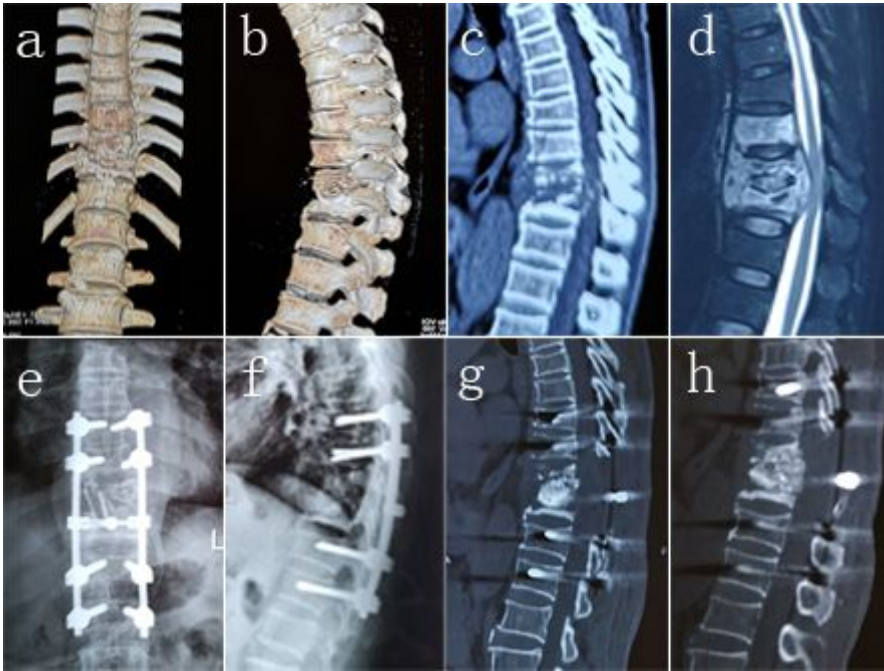


Figure 2

A 55 year old male patient with T10-11 active spinal TB paraplegia received one stage posterior spinal cord decompression, lesion removal, interbody fusion and pedicle fixation. (a–d), Preoperative images show osteolytic destruction and collapse of vertebral body, epidural cold abscess formation and spinal cord compression. (e–g) Postoperative image seven days after the operation shows good positioning of pedicle screw fixation and interbody bone graft, as well as correction of kyphosis deformity. (h) Postoperative image 12 months after the operation showed that interbody fusion was achieved and that no significant loss of the kyphotic correction was observed.