

# Genetic Spectrum and Clinical Characteristics of 3 $\beta$ -hydroxy- $\Delta^5$ -C<sub>27</sub>-steroid Oxidoreductase (HSD3B7) Deficiency in China

**Jing Zhao**

Fudan University <https://orcid.org/0000-0002-3208-9009>

**Kenneth DR Setchell**

Cincinnati Children's Hospital Medical Center

**Ying Gong**

Children's Hospital of Fudan University

**Yinghua Sun**

Children's Hospital of Fudan University

**Ping Zhang**

Children's Hospital of Fudan University

**James E Heubi**

Cincinnati Children's Hospital Medical Center

**Lingjuan Fang**

Children's Hospital of Fudan University

**Yi Lu**

Children's Hospital of Fudan University

**Xinbao Xie**

Children's Hospital of Fudan University

**Jingyu Gong**

Fudan University

**Jian-She Wang** (✉ [jshwang@shmu.edu.cn](mailto:jshwang@shmu.edu.cn))

Children's Hospital of Fudan University

---

## Research Article

**Keywords:** bile acid synthesis, chenodeoxycholic acid, genetic spectrum, HSD3B7, renal lesions, 3 $\beta$ -hydroxy- $\Delta^5$ -C<sub>27</sub>-steroid oxidoreductase deficiency

**Posted Date:** May 21st, 2021

**DOI:** <https://doi.org/10.21203/rs.3.rs-488210/v1>

**License:**  This work is licensed under a Creative Commons Attribution 4.0 International License. [Read Full License](#)

---

# Abstract

## Background

Biallelic variants in *HSD3B7* cause 3 $\beta$ -hydroxy- $\Delta^5$ -C<sub>27</sub>-steroid oxidoreductase (HSD3B7) deficiency, a life-threatening but treatable liver disease. Genetic and correlated clinical information is limited. We retrospectively reviewed the records of 39 unrelated patients with genetically confirmed HSD3B7 deficiency.

## Results

In this cohort, 44 variants (34 novel) of *HSD3B7* were detected. 31 patients were referred before one year old for neonatal cholestasis. eight patients were referred after one year old for liver failure (n=2), liver cirrhosis (n=3), cholestasis (n=1), renal cysts and abnormal liver biochemistries (n=1), coagulopathy of vitamin K1 deficiency and abnormal liver biochemistries (n=1) respectively. Renal lesions, including renal cysts, renal stones, calcium deposition and renal enlargement were observed in 10 out of 35 patients with available data. 33 patients received oral chenodeoxycholic acid (CDCA) administration, 22 achieved normalization of liver biochemistries, five showed significant clinical improvement, six underwent liver transplantation or died. Renal lesions in six patients resolved after CDCA administration or liver transplantation. There is no significant correlation between genotype and clinical outcome.

## Conclusions

This is so far the largest cohort of HSD3B7 deficiency, and reveals that renal lesion is a notable clinical feature of HSD3B7 deficiency and can be resolved with suppression of atypical bile acids.

## Background

3 $\beta$ -hydroxy- $\Delta^5$ -C<sub>27</sub>-steroid oxidoreductase (HSD3B7) deficiency is an autosomal-recessive disorder of bile acid synthesis caused by biallelic pathogenic variants in the *HSD3B7* gene.(1, 2) As previously reported, patients may present with diverse clinical features, but mainly with neonatal cholestasis.(3-5). Some affected patients present with late-onset chronic liver disease or fat-soluble vitamin deficiency.(4, 6, 7) Definitive diagnosis of HSD3B7 deficiency is achieved by the detection of increased levels of atypical 3 $\beta$ -hydroxy- $\Delta^5$  bile acids in urine and confirmation by genetic analysis for variants in *HSD3B7*.(3) Replacement therapy with cholic acid (CA) or chenodeoxycholic acid (CDCA) has been shown to be an effective therapy.(8-10) If untreated, HSD3B7 deficiency-associated liver disease may lead to liver failure requiring liver transplantation.(9) Thus, increasing awareness and knowledge of the clinical and genetic features of HSD3B7 deficiency is necessary to guide and improve the outcome in this rare disorder.(11)

Comprehensive information about HSD3B7 deficiency is limited, with worldwide less than 100 cases reported.(1, 2, 4, 7, 10, 12-21) Genotype and phenotype correlation has never previously been explored. Due to the lack of urinary analysis by mass spectrometry in some regions of the world, the more frequent use of panel or whole exome sequencing has led to molecular analysis playing a critical role in establishing an early diagnosis. However, how to interpret the genetic variants detected remains a critical roadblock.(22, 23) Underlying pathogenic variants are often classified as variants of uncertain significance (VUS) for lack of data, which could lead to under-recognition of this treatable disorder.

In this study, the aim was to present the genetic spectrum, clinical features and treatment outcome of Chinese patients with a confirmed HSD3B7 deficiency, and discuss the possible impacts of HSD3B7 variants on clinical phenotype.

## Methods

### Patients

We retrospectively reviewed 39 patients diagnosed with HSD3B7 deficiency at Children's Hospital of Fudan University from 2009 to 2020. These include five patients (P5, P9, P11, P13, and P14) that were reported previously.(17-19, 24) In 33 patients, the diagnosis was established by clinical features, serum liver biochemistries, urinary bile acid analysis by fast atom bombardment ionization mass spectrometry (FAB-MS), and molecular analysis. In six cases (P3, P6, P36~P39) unavailable for urinary bile acid analysis, the diagnosis was suspected by clinical characteristics and serum liver biochemistries, then confirmed by genetic studies with parental verification. The following information was abstracted from patient records: gender, geographical origin, age at disease onset, age at first visit to our hospital, clinical features, laboratory findings, radiological studies, genetic data, type and duration of therapies, and response to treatment.

This study was approved by the Ethics Committees on Human Research of the Children's Hospital of Fudan University.

### Genetic study

Before December 2015, all exons and adjacent introns of *HSD3B7* (RefSeq NM\_025193.4) were Sanger sequenced as described.(17) After January 2016, panel sequencing and Sanger confirmation were performed.(25) Large fragment deletion was confirmed by quantitative polymerase chain reaction (qPCR). Variants were annotated for frequency in public databases (Genome Aggregation Database and Exome Aggregation Consortium) and predicted pathogenicity in PROVEAN (<http://provean.jcvi.org>), Polyphen-2 (<http://genetics.bwh.harvard.edu/pph2/>), MutationTaster (<http://www.mutationtaster.org>), SIFT (<http://sift.jcvi.org>) and FATHMM (<http://fathmm.biocompute.org.uk>). Variant with minor allele frequency <0.005 and predicted to be pathogenic by at least one of the five programs was considered as predicted pathogenic variant. The American College of Medical Genetics and Genomics (ACMG) guidelines was used for clinical sequence interpretation.(26)

To explore the possible genotype-phenotype association, all variants were categorized into two classes. Frameshift, nonsense, classical splicing variants and large fragment deletion predicted to result in nonsense mRNA decay or protein truncation were defined as null variants. Other variants, including missense,

non-classical splicing and non-frameshift small indel types, were defined as non-null variants.

### Urinary bile acid analysis

Urine samples were collected before treatment with primary bile acid and analyzed in Cincinnati using mass spectrometry with FAB-MS for the detection of atypical 3 $\beta$ -hydroxy- $\Delta^5$ -bile acid biomarkers. In patients on prior treatment with ursodeoxycholic acid (UDCA) urine was collected after the therapy was stopped at least 5 days. Diagnosis of HSD3B7 deficiency was based on the finding of a lack of primary bile acid conjugates and elevations of atypical 3 $\beta$ -hydroxy- $\Delta^5$ -bile acids that are the signature metabolites for this genetic defect in bile acid synthesis.(1, 27)

### Statistical analysis

Statistical analysis was performed using SPSS 17. Mann-Whitney test and Fisher's exact test were performed. Values for  $p < 0.05$  was considered statistically significant.

## Results

### The genetic spectrum of HSD3B7 deficiency

There were 44 pathogenic / predicted pathogenic variants identified (Table 1, supplementary table S1 and S2). 23 were missense variants (42.3%), five nonsense variants (16.7%), 3 splice site variation (5.1%), 12 small (<15 bp) deletions or insertions (34.6%) and one 1.2-kb deletion (1.3%). Information regarding paternity and maternity revealed homozygotes in 14 patients (35.9%), compound heterozygotes in 17 patients (43.6%). In eight patients (20.5%), parental verification was not performed (Table 1). According to ACMG standards and guidelines, 5 out of 44 variants were assigned as "pathogenic variants," 17 as "likely pathogenic," and the remaining 22 as "VUS" (Table 1).

Among the 44 variants, 10 were reported in previously literature and 34 were novel.(16-19, 24, 28) All 34 novel variants were absent or with very low frequency (less than 1/10, 000) in Genome Aggregation Database and Exome Aggregation Consortium. All were predicted to cause deleterious disruptions to the protein by at least one of the five programs: PROVEAN, MutationTaster, PolyPhen-2, SIFT and FATHMM software (supplementary table S1). Variants identified were spread throughout the *HSD3B7* gene. Over 75% of patients carried an *HSD3B7* variant on exon 4, 5 or 6 (Figure 1). The four most common variants were c.45\_46delAG (n = 6, 7.7%) in exon 1, c.503G>A (n = 9, 11.5%) in exon 4, c.543dupG (n = 6, 7.7%) and c.683G>A (n = 5, 6.4%) in exon 5.

## Clinical data and laboratory evaluation

Among the 39 patients enrolled, 24 were male and 15 were female. Four patients (P2, P6, P24, P26) had one sibling respectively with neonatal cholestasis that died before 3 years of age. Table 2 summarized the clinical features, urinary bile acid analysis, medical treatment, and outcome.

The median age of onset of symptoms was 10 days (range 2 days-16.8 years old). The median age at diagnosis was 4.8 months (range 1.7 months-17.2 years old). Depending on the age of first referral, we classified our patients into two groups. The first group included 31 patients (79.5%) referred before one year of age: all for neonatal cholestasis. The second group included 8 patients referred after one year of age: for neonatal cholestasis and liver failure (P37), adolescence-onset cholestasis and liver failure (P6), liver cirrhosis with (P22) or without (P31, P35) a history of transient neonatal cholestasis, recurrent cholestasis (P15), renal cysts and abnormal liver biochemistries with transient neonatal cholestasis (P2), and coagulopathy of vitamin K1 deficiency and abnormal liver biochemistries (P8). The serum liver biochemistries at first referral were compared between the two groups. Compared to the patients who were referred after one year of age, the patients who were referred before one year old had significantly higher serum total bilirubin, direct bilirubin, alanine aminotransferase, aspartate transaminase, serum gamma-glutamyl transpeptidase (GGT) and total cholesterol (TCH) (Table 3).

Neonatal cholestasis with low GGT and total bile acids (TBA) is believed the feature of HSD3B7 deficiency. The range GGT at referral in the patients who were referred before one year old were 15-65.1U/L and the range of TBA were 0.2-85.4 $\mu$ mol/L. The concentration of serum TBA was between 10  $\mu$ mol/L and 30 $\mu$ mol/L in six patients of whom five stopped UDCA treatment for five days, above 30 $\mu$ mol/L in three patients of whom two (P4 and P38) were on UDCA therapy and one (P21) had progressed to liver failure which accounts for this elevation.

Renal images were collected from 35 patients before treatment with CDCA, of whom 10 (28.6%) had renal lesions, including renal cysts (n=6), renal stones (n=2), calcium deposition (n=2), renal enlargement (n=1) and multiple abnormal echoes in the calyx (n=1) (Table 4 and Figure 2). In these patients, the serum creatinine levels and urinalysis were all within the normal range (Table 4). The patients with renal lesions (median age 3.1 years, range 3.7months to 17.2 years) were referred significantly later in age than patients that did not have identifiable renal lesions (median age 4.5 months, range 1.7 months to 5.2 years,  $P < 0.001$ ).

### Urinary bile acid analysis

Urine samples from 33 patients were collected and analyzed using FAB-MS. The profiles of 32 patients showed an absence or a lack of the normal primary bile acid conjugates and marked elevations in sulfate and glyco-sulfate conjugates of dihydroxy- and trihydroxy-cholenoic acids (ions at  $m/z$  469, 485, sulfate conjugates;  $m/z$  526, 542, glyco-sulfate conjugates) that are the biomarkers for the HSD3B7 deficiency. Compared with typical bile acid metabolites, the profile of Patient 21 showed only traces of these ion features, presumably because of liver failure and so the metabolic synthesis of bile acids was reduced (Figure 3).

## Clinical follow-up and outcome

Apart from 2 patients (P4 and P6) that died before a diagnosis of HSD3B7 deficiency was established, 1 patient (P23) that refused oral CDCA therapy and 3 patients (P3, P7 and P11) that was lost to follow-up, 33 patients were treated with CDCA (initial dose ranging 3-10mg/kg/d) and regularly followed up. The median follow-up period was 26mo (range 10 days - 9 years and 4 months). Of these, 22 (64.7%) achieved complete normalization of serum liver biochemistries, 5 (14.7%) showed significant clinical improvement, 5 (14.7%) underwent liver transplantation, and 1 (3%) died. There is no significant difference in term of the age at diagnosis between the died or transplanted patients (median 4.9 mo, n=6, range 1.8mo - 11.5 mo) and the alive patients (median 4.8 mo, n=27, range 1.4 mo - 6.6 y,  $P = 0.874$ ).

Among the 10 patients with renal lesions, one (P6) died before a definite diagnosis of HSD3B7 deficiency was made, two other patients (P15, P35) had not undergo repeat renal imaging yet. Renal ultrasonography was repeated in the other seven patients: Six patients were on continuous CDCA therapy, one was liver transplanted (P21) 10 days after. Renal lesions disappeared in 6 patients eventually, including in five patients (P2, P5, P8, P16, P22) after a median of 16mo (range 2.5 mo to 33mo) CDCA administration, and one patient (P21) at 18mo after liver transplantation, concomitant with a decrease or disappearance of atypical bile acids in urine and normalization of serum liver biochemistries. Bilateral renal enlargement in the other (P37) improved after CDCA administration for 11 months (left renal 87.9mm\*27.6mm\*24.3mm, right renal 83.1mm\*31.6\*37.6mm), compared with renal ultrasound before diagnosis (left renal 105mm\*25.1mm\*29.7mm, right renal 89.8mm\*29.1\*32.5mm).

### Genotype-phenotype relationship

For patients with biallelic null variants, 75% (9/12) presented with neonatal cholestasis, 18.2% (2/11) died or underwent liver transplantation. Of those patients with one null and one non-null variants, 81.3% (13/16) presented with neonatal cholestasis and 20% (3/15) died or were transplanted. Of those patients with biallelic non-null variants, 90.9% (10/11) presented with neonatal cholestasis and 36.4% (4/11) died or were transplanted. No significant difference was observed in term of disease onset age and clinical outcome among the patients with different genotypes.

## Discussion

This study describes the up-to-now worldwide largest series of HSD3B7 deficiency patients and reports the identification of 34 *HSD3B7* novel pathogenic or predicted pathogenic variants. The observation that 10 patients presented with renal lesions, and in 6 of them the renal lesions resolved after oral CDCA administration or liver transplantation, along with suppression of the atypical bile acid biomarkers, highlights renal lesions as an important clinical feature of HSD3B7 deficiency.

In this study, we identified 44 variants from our patients. The diagnosis of these subjects were not only based on genetic analysis, but also based on urinary bile acid profiling combining with clinical manifestation and liver biochemistry. These are very helpful for the pathogenicity assessment of the variants. The recurrent of variants with a high frequency of c.45\_46delAG, c.503G>A, c.543dupG and c.683G>A in this group has never been recorded, or have a very low frequency in normal human database further increase the probability of its pathogenicity. The bile acid profiles of 17 patients with 20 variants assigned as VUS were consistent with HSD3B7 deficiency. In two patients with the remaining two variants of uncertain significance (c.968 C>T and c.484\_485delinsCC), serum TBA (measured by enzyme immunoassay) were low (<10 $\mu$ mol/L) and consistent with expectations for a bile acid synthesis disorder.(20) Elevated atypical urinary bile acid metabolites and low serum TBA (taken when off UDCA therapy) enabled us to make the final diagnosis and to prove that 22 variants of uncertain significance reported here are likely pathogenic.

In our patients, neonatal cholestasis (82.1%) was the most common clinical phenotype. Liver biochemistries included serum conjugated hyperbilirubinemia, elevated aminotransferases, and normal GGT, which is consistent with previously reported cases.(16) Care is required when interpreting a routine serum TBA level obtained when the patient is receiving UDCA therapy because a slightly elevated serum TBA may not necessarily exclude a diagnosis HSD3B7 deficiency in neonates.

Our findings show that renal lesions with normal renal chemistries have a prevalence of 28.6% in HSD3B7 deficiency and the most common renal involvement was renal cysts (5/10). Renal cysts have been described in a few patients but a causal association was not previously confirmed.(29) In patients with HSD3B7 deficiency, primary bile acids are not synthesized and instead there is an accumulation of hepatotoxic 3 $\beta$ -hydroxy- $\Delta^5$ -bile acids that lead to cholestatic liver injury that often progresses to subsequent liver failure. Urinary excretion consequently becomes the major route of elimination of these atypical bile acids. The cause of renal lesions is unclear but animal studies suggest that high concentrations of bile acids can be toxic on renal tubules and may generate or initiate renal lesions.(30) Whether chronic exposure of the kidney to high concentrations of the atypical 3 $\beta$ -hydroxy- $\Delta^5$ -bile acids associated with HSD3B7 deficiency can explain the renal disease is conjecture. Significant was our finding that renal lesions appeared mainly in the older children and that these were resolved upon suppression of bile acid synthesis, or after liver transplantation, both of which eliminate the production of 3 $\beta$ -hydroxy- $\Delta^5$ -bile acids. No common variant is associated with renal lesions of HSD3B7 deficiency. These findings suggest that it is the accumulation over time of 3 $\beta$ -hydroxy- $\Delta^5$ -bile acids that appear to underlie the renal pathology.

In conclusion, this study presents a comprehensive description of the the *HSD3B7* genetic spectrum and clinical characteristics of HSD3B7 deficiency in a large cohort of infants and children from China. It concludes that the genotype is not a good predictor of the phenotype or clinical outcome. Furthermore, our data highlight the significant prevalence of renal lesions in HSD3B7 deficiency and that these lesions can be resolved by primary bile acid therapy. Thus, targeted renal evaluation, including serum biochemistries, renal ultrasound, and urinalysis, should be included in the standard work-up of children with HSD3B7 deficiency.

## Abbreviations

HSD3B7: 3 $\beta$ -hydroxy- $\Delta^5$ -C<sub>27</sub>-steroid oxidoreductase

CA: Cholic acid

CDCA: Chenodeoxycholic acid

VUS: Variants of uncertain significance

FAB-MS: Fast atom bombardment ionization mass spectrometry

qPCR: Quantitative polymerase chain reaction

ACMG: The American College of Medical Genetics and Genomics

UDCA: Ursodeoxycholic acid

GGT: Gamma-glutamyl transpeptidase

TCH: Total cholesterol

TBA: Total bile acids

## Declarations

### Availability of data and materials

The datasets generated during and/or analysed during the current study are available from the corresponding author on reasonable request.

### Author contributions

Jing Zhao performed the genetic studies, statistical analysis and manuscript preparation; Kenneth D. R. Setchell and James E Heubi contributed to the analysis and interpretation of urinary bile acids, and manuscript preparation; Ying Gong and Yinghua Sun were involved in renal imaging studies; Jian-She Wang contributed to obtaining funding, study concept, design, supervision and manuscript preparation. All authors involved in acquisition, analysis and interpretation of data, and manuscript revision and final approval of its publication.

### Ethical Approval and Consent to participate

This study was approved by the Ethics Committees on Human Research of the Children's Hospital of Fudan University.

### Consent for publication

Not applicable.

### Competing interests

The authors disclose no conflicts. KDRS and JEH have minor equity in Asklepiion Pharmaceuticals and are consultants to Retrophin.

### Funding

Financial support was provided by the National Natural Science Foundation of China (81361128006) [to J.S.W.] and Fund of Science Committee of Health Department of Shanghai Government (20184Y0256) [to J.Z].

### Acknowledgments

**We thank all individuals and their families for their cooperation in this study.**

## Availability of data and materials

All data generated and analyzed during this study are included in this article and its supplementary tables.

## References

1. Clayton PT, Leonard JV, Lawson AM, Setchell KD, Andersson S, Egestad B, et al. Familial giant cell hepatitis associated with synthesis of 3 beta, 7 alpha-dihydroxy- and 3 beta, 7 alpha, 12 alpha-trihydroxy-5-cholenoic acids. *J Clin Invest.* 1987;79(4):1031-8.

2. Schwarz M, Wright AC, Davis DL, Nazer H, Bjorkhem I, Russell DW. The bile acid synthetic gene 3beta-hydroxy-Delta(5)-C(27)-steroid oxidoreductase is mutated in progressive intrahepatic cholestasis. *J Clin Invest*. 2000;106(9):1175-84.
3. Heubi JE, Setchell KDR, Bove KE. Inborn Errors of Bile Acid Metabolism. *Clin Liver Dis*. 2018;22(4):671-87.
4. Subramaniam P, Clayton PT, Portmann BC, Mieli-Vergani G, Hadzic N. Variable clinical spectrum of the most common inborn error of bile acid metabolism—3beta-hydroxy-Delta 5-C27-steroid dehydrogenase deficiency. *J Pediatr Gastroenterol Nutr*. 2010;50(1):61-6.
5. Jahnel J, Zohrer E, Fischler B, D'Antiga L, Debray D, Dezsofi A, et al. Attempt to Determine the Prevalence of Two Inborn Errors of Primary Bile Acid Synthesis: Results of a European Survey. *J Pediatr Gastroenterol Nutr*. 2017;64(6):864-8.
6. Molho-Pessach V, Rios JJ, Xing C, Setchell KD, Cohen JC, Hobbs HH. Homozygosity mapping identifies a bile acid biosynthetic defect in an adult with cirrhosis of unknown etiology. *Hepatology*. 2012;55(4):1139-45.
7. Akobeng AK, Clayton PT, Miller V, Super M, Thomas AG. An inborn error of bile acid synthesis (3beta-hydroxy-delta5-C27-steroid dehydrogenase deficiency) presenting as malabsorption leading to rickets. *Arch Dis Child*. 1999;80(5):463-5.
8. Gonzales E, Matarazzo L, Franchi-Abella S, Dabadie A, Cohen J, Habes D, et al. Cholic acid for primary bile acid synthesis defects: a life-saving therapy allowing a favorable outcome in adulthood. *Orphanet J Rare Dis*. 2018;13(1):190.
9. Setchell KD, Heubi JE. Defects in bile acid biosynthesis—diagnosis and treatment. *J Pediatr Gastroenterol Nutr*. 2006;43 Suppl 1:S17-22.
10. Horslen SP, Lawson AM, Malone M, Clayton PT. 3 beta-hydroxy-delta 5-C27-steroid dehydrogenase deficiency; effect of chenodeoxycholic acid therapy on liver histology. *J Inher Metab Dis*. 1992;15(1):38-46.
11. Bove KE, Heubi JE, Balistreri WF, Setchell KD. Bile acid synthetic defects and liver disease: a comprehensive review. *Pediatr Dev Pathol*. 2004;7(4):315-34.
12. Buchmann MS, Kvittingen EA, Nazer H, Gunasekaran T, Clayton PT, Sjovall J, et al. Lack of 3 beta-hydroxy-delta 5-C27-steroid dehydrogenase/isomerase in fibroblasts from a child with urinary excretion of 3 beta-hydroxy-delta 5-bile acids. A new inborn error of metabolism. *J Clin Invest*. 1990;86(6):2034-7.
13. Ichimiya H, Egestad B, Nazer H, Baginski ES, Clayton PT, Sjovall J. Bile acids and bile alcohols in a child with hepatic 3 beta-hydroxy-delta 5-C27-steroid dehydrogenase deficiency: effects of chenodeoxycholic acid treatment. *J Lipid Res*. 1991;32(5):829-41.
14. Kobayashi M, Koike M, Sakiyama M, Okuda S, Okuda M, Tanaka T, et al. 3beta-hydroxy-delta5-C27-steroid dehydrogenase/isomerase deficiency in a 23-year-old woman. *Pediatr Int*. 2000;42(6):685-8.
15. Cheng JB, Jacquemin E, Gerhardt M, Nazer H, Cresteil D, Heubi JE, et al. Molecular genetics of 3beta-hydroxy-Delta5-C27-steroid oxidoreductase deficiency in 16 patients with loss of bile acid synthesis and liver disease. *J Clin Endocrinol Metab*. 2003;88(4):1833-41.
16. Gonzales E, Gerhardt MF, Fabre M, Setchell KD, Davit-Spraul A, Vincent I, et al. Oral cholic acid for hereditary defects of primary bile acid synthesis: a safe and effective long-term therapy. *Gastroenterology*. 2009;137(4):1310-20 e1-3.
17. Yang TJ, Xie XB, Yao WL, Wang HJ, Yu H, Wang XH. [Clinical features of a Chinese infant with inborn error of bile acid metabolism-3beta-hydroxy-Delta(5)-C27-steroid dehydrogenase deficiency and review of the literature]. *Zhonghua Er Ke Za Zhi*. 2013;51(8):625-9.
18. Li X, Huang Z, Wang H. [Infant with 3beta-hydroxy-Delta(5)-C27 steroid dehydrogenase deficiency: report of two cases and literatures review]. *Zhonghua Er Ke Za Zhi*. 2015;53(5):360-5.
19. Huang HY, Zhou H, Wang H, Chen YX, Fang F. Novel Mutations in the 3beta-hydroxy-5-C27-steroid Dehydrogenase Gene (HSD3B7) in a Patient with Neonatal Cholestasis. *Chin Med J (Engl)*. 2016;129(1):98-100.
20. Al-Hussaini AA, Setchell KDR, AlSaleem B, Heubi JE, Lone K, Davit-Spraul A, et al. Bile Acid Synthesis Disorders in Arabs: A 10-year Screening Study. *J Pediatr Gastroenterol Nutr*. 2017;65(6):613-20.
21. Mizuochi T, Takei H, Nittono H, Kimura A. Bile Acid Synthesis Disorders in Japan: A Long-Term Outcome and an Efficacy of Chenodeoxycholic Acid Treatment. *Hepatology*. 2019;70:1025a-6a.
22. Starita LM, Ahituv N, Dunham MJ, Kitzman JO, Roth FP, Seelig G, et al. Variant Interpretation: Functional Assays to the Rescue. *Am J Hum Genet*. 2017;101(3):315-25.
23. Hoffman-Andrews L. The known unknown: the challenges of genetic variants of uncertain significance in clinical practice. *J Law Biosci*. 2017;4(3):648-57.
24. Wang NL, Lu Y, Gong JY, Xie XB, Lin J, Abuduxikuer K, et al. Molecular findings in children with inherited intrahepatic cholestasis. *Pediatr Res*. 2020;87(1):112-7.
25. Wang NL, Lu YL, Zhang P, Zhang MH, Gong JY, Lu Y, et al. A Specially Designed Multi-Gene Panel Facilitates Genetic Diagnosis in Children with Intrahepatic Cholestasis: Simultaneous Test of Known Large Insertions/Deletions. *PLoS One*. 2016;11(10):e0164058.
26. Richards S, Aziz N, Bale S, Bick D, Das S, Gastier-Foster J, et al. Standards and guidelines for the interpretation of sequence variants: a joint consensus recommendation of the American College of Medical Genetics and Genomics and the Association for Molecular Pathology. *Genet Med*. 2015;17(5):405-24.
27. Vaz FM, Ferdinandusse S. Bile acid analysis in human disorders of bile acid biosynthesis. *Mol Aspects Med*. 2017;56:10-24.
28. Rinawi F, Iancu TC, Hartman C, Cohen H, Yarden-Bilavsky H, Bar Lev MR, et al. Fat Malabsorption due to Bile Acid Synthesis Defect. *Isr Med Assoc J*. 2015;17(3):190-2.
29. Bossi G, Giordano G, Rispoli GA, Maggiore G, Naturale M, Marchetti D, et al. Atypical clinical presentation and successful treatment with oral cholic acid of a child with defective bile acid synthesis due to a novel mutation in the HSD3B7 gene. *Pediatr Rep*. 2017;9(3):7266.
30. Fickert P, Krones E, Pollheimer MJ, Thueringer A, Moustafa T, Silbert D, et al. Bile acids trigger cholemic nephropathy in common bile-duct-ligated mice. *Hepatology*. 2013;58(6):2056-69.

## Tables

Table 1. *HSD3B7* variants in 39 patients with 3 $\beta$ -hydroxy- $\Delta^5$ -C<sub>27</sub>-steroid oxidoreductase (HSD3B7) deficiency

Patients	Zygoty	Location	Nucleotide change (NM_025193.4)	Predicted amino acid change (NP_079469.2)	ACMG classification <sup>†</sup>		Parental derivati
					Classification	Evidence	
P1	Hom	Ex6	c.1031A>G	p.Tyr344Cys	LP	PS3+PM2_S+PP4	Paternal
P2	Het	Ex1	c.45_46delAG	p.Gly17Leufs*26	P	PVS1+PS4+PM2_S	Maternal
	Het	Ex6	c.988_990delACC	p.Thr329del	LP	PM2_S+PM3+PM4+PP3	Paternal
P3	Hom	Ex6	c.968 C>T	p.Thr323Met	VUS	PM2_S+PP3	Paternal
P4	Het	Ex5	c.683G>A	p.Arg228Gln	LP	PS4+PM2_S+PM3+PP3	Paternal
	Het	Ex6	c.1040delT	p.Leu347Argfs*70	LP	PVS1+PM2_S	Maternal
P5	Het	Ex1	c.45_46delAG	p.Gly17Leufs*26	P	PVS1+PS4+PM2_S	Maternal
	Het	Ex2	c.262G>C	p.Gly88Arg	VUS	PM2_S+PM3+PP3	Paternal
P6	Hom	Ex4	c.484_485delinsCC	p.Ser162Pro	VUS	PM2_S+PM5+PP3	Paternal
P7	Hom	Ex5	c.544delC	p.Leu182Cysfs*4	LP	PVS1+PM2_S	Paternal
P8	Hom	Ex4	c.474delC	p.Tyr159Ilefs*27	LP	PVS1+PM2_S	Paternal
P9	Het	Ex5	c.543dupG	p.Leu182Alafs*16	P	PVS1+PS4_M+PM2_S+PM3	Maternal
	Het	Ex6	c.790C>A	p.Pro264Thr	VUS	PM2_S+PM3+PP3	Paternal
P10	Het	Ex6	c.781G>A	p.Asp261Asn	VUS	PM2_S+PM3+PP3+PP4	NA
	Het	Ex6	c.1079G>A	p.Trp360Ter	LP	PVS1-Strong+PM2_S+PP4	NA
P11	Het	Ex3	c.401G>A	p.Gly134Glu	VUS	PM2_S+PP3+PP4	NA
	Het	In4	c.532-3C>G		VUS	PM2_S+PP4	NA
P12	Het	Ex5	c.682C>T	p.Arg228Trp	VUS	PM2_S+PM5+PP3+PP4	NA
	Het	Ex6	c.1061G>C	p.Arg354Pro	VUS	PM2_S+PP3+PP4	NA
P13	Het	Ex4	c.503G>A	p.Trp168Ter	P	PVS1+PS4+PM2_S	Maternal
	Het	Ex5	c.683G>A	p.Arg228Gln	LP	PS4+PM2_S+PM3+PP3	Paternal
P14	Het	Ex1	c.147G>A	p.Trp49Ter	LP	PVS1+PM2_S	NA
	Het	Ex4	c.503G>A	p.Trp168Ter	P	PVS1+PS4+PM2_S	NA
P15	Het	Ex4	c.503G>A	p.Trp168Ter	P	PVS1+PS4+PM2_S	Paternal
	Het	Ex5	c.569G>A	p.Arg190His	VUS	PM2_S+PM3+PP3+PP4	Maternal
P16	Hom	Ex5	c.682C>T	p.Arg228Trp	VUS	PM2_S+PM5+PP3+PP4	Paternal
P17	Hom	Ex6	c.988_990delACC	p.Thr329del	LP	PM2_S+PM3+PM4+PP3	Paternal
	Het	Ex5	c.543dupG	p.Leu182Alafs*16	P	PVS1+PS4_M+PM2_S+PM3	Maternal
P18	Het	Ex5	c.683G>A	p.Arg228Gln	LP	PS4+PM2_S+PM3+PP3	Paternal
	Het	Ex1	c.45_46delAG	p.Gly17Leufs*26	P	PVS1+PS4+PM2_S	NA
P19	Het	Ex6	c.770A>G	p.Tyr257Cys	VUS	PM2_S+PP3	NA
	Het	Ex5	c.683G>A	p.Arg228Gln	LP	PS4+PM2_S+PP3	NA
P20	Het	Ex5	c.683G>T	p.Arg228Leu	VUS	PM2_S+PM5+PP3	NA
	Het	Ex5	c.561T>G	p.Cys187Trp	VUS	PM2_S+PP3+PP4	NA
P21	Het	Ex5	c.586G>A	p.Gly196Ser	VUS	PM2_S+PP3+PP4	NA
	Het	Ex3	c.346T>C	p.Cys116Arg	VUS	PM2_S+PM3+PP3+PP4	Paternal
P22	Het	Ex6	C.964_965dup	p.Leu324Argfs*94	LP	PVS1+PM2_S+PP4	Maternal
	Hom	Ex4	c.503G>A	p.Trp168Ter	P	PVS1+PS4+PM2_S	Paternal
P24	Het	Ex5	c.676C>T	p.His226Tyr	VUS	PM2_S+PP3+PP4	Maternal



	Het		c.-205_323-108del		P	PVS1+PS4+PM2-S+PP4	Paternal
P25	Het	Ex4	c.503G>A	p.Trp168Ter	P	PVS1+PS4+PM2-S	Maternal
	Het	Ex6	c.743G>C	p.Arg248Pro	LP	PM2-S+PM3+PM6+PP4	Assumed paternal <sup>†</sup>
P26	Hom	In3	c.431+2dupT		LP	PVS1+PM2-S	Paternal
P27	Hom	Ex4	c.485_487delGCA	p.Ser162del	VUS	PM2-S+PM4+PP4	Paternal
P28	Het	Ex5	c.683G>A	p.Arg228Gln	LP	PS4+PM2_S+PP3	Paternal
	Het	In5	c.694+2T>C		LP	PVS1+PM2_S+PM3	Maternal
P29	Het	Ex2	c.173_174del	p.Val58Gluufs*14	LP	PVS1+PM2_S	Paternal
	Het	Ex3	c.371T>C	p.Leu124Pro	VUS	PM2-S+PM3+PP3+PP4	Maternal
P30	Het	Ex5	c.557C>T	p.Thr186Met	VUS	PM2-S+PP3	Maternal
	Het	Ex6	c.968C>G	p.Thr323Arg	VUS	PM2-S+PP3	Paternal
P31	Het	Ex1	c.45_46delAG	p.Gly17Leufs*26	P	PVS1+PS4+PM2_S	Paternal
	Het	Ex5	c.543dupG	p.Leu182Alafs*16	P	PVS1+PS4_M+PM2_S+PM3	Maternal
P32	Hom	Ex4	c.499G>A	p.Glu167Lys	VUS	PM2-S+PP3	Paternal
P33	Het	Ex6	c.698A>G	p.Asn233Ser	VUS	PM2_S+PM3+PP3	Paternal
	Het	Ex6	c.1033G>T	p.Glu345Ter	LP	PVS1+PM2_S	Maternal
P34	Het	Ex6	c.920_931delGGCTGCTGCGGC	p.Trp307_Pro311delinsSer	LP	PM2-S+PM3+PM4+PP4	NA
	Het	Ex5	c.543dupG	p.Leu182Alafs*16	P	PVS1+PS4_M+PM2_S+PM3	NA
P35	Het	Ex1	c.45_46delAG	p.Gly17Leufs*26	P	PVS1+PS4+PM2_S	Paternal
	Het	Ex2	c.319C>T	p.Gln107Ter	LP	PVS1+PM2_S	Maternal
P36	Het	Ex1	c.45_46delAG	p.Gly17Leufs*26	P	PVS1+PS4+PM2_S	Paternal
	Het	Ex6	c.905delA	p.Asn302Metfs*18	LP	PVS1+PM2_S+PM3	Maternal
P37	Het	Ex3	c.402_403insG	p.Pro135Alafs*2	LP	PVS1+PM2_S+PM3	Maternal
	Het	Ex4	c.503G>A	p.Trp168Ter	P	PVS1+PS4+PM2-S	Paternal
P38	Hom	Ex5	c.543dupG	p.Leu182Alafs*16	P	PVS1+PS4_M+PM2_S+PM3	Paternal maternal
P39	Hom	Ex4	c.503G>A	p.Trp168Ter	P	PVS1+PS4+PM2-S	Paternal maternal

Abbreviations: Het, heterozygous; Hom homozygous; Ex, exon; In, Intron; P, pathogenic; LP, likely pathogenic; VUS, variant of uncertain significance; PVS, pathogenic very strong; PS, pathogenic strong; PM, pathogenic moderate; PP, pathogenic supporting.

<sup>†</sup> According to the American College of Medical Genetics and Genomics interpretation guidelines.

<sup>‡</sup> Without confirmation of paternity and maternity

Table 2. Clinical features, urinary bile acid profiling, treatment, and outcome of patients with HSD3B7 deficiency

Patients	Gender	Age at onset	Age at first referral <sup>†</sup>	Presenting symptoms	Renal lesions	Urinary bile acids profiling <sup>§</sup>	Treatment after diagnosis	Status/age at last follow-up
P1	M	1.5mo	5.7mo	Neonatal cholestasis, hepatomegaly	-	+	UDCA × 2 y, CDCA × 9y4mo	Transaminase slightly elevated/11.3y
P2	M	10d	16.5mo	Renal cysts, abnormal liver biochemistries, hepatomegaly with a history of transient neonatal cholestasis,	+	+	UDCA × 2.5 y, CDCA × 7y6mo	Normal/11.2y
P3	M	5d	4.5mo	Neonatal cholestasis, hepatomegaly	-	NA	NA	Liver failure, then to lost follow-up/8mo
P4	F	7d	4.5mo	Neonatal cholestasis, hepatosplenomegaly	-	+	NA	Died/10mo
P5	M	5d	3.7mo	Neonatal cholestasis, hepatosplenomegaly	+	+	CDCA × 7y	Normal/7.3y
P6	M	16.8y	17.2y	Cholestasis, hepatosplenomegaly and then liver failure	+	NA	NA	Died/17.2y
P7	M	1mo	2.2mo	Neonatal cholestasis, coagulopathy, abdominal hematoma	-	+	NA	Lost follow-up/2.2mo
P8	F	3.5y	4.3y	Coagulopathy of vitamin K1 deficiency, abnormal liver biochemistries, hepatosplenomegaly	+	+	CDCA × 6y2mo	Normal/10.4y
P9	M	1mo	6.6mo	Neonatal cholestasis, hepatomegaly	-	+	CDCA × 5y8mo	Normal/6.2y
P10	M	2-3d	3.4mo	Neonatal cholestasis, hepatosplenomegaly	NA	+	CDCA × 6y	Normal/6.3y
P11	M	2d	5.2mo	Neonatal cholestasis, hepatomegaly	-	+	CDCA × 12d	Liver biochemistries improved/6mo
P12	F	1.5mo	2.6mo	Neonatal cholestasis	NA	+	CDCA × 2y4mo	Normal/2.5y
P13	F	10d	2mo	Neonatal cholestasis, hepatomegaly	-	+	CDCA × 3y10mo	Normal/4y
P14	M	2mo	6.3mo	Neonatal cholestasis	-	+	CDCA × 4y	Normal/4.5y
P15	F	3d	6.6y	Recurrent cholestasis, splenomegaly	+	+	CDCA × 2y11mo	Normal/9.5y
P16	F	3d	5.8mo	Neonatal cholestasis	+	+	CDCA × 3y4mo	Normal/3.8y
P17	F	2mo	4.8mo	Neonatal cholestasis, hepatomegaly	NA	+	CDCA × 2y5mo	Normal/2.8y
P18	F	1mo	4.6mo	Neonatal cholestasis	-	+	CDCA × 2y9mo	Normal/3.2y
P19	M	3d	1.7mo	Neonatal cholestasis	-	+	CDCA × 1y9mo	Normal/1.9y
P20	M	2d	5.5mo	Neonatal cholestasis, hepatosplenomegaly	NA	+	CDCA × 2y5mo	Normal/2.8y
P21	M	10d	11.5mo	Neonatal cholestasis, liver failure, hepatosplenomegaly	+	+	CDCA × 10d, then liver transplanted	Aliver/4.8y
P22	M	3-4d	4.9y	liver cirrhosis, hepatosplenomegaly with a history of transient neonatal cholestasis	+	+	CDCA × 3y	Normal/7.9y
P23	M	1mo	8.7mo	Neonatal cholestasis	-	+	UDCA × 9mo	Hyperbilirubinemia resolved and transaminase slightly elevated / 10mo
P24	M	11d	2.4mo	Neonatal cholestasis, hepatosplenomegaly	-	+	CDCA × 2y1mo	Normal/2.3y
P25	M	3d	3mo	Neonatal cholestasis, hepatosplenomegaly	-	+	CDCA × 3mo, then	Aliver/3.4y

								liver transplanted	
P26	M	1mo	2.2mo	Neonatal cholestasis	-	+	CDCA × 3y2mo	Normal/3.4y	
P27	M	7d	2.2mo	Neonatal cholestasis	-	+	CDCA × 1y1mo	Normal/1.3y	
P28	M	18d	8mo	Neonatal cholestasis	-	+	CDCA × 3mo, then liver transplanted	Died / 11mo	
P29	M	3d	4.6mo	Neonatal cholestasis	-	+	CDCA × 2y2mo	Normal/2.5y	
P30	M	7d	7.8mo	Neonatal cholestasis	-	+	CDCA × 3mo, then liver transplanted	Alive/2.7y	
P31	F	4y	5.2y	Liver cirrhosis, splenomegaly	-	+	CDCA × 2y6mo	Normal/7.7y	
P32	F	3d	3.3mo	Neonatal cholestasis	-	+	CDCA × 1y5mo	Normal/1.7y	
P33	F	3d	5mo	Neonatal cholestasis	-	+	CDCA × 12mo	Normal/1.4y	
P34	M	3d	1.8mo	Neonatal cholestasis	-	+	CDCA × 3mo, then liver transplanted	Alive/1.3y	
P35	F	4.5y	4.7y	Liver cirrhosis, splenomegaly	+	+	CDCA × 11mo	Hypersplenism improved/5.7y	
P36	M	1mo	4.4mo	Neonatal cholestasis	-	NA	CDCA × 1mo	Died / 6mo	
P37	M	1mo	1.8y	Neonatal cholestasis, liver failure	+	NA	CDCA × 4mo	Liver biochemistries and coagulopathy improved /2.1y	
P38	F	3d	4mo	Neonatal cholestasis	-	NA	CDCA × 4mo	Hyperbilirubinemia resolved /7mo	
P39	F	2d	4.7mo	Neonatal cholestasis	-	NA	CDCA × 1mo	Liver biochemistries improved/5.7mo	

Abbreviations: + positive, - negative; M, male; F, female; d, day; mo, month; y, year; NA, not available; UDCA, ursodeoxycholic acid; CDCA, chenodeoxycholic acid; † age at first visit to our center; ‡ If renal imagine indicate renal lesions, the result is positive; § If FAB-MS profile show an absence or a lack of the normal primary bile acid conjugates and marked elevations of atypical 3β-hydroxy-Δ<sup>5</sup>-bile acids, the result is positive and supports a diagnosis of 3β-HSD deficiency

Table 3. Liver chemistries in two groups of patients with HSD3B7 deficiency

	TB (μmol/L)	DB (μmol/L)	ALT (U/L)	AST (U/L)	GGT (U/L)	TBA (μmol/L)	Alb (g/L)	TCH (μmol/L)
Age of first referral before 1y (n=31)	133.9 (41.4-436)	70.1 (23.3-327.1)	152(36-938.4)	197 (76-1526.8)	33 (15-65.1)	5 (0.2-85.4)	41.7 (37-49.8)	4.08 (2.9-8.56)
Age of first referral after 1y (n=8)	30.7 (15.3-96)	19 (3.6-68)	49 (26-217.1)	61 (34-385)	17 (8-70)	4 (1-14)	41.7 (32.2-46)	2.57 (1.54-2.81)
P values	<0.001	<0.001	0.006	0.001	0.002	0.505	0.406	0.001
Reference range	3.4-17.1	0-6	7-40	13-35	≤100	0-10	40-55	0-5.18

Note: For continuous variables, medians, ranges and sample sizes are shown.

Abbreviations: y, year; TB, total bilirubin; DB, direct bilirubin; ALT, alanine transaminase; AST, aspartate transaminase; GGT, gamma glutamyl transpeptidase; TBA, total bile acids; Alb, albumin; TCH, total cholesterol.

Table 4. Manifestations of renal lesion and its revolution in patients with HSD3B7 deficiency

Patient	Age at first imaging	Renal imagine before chenodeoxycholic acid (CDCA) administration		Renal Tests		Management	Status of renal lesions/ age at last follow-up
		Ultrasound	Magnetic Resonance Imagine	Serum Cr (μmol/L)	Urinalysis		
P2	16.5mo	Medullary sponge kidney with with calcification	Multiple small cystic high signal in bilateral renal medulla	33.8	Normal	UDCA × 2.5 y, CDCA 10mg/kg/day × 7y6mo	Normalized/11.2y
P5	3.7mo	Multiple abnormal echoes in the calyx	NA	13	Normal	CDCA 10mg/kg/day × 7y	Normalized/7.3y
P6	17.2mo	Renal stones	Renal cysts	29	Normal	-	NA
P8	4.3y	Renal stones	NA	18	Normal	CDCA 10mg/kg/day × 6y2mo	Normalized/10.4y
P15	6.6y	Renal cysts with calcification	NA	36	Normal	CDCA 8mg/kg/day × 3mo, 10mg/kg/day × 2y8mo	NA
P16	5.8mo	Renal cysts	Progressively abnormal signals	14	Normal	CDCA 10mg/kg/day × 5.5mo	Normalized/3.8y
P21	11.5mo	Calcium deposition	NA	8	Normal	CDCA 8mg/kg/day × 7d, 6mg/kg/day × 4d, then liver transplanted × 18mo	Normalized/4.8y
P22	4.9y	Renal cysts	NA	25	Normal	CDCA 8mg/kg/day × 21d, 5mg/kg/day × 4mo, 6mg/kg/day × 31mo	Normalized/7.9y
P35	4.7y	Bilateral renal enlargement	NA	29	Normal	CDCA 3mg/kg/day × 11mo	Improved/5.7y
P37	1.8y	Renal cysts	Renal cysts	17	Normal	CDCA 4.5kg/kg/day × 4mo	NA

Abbreviations: NA, not available.

## Figures

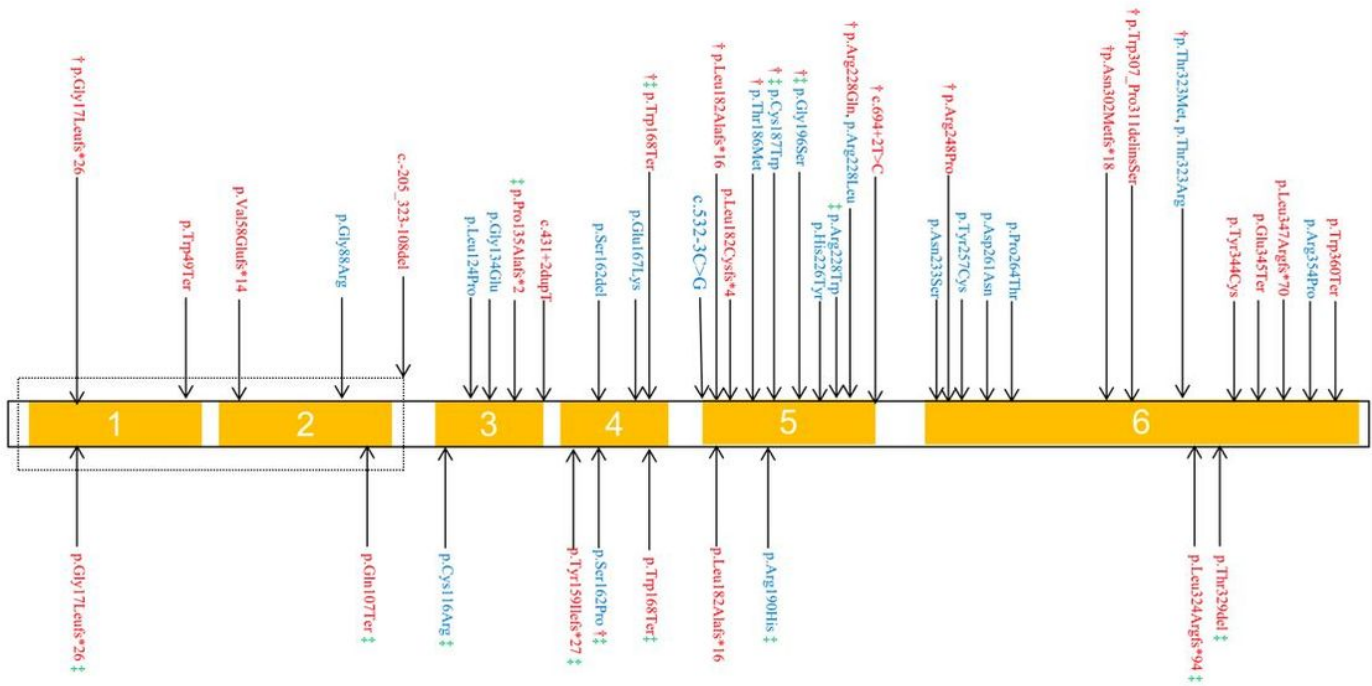
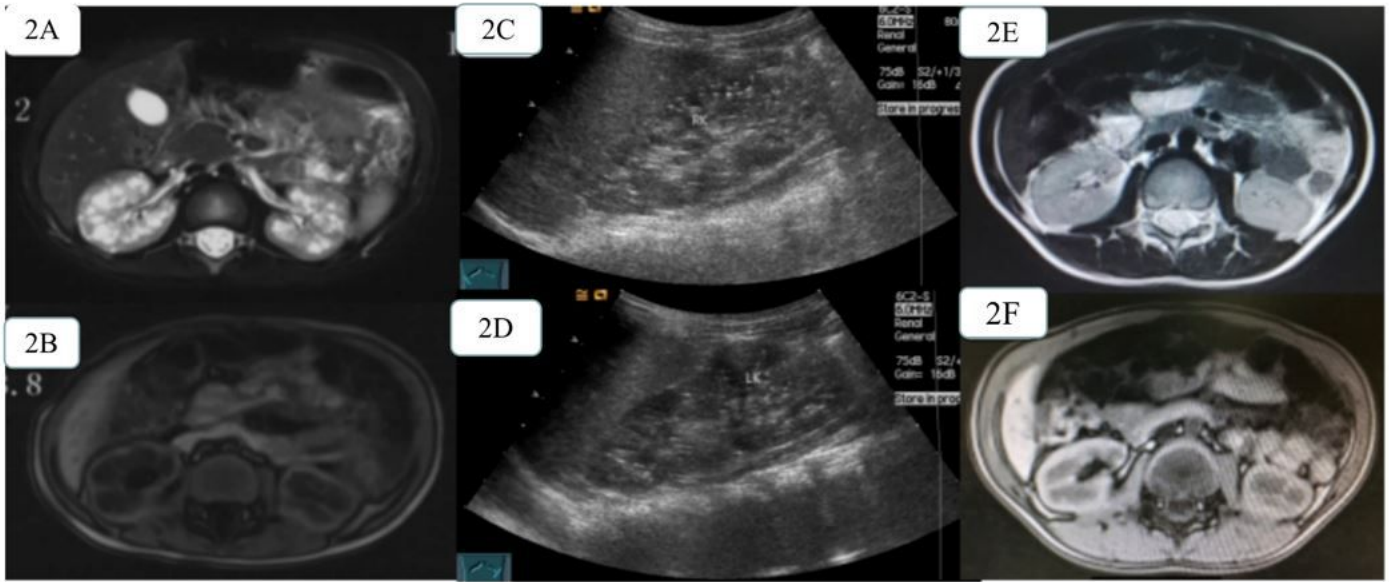


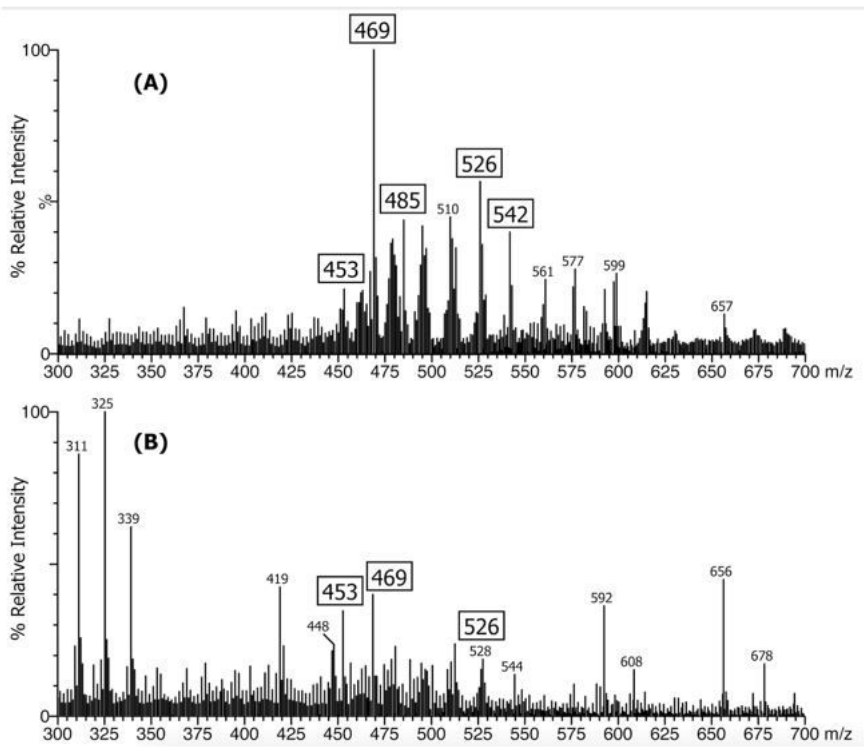
Figure 1

Schematic representation of variant locations in HSD3B7 from 39 children with HSD3B7 deficiency. A total of 44 variants were identified in this study and presented here. Each arrow represents one variant. Variants detected in patients presenting as neonatal cholestasis are shown on the top and variants detected

in the later onset occurrence patients are shown on the bottom. Variants from patients liver transplanted or died are marked with †, and variants from patients with renal lesions are marked with ‡. Pathogenic or likely pathogenic variants are shown in red, variants with uncertain significance in blue.



**Figure 2**  
Evolution of renal lesions in patient 2. Before the commencement of chenodeoxycholic acid (CDCA) administration, diminished corticomedullary differentiation and multiple small cystic were revealed with high signal on T2WI-FS (2A) and low signal on T1WI-Flash (2B) in bilateral renal medulla by MRI. It presented as bilateral renal sponge-like degeneration with point-like deposition of calcium salts by renal ultrasound (2C and 2D). After CDCA treatment over a period of about 33 months (2012.2-2014.11), MRI showed no renal lesions at all in the same patient.



**Figure 3**  
The negative ion FAB-MS spectrum of the urine from patients consistent for HSD3B7 deficiency and patient 21. A, the mass spectrum reveals marked elevations in sulfate and glyco-sulfate conjugates of dihydroxy- and trihydroxy-cholenic acids (i.e. unsaturated C24 bile acids) evidenced by the pairs of ions

at m/z 469, 485 (sulfate conjugates) and m/z 526, 542 (glyco-sulfate conjugates). B, the mass spectrum of patient 21 show low intensity ions for these atypical 3  $\beta$ -hydroxy- $\Delta$ 5 bile acid that are the biomarkers for HSD3B7 deficiency due to the more advanced liver disease and loss of synthetic function

## Supplementary Files

This is a list of supplementary files associated with this preprint. Click to download.

- [0428Supplementarytables.docx](#)