

Liver Transplantation Is Highly Effective in Children With Irresectable Hepatoblastoma

Simon Moosburner

Charite University Hospital Berlin: Charite Universitätsmedizin Berlin

Moritz Schmelzle

Charite University Hospital Berlin: Charite Universitätsmedizin Berlin

Brigitta Globke

Charité Universitätsmedizin Berlin: Charite Universitätsmedizin Berlin

Wenzel Schöning

Charité Universitätsmedizin Berlin: Charite Universitätsmedizin Berlin

Angelika Eggert

Charité Universitätsmedizin Berlin: Charite Universitätsmedizin Berlin

Philippa Seika

Charité Universitätsmedizin Berlin: Charite Universitätsmedizin Berlin

Anika Kästner

Universitätsmedizin Greifswald: Universitätsmedizin Greifswald

Johann Pratschke

Charite University Hospital Berlin: Charite Universitätsmedizin Berlin

Robert Öllinger

Charite University Hospital Berlin: Charite Universitätsmedizin Berlin

Safak Gül-Klein (✉ safak.guel@charite.de)

Charité Universitätsmedizin Berlin: Charite Universitätsmedizin Berlin <https://orcid.org/0000-0003-1013-7126>

Research

Keywords: Hepatoblastoma, Pediatric Liver Transplantation, Pediatric Liver Resection, Survival, Postoperative Complications

Posted Date: May 7th, 2021

DOI: <https://doi.org/10.21203/rs.3.rs-473238/v1>

License: © ⓘ This work is licensed under a Creative Commons Attribution 4.0 International License.

[Read Full License](#)

Abstract

Introduction

In children, hepatoblastoma preferentially is managed by liver resection (LR). However, in irresectable cases, liver transplantation (LT) is required. Aim of our study was to compare short- and long-term results after LR and LT for the curative treatment of hepatoblastoma.

Materials and methods

Retrospective analysis of all patients treated surgically for hepatoblastoma from January 2000 till December 2019. Demographic and clinical data were collected before and after surgery. Primary endpoints were disease free survival and patient survival.

Results

In total, 38 patients were included into our analysis (n=28 for LR, n=10 for LT) with a median follow up of 5 years. 36 patients received chemotherapy prior to surgery. Total hospital stay and intensive care unit (ICU) stay were significantly longer within the LT vs. the LR group (ICU 23 vs. 4 days, hospital stay 34 vs. 16 days, respectively; $p < 0.001$). Surgical complications (\leq Clavien-Dindo 3a) were equally distributed in both groups (60% vs. 57%; $p = 1.00$). Severe complications (\geq Clavien-Dindo 3a) were more frequent after LT (50% vs. 21.4%; $p = 0.11$). Recurrence rates were 7% for LR and 0% for LT at 5 years after resection or transplantation ($p =$). Overall, 5-year survival was 90% for LT and 96% for LR ($p = 0.44$).

Conclusion

In unresectable cases, liver transplantation reveals excellent outcomes in children with hepatoblastoma with an acceptable number of perioperative complications.

Introduction

Primary hepatic tumors in children account for about 1% of all childhood malignancies. Hepatoblastoma is the most common malignant hepatic tumor with 90%^{1,2}. Despite hepatoblastoma remaining a relatively rare disease, hepatoblastoma has shown an annual increase in incidence of 4.3% in children under the age of 19, especially in countries with a high human development index³⁻⁵.

Patients generally remain asymptomatic and are diagnosed in a progressed state of the disease, requiring a multimodal treatment strategy of chemotherapy (CTx) and surgery. Staging is performed through the PRE-Treatment EXtent of disease (PRETEXT) system, a radiological score for risk stratification prior to neoadjuvant chemotherapy influencing the method of surgical treatment⁶.

Over the past three decades, several multicenter study groups have introduced effective risk-based chemotherapeutic regimens, which in combination with more aggressive surgical approaches, including

liver transplantation (LT), have resulted in significant improvements in outcomes⁷⁻¹². Nevertheless Hiyama et al., for the Japanese Study Group for Pediatric Liver Tumors, recently showed that neoadjuvant and adjuvant CTx with cisplatin-tetrahydropyranyl-adriamycin (pirarubicin; CITA) was effective for resectable hepatoblastoma, but remained unsatisfactory for unresectable and metastatic hepatoblastoma patients¹². After CTx, surgical completion through LR or LT, if hepatoblastoma remains unresectable, in the following phase can lead to a completely curative treatment¹³.

Primary resectability implies radical surgical resection as a first-line therapy. Nevertheless, curative LR after successful tumor reduction remains a challenge, especially in cases of extensive liver resection. LT is in turn the treatment of choice for unresectable tumors (bilobar localization, vascular infiltration) and in cases of expected excessive parenchymal loss by radical resection^{14,15,16,17}. Overall, an improvement in survival rates, with 5-year survival rates as high as 90%, has been observed over the past four decades^{18,19}. Advanced hepatoblastoma requires a decision to be made between a complex and radical LR or alternatively a LT, which is also known as a complex procedure - especially in infants. LT as well as extended resections for metastatic and locally advanced hepatoblastoma after neoadjuvant chemotherapy require referral to centers with expertise in both pediatric transplantation and hepatobiliary surgery. Preoperative imaging may identify hepatoblastomas as presumptively inoperable and subvert surgical exploration. Synchronous pulmonary metastases are seen in approximately 20% of cases and, per se, are no contraindication for a radical surgical approach, however, this is an ongoing matter of discussion²⁰.

The aim of our study was to evaluate patients after LR and after LT in the postoperative course with respect to early and late complications and recurrence of hepatoblastoma.

Materials And Methods

Study Design and Participants

All patients with hepatoblastoma presenting at the Surgical Department, Campus Charité Mitte and Campus Virchow-Klinikum at Charité – Universitätsmedizin Berlin from 1990 to 2019 were included in the study.

Demographic and clinical data before and after surgery, i.e. age at presentation, gender, tumor size, presence of distant metastasis, values of alpha-fetoprotein (AFP), chemotherapy, type of surgery, postoperative complications, complication management, tumor recurrence/disease free survival and mortality for both groups were collected. Patients were followed up at regular time intervals through routine follow-up examinations. In addition, all unplanned inpatient stays were considered for both groups, with special attention given to readmissions that entailed re-operations or were associated with complications in general. PRETEXT staging was performed by our radiologists at the time of diagnosis according to standardized criteria⁶. Postoperative complications were classified after Clavien-Dindo. Cancer recurrence was defined as local recurrence or distant metastasis.

Immunosuppression was administered based on individualized protocols including calcineurin inhibitors, mycophenolate mofetil (MMF), mTOR inhibitors and steroids.

Patients who underwent LR before LT were included in the LT group. The study was approved by the institutional ethics board (EA2/267/20).

Surgical Technique

LT from deceased donors were donations after brain death only (DBD) due to regulations in Germany. DBD donors were chosen based on donor age, size of the donor organ, cause of death, laboratory values at time of organ donation, perspective cold ischemia time and frozen cut section analysis, if available. Living donors for partial living donor liver transplantation (LDLT) were carefully evaluated, including the ethics board of the German federal medical association ("Bundesärztekammer") and underwent S2/3 sectionectomy using a small median laparotomy. Full size organs were transplanted orthotopically whereas split grafts and grafts from living donors were placed in a modified piggy-back technique, using the recipients unified left and middle hepatic vein for venous anastomosis. Portal vein and arterial anastomoses were all performed in an end-to-end fashion using loupes or a microscope for magnification. Biliary anastomosis was performed in side-to-side technique with the addition of a T-Drain. If duct-to-duct anastomosis was not feasible a hepaticojejunostomy was performed with intraoperative placement of a Polyvinyl-drainage.

LR was performed as open surgery with a right subcostal incision and upper midline extension to the xiphoid. Intraoperative ultrasound was used to identify a dissection plane. Pringle's maneuver was prepared for use if needed. Parenchymal dissection was carried out using ultrasound dissection.

Statistical Analysis

Statistical analysis was performed using the software solutions *R* (version 4.0.3) and *R Studio* (version 1.25) for macOS (both: *R Foundation for Statistical computing*, Vienna, Austria). Graphs were plotted using GraphPad PRISM version 8.2 for macOS (GraphPad Software, La Jolla, CA, USA). Survival was analyzed using the Kaplan-Meier curves and compared with the log rank method. Data was tested for normality using the Shapiro-Wilk test and analyzed with a student's t-test or Mann-Whitney-U test accordingly. Data, unless otherwise stated, is reported as mean and standard deviation (SD) or median and interquartile range (IQR).

Results

Patient characteristics

During the analysis period 42 patients with suspected hepatoblastoma were surgically treated in the Charité – Universitätsmedizin Berlin. Of those 42 patients, 4 were excluded from our analysis due to final histopathology showing no hepatoblastoma (n = 2) or patients being lost to follow-up (n = 2). Median age

at time of presentation was 2 years (IQR 1 year). Median follow-up was 64 months for LR and 170 months for LT patients respectively.

Ten patients (26%) underwent LT for hepatoblastoma. Within these 10 patients, 5 patients received a graft from a living donor, the remaining 5 patients either a segment II/III split graft (n = 3) or a full-size graft (n = 2) from a deceased donor (supplemental table 2). For three patients, LT was a rescue procedure due to recurrent disease, small for size syndrome or cirrhosis in the remnant liver. Immunosuppression in the 10 LT patients was carried out as mono-therapy with tacrolimus (tac) in 5 patients, while 3 patients had dual-therapy (Tacrolimus and plus Mycophenolate mofetil). One patient received mono-therapy with Everolimus. A total of 28 patients underwent LR, amongst them 1 patient with a segment II resection, 3 patients with atypical resections including > 2 segments, 4 patients left-lateral hepatectomy (SII and III), 4 patients left hemihepatectomy, 7 patients right hemihepatectomy, 5 patients extended right hemihepatectomy and 4 patients extended left hemihepatectomy (supplemental table 2).

Tumor characteristics

Histopathological analysis showed the majority of tumors being of fetal origin (54% in LR group, 50% in LT group) and roughly a third of mixed origin. Macroscopical tumor free resection margins were achieved in all LT and LR patients. In four patients (14.3%) after LR, there was microscopical invasion by tumor cells in the resection margins (R1). Synchronous distant metastases did not differ between groups and affected one third of patients (p = 1.00). There were mostly lung metastases (n = 7) in the LR group and one bone and one spinal cord metastasis. One patient in the LT group had pulmonary metastases and two patients lymphonodal metastases. Almost all (n = 27, 96.4%) patients after LR received adjuvant chemotherapy vs 10% in the patient group after liver transplantation.

Perioperative Complications

Surgical complications (\leq Clavien-Dindo 3a) were equally distributed in both groups (60% vs. 57%; p = 1.00). Severe complications \geq Clavien-Dindo 3a were more frequent in patients after LT (Table 1). Complications after LT were biliary complications (n = 3, 30.0%), hemorrhage (n = 2, 20%) and portal vein thrombosis (n = 2; 20%). After LR, biliary complications were most common (n = 5; 17.9%, vs. 30% for LT; p = 0.41) followed by hemorrhage (n = 3; 10.7%, vs. 20% for LT; p = 0.59) (Table 2).

Table 1
Liver Transplantation and Liver Resection compared

	Liver Resection	Liver Transplantation	<i>p</i>
	N = 28	N = 10	
Sex [f]	10 (35.7%)	7 (70.0%)	0.078
Age [years]	1.00 [0.00;2.00]	2.00 [2.00;3.00]	0.069
Age Groups [years]			0.328
< 1	9 (32.1%)	1 (10.0%)	
1–2	13 (46.4%)	5 (50.0%)	
≥ 3	6 (21.4%)	4 (40.0%)	
PreTEXT			0.002
1	7 (25.9%)	0 (0.00%)	
2	10 (37.0%)	0 (0.00%)	
3	9 (33.3%)	5 (55.6%)	
4	1 (3.70%)	4 (44.4%)	
Metastasis	8 (28.6%)	3 (30.0%)	1.000
Metastasis Localization			0.101
bone and spinal	1 (3.57%)	0 (0.00%)	
lung	7 (25.0%)	1 (10.0%)	
Operative Time [min]	168 (50.5)	392 (103)	< 0.001
Hospital Stay [d]	15.5 [10.0;21.2]	34.0 [28.0;44.0]	0.001
Intensive Care Unit [d]	3.50 [2.00;6.00]	23.0 [19.0;29.0]	< 0.001
Complications	16 (57.1%)	6 (60.0%)	1.000
Clavien-Dindo			0.087
0	12 (42.9%)	4 (40.0%)	
1	2 (7.14%)	0 (0.00%)	
2	8 (28.6%)	1 (10.0%)	
3a	1 (3.57%)	0 (0.00%)	
3b	2 (7.14%)	5 (50.0%)	

	Liver Resection	Liver Transplantation	<i>p</i>
4a	3 (10.7%)	0 (0.00%)	
Follow-up in Days	1876 [947;2608]	5168 [1486;6805]	0.104
Follow-up in Months	64.0 [42.0;91.5]	170 [52.5;224]	0.127
Follow-up in years	5.00 [3.00;7.00]	14.0 [4.25;18.5]	0.093
Neoadjuvant Chemotherapy	27 (96.4%)	9 (90%)	0.43
Adjuvant Chemotherapy	27 (96.4%)	1 (12.5%)	<0.001
AFP			0.178
< 999	0 (0.00%)	1 (12.5%)	
1,000–9,999	5 (20.8%)	0 (0.00%)	
10,000–99,999	6 (25.0%)	4 (50.0%)	
100,000-999,999	11 (45.8%)	3 (37.5%)	
> 1,000,000	2 (8.33%)	0 (0.00%)	

Table 2
Complications after Liver Transplantation and Liver Resection

	Liver Resection	Liver Transplantation
	N = 28	N = 10
Early Complications		
Biliary	5 (17.86%)	3 (30%)
Vascular	0 (0%)	2 (20%)
Bleeding	3 (10.71%)	2 (20%)
Infection	0 (0%)	1 (10%)
Acute rejection	0 (0%)	1 (10%)
Other	2 (7.14%)	0 (0%)
Late Complications		
Ototoxicity	3 (10.71%)	0 (0%)
Adhesions	0 (0%)	1 (10%)
Immunosuppression side-effects	0 (0%)	1 (10%)
Bile strictures	2 (7.14)	0 (0%)
Recurrence	3 (10.71%)	0 (0%)

One patient after LT had impaired renal function postoperatively without the necessity of dialysis. One patient rejected once resolved by corticosteroid pulse treatment. Another patient suffered from two phases of acute rejection both successfully treated with steroids. One patient suffered from one instance of short-term leukopenia under tacrolimus therapy.

Long Term Complications and Survival

Two patients after LR suffered from chronic bile strictures and required frequent endoscopic therapy. Three patients in the LR group had tumor recurrence, one month, 6 months and 8 months after resection, by the means of metachronous pulmonary metastases and in one case additional intrahepatic metastases.

The 1-,5-,10-year recurrence-free rates were 89%, 89%, 89% for LR and 100%,100%, 100% for LT ($p = 0.94$). Overall survival 1-,5-,10-year survival was 90%,90,90% for LT and 96%,96%,96% for LR ($p = 0.44$) (Fig. 1). One patient died after emergency adhesiolysis surgery as a result of his abdominal sepsis three months after LT. The second patient died due to septic shock caused to pneumococcal infection 23 years after LT.

One patient in the LR group, who had already undergone surgery in an M1 setting (pulmonary, osseous metastases), died 3 months after LR due to extensive intrahepatic recurrence after initial R0 resection with all other patients being alive at the date of the last follow up.

Discussion

Hepatoblastoma is a rare, but the most frequent intrahepatic malignancy of the childhood. In general, hepatoblastomas are diagnosed at a late stage with often large size and frequent vascular infiltration²¹. Neoadjuvant CTx is the gold standard before surgical resection. Excellent results can be achieved with a monotherapy of cisplatin in standard risk tumors, cisplatin alternating with carboplatin-doxorubicin in high risk tumors and dose-intensive weekly cisplatin/doxorubicin induction therapy for very high risk tumors by the means of shrinkage of the primary tumor and control of distant metastasis¹⁰. A combination of chemotherapy and resection reaches survival rates of 81.5% and 81.0% at 5/10 years^{30,31}. However, despite advances in CTx, in certain cases, resection is not always feasible for anatomical or functional reasons, leaving LT as the only curative option²². We herein analyzed our own data comparing outcomes in children with hepatoblastoma after resection with LT.

Demographic data showed an equal distribution in both groups. As expected, in the LT cohort, disease severity according to PRETEXT was significantly higher. Similarly, Kulkarni et al. demonstrated that patients with bilobar involvement were more likely to receive LT based on an analysis of the National Cancer Database for surgical therapy of pediatric hepatoblastoma. However, patients in the LT group had a longer overall time from diagnosis to surgery associated with waiting list time in addition to neoadjuvant chemotherapy²³. With respect to early and late complications, long-term course and metastases, the results of our analysis show an equal distribution in both groups. Interestingly, none of the patients developed hepatic local recurrence or intrahepatic metastasis after LT and only three patients after LR.

Nevertheless, the decision, when to opt for surgical resection, LT or CTx without surgical intervention can become a balancing act: In general, the basic recommendation for LT in PRETEXT stage IV tumors and centrally placed PRETEXT stage III tumors with infiltration of vascular structures after neoadjuvant CTx is primary resection²⁴. Additionally, according to the current surgical guidelines of the Children's Oncology Group, children with suspected inoperable findings should be referred to a specialized center at an early stage, so that a decision between liver tumor resection and transplantation by a liver specialist can be made²⁵. Especially, as LT as an emergency therapy after primary LR with a small for size liver remnant or in case of a relapse after LR must be considered, as described for one patient in our cohort. The decision-making process for the most suitable therapy after neoadjuvant CTx is determined by specific tumor characteristics, such as particularly hepatoblastoma size, critical anatomical localization for LR (involvement of vascular/biliary structures, multicenter localization) and probable function of the future liver remnant^{17,26-28}. As Meyers et al. showed, the Children's Hepatic Tumors International Collaboration (CHIC), has created a unified global approach to risk stratification for children with hepatoblastoma²⁹.

Regardless of this, molecular biological studies on prognostic tumor markers may play a decisive role in risk stratification and optimized patient selection in the future and will have the potential to increase the number of primarily resectable patients.

Excellent tumor control was achieved in our series with the combination of CTx and LT, considering that immunosuppression would be assumed bearing a higher recurrence risk (e.g. like in hepatocellular carcinoma in adults)³⁵. There was no incidence of local recurrence or secondary malignant tumors in our LT group.

Due to concerns for the transplanted graft, only one patient received adjuvant chemotherapy after LT (i.e. our patient with pulmonary metastases). In contrast, 96.4% of the patients in the LR group received adjuvant treatment. This is of special interest, as the recurrence rate was 0% in the LT group. While there is no unique strategy or consent on adjuvant chemotherapy after LT, admittedly there are centers following this concept. Without any decisive evidence, this decision probably has to be made on an individualized level. SIOPEL-1 and the World Experience Review showed even superior survival rates of 85% at 10 years and 82% at 10 years after primary transplantation^{30,31}. Zsiros et al. showed in the SIOPEL-3 and-4 studies that transplantation was associated with a 75% 3-year survival rate^{32,33}.

With respect to peri- and post-operative complications, these were comparable in our cohort between both groups. However, as expected, operative time, ICU stay and hospital stay were considerably longer in the LT group, matching the study by Kulkarni et. al.²³. In general, outcomes after LT in pediatric patients are superior to adults, independent of donor or indication for transplantation, reaching 1-year survival rates of up to 95%³⁴. Adults undergoing LT for malignant tumors, have unsatisfactory outcomes, in part due to tumor recurrence. Certainly, hepatocellular carcinoma or cholangiocellular carcinoma cannot be directly compared to hepatoblastoma with respect to long term recurrence outcomes, however, hepatoblastoma patients must be considered for LT in unresectable cases, despite donor organ scarcity due to the excellent results.

Limitations of our study are the small sample size, the retrospective study design and the variance in the different therapy strategies. However, data to hepatoblastoma are not widely published and we feel indeed, that our study adds to previously published research.

In conclusion, we want to highlight the necessity of a detailed assessment by an experienced interdisciplinary team in a center for HPB, pediatric and transplant surgery for LR in hepatoblastoma, especially in advanced cases. Results after CTx plus LT in advanced cases of HB are excellent and long term outcome is comparable to resection in combination with CTx.

Abbreviations

CITA	cisplatin-tetrahydropyranyl-adriamycin
CTx	chemotherapy
HEPATOBLASTOMA	Hepatoblastoma
HEPATOBLASTOMA99	Carboplatin/VP16
HDI	high human development index
ICU	Intensive care unit
IPA	Ifosfamide, Cisplatin, Doxorubicin
LDLT	Living Donor Liver Transplantation
LT	Liver Transplantation
LR	Liver Resection
MMF	Mycophenolate Mofetil
PRETEXT	Pretreatment Extent of Disease
SIOPEL	International Childhood Liver Tumors Strategy Group

Declarations

Ethics approval and consent to participate

We hereby declare that our work contains an ethical approval and consent of the Ethics Committee of the Charité - Universitätsmedizin Berlin (EA2/267/20).

Consent for publication

Not applicable

Availability of data and materials

The data sets used and/or analyzed in the current study are available on reasonable request from the corresponding author and with approval of the ethics committee of Charité - Universitätsmedizin Berlin.

Competing interests

The authors declare that they have no competing interests.

Funding

Dr. Simon Moosburner and Dr. Brigitta Globke are participants in the BIH-Charité Clinician Scientist Program funded by the Charité – Universitätsmedizin Berlin and the Berlin Institute of Health.

Authors' contributions

SM, SGK, RÖ designed and wrote the manuscript. AK and PS collected data. AK completed and approved all data. SM, SGK interpreted and statistically analyzed the data. All authors read and approved the final manuscript.

Acknowledgements

We acknowledge support from the German Research Foundation (DFG) and the Open Access Publication Fund of Charité— Universitätsmedizin Berlin for open access publication costs.

References

1. Litten JB, Tomlinson GE. Liver Tumors in Children. *The Oncol.* 2008;13(7):812-820. doi:10.1634/theoncologist.2008-0011
2. Darbari A. Epidemiology of primary hepatic malignancies in U.S. children. *Hepatology.* 2003;38(3):560-566. doi:10.1053/jhep.2003.50375
3. Hadzic N, Finegold MJ. Liver Neoplasia in Children. *Clinics in Liver Disease.* 2011;15(2):443-462. doi:10.1016/j.cld.2011.03.011
4. Hubbard AK, Spector LG, Fortuna G, Marcotte EL, Poynter JN. Trends in International Incidence of Pediatric Cancers in Children Under 5 Years of Age: 1988–2012. *JNCI Cancer Spectrum.* 2019;3(1):pkz007. doi:10.1093/jncics/pkz007
5. Allan BJ, Parikh PP, Diaz S, Perez EA, Neville HL, Sola JE. Predictors of survival and incidence of hepatoblastoma in the paediatric population. *HPB.* 2013;15(10):741-746. doi:10.1111/hpb.12112
6. Towbin AJ, Meyers RL, Woodley H, et al. 2017 PRETEXT: radiologic staging system for primary hepatic malignancies of childhood revised for the Paediatric Hepatic International Tumour Trial (PHITT). *Pediatr Radiol.* 2018;48(4):536-554. doi:10.1007/s00247-018-4078-z
7. Perilongo G, Shafford E, Plaschkes J. SIOPEL trials using preoperative chemotherapy in hepatoblastoma. *The Lancet Oncology.* 2000;1(2):94-100. doi:10.1016/S1470-2045(00)00018-8
8. Katzenstein HM, London WB, Douglass EC, et al. Treatment of Unresectable and Metastatic Hepatoblastoma: A Pediatric Oncology Group Phase II Study. *JCO.* 2002;20(16):3438-3444. doi:10.1200/JCO.2002.07.400
9. Sasaki F, Matsunaga T, Iwafuchi M, et al. Outcome of hepatoblastoma treated with the JPLT-1 (Japanese Study Group for Pediatric Liver Tumor) Protocol-1: A report from the Japanese Study Group for Pediatric Liver Tumor. *Journal of Pediatric Surgery.* 2002;37(6):851-856. doi:10.1053/jpsu.2002.32886
10. Perilongo G, Maibach R, Shafford E, et al. Cisplatin versus Cisplatin plus Doxorubicin for Standard-Risk Hepatoblastoma. *N Engl J Med.* 2009;361(17):1662-1670. doi:10.1056/NEJMoa0810613

11. Hishiki T, Matsunaga T, Sasaki F, et al. Outcome of hepatoblastomas treated using the Japanese Study Group for Pediatric Liver Tumor (JPLT) protocol-2: report from the JPLT. *Pediatr Surg Int*. 2011;27(1):1-8. doi:10.1007/s00383-010-2708-0
12. Hiyama E, Hishiki T, Watanabe K, et al. Outcome and Late Complications of Hepatoblastomas Treated Using the Japanese Study Group for Pediatric Liver Tumor 2 Protocol. *JCO*. 2020;38(22):2488-2498. doi:10.1200/JCO.19.01067
13. Kremer N, Walther AE, Tiao GM. Management of hepatoblastoma: an update. *Current Opinion in Pediatrics*. 2014;26(3):362-369. doi:10.1097/MOP.0000000000000081
14. Lim IIP, Bondoc AJ, Geller JI, Tiao GM. Hepatoblastoma—The Evolution of Biology, Surgery, and Transplantation. *Children*. 2018;6(1):1. doi:10.3390/children6010001
15. Pham TA, Gallo AM, Concepcion W, Esquivel CO, Bonham CA. Effect of Liver Transplant on Long-term Disease-Free Survival in Children With Hepatoblastoma and Hepatocellular Cancer. *JAMA Surg*. 2015;150(12):1150. doi:10.1001/jamasurg.2015.1847
16. Czauderna P, Otte JB, Aronson DC, et al. Guidelines for surgical treatment of hepatoblastoma in the modern era – Recommendations from the Childhood Liver Tumour Strategy Group of the International Society of Paediatric Oncology (SIOPEL). *European Journal of Cancer*. 2005;41(7):1031-1036. doi:10.1016/j.ejca.2005.02.004
17. Meyers RL. Liver transplantation in the management of unresectable hepatoblastoma in children. *Front Biosci*. 2012;E4(4):1293-1302. doi:10.2741/e460
18. Ezekian B, Mulvihill MS, Schroder PM, et al. Improved contemporary outcomes of liver transplantation for pediatric hepatoblastoma and hepatocellular carcinoma. *Pediatr Transplant*. 2018;22(8):e13305. doi:10.1111/petr.13305
19. Ismail H, Broniszczak D, Kaliciński P, et al. Changing treatment and outcome of children with hepatoblastoma: analysis of a single center experience over the last 20 years. *Journal of Pediatric Surgery*. 2012;47(7):1331-1339. doi:10.1016/j.jpedsurg.2011.11.073
20. Angelico R, Grimaldi C, Gazia C, et al. How Do Synchronous Lung Metastases Influence the Surgical Management of Children with Hepatoblastoma? An Update and Systematic Review of the Literature. *Cancers (Basel)*. 2019;11(11). doi:10.3390/cancers11111693
21. Shi Y, Commander SJ, Masand PM, Heczey A, Goss JA, Vasudevan SA. Vascular invasion is a prognostic indicator in hepatoblastoma. *Journal of Pediatric Surgery*. 2017;52(6):956-961. doi:10.1016/j.jpedsurg.2017.03.017
22. Feng J, Polychronidis G, Heger U, Frongia G, Mehrabi A, Hoffmann K. Incidence trends and survival prediction of hepatoblastoma in children: a population-based study. *Cancer Communications*. 2019;39(1):62. doi:10.1186/s40880-019-0411-7
23. Kulkarni S, Brauer DG, Turmelle Y, et al. Surgical Therapy for Pediatric Hepatoblastoma in the USA over the Last Decade: Analysis of the National Cancer Database. *J Gastrointest Canc*. Published online May 27, 2020. doi:10.1007/s12029-020-00421-z

24. Otte J-B. Progress in the surgical treatment of malignant liver tumors in children. *Cancer Treatment Reviews*. 2010;36(4):360-371. doi:10.1016/j.ctrv.2010.02.013
25. Meyers RL, Czauderna P, Otte J-B. Surgical treatment of hepatoblastoma. *Pediatr Blood Cancer*. 2012;59(5):800-808. doi:10.1002/pbc.24220
26. Pimpalwar AP, Sharif K, Ramani P, et al. Strategy for hepatoblastoma management: Transplant versus nontransplant surgery. *Journal of Pediatric Surgery*. 2002;37(2):240-245. doi:10.1053/jpsu.2002.30264
27. Lautz TB, Ben-Ami T, Tantemsapya N, Gosiengfiao Y, Superina RA. Successful nontransplant resection of POST-TEXT III and IV hepatoblastoma. *Cancer*. 2011;117(9):1976-1983. doi:10.1002/cncr.25722
28. Meyers RL, Tiao GM, Dunn SP, McGahren ED, Langham MR, On behalf of the Central Surgical Review Committee, Children's Oncology Group AHEP-0731, Treatment of Children with All Stages Hepatoblastoma. Surgical management of children with locally advanced hepatoblastoma. *Cancer*. 2012;118(16):4090-4091. doi:10.1002/cncr.26715
29. Meyers RL, Maibach R, Hiyama E, et al. Risk-stratified staging in paediatric hepatoblastoma: a unified analysis from the Children's Hepatic tumors International Collaboration. *The Lancet Oncology*. 2017;18(1):122-131. doi:10.1016/S1470-2045(16)30598-8
30. Otte J-B, Meyers RL, de Ville de Goyet J. Transplantation for liver tumors in children: Time to (re)set the guidelines? *Pediatr Transplantation*. 2013;17(8):710-712. doi:10.1111/petr.12160
31. Otte JB, Pritchard J, Aronson DC, et al. Liver transplantation for hepatoblastoma: Results from the International Society of Pediatric Oncology (SIOP) study SIOPEL-1 and review of the world experience. *Pediatr Blood Cancer*. 2004;42(1):74-83. doi:10.1002/pbc.10376
32. Zsiros J, Brugieres L, Brock P, et al. Dose-dense cisplatin-based chemotherapy and surgery for children with high-risk hepatoblastoma (SIOPEL-4): a prospective, single-arm, feasibility study. *The Lancet Oncology*. 2013;14(9):834-842. doi:10.1016/S1470-2045(13)70272-9
33. Zsíros J, Maibach R, Shafford E, et al. Successful Treatment of Childhood High-Risk Hepatoblastoma With Dose-Intensive Multiagent Chemotherapy and Surgery: Final Results of the SIOPEL-3HR Study. *JCO*. 2010;28(15):2584-2590. doi:10.1200/JCO.2009.22.4857
34. Özen J, Beime J, Brinkert F, Fischer L, Herden U, Grabhorn E. Short- and long-term results of liver transplantation according to age at transplant: a single center experience of 351 children. *Transpl Int*. Published online March 27, 2021. doi:10.1111/tri.13872
35. Croome KP, Wall W, Chandok N, Beck G, Marotta P, Hernandez-Alejandro R. Inferior survival in liver transplant recipients with hepatocellular carcinoma receiving donation after cardiac death liver allografts. *Liver Transpl*. 2013;19(11):1214-1223. doi:10.1002/lt.23715

Figures

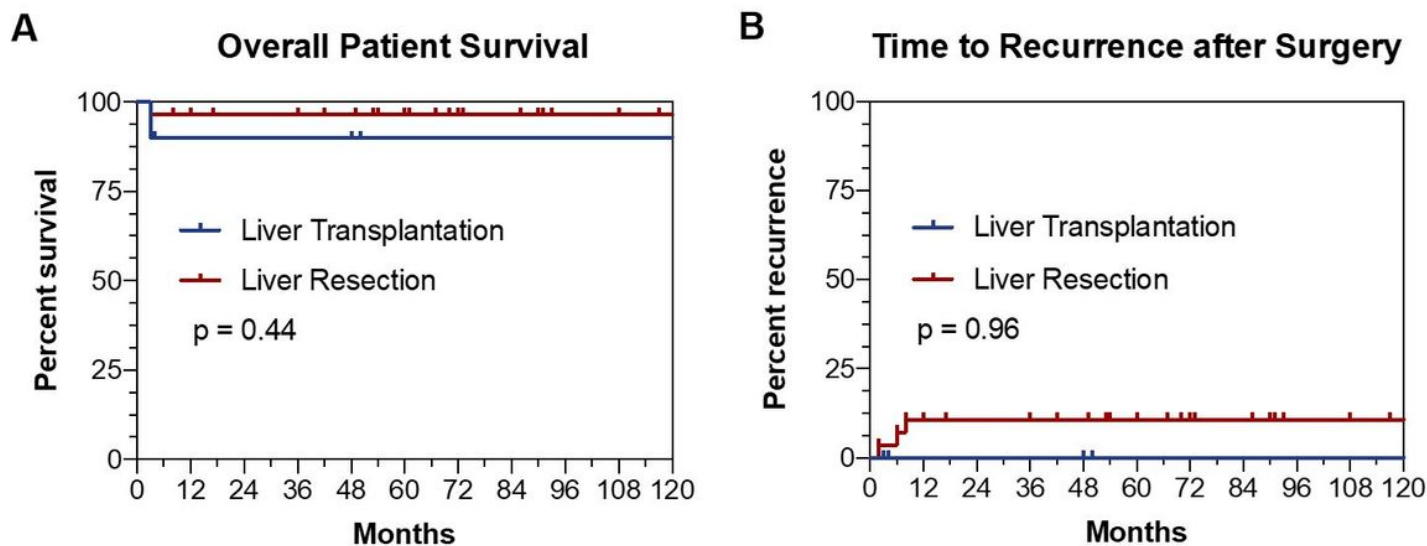


Figure 1

Patient survival after liver resection and liver transplantation. A Overall patient survival after liver resection or liver transplantation B Time to Recurrence after Surgery.