Research Square

Preprints are preliminary reports that have not undergone peer review. They should not be considered conclusive, used to inform clinical practice, or referenced by the media as validated information.

Perioperative Diabetes Insipidus: Report of two unusual cases

Nissar Shaikh (smaheboob@hamad.qa)
Hamad Medical Corporation
Muhmmad Zubair
Hamad Medical Corporation
Shoaib Nawaz
Hamad Medical Corporation
Zia Awan
Hamad Medical Corporation
Qazi zeeshan
Hamad Medical Corporation
Lance Marcus
Hamad Medical Corporation

Case Study

Keywords: Cervical discectomy, diabetes insipidus, desmopressin polyuria, hypernatremia, ventricular cyst

Posted Date: August 4th, 2020

DOI: https://doi.org/10.21203/rs.3.rs-46913/v1

License: This work is licensed under a Creative Commons Attribution 4.0 International License.
Read Full License

Abstract

Diabetes insipidus (DI) is a rare clinical condition in the post-operative period. Post-surgery polyuria is a common finding, as body excretes the excessive fluid given during surgery. It is important to diagnose and differentiate the DI from post-operative polyuria, as DI can lead to severe dehydration and electrolyte disturbances. We report two unusual cases of perioperative DI requiring desmopressin therapy.

Case1: A 46-year-old healthy male patient developed intraoperative DI leading to hypernatremia during the anterior cervical discectomy and fusion. Anaesthesia was maintained with propofol and remifentanil target-controlled infusion (TCI). After two hours of surgery, patient became polyuric and was passing diluted urine. He received desmopressin and hydration. Patient recovered, was transferred to the ward and discharged home without any clinical or neurological problems.

Case2: 36 years healthy male patient underwent elective 3rd ventricular cyst excision. Pre-anaesthesia assessment did not reveal any comorbidities and the surgery was uneventful. His anesthesia was maintained with propofol and remifentanil TCI (target-controlled infusion). In the post-operative period, he developed DI requiring hydration and desmopressin. Patient's further recovery was uneventful. He was discharged home through ward.

Conclusion: The occurrence of DI in above mentioned surgeries is very rare. Both surgical procedure and anaesthesia medications can cause perioperative DI.

Introduction

Diabetes insipidus (DI) is a clinical disorder of water metabolism in the human homeostasis, commonly resulting from the deficiency of antidiuretic hormone (ADH) or due to the inability of the kidney to respond normally to ADH. DI manifests as passing diluted copious amount of urine by the patient.[1] DI is classified as central or nephrogenic and pregnancy induced. In central DI, posterior pituitary gland fails to secrate ADH resulting in an absolute shortage. In contrast, nephrogenic DI is when the renal receptors do not respond adequately to an adequate level of ADH. Finally, pregnancy induced DI is when placenta consumes most of the secreted ADH, leading to ADH deficency.[2] DI is common after the pituitary gland surgeries.[3] There are a few case reports of DI after general surgical procedures.[4] Although polyuria is common in the post-operative period, it is important to diagnose DI to prevent severe dehydration and life-threatening electrolyte imbalance. We report two unusual cases of DI during the perioperative period requiring hydration and intravenous desmopressin.

Case1: A 49 years old healthy male was diagnosed with cervical vertebral disc prolapse (C5-6) and planned for an elective cervical discectomy and cage fusion. General anaesthesia was induced with etomidate and fentanyl, trachea was intubated under the effect of rocuronium. In addition, the patient received ketamine and cefazolin during induction. Anaesthesia was maintained by propofol and remifentanil target-controlled infusion (TCI) striving for a BIS (Bispectral Index) between 40 and 60. Foley's catheter was inserted before positioning the patient, for intraoperative measurement of urine

output (UOP). UOP was 50 to 70 ml for first two hours. During the procedure his hemodynamics were stable. In the 3rd hour of surgery he became polyuric and passed 700 to 800ml diluted urine in next 2 hours until the surgical procedure was over. He did not receive any diuretic or mannitol. He was started on 50ml/hour of 0.45% saline and shifted to post anaesthesia care unit. Still he remained polyuric and kept passing 300 and 400ml of diluted urine for the next 2 hours (Figure1). Finally, he developed hypernatremia although his renal functions were with in normal range and urine specific gravity was <1005, diagnosed to have central diabetes insipidus and was given intravenous (IV) 2 micrograms (µgrams) of desmopressin. For the next hours his urine became concentrated and urine output dropped to 50, 60 and 70ml/hour respectively (Figure1). Next day he was transferred to high dependency unit (HDU), remained stable, from there discharged home and followed up in neurosurgical outpatient clinics.

Case 2

A 36-year-old healthy male presented with on and off headache. After neuroimaging (Computer tomography-CT and MRI-magnetic resonance tomography) a cyst in the third ventricle was diagnosed. Due to this finding, he underwent right frontal craniotomy and excision of ventricular cyst. Anaesthesia was induced with propofol and remifentanil, trachea was intubated under the effect of rocuronium. He received cefazolin during the induction of anaesthesia. Anaesthesia was maintained with remifentanil and propofol TCI-infusion. Patient remained hemodynamically stable. His urine output remained 50 to 70 ml/hour during the surgical period. After the procedure the patient was transferred to the surgical intensive care unit (SICU) for further monitoring. In the SICU during the 1st and 2nd hour he passed 600ml and 700ml of diluted urine respectively (figure 2). His serum sodium increased to 148 mmol/litre. However, his renal functions were normal and urinary specific gravity was <1005. The patient was started on 100ml/hour of 0.45% saline and desmopressin 2 µgram was administrated intravenously. From the next hour his urine became concentrated and urine output dropped to 50 to 100ml/hour. The patient remained hemodynamically stable and serum sodium became normal. The next day he was transferred to the ward and from there discharged home. He was followed up in the neurosurgical outpatient clinic was without any issues.

Discussion

If not treated in time the diabetes insipidus (DI) will cause severe dehydration and life-threatening electrolyte disturbances. Hence it is of vital importance that DI should be differentiated from routine post-operative diuresis. [1,2,3] Increased post-operative diuresis occurs in 6.7% of craniotomies, 4% after cerebral aneurysm surgeries, and in 2% patients after traumatic brain injury. [5] In contrast most of the patients have polyuria in the post-operative period because they mobilize the excessive fluids transfused during the surgical procedure. We should also exclude other aetiologies for the polyuria such as hyperglycaemia and diuretic medication effects. The diagnosis of DI in the postoperative period should be done with combination of diluted polyuria (3 to 5 litres urine output with low specific gravity for 24 hours) and hypernatremia (serum sodium > 146 mmol/litre) with high index of suspicion. [6]

In the literature one case of DI was described after anterior cervical discectomy and laminoplasty.[7] Pinto et al. mentioned a case of diabetes insipidus in their case series of endoscopic treatment of 3rd ventricular colloidal cyst. [8] For both the cases of DI, there was no detailed explanation of the mechanism in the respective literature.

Both of our surgical patients were managed with propofol total intravenous anaesthesia. Soo et al. reported that DI was associated with propofol anaesthesia.[9] Maintenance of anaesthesia with propofol and remifentanil was also reported to cause diabetes insipidus.[10] Use of ketamine during anaesthesia also mentioned to cause diabetes insipidus.[11]

Concluding line from our case reports is that apart from the surgical causes we have to consider anaesthesia medications as one of the aetiologies for the perioperative DI.

Abbreviations

ADH Antidiuretic Hormone

BIS Bispectral index

CT Computed Tomography

DI Diabetes Insipidus

HDU High Dependency Unit

MRI Magnetic Resonance Imaging

SICU Surgical Intensive Care Unit

TCI Target Controlled Infusion

UOP urine output

Declarations

Ethics approval and consent to participate:

The study was approved from medical research center. Consent waiver was given by the ethics committee as it was a retroscopective observational study.

Consent for publication:

Not applicable. No personal data, images or videos are included in this study.

Availability of data and materials:

All data generated or analysed during this study are included in this manuscript of article or supplementary material.

Competing interests:

All authors declare that they do not have any competing interests in the publication of this study.

Funding:

Not applicable

Authors' contributions:

Nissar Shaikh (NS) contributed to the clinical care and data collection.

Acknowledgements

Not applicable

References

1. Saifan C, Nasr R, Mehta S, Acharya PS, Perrera I, Faddoul G, et al. diabetes insipidus: A clinical challenging diagnosis with new drug therapy. ISRN Nephro. 2013;2013:1–7.
2. Kalra S, Zargar AH, Jain SM, Sethi B, Chowdhury S, Singh AK, et al. diabetes insipidus. The other diabetes. Ind J Endocrinol Metab. 2016;20(1):9–21.
3. Hirotsugu M, Ryuji N, Hiroshi H. Nephrogenic diabetes mellitus during the Tran sphenoidal pituitary adenectomy. J neurosurg Anesth. 2016;28(1):79–80.
4. Yamashita H, Ishimaru M, Yanaguchi H, Yamauchi H, Sugiura A, et al. Massive post-operative polyuria following total gastrectomy Anesthesia. 2006;20(1):36–9.
5. Magbri A, El- Magbri E, Hershit S. hypernatremia and central diabetes insipidus following neurosurgical procedure after trauma. Arch Pathol Clin Res 2017:1;5–8.
6. Edate S, Albanese A. Management of Electrolyte and Fluid Disorders after Brain Surgery for Pituitary/Suprasellar Tumours. Horm Res Paediatr. 2015;83:293–301.

7. Kaplan L, Bronstein Y, barzilay Y, Hasharoni A, Finkelstein J. Canal expensive laminectomy in the management of cervical sponylotic myelopathy. IMAJ. 2006;8:548–22.
8. Pinto FCG, Chavantes MC, Fonoff ET, Teixeira MJ. Treatment of colloid cysts of the third ventricle through neuroendoscopic Nd:YAG laser stereotaxis. Arq. Neuro-Psiquiatr2009;67;1082-87.
9. Soo J, Gray J, Manecke G. propofol and diabetes insipidus. J Clin Anesth. 2014;26(8):679–83.
10. Kassebaum N, Hairr J, Goldsmith W, John Barwise J, Pandharipande PM. Diabetes insipidus associated with propofol anesthesia. J Clin Anesth. 2008;20:466–8.
11. Gaffar S, Jonathan P, Eskander BD, Beakley Brian P, McClure, Amenta P, Pierre N. A case of central diabetes insipidus after ketamine infusion during an external to internal carotid artery bypass. J Clin Anesthesia. 2017;36:72–5.

Figures

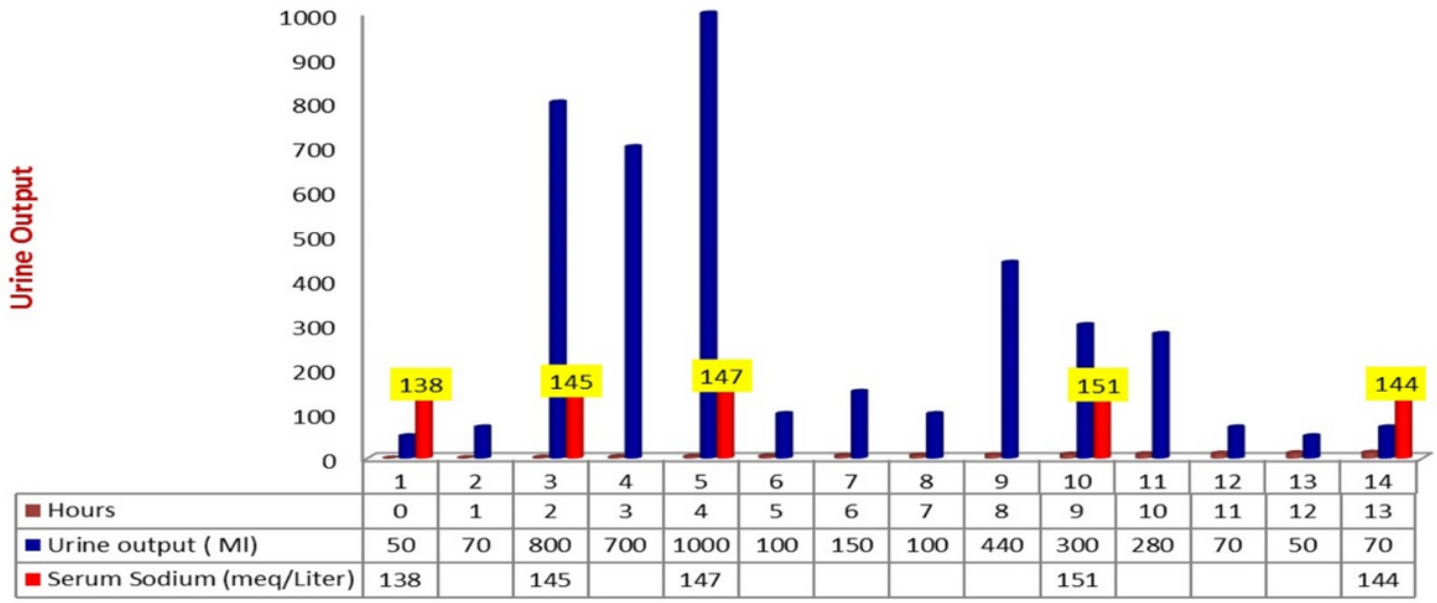

Figure 1

Urine out per hour (Case 1)

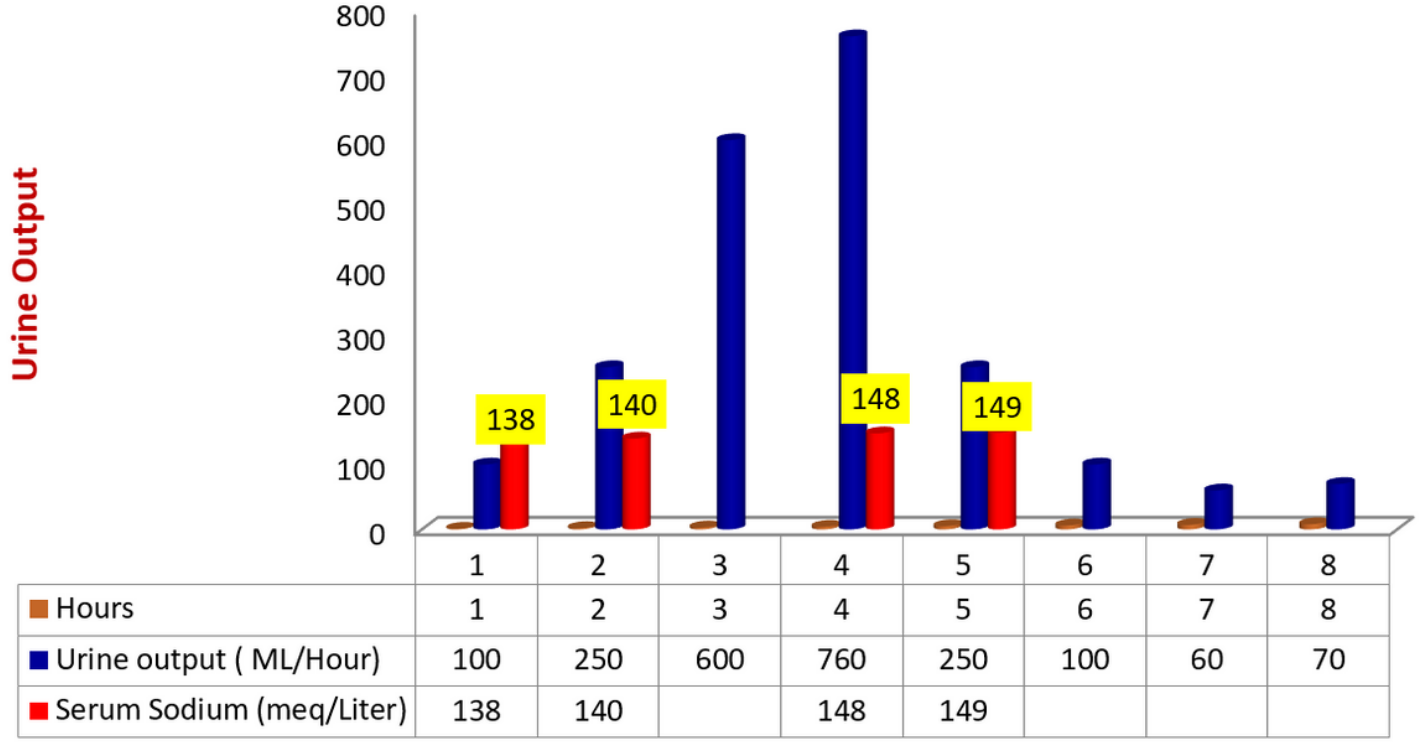

Figure 2

Urine out per hour (Case 2)