

Anatomical variability in the position of cystic artery and its affect on surgical approach during laparoscopic cholecystectomy

Muhammad Samir Irfan Wasi (✉ dr.sameerirfan@gmail.com)

Liaquat National Hospital and Medical College <https://orcid.org/0000-0002-2080-4212>

Omer Fateh

Sindh Government Qatar Hospital

Syed Muhammad Abdullah Bukhari

Sindh Government Qatar Hospital

Research article

Keywords: Laparoscopy, cholecystectomy, cystic artery variation, cystic duct, iatrogenic injury

Posted Date: July 23rd, 2020

DOI: <https://doi.org/10.21203/rs.3.rs-46689/v1>

License:   This work is licensed under a Creative Commons Attribution 4.0 International License.

[Read Full License](#)

Abstract

Background: The laparoscopic view of extrahepatic biliary tract and cystic artery is different anatomically from open approach. Consequently iatrogenic injuries due to inadvertent damage to cystic artery are not uncommon. These complications can be prevented by careful dissection in Calots triangle and better knowledge of laparoscopic anatomy of cystic artery and its variations. The aim of this study is to establish the prevalence of variation in position of cystic artery in relation to cystic duct in Asia's largest slum area. This will help identify the safe area for dissecting peritoneum in Calots triangle and thus help young surgeons overcome the long learning curve associated with laparoscopy.

Methods: During a 2 year period from 2018-2019, 192 laparoscopic cholecystectomies that were performed at a tertiary care hospital were studied. Patients above the age of 70 years, pregnant females, patients with history of previous abdominal surgery and the cases of conversion from laparoscopic to open cholecystectomy were excluded from the study. Cystic artery was divided into four groups based on its relative position to cystic duct. It includes superomedial, superolateral, anterior and absent cystic artery relative to the cystic duct.

Results: Out of 192 cases of laparoscopic cholecystectomy 174 (90.62%) patients had cystic artery superomedial to cystic duct and 10 (5.208%) had a cystic artery at superolateral position to cystic duct. In 5 (2.6%) patients it was found anterior to cystic duct and in 3 (1.56%) patients it was absent.

Conclusions: As the least common position of cystic artery was found to be anterior to cystic duct in our study, it is concluded that blind dissection from anterior side is the safest approach to avoid injury to cystic artery. This technique can help young surgeons overcome the long learning curve associated with laparoscopy.

Background

Cholelithiasis is one of the most common and prevalent surgical pathology all over the world^{1,2,3}. The laparoscopic view of extrahepatic biliary tract and cystic artery is different anatomically from view in open approach. The introduction of laparoscopic technique has revolutionized the management of cholelithiasis. Although it has a very long learning curve, yet it is now the standard procedure for symptomatic cholelithiasis⁴ as it offers significant benefits over open technique.⁵

Despite its advantages laparoscopic cholecystectomy was initially associated with a higher number of iatrogenic bile duct injuries and arterial haemorrhages^{6,7}. This was due to the fact that a surgeon who is used to the open technique has to deal with novel anatomical relations. The learning curve of the procedure is long and poses additional difficulties for the surgeon. The limited operative view in laparoscopic procedure complicates identification of anatomic relations of structures

In addition to adequate anatomical knowledge of associated regions, proper knowledge and identification of Calots triangle is essential for laparoscopic cholecystectomy.

J.F. Calot in 1891 described a triangular area comprised of the cystic duct, right hepatic duct, and lower edge of the liver.⁸ Rocko et al in 1981 described the possible variations in the region of Calot's triangle.⁹ In 1992, Hugh et al suggested Calot's triangle should be renamed the hepatobiliary triangle, with the small cystic artery branches supplying the cystic duct being called Calot's arteries.¹⁰ The cystic artery typically arises from the right hepatic artery and courses within the cystohepatic triangle to the right of the common hepatic duct.¹¹

Bleeding of cystic artery is a very troublesome complication during laparoscopic cholecystectomy as it decreases the overall visibility in abdomen. Reported incidence of conversion to open surgery because of blood vessel injuries is approximately 6.62%.¹² Young surgeons who have recently started using laparoscopic approach often struggle with approaching the Calot's triangle. Iatrogenic injuries in this region contribute to a major percentage of morbidity in patients treated with either open or laparoscopic cholecystectomy. So it is the prime focus for research in laparoscopic cholecystectomy for the classification of various structures in Calot's triangle.¹³

The present study is conducted to find the prevalence of positional variations in cystic artery as seen in laparoscopic view in a local population of the largest slum area in Asia. The aim of this study is to identify the variation in position of cystic artery in relation to cystic duct so that we can identify the safe area for dissecting peritoneum in Calot's triangle. This study can play its part in decreasing the incidence of vascular complications in laparoscopic cholecystectomy and help young surgeons with minimal experience overcome the long learning curve associated with it.

Methods

This is a prospective, sequential, non-randomised, descriptive study which was conducted at a tertiary care hospital within duration of two years from 2018 to 2019. All the patients who were admitted with the diagnosis of cholelithiasis and underwent elective laparoscopic cholecystectomy were included in this study during the specified duration.

All patients who were converted to open cholecystectomy were excluded from the study. Patients above the age of 70, pregnant patients and patients with the history of previous upper abdominal surgeries were also excluded from this study.

Sample size was calculated using WHO sample size calculator with one-sided hypothesis test mode. The level of significance was 5% while the power of the test was set to be 95%. Non probability consecutive sampling technique was used thus nullifying the selection bias. The sample size was calculated to be 192.

After approval from ethical committee, informed consent was taken from patients. All patients underwent routine investigations and ultrasound of whole abdomen prior to surgery. Complete blood count, liver function test were done to rule out acute cholecystitis. Three surgeons performed the surgeries in a

randomized fashion. All surgeries were carried out under general anaesthesia. Pneumoperitoneum was created by Veress needle. A standard 4 port approach was used to proceed with cholecystectomy. Olympus laparoscope with 0 degree camera was used. Visualisation of Calots triangle and variations in position of cystic arteries were visualized on medical grade monitor and duly noted in the prescribed performa. Variations in the position of cystic artery were classified into 4 groups as shown in Table 1.

Table 1
Anatomical groups of cystic artery in relation to cystic duct.

Group	Cystic artery position	Prevalence
1	cystic artery superomedial to cystic duct	90.62%
2	cystic artery posterolateral to cystic duct.	5.2%
3	cystic artery anterior to cystic duct	2.6%
4	absent cystic artery	1.56%

All the variations were recorded using performa and were statistically analysed via SPSS version 23.

Patients were discharged on the 1st postoperative day on analgesics.

Results

A total of 192 patients were included in the study who underwent laparoscopic cholecystectomy during the specified duration. All patients included in the study underwent routine preoperative investigations including LFTs and ultrasound upper abdomen.

Out of 192 patients included in the study 172 (89.58%) were females and 20 (10.41%) were males. Minimum age was found to be 19 years and maximum age was 46 years with the mean being 30.39. The standard deviation was found to be 6.098.

Out of these patients 4 (2.08%) were diagnosed as acute cholecystitis and 182 (94.7%) were diagnosed as cholelithiasis. 4 were (2.08%) diagnosed as mucocele of gallbladder and 2 (1.04%) were diagnosed as empyema gallbladder.

Among the 192 patients operated for laparoscopic cholecystectomy, 3 (1.5%) were converted to open cholecystectomy while 189 (98.43%) were carried out successfully.

The study revealed that among these 192 patients 174 (90.62%) had cystic artery at superomedial position to cystic duct and were included in group 1 (Figure A). The second most common position was found to be cystic artery posterolateral to cystic duct in 10 (5.208%) patients and included in group 2 (Figure B). In 5 (2.6%) patients cystic artery was found to be at anterior position to cystic duct (Figure C) and absent in 3 (1.56%) patients thus included in group 3 and 4 respectively.

Discussion

The course, length and position of cystic artery are highly variable and are thus prone to iatrogenic injury. In order to avoid such complication it is essential to perform careful blunt dissection in Calots triangle during laparoscopic and open cholecystectomy. In this study we aim to establish a safe approach zone for dissection in Calots triangle. We studied the variations in cystic artery anatomy with relation to the cystic duct aimed to determine an area of dissection least likely to encounter cystic artery. We found that the superomedial was the most common position (90.62%) in relation to cystic duct and the least common position was found to be anterior (2.6%). It was found absent in 3 (1.56%) patients. It has previously been described in literature that in cases where cystic artery cannot be found in the Calot's triangle, the gall bladder receives its blood supply from vessels arising directly from the liver parenchyma.¹⁴

In view of these results we aim to establish that it is safe to dissect the peritoneum anterior to the cystic duct as this is the area with least prevalence of cystic artery.

In a study conducted by M. Taimur et al¹⁵ the most common position of cystic artery was found to be superomedial (88%) and least common position was posterior (3%) while anterior was found to be in 6% of patients. M Ayyaz et al¹⁶ have reported the anterior position of cystic artery in 15% of patients. These studies show a much higher frequency in the anterior region than our study. However our study was conducted on a larger sized population and comparable sample size.

Despite several advantages over open procedures laparoscopic cholecystectomy has a high risk of iatrogenic injury to bile duct and cystic artery. To avoid such iatrogenic injury to bile duct and vascular structures, a surgical strategy was advised by Strasberg et al¹⁷ involving three steps. First step is blind dissection of Calots triangle including hepatoduodenal ligament. Second step involves mobilization of lower part of gallbladder. Third step include identification and isolation of two main structures that is cystic duct and artery. This strategy is known among surgeons as the critical view of safety.

The first step in critical view of safety is the most significant part of the procedure as it deals with the blind dissection in Calots triangle. As with any other blind procedure, this blind dissection poses risk of vascular damage as the relevant artery is not visible during this step. This vascular damage causes obstruction of field of vision leading to increased risk of further iatrogenic injury to biliary tree. All this menace may result in conversion to open cholecystectomy.

The thorough knowledge of anatomy of extrahepatic biliary tract arterial supply and its variation is crucial. This knowledge helps in reducing the unwanted bleeding that might result in obscuring the vision causing damage to other biliary and vascular structures. Iatrogenic injury to common bile duct and cystic artery can be avoided by careful dissection at Calots triangle and hepatoduodenal ligament¹⁸

It is thus essential to establish a safe zone for the blind dissection where the cystic artery can be present least likely. This study provides evidence for this step to be carried out safely without bleeding the cystic

artery. As a first step in achieving critical view of safety, blind dissection in Calots triangle can be safely started anterior to the cystic duct thus reducing the chance of injury to cystic artery.

Conclusion

It is concluded in this study that during laparoscopic cholecystectomy the blind dissection in Calots triangle, as the first step to achieve critical view of safety, should be performed anterior to the cystic duct. It is least likely to encounter cystic artery while proceeding with this approach thus reducing the complication of iatrogenic injury. Young surgeons can benefit from these findings in overcoming fear of complications and the learning curve associated with laparoscopic approach.

Declarations

Ethics approval and consent to participate

Ethical approval was taken from the Institutional Review Board of Sindh Government Qatar hospital where the study was conducted. All procedures performed in studies involving human participants were in accordance with the ethical standards of the institutional and/or national research committee (name of institute/committee) and with the 1964 Helsinki declaration and its later amendments or comparable ethical standards.

Consent to Publish

The authors consent that this manuscript can be published by BMC Surgery in print and online form.

Availability of Data and Materials

The data collected and analyzed during this study is available and will be shared upon request.

Competing Interests

The authors have no conflict of interest with any third party.

Funding

There was no involvement of any third party while conducting this study. No grants were taken from any institute or organization in the research process of this study.

Authors' Contributions

Muhammad Samir Irfan Wasi: Design, writing of manuscript, Analysis, Sketching and graphics.

Omer Fateh: Study design, Concept, Proof reading, analysis.

Syed Muhammad Abdullah Bukhari: Writing of manuscript, Data collection.

Acknowledgements

None to be declared by the authors.

References

1. Rao G, et al. Surgical management of gall bladder stones at tertiary care institute of Bhuj, Kutch, Gujarat. *Int Surg J*. 2019 Jul;6(7):2553–2555.
2. Kapoor R, Sharma R, Hingora O, Roy A, Ahmed F, Sinha N. Correlation of Serum Biochemical Characteristics With Its Gallstone Compositions. *JBSM* 2018; 4: 9–18.
3. Everhart JE, et al. Prevalence and ethnic differences in gallbladder disease in the United States. *Gastroenterology* 1999;117(3):632–9.
4. A Koirala, R Sulaimankulov, D Thakur, S Agrawal, B L Chaudhary, **S Poudel. Comparative Study of Single Incision Laparoscopic Cholecystectomy with Standard Four Port Laparoscopic Cholecystectomy for Symptomatic Cholelithiasis. JKISTMC** 2019;1(1):10–15
5. Comitalo J. Laparoscopic cholecystectomy and newer techniques of gall bladder removal. *Journal of Society of laparoendoscopic surgeons*. 2012;16(3):406–12.
6. De Silva WM, Sivananthan S, De Silva D, Fernando N. Biliary tract injury during cholecystectomy: a retrospective descriptive review of clinical features, treatment and outcome. *Ceylon Med J*. 2006;51:132–6.
7. Strasberg SMMD, Brunt L. Michael MD The Critical View of Safety, *Annals of Surgery*: March 2017 - Volume 265 - Issue 3 - p 464–465 doi: 10.1097/SLA.0000000000002054.
8. Callot JF. De la cholecystecomie. *Med. Frc de Paris, Dissertation*, 189.
9. Rocko JM, Di Gioia JM. Calot's triangle revisited. *SurgGynecolObstet*. 1981;153:410–4.
10. Hugh TB, Kelly MD, Li B. Laparoscopic anatomy of the cystic artery. *Am J Surg*. 1992;163:593–5.
11. The Gastrointestinal Tract
Mau Lo C, Ng KK. The Gastrointestinal Tract. (2012). In: Fischer JE, editor *Fischer's mastery of surgery*, 6th edn, Vol. 1. Wolters Kluwer Health/Lippincott Williams & Wilkins, Philadelphia; 2012: 1158–1159.
12. V Kudurupaka, M R Danda. Study of factors leading to conversion of laparoscopic cholecystectomy to open cholecystectomy. *Indian journal of research* 2019; 8(3): 1–5.
13. Singh K, Ohri A. Anatomic landmarks: their usefulness in safe laparoscopic cholecystectomy. *SurgEndosc*. 2006;20(11):1754–8.

14. Ding YM, Wang B, Wang WX, Wang P, Yan JS. New classification of the anatomical variations of cystic artery during laparoscopic cholecystectomy. *World Journal of Gastroenterology*. 2007;13(42):5629–34.
15. Taimur M, Hasan A, Ullah S, Masood R, Imran M. Vascular variations in the calot's triangle seen on laparoscopic cholecystectomy. *PAFMJ* 2011; 61 (4).
16. ayyaz M, Fatima T. G. Ahmed. Arterial Anatomy in Calot's Triangle as Viewed through the Laparoscope. *AKEMU*. 2001; 7 (3).
17. Strasberg SM, Hertl M, Soper NJ. An analysis of the problem of biliary injury during laparoscopic cholecystectomy. *J Am Coll Surg* 1995 Jan; 180(1):101–25.
18. Singh K, Singh R, Kaur M. Clinical reappraisal of vasculobiliary anatomy relevant to laparoscopic cholecystectomy. *J Minim Access Surg*. 2017;13(4):273–9. doi:10.4103/jmas.JMAS_268_16.

Figures

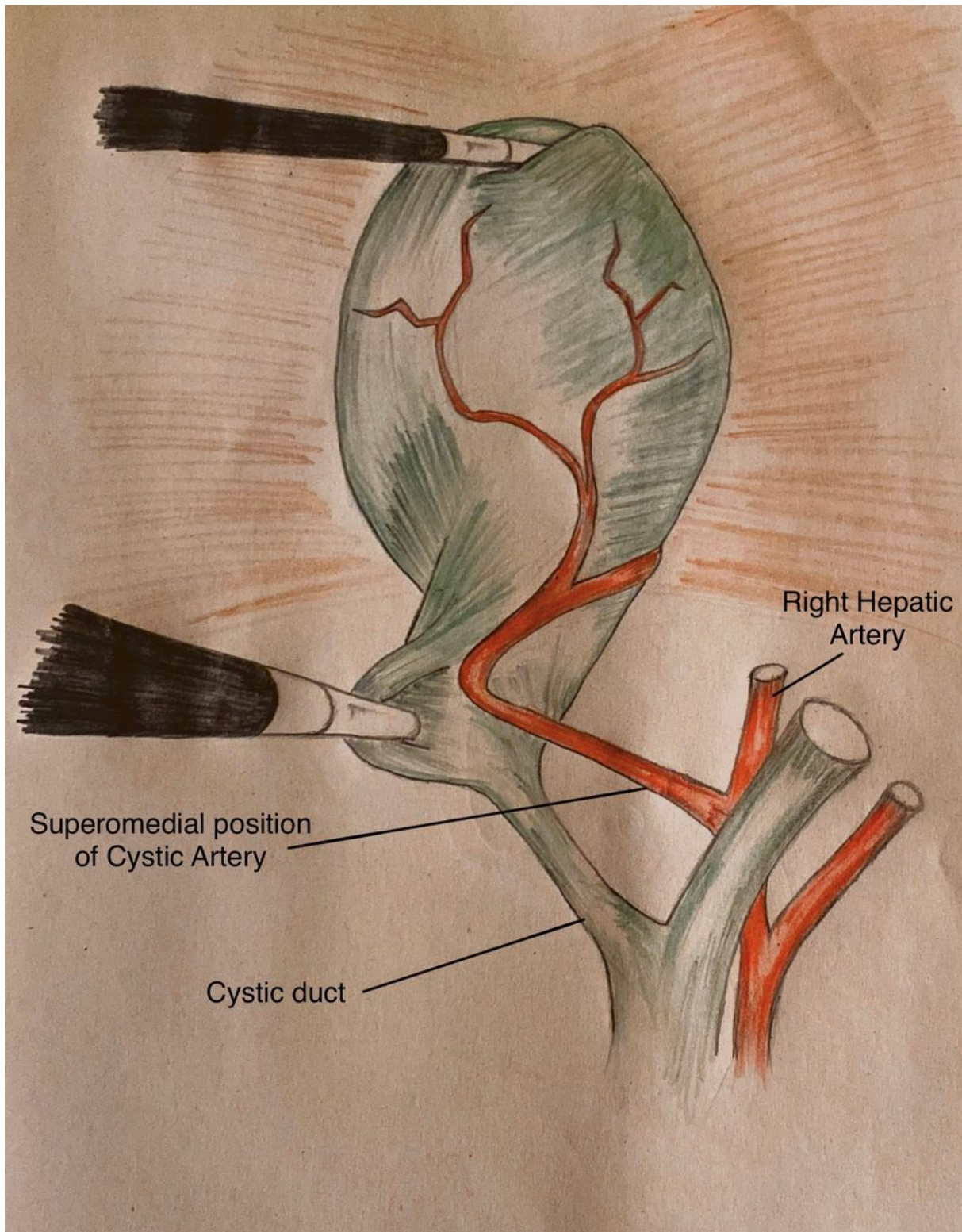


Figure 1

Superomedial position of cystic artery

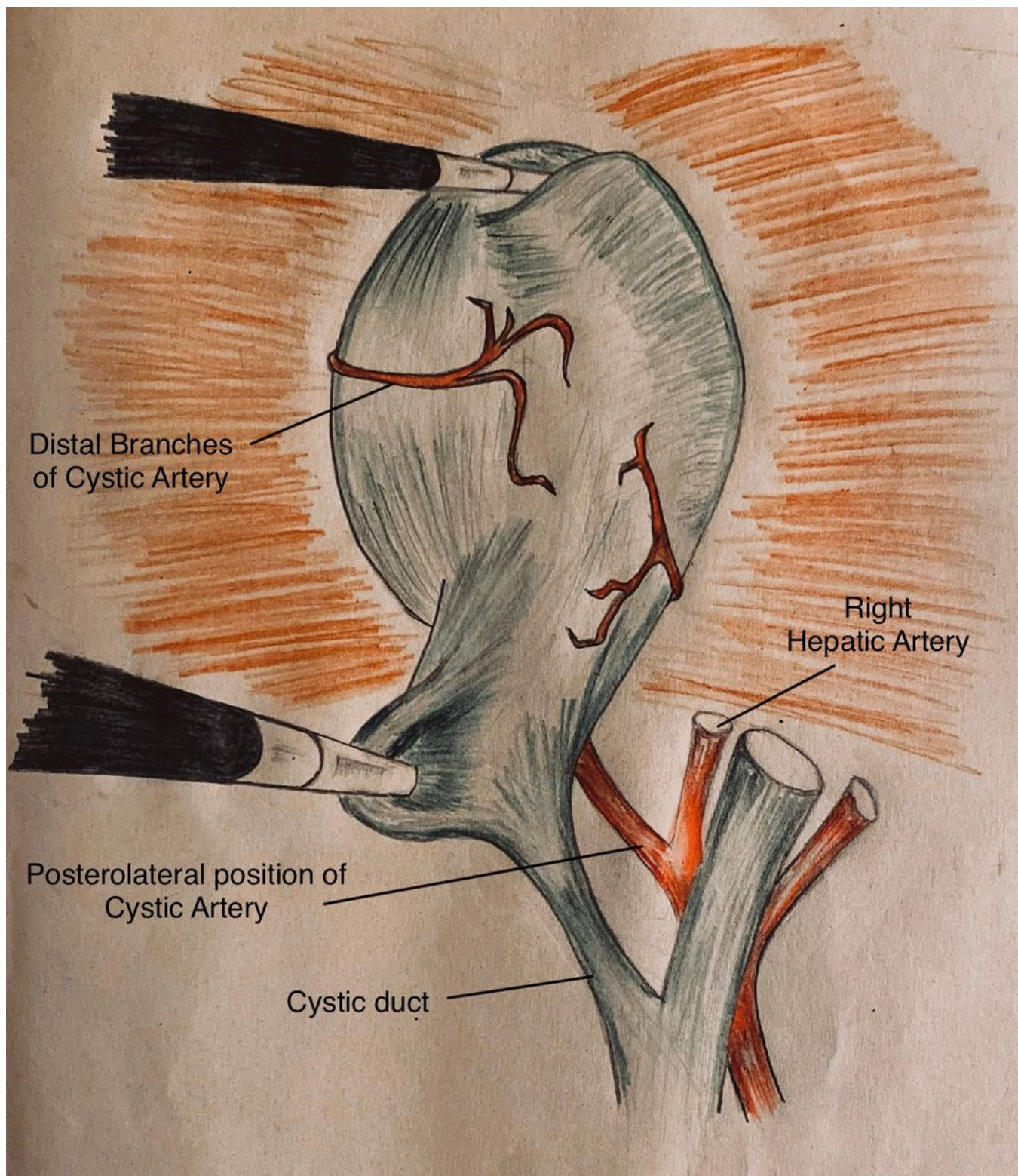


Figure 2

Posterolateral position of cystic artery

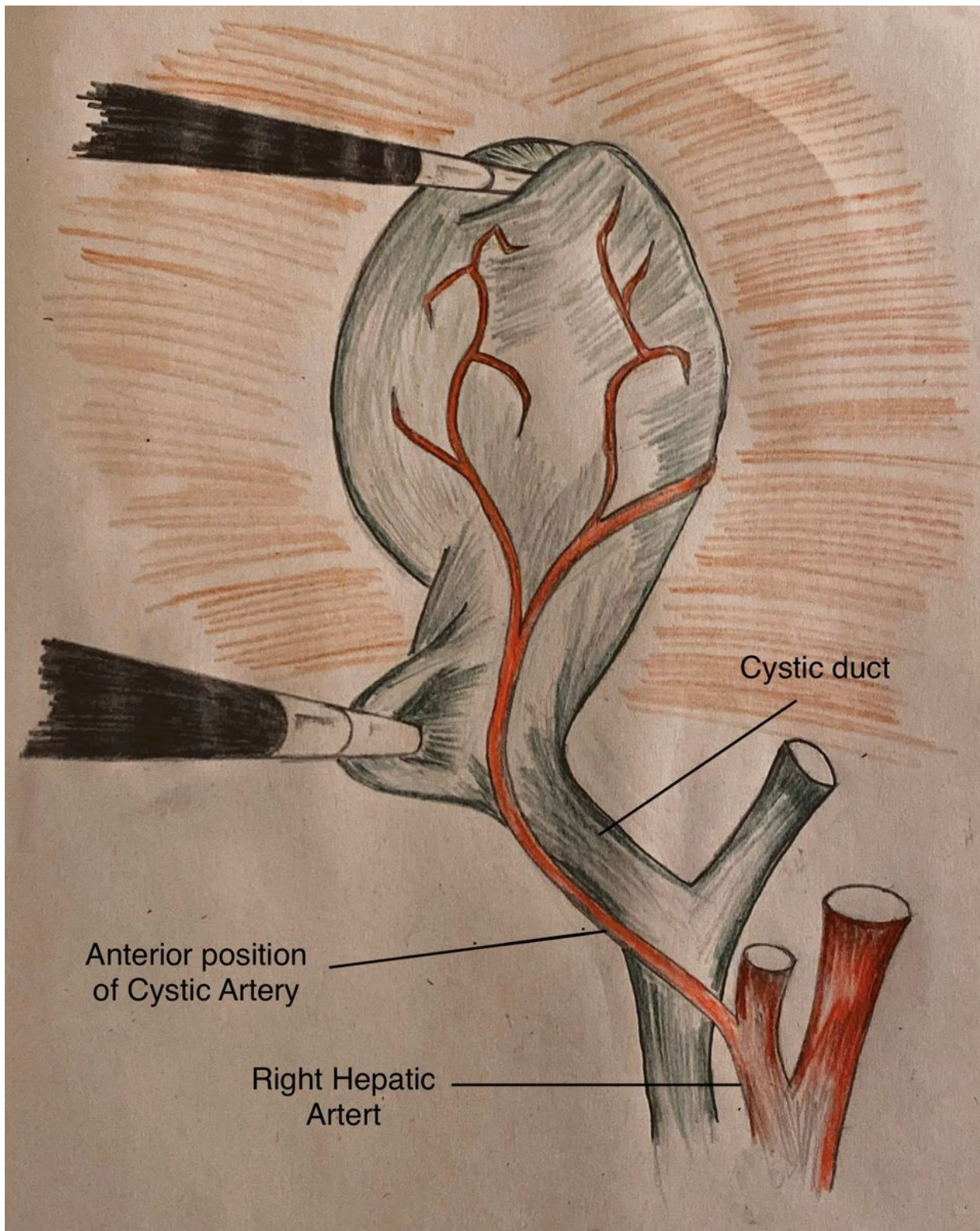


Figure 3

Anterior position of cystic artery