

Treatment of direct carotid cavernous fistula with Willis covered stent with midterm follow-up

Qinglin Liu

Department of Interventional Neuroradiology, Beijing Neurosurgical Institute & Beijing Tiantan Hospital, Capital Medical University <https://orcid.org/0000-0001-6980-3942>

Changjing Qi

Nursing department of Qilu Hospital, Shandong University

Yunyan Wang

Neurosurgery department of Qilu Hospital, Shandong University

Wandong Su

Neurosurgery department of Qilu Hospital, Shandong University

Gang Li

Neurosurgery department of Qilu Hospital, Shandong University

Donghai Wang (✉ drwangdonghai@163.com)

Neurosurgery department of Qilu Hospital, Shandong University

Research

Keywords: Fistula, Endovascular Procedures, Stents, Endoleak

Posted Date: July 21st, 2020

DOI: <https://doi.org/10.21203/rs.3.rs-44705/v1>

License: © ⓘ This work is licensed under a Creative Commons Attribution 4.0 International License. [Read Full License](#)

Abstract

Background

Willis covered stent is the first stent designed exclusively for intracranial vasculature and its application in carotid cavernous fistula is limited. The aim is to evaluate the feasibility and efficacy of this device in treating direct carotid cavernous fistula.

Methods

10 consecutive patients with direct carotid cavernous fistula were treated in our institution with Willis covered stents from September 2013 to December 2015. The characteristics of these patients and the immediate and follow-up results were retrospectively reviewed.

Results

Of the 10 patients, 8 were treated for the first time, and 2 had been treated elsewhere. Willis covered stents were successfully released in 9 patients. Abnormal arteriovenous shunt disappeared in 6 cases immediately after stent deployment and endoleak occurred in 3 cases. Endoleak disappeared at 6-month angiography follow-up in one case and was sealed with coils through a pre-set microcatheter in another case. Parent artery was sacrificed as endoleak remained despite repeated balloon dilation and a second stent deployment in the third case. All patients got clinical follow-up for at least 24 months and 7 patients received angiographic follow-up. Symptoms relieved gradually in all cases except for slight oculomotor paralysis and visual acuity in one case, respectively. In-stent stenosis was found in 1 case and no recurrence was observed.

Conclusions

Willis covered stent is feasible for direct carotid cavernous fistula.

Introduction

Direct carotid cavernous fistula (CCF) is featured by a direct shunt between the internal carotid artery (ICA) and the cavernous sinus, which mainly results from head traumas that damaged the cavernous ICA. Spontaneous direct CCF may also occur after rupture of a cavernous ICA aneurysm. The typical clinical manifestation of a direct CCF is a triad consisted of pulsating exophthalmos, chemosis and visual loss. Stealing of the blood may result in hypoperfusion of the ipsilateral hemisphere and the drainage pattern determines the hazardous consequences of the disease. Cortical superficial vein drainage may cause lethal intracranial hemorrhage.

The optimal goal for treating CCFs is to occlude the abnormal shunt and preserve ICA patency. In 1973, Parkinson first reported surgical repair of direct CCFs with parent artery preservation, but the technical

difficulty and significant morbidity have precluded its widespread use.[1] In 1974, Serbinenko reported his experience with detachable balloons for treating CCFs. [2] This technique results in closure of the fistula with ICA preservation in up to 80% of cases and has been the first-line therapy for direct CCFs.[3] Easy delivery and low cost are the main advantages of this technique. However, it also has some technical problems such as early detachment/deflation of the balloon or occasional rupture of the balloon stabbed by the bone fragments. [4] Detachable coils were used in 1992 by Guglielmi with the advantages of thrombogenicity, controllable deposit, radiopacity, and biocompatibility.[5] Dense packing of the cavernous sinus might cause nerve paralysis. Furthermore, the coils may protrude into the ICA and cause embolic events. Liquid embolic agents including n-butylcyanoacrylate and Onyx have also been used solely or in combination with coils in treating direct CCFs with favorable results.[6, 7] The potential of the embolic agent refluxing into the ICA or draining veins is the main disadvantage of this approach. [8]

Recently, covered stents for treating CCFs have been reported.[4, 9, 10] But all these covered stents were not initially for neurovascular use. As the first device designed exclusively for intracranial vascular defect, the Willis covered stent (MicroPort, Shanghai, China), was approved by the Chinese Food and Drug Administration in 2013. It is a balloon-expandable endoprosthesis composed of a bare stent and an expandable polytetrafluoroethylene membrane. Recently, it has been used for aneurysms[11] and arterial dissections[12] with satisfying results. However, its application for CCF is still limited.[9] In this study, we will explore the feasibility and safety of this stent in treating direct CCF.

Materials And Methods

Patient cohort

From September 2013 to December 2015, 10 patients with traumatic direct CCF received Willis covered stent implantation in our institution. This study was approved by the ethics committee of our hospital and informed consents were obtained from all the patients before operation. The angiographic data was reviewed by 3 senior neuro-radiologists for screening the candidates for Willis covered stent treatment. The major considerations were the tortuosity of the parent artery, the presence of vital perforators, and the contradictions for antiplatelet therapy. Details of alternative treatment strategies such as embolization with coils, ethylene vinyl alcohol copolymer (Onyx, Covidien, Minneapolis, MN), and balloon were informed to the patients and their relatives, and the patients made the final treatment decision.

Endovascular procedure

All patients received a diagnostic 6-vessel digital subtraction angiography (DSA). Angiographic evaluation included ipsilateral vertebral and contralateral carotid angiographies with ipsilateral carotid compression. Aspirin (Bayer Pharma AG., Leverkusen, Germany) and Clopidogrel (Bristol-Myers Squibb/Sanofi Pharmaceuticals, Bridgewater, NJ, 300 mg, respectively) were prescribed 2 hours before operation. All the procedures were performed under general anesthesia using the Siemens Artis Zee floor system (Siemens, Germany). Heparinization was monitored with activated clotting time of 250–300 seconds.

An 8F guiding catheter (Boston Scientific Co., USA) was placed to the internal carotid artery. Through this stiff guiding catheter a 5F Navien (EV3, Irvine, CA, USA) catheter, an XT-27 microcatheter (Stryker, Kalamazoo, MI, USA) and a 0.014-inch Synchro microwire (Stryker, West Valley City, Utah, USA) were delivered in co-axis. The distal tip of the 5F Navien catheter should be delivered across the fistula and to the ICA bifurcation. Then, the Synchro microwire was exchanged for a 300 cm exchanging microwire (Stryker, West Valley City, Utah, USA) and the XT-27 microcatheter was withdrawn. Over the exchanging microwire, the Willis covered stent was delivered to cover the fistula. Then, the 5F Navien catheter was withdrawn gradually to the proximal of the fistula carefully while keeping the stent stable. After confirming the position of the stent with angiography from the Navien catheter, the balloon was dilated to release the stent. Subsequent angiography was obligated to evaluate the result. Repeated balloon inflation, another stent deployment or parent artery occlusion would be considered for unexpected endoleak.

For patient 4, a 'pre-set microcatheter' strategy was employed. In brief, besides the delivering system described above, a 5F guiding catheter (Boston Scientific Co., USA) was delivered from left femoral artery to the ipsilateral ICA, and through which an Echelon-10 (EV3, Irvine, CA, USA) microcatheter was delivered into the cavernous sinus via the fistula. Microcoils or Onyx would be delivered through the pre-set microcatheter as salvage for the unexpected endoleak after stent implantation.

Dual antiplatelet medication (Aspirin 100 mg/d, Clopidogrel 75 mg/d) were maintained for at least three months after the procedure, and Aspirin alone was maintained for another three months.

Clinical and graphical follow-up regime

Clinical follow-up was arranged for all patients at 1, 6 and 24 months after discharge. DSA follow-up was arranged 6 months after discharge for all patients except for the two cases who received parent artery occlusion.

Results

Patients' information

Three females and 7 males were enrolled in this study. The average age was 28 ± 2.556 years (18-45 years) and the average medical course was 33.6 ± 17.39 days (2days-6months). Eight patients were treated for the first time and the other 2 had been treated previously elsewhere. The typical symptoms include chemosis, exophthalmos, intracranial bruit, and ocular movement disorder. Detailed information of these patients was summarized in table 1.

Immediate angiographic results

Willis covered stents were successfully delivered and released in 9 of the 10 patients, except for one case due to the tortuous ICA, for whom the parent artery was occluded with detachable balloons after an occlusion test. Immediate blockage of the abnormal shunt was achieved in 6 patients with one stent for each patient. Endoleak occurred in 3 patients. For one patient, repeated balloon inflation dramatically diminished the endoleak (Patient 10). For another patient, endoleak remained even after repeated balloon dilation and

another stent deployment, and this patient got parent artery occlusion with balloons after an occlusion test. The blood flow was compensated by the anterior and posterior communicating artery (Patient 2). For the third patient, endoleak was sealed with coils through a pre-set microcatheter (Case 4, Fig 4, Patient 4).

Clinical and graphical follow-up results

Symptoms gradually relieved after the operation in all patients. Clinical follow-up 1 month after discharge showed disappear of chemosis and no new neurological deficits in all patients. Ocular motor disturbance disappeared in two patients (Patients 2 and 7) and relieved in another (Patient 4). Clinical follow-up 6 and 24 months after initial discharge showed no related neurological defects in all patients except for decreased visual acuity in patient 2 and slight oculomotor paralysis in patient 4.

Angiographic follow-up was available in 7 patients 6 to 10 months after initial discharge. Slight in-stent stenosis was found in 1 case (Patient 10) at six-month follow-up. In the patient with slight endoleak at discharge (Patient 10), the endoleak disappeared. For the two patients who received parent artery occlusion, DSA follow-up was not arranged for their silent symptoms. One patient (Patient 8) refused DSA follow-up for intact neurological function and economic burden.

Illustrative cases

Case-1 (Patient 1)

A 25 years old girl was transferred to our department for right chemosis for 7 days after a vehicle accident. She was diagnosed as right CCF by six-vessel angiography. The fistula was successfully repaired with 1 Willis covered stent. At one-month follow-up, the right chemosis disappeared with no new neurological deficits. Angiographic follow-up six months after discharge showed patency of the parent artery with no stenosis (Fig 1). Clinical follow-up 6 and 24 months after initial discharge showed no neurological deficit.

Case-2 (Patient 8)

A 31 years old man was admitted for right chemosis and intracranial bruit for 2 months. He had head trauma 2 months ago and was diagnosed as traumatic CCF. He received embolization with coils and Onyx-18 in a local hospital. The signs relieved just after operation but aggravated in the last 10 days before being transferred to our hospital. DSA confirmed recurrence of the CCF, and the fistula was repaired by a Willis covered stent. The bruit disappeared just immediately after the operation and the chemosis gradually relieved and disappeared at one-month follow-up after discharge (Fig 2). This patient refused DSA follow-up as the economic burden. Clinical follow-up at 6 and 24 months showed disappear of the signs, but decreased right visual acuity.

Case-3 (Patient 10)

A 35 years old man, who suffered from severe head trauma and subsequent intracranial hematoma evacuation and decompressive craniectomy 1.5 months ago, came to our department for persistent left chemosis and exophthalmos. DSA confirmed a left high flow CCF. A slight endoleak was encountered even after repeated balloon inflation and a second stent deployment. His eye signs gradually diminished and

completely disappeared at the one-month clinical follow-up. Angiographic follow-up showed disappear of the endoleak and slight in-stent stenosis (Fig 3). Clinical follow-up 6 and 24 months showed no neurological signs.

Case 4 (Patient 4)

A 21 years old man suffered from chemosis, exophthalmos, intracranial bruit and ocular movement disorder for 6 days after a vehicle accident. Diagnostic angiography confirmed right CCF. To eliminate the potential endoleak, a microcatheter was pre-set into the cavernous sinus through the fistula. After stent deployment and a second balloon dilation, the unexpected endoleak was sealed with 2 coils just near the fistula (Fig 4). His signs gradually relieved and completely resolved at one-month follow-up. He received angiographic follow-up in a local hospital but lost the imaging data. The copied in-hospital record described disappear of the fistula with no in-stent stenosis. Clinical follow-up 24 months after initial discharge was normal.

Discussion

Originally approved as a 'bailout' in the event of coronary artery rupture, covered stents could reconstruct the vessel defects immediately while preserving the parent artery. Willis is the first covered stent exclusively designed for intracranial vasculature. In this paper, we shared our experience of this device for treating direct CCFs.

Compared with traditional treatment modalities for CCFs with coils, Onyx, and balloons, covered stent has some advantages: high overall complete occlusion rate; a relatively simple and rapid procedure; no coil herniation into the parent artery; no mass effect, and no CCF recanalization and recurrence. Of these advantages, the high overall complete occlusion rate is the most important.[13] However, there are also some limitations for covered stent in repairing vascular defects. First, small perforating vessel sacrifice restricts its usage. Absence of important branches at the cavernous ICA provides the feasibility of covered stent for direct CCFs. Second, the tortuous ICA makes delivery of the stiff stent difficult. To overcome this difficulty, a strong supporting system is necessary.[14] We proposed an effective delivery system as described above, which consisted of 8F guiding catheter, 5F Navien catheter, XT-27 microcatheter and an exchanging microwire in co-axis. In our series, all stent deliveries with this system were successfully. In patient 3, unavailability of the soft Navien catheter lead to stent delivery failure. These results proved the necessity and efficacy of our delivering system.

Defined as persistent perfusion of the space between the stent graft and parent vessel wall, [15] endoleak occurred in 38.89% cases immediately after covered stent deployment, [16] which was consistent with our cases (30%, 3/10). As major endoleak remained even after repeated balloon dilation and a second stent deployment, we had to sacrifice the ICA with balloons in patient 2. In patient 10 (Case 3, Fig. 3), endoleak diminished after re-dilation of the balloon and disappeared spontaneously at 6-month follow-up. In patient 4 (Case 4), the endoleak was sealed with two coils via a pre-set microcatheter (Fig. 4). As we knew, this is the first report to pre-set a microcatheter for unexpected endoleak after stent deployment. As a pre-set microcatheter may induce a gap between the arterial wall and the stent leading to persistent endoleak, it is more reasonable to deliver the microcatheter via the venous route. Oblate vessel wall, diameter variance of

the covered vessel, sharp bone fracture that stabbing the stent membrane, vasospasm, and stent diameter mismatch may contribute to immediate endoleak.[16] Balloon re-dilation and additional stent deployment were reported to solve this complication, and slight endoleak might disappear spontaneously in follow-up. [15] The efficacy of these strategies was validated in patient 10 (Case 3, Fig. 3). In this patient, endoleak dramatically relieved after repeated balloon dilation, and the residual endoleak disappeared spontaneously at the 6-month angiographic follow-up. For patient 2, parent artery was sacrificed as persistent endoleak despite repeated balloon dilation and a second stent deployment.

In-stent stenosis was reported to occur in 18.0% and 20.9% patients after Willis stent implantation at 2 and 6 years follow-up. [16] In our series, in-stent stenosis was seen in 1 case at 6 month follow-up (10.0%, Case 3, Fig. 3). Smoking and stent angulation were predictors of late in-stent stenosis.[16] Repeated balloon dilation induced intima damage may contribute to the aggressive intima hyperplasia in this patient. Aspirin was prescribed and intermittent clinical follow-up was scheduled for him.

Recurrent or partially occluded CCF is always a nightmare for physicians, as delivery of the microcatheter may be extremely difficult. Under this condition, covered stent may serve as an alternative. In patient 8 (Fig. 2, Case 2), the inferior petrosal sinus had already been occluded in the initial operation and covered stent was selected as the salvage treatment. The fistula was occluded immediately after stent deployment.

Conclusions

In conclusion, our initial results indicated that Willis covered stent is feasible and efficient in treating direct CCFs. More cases are needed to further elucidate this issue.

Abbreviations

CCF
carotid cavernous fistula
DSA
digital subtraction angiography
ICA
internal carotid artery

Declarations

Ethics approval and consent to participate

This study was approved by the ethics committee of Qilu Hospital and informed written consents were obtained from all patients or their guardians.

Consent for publication

Consent for publication was obtained from each patient before operation.

Availability of data and materials

The datasets used during the current study are available from the corresponding author on reasonable request.

Competing interests

The authors declare that they have no competing interests

Funding

This study was supported by the China postdoctoral science foundation [grant NO. 2019M660714].

Author contributions

QL designed this study and wrote the manuscript; CQ, YW and WS contributed to data collection, GL and DW supervised this study. All authors read and approved the final manuscript

Acknowledgements

Not applicable

References

1. Parkinson D. Carotid cavernous fistula: direct repair with preservation of the carotid artery. Technical note. *Journal of neurosurgery*. 1973;38(1):99–106.
2. Serbinenko FA. Balloon catheterization and occlusion of major cerebral vessels. *Journal of neurosurgery*. 1974;41(2):125–45.
3. Parkinson D. Management of 100 consecutive direct carotid-cavernous fistulas: results of treatment with detachable balloons. *Neurosurgery*. 1995;37(2):357.
4. Archondakis E, Pero G, Valvassori L, Boccardi E, Scialfa G. Angiographic follow-up of traumatic carotid cavernous fistulas treated with endovascular stent graft placement. *AJNR American journal of neuroradiology*. 2007;28(2):342–7.
5. Guglielmi G, Vinuela F, Briganti F, Duckwiler G. Carotid-cavernous fistula caused by a ruptured intracavernous aneurysm: endovascular treatment by electrothrombosis with detachable coils. *Neurosurgery*. 1992;31(3):591–6. discussion 596–597.
6. Zenteno M, Santos-Franco J, Rodriguez-Parra V, Balderrama J, Aburto-Murrieta Y, Vega-Montesinos S, Lee A. Management of direct carotid-cavernous sinus fistulas with the use of ethylene-vinyl alcohol (Onyx) only: preliminary results. *Journal of neurosurgery*. 2010;112(3):595–602.
7. Ramalingaiah AH, Prasad C, Sabharwal PS, Saini J, Pandey P. Transarterial treatment of direct carotico-cavernous fistulas with coils and Onyx. *Neuroradiology*. 2013;55(10):1213–20.
8. Gonzalez LF, Chalouhi N, Tjoumakaris S, Jabbour P, Dumont AS, Rosenwasser RH. Treatment of carotid-cavernous fistulas using intraarterial balloon assistance: case series and technical note. *NeuroSurg*

Focus. 2012;32(5):E14.

9. Wang W, Li MH, Li YD, Gu BX, Lu HT: **Reconstruction of the Internal Carotid Artery After Treatment of Complex Traumatic Direct Carotid-Cavernous Fistulas With the Willis Covered Stent: A Retrospective Study With Long-Term Follow-up.** *Neurosurgery* 2016.
10. Gomez F, Escobar W, Gomez AM, Gomez JF, Anaya CA. Treatment of carotid cavernous fistulas using covered stents: midterm results in seven patients. *AJNR American journal of neuroradiology.* 2007;28(9):1762–8.
11. Zhu YQ, Li MH, Fang C, Tan HQ, Wang W, Zhang PL, Cheng YS, Wang JB, Ma LT. Application of the Willis covered stent in the treatment of aneurysm in the cisternal segment of the internal carotid artery: a pilot comparative study with midterm follow-up. *Journal of endovascular therapy: an official journal of the International Society of Endovascular Specialists.* 2010;17(1):55–65.
12. Cai X, Guan J, Ren S, Wei Y, Peng X, Qiu W, Chen J. Treatment of internal carotid artery dissection with Willis covered stent: A case report of recurrent limb weakness and no response to medical therapy. *Experimental therapeutic medicine.* 2016;11(5):1983–6.
13. Yin B, Sheng HS, Wei RL, Lin J, Zhou H, Zhang N. Comparison of covered stents with detachable balloons for treatment of posttraumatic carotid-cavernous fistulas. *Journal of clinical neuroscience: official journal of the Neurosurgical Society of Australasia.* 2013;20(3):367–72.
14. Felber S, Henkes H, Weber W, Miloslavski E, Brew S, Kuhne D. Treatment of extracranial and intracranial aneurysms and arteriovenous fistulae using stent grafts. *Neurosurgery.* 2004;55(3):631–8. discussion 638–639.
15. Tan HQ, Li MH, Li YD, Fang C, Wang JB, Wang W, Wang J, Zhang PL, Zhu YQ. Endovascular reconstruction with the Willis covered stent for the treatment of large or giant intracranial aneurysms. *Cerebrovascular diseases.* 2011;31(2):154–62.
16. Zhu YQ, Li MH, Lin F, Song DL, Tan HQ, Gu BX, Zhang HQ, Leng B, Zhang PL. Frequency and predictors of endoleaks and long-term patency after covered stent placement for the treatment of intracranial aneurysms: a prospective, non-randomised multicentre experience. *European radiology.* 2013;23(1):287–97.

Table

Table 1 patient information

patient No.	Sex (F/M)	years	presentation	Duration	Recurrent (yes/No)	Operation process	Immediate angiographic result	follow up result
1	F	25	Chemosis	7d	No	One stent	Patent, no endoleak	No symptom. Patent, no stenosis
2	M	28	Chemosis/exophthalmos/bruit/ocular movement disorder	5d	No	One stent, repeated dilation, persistent endoleak, second stent, endoleak, occlude the ICA with balloons.	ICA occlusion	Decreased visual acuity. No DSA follow-up
3	M	45	chemosis	12d	No	Could not deliver the stent to the fistula, occlude the ICA with balloons.	ICA occlusion	No symptom. No DSA follow-up
4	M	21	Chemosis/exophthalmos/bruit/ocular movement disorder	6d	No	One stent, endoleak, seal the fistula with coils	Patent, no endoleak	Slight ocular movement disorder. Patent, DSA follow-up in a local hospital.
5	M	19	Chemosis/exophthalmos/bruit	14d	No	One stent	Patent, no endoleak	No symptom. Patent, no stenosis
6	F	29	Chemosis/exophthalmos	3d	No	One stent	Patent, no endoleak	No symptom. Patent, no stenosis
7	F	18	Chemosis/exophthalmos/bruit/ocular movement disorder	4d	No	One stent	Patent, no endoleak	No symptom. Patent, no stenosis
8	M	31	chemosis /bruit	2m	Yes	One stent	Patent, no endoleak	Decreased visual

								acuity. Refuse DSA follow up.
9	M	29	chemosis	6m	Yes	One stent	Patent, no endoleak	No symptom. Patent, no stenosis
10	M	35	Chemosis/ exophthalmos	1.5m	No	One stent, repeated dilation,	Patent, slight endoleak	No symptom. Patent, slight stenosis, no endoleak

Note: F: female; M: Male; ICA: internal carotid artery; DSA: digital subtraction angiography

Figures

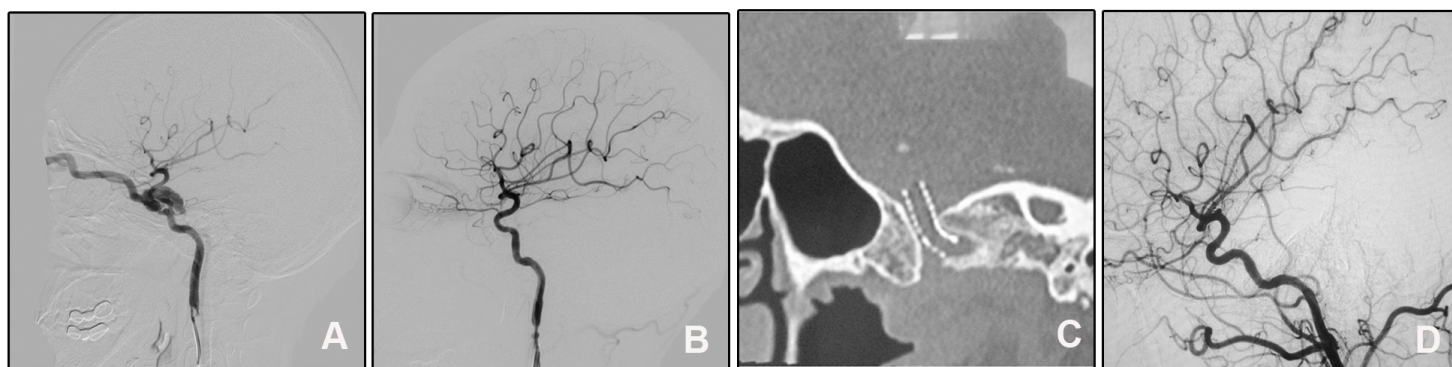


Figure 1

A direct CCF was cured by a Willis stent deployment. a: DSA of the right ICA showed a direct CCF and was drained by the superior ophthalmic vein. b: A Willis covered stent was delivered and dilated to cover the fistula and immediate angiography showed perfect repair of the vascular lumen. c: DynaCT showed complete inflated stent. d: Angiographic follow-up six months after discharge showed patency of the ICA and no obvious in-stent stenosis.

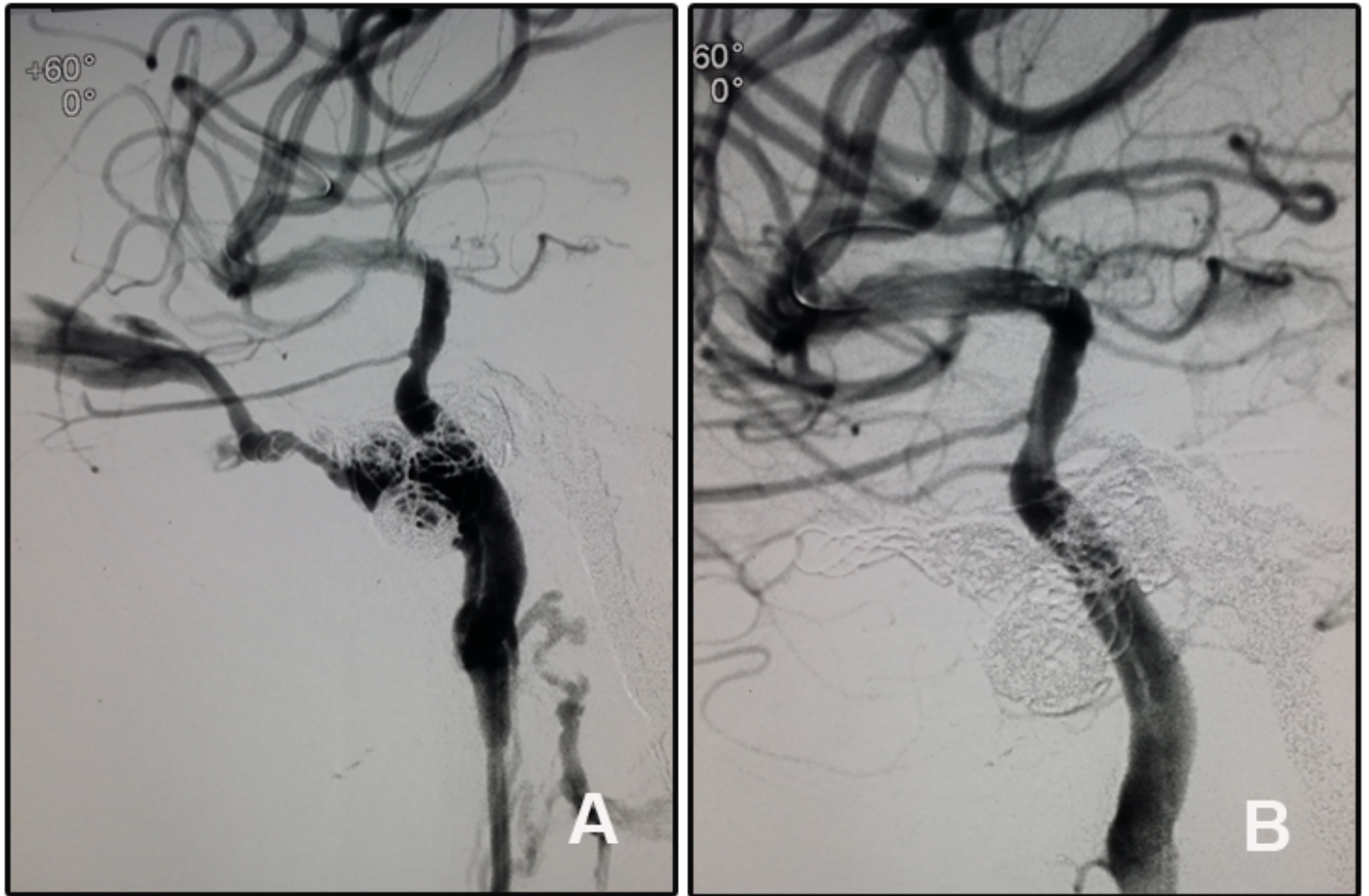


Figure 2

A recurrent CCF was treated with Willis covered stent. a: The fistula located at the cavernous segment of the right ICA and was drained by the superior ophthalmic vein. The embolization materials of microcoils and Onyx were seen. b: Angiography after the stent deployment showed disappear of the fistula and patency of the parent artery.

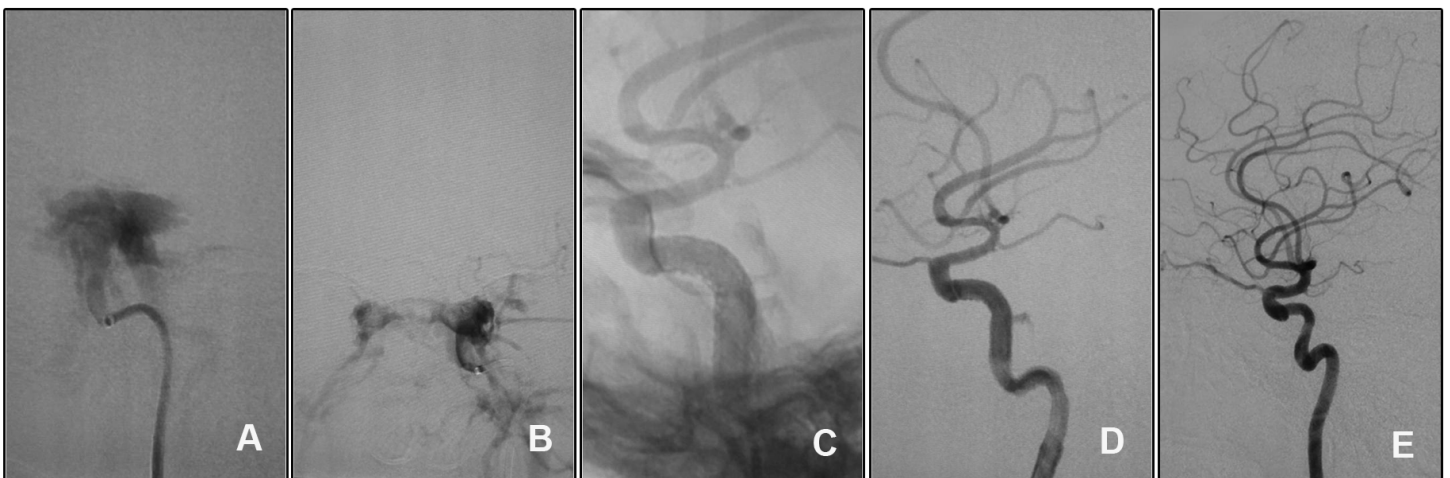

Figure 3

The endoleak after Willis covered stent deployment disappeared spontaneously. a-b: Angiography of the left ICA showed a high flow CCF of the cavernous segment. c-d: The endoleak persisted although repeated balloon inflation. e: Follow-up angiography showed disappear of the endoleak and a slight in-stent stenosis

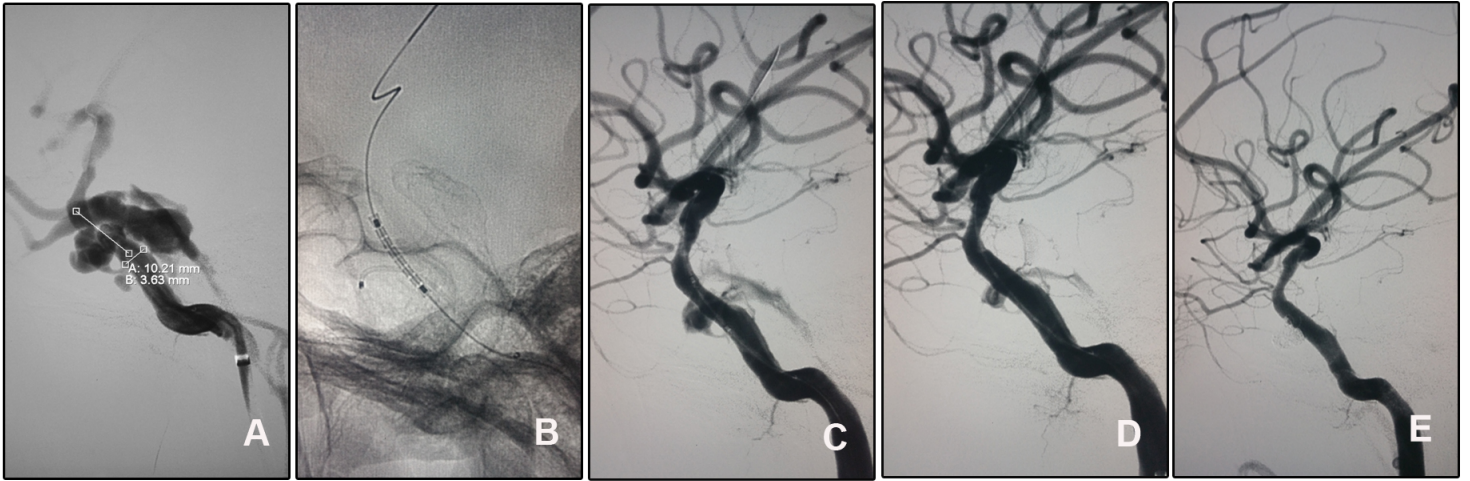


Figure 4

The endoleak after stent deployment was sealed with coils through a pre-set microcatheter. a: Angiography of the right ICA confirmed the diagnosis and showed the fistula. b: A microcatheter was placed into the cavernous sinus through the fistula and we could see the position of the stent. c-d: After the stent deployment and repeated balloon dilation, an endoleak was seen. e: The endoleak was sealed with two coils delivered through the pre-set microcatheter.