

Effect of Panretinal Photocoagulation on Macular and Disc Vasculature using Optical Coherence Tomography Angiography

Houshang Faghihi

Farabi Eye Hospital

Hamid Riazi-Esfahani (✉ hamidriazi@gmail.com)

Farabi Eye Hospital <https://orcid.org/0000-0003-2277-398X>

Alireza Khodabandeh

Farabi Eye Hospital

Ahmad Mirshahi

Farabi Eye Hospital

Fariba Ghasemi

Farabi Eye Hospital

Reza Mirshahi

Farabi Eye Hospital

Hassan Khojasteh

Farabi Eye Hospital

Fatemeh Bazvand

Farabi Eye Hospital

Ali Torkashvand

Farabi Eye Hospital

Amirhossein Hashemi

Farabi Eye Hospital

Fereshteh Tayebi

Farabi Eye Hospital

Shahin Faghihi

Farabi Eye Hospital

Mohammad Riazi Esfahani

Gavin Herbert Eye Institute

Research article

Keywords: Diabetic retinopathy, Vascular densities, Foveal avascular zone, Circularity index, Central macular thickness

Posted Date: August 30th, 2019

DOI: <https://doi.org/10.21203/rs.2.13756/v1>

License: © ⓘ This work is licensed under a Creative Commons Attribution 4.0 International License.

[Read Full License](#)

Version of Record: A version of this preprint was published at European Journal of Ophthalmology on August 21st, 2020. See the published version at <https://doi.org/10.1177/1120672120952642>.

Abstract

Background: To evaluate the changes of macular vascular density in the superficial capillary (SCP) and the deep capillary plexus (DCP), Foveal avascular area (FAZ), choroidal flow, macular thickness and parapapillary flow after panretinal photocoagulation (PRP).

Method: In this prospective interventional non-comparative case series, patients with very severe nonproliferative (NPDR) and early proliferative diabetic retinopathy (PDR) and no significant macular edema who were candidates for panretinal photocoagulation underwent measurement of corrected distance visual acuity (CDVA), optical coherence tomography (OCT), Optical coherence tomography angiography (OCTA) at the baseline (1–5 days before PRP), 1, and 5 to 7 months following completion of PRP treatment.

Results: Thirty-nine eyes from 21 patients with diabetes were enrolled. foveal SCP ($P > 0.1$), foveal DCP ($P > 0.1$), parafoveal SCP ($P > 0.1$), and parafoveal DCP ($P > 0.1$) did not change 1 month and 6 months after PRP. The parafoveal inner retina thick slab density was significantly decreased at 6 months after PRP ($p=0.015$). Deep FAZ area constricted 6 months following PRP ($P = 0.075$). Based on calculated circularity index, the FAZ area became significantly more circular. ($P=0.047$). One month after PRP the inside disc vascular density was significantly increased from baseline ($p=0.041$); while, it was decreased to lower than baseline amount, 6 months after PRP .

Conclusion: Although OCTA parameters were not significantly affected by PRP at both short- (1-month) long-term (6-month) follow-up, but FAZ area may be become more circular and regular after PRP may be due to reflow of occluded capillary plexus.

Background

Diabetic retinopathy is characterized by the ischemic process within the retina caused by microangiopathies, which eventually leads to proliferative diabetic retinopathy (PDR).[1]

Panretinal photocoagulation (PRP) is considered the mainstay of treatment for PDR. Despite its benefits in reducing the rate of severe visual loss, PRP is reported to be associated with mild visual acuity (VA) loss, macular edema and constricted visual field.[2]

It has been shown that PRP may disrupt blood-retinal barrier with subsequent alterations in retinal vasculature and hemodynamics.[3] The decrease in vascular endothelial growth factor (VEGF) may result in retinal and choroidal flow redistribution [4, 5]. Additionally, the choroidal vasculature and thickness changes following PRP, have been investigated [6, 7]; however, while some studies have reported that PRP can slow the process of retinal capillary closure in patients with diabetic retinopathy others have noted progressive capillary closure due to VEGF reduction.[8–11]. The most important shortcoming of such studies is the utilization of fluorescein angiography (FA) for quantification of retinal ischemia. The

assessment of nonperfusion in the deep retinal capillary plexus is limited by FA due to masking with leakages and haemorrhages.[12]

Optical coherence tomography angiography (OCTA), as a depth-resolved non-invasive modality rendered the possibility of mapping the retinal vasculature at different capillary plexuses. [13–15]

There are multiple studies demonstrating the capability of OCTA in the quantification of microvascular density, capillary non-perfusion, Foveal avascular area (FAZ) and choroidal flow in diabetic patients. [16–19]

This study aims to evaluate the short-term and long term alterations in macular vascular density, FAZ area and regularity, choroidal flow, macular thickness and parapapillary flow after PRP in patients with early proliferative diabetic retinopathy (PDR) and very severe nonproliferative (NPDR)..

Methods

This prospective interventional case series was approved by local institutional review board (IR.TUMS.FARABIH.REC.1398.021, <http://ethics.research.ac.ir/>) and verbal informed consents were obtained from the patients. The study adhered to the tenets of the Declaration of Helsinki.

From February 2015 to November 2018, consecutive patients with very severe nonproliferative (NPDR) and early proliferative diabetic retinopathy (PDR) and no significant macular edema who were candidates for panretinal photocoagulation were enrolled in this experiment. Patients with high risk PDR, moderate or mild NPDR, central macular thickness more than 300 micron or evidence of any centre involved cystoid maculae edema based on optical coherence tomography (OCT), presence of fibrovascular proliferation in the macular area, uncontrolled glaucoma, uveitis, eyes with visual acuity less than 20/200 and refractive error $> +3$ and < -3 were excluded. The eye was also excluded in case of significant media opacity impeding high quality imaging. History of previous panretinal photocoagulation, macular photocoagulation and anti-VEGF injections were other criteria for exclusion.

Patients underwent thorough ophthalmic examination including biomicroscopy and dilated indirect ophthalmoscopy and fundus photo. A masked optometrist measured the corrected distance visual acuity (CDVA) (using snellen chart), and the result was then converted to logarithm of the minimum angle of resolution (LogMAR).

RTVue XR 100 Avanti instrument (Optovue, Inc., Fremont, CA, USA) was used to perform optical coherence tomography angiography (OCTA). Images were acquired at the baseline (few days before PRP), 1, and 5 to 7 months following completion of PRP treatment. A 3×3 mm foveal centered image was obtained consecutively for each eye. Quality score more than 5 based on OCTA software report was the minimum requirement and imaging was repeated until this goal was achieved. Eyes with significant image quality or different artifacts preventing accurate measurement of the vascular density, flow or FAZ area were excluded.

After using projection artifact removal (PAR) algorithm, the built-in module in AngioAnalytics software (version 2017.1.0.151), different layers of retina were segmented automatically. The retinal slab for superficial capillary plexus (SCP) en face image was defined at an inner boundary at 3 µm under the internal limiting membrane (ILM) and having an outer boundary at 15 µm beneath the inner plexiform layer (IPL). The deep capillary plexus (DCP) en face image started at 15 µm beneath the IPL and ended at 70 µm below the IPL. Manual correction was executed and propagated in case of erroneous determination by the built-in software. In addition, to capture all flow signals that might be affected by induced intraretinal edema following PRP, an "inner retinal slab" was manually modified by starting at 3 µm under the ILM and ending at 70 µm or more beneath the IPL.

The vascular density was measured and recorded by the built-in software at the mentioned slabs.. The fovea and parafovea were defined based on Early Treatment Diabetic Retinopathy Study (ETDRS) grid considering the 1mm and 3mm rings.. The FAZ area in the DCP was automatically measured in mm² and rechecked by two experienced investigators. If the software could not detect the outlines of the non-flow area, an experienced investigator manually depicted the borders.

The automatically generated Perim (perimeter of the outlined FAZ) was used to calculate the circularity index with the below formula, it is a measure of compactness of a shape relative to a circle:

$$\text{Circularity Index} = 4\pi \times \text{FAZ} / \text{Perimeter}^2$$

The circularity index of a regular circle is 1.0. Thus, a ratio closer to 0 indicates an irregular shape. The automatically measured choroidal flow, the peripapillary, inside disk and also the whole disc density were also documented.[20–22]

Based on the guidelines published by ETDRS Research Group, PRP was done at 2 to 3 consecutive sessions by an independent ophthalmologist..[23] The laser power had been titrated to produce the typical gray-white lesion with a spot size of 500 µm with a number of at least 600 to 800 spots in each session evenly distributed in all 4 peripheral quadrants.

Patients were evaluated at months 4, 8 and 12 to determine the necessity of additional PRP. Intravitreal bevacizumab was injected after PRP if the CMT was more than 310 and vision was decreased to less than 20/25.

Statistical Analysis

To assess the relation of the variables in different times, we used correlation coefficient. Also, we used a linear mixed model to assess the relation of the changes of different variables on the CMT changes after treatment. In order to address the inter-eye correlation, generalized estimating equation (GEE) model was used. All statistical analysis performed by SPSS Software (IBM Corp. Released 2017. IBM SPSS Statistics for Windows, Version 25.0.

Armonk, NY: IBM Corp.). P-value less than 0.05 is considered statistically significant.

Results

Among 48 eyes (27 patients), 39 eyes (21 patients) were enrolled in to the analysis.

Nine eyes were excluded due to poor imaging qualities at 1 or 6 months after PRP or loss to follow up.

PDR was regressed after 1 month in all the 39 eyes and there was no need for additional PRP. The Table 1 shows visual acuity, superficial and deep retinal capillary densities, deep FAZ area, perim, circularity index and retinal thickness measurements before and after PRP.

Table1. The Optical coherence tomography angiography (OCT-A) parameters of macula at baseline, 1 month and 6 months after pan-retinal photocoagulation (PRP)

	Baseline	1 month after PRP	6 months after PRP	P value*	P value†	P Value ‡
CDVA (LogMAR)	0.29 ± 0.17 (0-0.7)	0.31 ± 0.16 (0-0.7)	0.34 ± 0.19 (0-0.7)	0.979	0.606	0.810
SCP Foveal (%)	13.521 ± 5.712	13.674 ± 5.692	14.593 ± 6.603	0.999	0.864	0.915
Parafoveal SCP (%)	40.405 ± 4.816	38.024 ± 4.814	38.41 ± 4.071	0.111	0.194	0.981
Foveal DCP (%)	26.223 ± 7.095	26.28 ± 6.938	27.743 ± 7.923	1.00	0.807	0.829
Parafoveal DCP (%)	45.792 ± 5.115	45.283 ± 6.436	45.379 ± 6.337	0.975	0.989	1.00
Foveal inner retinal slab capillary densities (%)	23.195 ± 6.14	22.909 ± 6.91	23.345 ± 9.275	0.997	1.00	0.997
Parafoveal inner retinal slab capillary densities (%)	49.215 ± 6.291	46.72 ± 6.109	45.259 ± 4.954	0.241	0.015	0.649
Deep FAZ area (mm ²)	0.35 ± 0.139	0.344 ± 0.162	0.287 ± 0.132	0.999	0.075	0.170
Perim (mm)	2.458 ± 0.471	2.46 ± 0.582	2.134 ± 0.585	1.00	0.097	0.126
Circularity index of FAZ	0.703± 0.162	0.705± 0.212	0.842± 0.245	0.989	0.0476	0.0496
CST (µm)	252.923 ± 14.36 (241-300)	277.914 ± 43.252 (240-310)	289.567 ± 60.757 (248-350)	0.012	0.011	0.767

CDVA: corrected distance visual acuity; SCP: superficial capillary plexus; DCP: deep capillary plexus; FAZ: foveal avascular zone; Perim: perimeter of foveal avascular zone; CST: central subfield thickness

* P Value: the difference between 1 month after PRP and baseline: Based on Mixed model

† P Value: the difference between 6 months after PRP and baseline: Based on Mixed model

‡ P Value: the difference between 1 months after PRP and 6 months after PRP: Based on Mixed model

Mean visual acuity were 0.29 ± 0.17 , 0.31 ± 0.16 and 0.34 ± 0.19 LogMAR before, 1 and 6 months after PRP, respectively. There wasn't any significant change after PRP at each time point ($P = 0.97$ and 0.60 for 1 and 6 months after PRP, correspondingly)

Foveal vessel density in the SCP and DCP were increased after PRP, although they weren't statistically significant (all $P > 0.1$). Parafoveal vessel density in the SCP and DCP statistically unchanged before and after PRP (all $P > 0.1$). Although the foveal inner retina thick slab density wasn't significantly different from the baseline at 1st and 6th month following PRP ($P = 0.9$ for both) but the parafoveal inner retina thick slab density was significantly decreased at 6 month after PRP ($p = 0.015$). The parafoveal inner retina thick slab density despite decrease was not significantly different from baseline in the 1st month follow up visit ($P = 0.241$)

Deep FAZ area constricted 6 months following PRP. It diminished in size from $0.35 \pm 0.13 \text{ mm}^2$ to $0.34 \pm 0.16 \text{ mm}^2$ at 1 month after PRP and to $0.28 \pm 0.13 \text{ mm}^2$ 6 month after PRP, and the constriction course led to a marginal significance at 6 months after PRP ($P \text{ value} = 0.075$) in statistical analysis.

Based on calculated circularity index, the FAZ area became significantly more circular. The circularity index was 0.703 ± 0.16 at baseline which improved to 0.842 ± 0.245 at 6th month after PRP ($P = 0.047$). (Figure 1)

The mean central subfield thickness (CST) was $252.92 \pm 14.36 \text{ mm}$ (241 to 300) before PRP that was increased to $277.91 \pm 43.25 \text{ mm}$ (240 to 310) and $289.56 \pm 60.35 \text{ mm}$ (248 to 350) at 1 and 6 months after PRP ($p = 0.012$ and 0.011 , respectively). The mean change in central subfield thickness was significantly correlated with the increase in foveal superficial, deep and inner retina thick slab vascular density and FAZ constriction. ($P = 0.001$, $P = 0.018$, $P = 0.001$ and $P = 0.05$, respectively)

Central macular thickness (CMT) was less than 310, 1 month after PRP, in all cases. It was increased to more than 320 in 4 eyes at 6 months after PRP, that anti-VEGF was injected in 3 of them due to the CDVA less than 20/25.

Although choroidal flow was decreased after PRP but it was statically significant neither at 1 month nor at 6 months ($P = 0.31$ and 0.23 , respectively).

Peripapillary vascular density was decreased from 48.33 ± 3.63 at baseline to 46.37 ± 3.81 at 1 month after PRP ($p = 0.082$) and then increased to 47.04 ± 3.58 . ($p = 0.423$ from baseline) One month after PRP the inside disc vascular density was significantly increased from 48.768 ± 5.879 at baseline to 55.603 ± 5.962 ($p = 0.041$); while, it was decreased to lower than baseline amount, 6 months after PRP (45.8 ± 5.176) ($p = 0.106$ from the baseline). (Table2)

Table 2. The Optical coherence tomography angiography (OCT-A) parameters of disc at baseline, 1 month and 6 months after pan-retinal photocoagulation (PRP)

	Baseline	1 month after PRP	6 months after PRP	P value*	P value†	P Value ‡
Peripapillary VD (%)	48.339 ± 3.632	46.372 ± 3.814	47.042 ± 3.582	0.082	0.423	0.861
Inside disc VD (%)	48.768 ± 5.879	55.603 ± 5.962	45.8 ± 5.176	0.041	0.106	0.033
Whole disc VD (%)	46.041 ± 3.198	44.472 ± 3.395	45.144 ± 3.146	0.132	0.608	0.805

VD: vascular density

* P Value: the difference between 1 month after PRP and baseline: Based on Mixed model

† P Value: the difference between 6 months after PRP and baseline: Based on Mixed model

‡ P Value: the difference between 6 months after PRP and 1 month after PRP: Based on Mixed model

Discussion

In the present study, using OCTA, the alterations of main elements of retinal hemodynamics including vascular density, FAZ, choroidal flow and disc vessels density following the laser PRP treatment in patients with diabetic retinopathy were documented.

Mean vascular density of the superficial and deep capillaries in the fovea and parafoveal area, remained statistically unchanged short term and long term after PRP. Although, parafoveal “inner retina” vascular density decline started at 1 month after PRP, its reduction became statically significant 6 months after PRP. (Table1) It appears that this decrease was mostly due to superficial vascular density reduction, as deep vascular density at parafoveal area remained stable either 1 month or 6 months from the baseline. We found small parafoveal cysts in 16 eyes of 39 enrolled eyes in the study, which may induce the density reduction due to imaging faults. Also the rearrangement of vascular plexus after PRP and inward migration of the parafoveal vessels due to these cysts may be the other explanation for parafoveal inner retinal vascular density reduction.[24, 25]

In this investigation, foveal superficial and deep vascular density slightly increased following PRP; while not statistically significant. Redistribution of the foveal superficial and deep vascular circulation after PRP might be a reason for this phenomena. In addition, nitric oxide(NO) overproduction due to PRP-induced inflammation, may play an important role in vasodilation of the retinal capillaries. It could be a trigger for reperfusion of the occluded vessels, make them more detectable with OCTA. [26, 27] This increase in vascular density was significantly associated with FAZ constriction ($p = 0.05$)

We detected a mild but statistically significant increase in the CMT 1 month following laser treatment that remained significant until 6 months. But, there wasn't any significant change in CDVA after PRP at early and late follow-ups. It is shown that laser PRP treatment, itself can induce clinical or subclinical macular edema. [28–32]. The blood-retinal barrier interruption has been suggested as the main etiology for this phenomena.[28] Meanwhile, the control of hyperglycemia and underlying diseases other than diabetes mellitus like blood pressure, also play an important role [31]. Although the change in foveal thickness was parallel to foveal SCP, DCP, inner thick retina slab density and FAZ constriction as well, the change in CMT was not associated with the alterations in visual acuity. As Soman et al[25] showed, CMT increase does not influence the functional outcomes in more than 80 % of their cases after PRP. As we have mentioned there were 3 eyes with macular thickness more than 320 micron and CDVA less than 20/25 that needed intravitreal injection after 6 months.

It has been suggested that, the alterations in the FAZ area could be an important marker for macular status monitoring before or after treatment in diabetic patients. [33–35]. Based on previous studies using OCTA, FAZ enlargement specially in deep capillary plexus might be a common finding in patients with diabetes mellitus regardless of concomitant diabetic retinopathy, in comparison to patients without DM. [19] Also, enlargement of FAZ in diabetic retinopathy, has been confirmed based on OCTA or FA findings[36, 37]. The capillary occlusion due to hyperglycemia induced microangiopathy has been suggested as the main etiology for FAZ enlargement in patients with diabetes mellitus [19]. Although marginally significant, our analyses revealed FAZ area constriction 6 months following PRP. But increasing in circularity index was statistically significant after 6 months, which means that FAZ area may be become more circular and regular after PRP. Based on previous studies, reflow of occluded macular capillary plexus is possible in the setting of both NPDR and PDR [38]. We hypothesis that, although PRP may induce transient VEGF overexpression but PRP-induced oxygenation of the retina and the resulting reduction in VEGF production in long term may be the reason [39], and therefore reflow of macular capillaries, is the acceptable mechanism underlying reduction in the FAZ area and the increase of circularity index after PRP. The OCTA's intrinsic ability to detect open vessels with sufficient blood flow led to this observation[18]. The observed increase in macular vascular density can also be justified by this theory.

Recently Lorusso et al.[40] investigated the short and long-term effects of PRP on macular perfusion based on OCTA imaging. In contrast to our results, they did not find any significant alteration in the retinal hemodynamics indices. The use frequency doubled Nd:YAG pattern scan laser in the mentioned study as opposed to the conventional argon laser PRP employed by us might be the source of difference. As it is

shown previously, the short-pulse laser delivery system results in less destructive and possibly anti-ischemic effects at the molecular levels. [41, 42]

In contrast to previously published investigation on choroidal flow following PRP by Takahashi et al. submacular choroidal flow did not change significantly after PRP in our study based on OCTA. They had used laser Doppler flowmetry and observed a significant rise in subfoveal choroidal flow 1 month following PRP in the cases without clinically significant macular edema [43]. They extrapolated two mechanisms for that increase in choroidal flow, one was the redistribution of choroidal blood flow from the peripherally located obliterated capillaries to the posterior pole and the other was the localized inflammatory responses in choroid that triggered by PRP [43]. Flower et al also reported marked increase in the choriocapillaris blood flow by indocyanine green angiography (ICGA) in the macular area in comparison to the peripheral capillaries in monkey eyes following coagulating the peripheral retinal area [24]. Augsten et al, reported improvement of macular choroidal circulation using a reflection spectra method in patients with PDR treated by peripheral retinal photocoagulation. [26] Using different measurement techniques; OCTA vs. Doppler flowmetry or ICGA may be the main reason for this discrepancy between the studies.

OCTA provides an effective way to visualize the vessels in the peripapillary and inside disk region. This allows us to evaluate their changes in the density after PRP. Peripapillary vascular density was decreased from baseline to 1 month after PRP ($p = 0.082$) and then increased after 6 months to the amount less than baseline ($p = 0.423$). One hypothesis for this reduction is peripapillary neovascularization reduction. Inside disc vascular density was increased at 1 month PRP and then the decrease to lower than baseline after 6 months may be due to optic disc tiny vessels dilatation immediately after PRP that return to normal diameter along with neovascularization regression in the following months. [44]

Our study had several limitations. The major drawback is the relatively small sample size impeding us from drawing a conclusion regarding the association between alterations of vessel density and PRP treatment. As this investigation was done on the eyes without significant macular edema and the eyes with high risk proliferative retinopathy were also excluded, therefore the results of this study should not be extrapolated to the treatment of the eyes with more severe retinopathies or macular edema. During the imaging process, several artifacts may interfere with OCTA measurements, especially in eyes with macular edema. Unfortunately, despite recent advances in the OCTA software, many of these artifacts cannot be readily fixed with the present-day technologies. Although the images with low quality were excluded, other forms of artifacts including projection, motion and segmentation artifact might still negatively affect our measurements. Another drawback is the lack of data regarding metabolic control in our patient, however the 5 to 7 months follow-up period deems it less necessary. Confounding factors such as the need for anti-VEGF injections and loss to follow up also precluded us from data gathering longer than 6 months.

Conclusion

Although OCTA parameters were not significantly affected by PRP at both short- (1-month) long-term (6-month) follow-up, but FAZ area may be become more circular and regular after PRP may be due to reflow of occluded capillary plexus.

Declarations

- Ethics approval and consent to participate

Institutional review board approval was obtained from the Tehran University of Medical Sciences (IR.TUMS.FARABIH.REC.1398.021, <http://ethics.research.ac.ir/>)

Written informed consents were obtained from each participant.

As the research involving human participants, all procedures performed in studies involving human participants were in accordance with the ethical standards of the institutional and/or national research committee and with the 1964 Helsinki declaration and its later amendments or comparable ethical standards.

- Consent for publication: Not applicable.
- Availability of data and materials:

The datasets used and /or analysed during the current study are available upon reasonable request.

- Competing interests: None of the authors have any proprietary interests or conflicts of interest related to this submission.
- Funding: None
- Acknowledgments

The authors appreciate MS.Pooran Fadakar who help us for providing the patient's OCT-Angiography images.

- Authors' contributions

Concept and design (HF, AK, FG); data acquisition (HR, AH, FB); data analysis/interpretation (HR, FT, HK, AK); drafting of the manuscript (HR, RM, SF); critical revision of the manuscript (HF, MR, FG, AT, HF); statistical analysis (RM, FT); supervision (HF, MR, AM); All authors read and approved the final manuscript.

Abbreviations

CDVA: Corrected distance visual acuity

VA: Visual acuity

CMT: Central macular thickness

DME: Diabetic macular edema

ELM: External limiting membrane

NPDR: Nonproliferative diabetic retinopathy

PDR: Proliferative diabetic retinopathy

SCP: Superficial capillary

DCP: Deep capillary plexus

FAZ: Foveal avascular area

Perim: perimeter

PRP: Panretinal photocoagulation

OCTA: Optical coherence tomography angiograph

OCT: optical coherence tomography

VEGF: Vascular endothelial growth factor

FA: fluorescein angiography

ILM: Internal limiting membrane

IPL: Inner plexiform layer

DCP: Deep capillary plexus

References

- 1.Ruta LM, Magliano DJ, Lemesurier R, Taylor HR, Zimmet PZ, Shaw JE: *Prevalence of diabetic retinopathy in Type 2 diabetes in developing and developed countries. Diabetic medicine: a journal of the British Diabetic Association* 2013, *30*(4):387–398.
- 2.*Photocoagulation treatment of proliferative diabetic retinopathy. Clinical application of Diabetic Retinopathy Study (DRS) findings, DRS Report Number 8. The Diabetic Retinopathy Study Research Group. Ophthalmology* 1981, *88*(7):583–600.
- 3.Moriarty AP, Spalton DJ, Shilling JS, Ffytche TJ, Bulsara M: *Breakdown of the blood-aqueous barrier after argon laser panretinal photocoagulation for proliferative diabetic retinopathy. Ophthalmology* 1996,

103(5):833–838.

4.Mansour AM, Bynoe LA, Welch JC, Pesavento R, Mahendradas P, Ziemssen F, Pai SA: *Retinal vascular events after intravitreal bevacizumab. Acta ophthalmologica* 2010, 88(7):730–735.

5.Shimura M, Yasuda K: *Macular ischaemia after intravitreal bevacizumab injection in patients with central retinal vein occlusion and a history of diabetes and vascular disease. The British journal of ophthalmology* 2010, 94(3):381–383.

6.Mendivil A: *Ocular blood flow velocities in patients with proliferative diabetic retinopathy after panretinal photocoagulation. Survey of ophthalmology* 1997, 42 Suppl 1:S89–95.

7.Savage HI, Hendrix JW, Peterson DC, Young H, Wilkinson CP: *Differences in pulsatile ocular blood flow among three classifications of diabetic retinopathy. Investigative ophthalmology & visual science* 2004, 45(12):4504–4509.

8.Campochiaro PA, Bhisitkul RB, Shapiro H, Rubio RG: *Vascular endothelial growth factor promotes progressive retinal nonperfusion in patients with retinal vein occlusion. Ophthalmology* 2013, 120(4):795–802.

9.Manousaridis K, Talks J: *Macular ischaemia: a contraindication for anti-VEGF treatment in retinal vascular disease? The British journal of ophthalmology* 2012, 96(2):179–184.

10.Yamana Y, Oka Y, Ohnishi Y, Ishibashi T, Inoguchi T: *Reflow of obstructed capillaries in the maculae of humans with diabetic retinopathy, observed by fluorescein angiography. The British journal of ophthalmology* 1988, 72(9):660–665.

11.Campochiaro PA, Wykoff CC, Shapiro H, Rubio RG, Ehrlich JS: *Neutralization of vascular endothelial growth factor slows progression of retinal nonperfusion in patients with diabetic macular edema. Ophthalmology* 2014, 121(9):1783–1789.

12.Spaide RF, Klancnik JM, Jr., Cooney MJ: *Retinal vascular layers imaged by fluorescein angiography and optical coherence tomography angiography. JAMA ophthalmology* 2015, 133(1):45–50.

13.Chalam KV, Sambhav K: *Optical Coherence Tomography Angiography in Retinal Diseases. Journal of ophthalmic & vision research* 2016, 11(1):84–92.

14.Sambhav K, Grover S, Chalam KV: *The application of optical coherence tomography angiography in retinal diseases. Survey of ophthalmology* 2017, 62(6):838–866.

15.Shahlaee A, Samara WA, Hsu J, Say EA, Khan MA, Sridhar J, Hong BK, Shields CL, Ho AC: *In Vivo Assessment of Macular Vascular Density in Healthy Human Eyes Using Optical Coherence Tomography Angiography. American journal of ophthalmology* 2016, 165:39–46.

- 16.Durbin MK, An L, Shemonski ND, Soares M, Santos T, Lopes M, Neves C, Cunha-Vaz J: *Quantification of Retinal Microvascular Density in Optical Coherence Tomographic Angiography Images in Diabetic Retinopathy. JAMA ophthalmology* 2017.
- 17.Schottenhamml J, Moulton EM, Ploner S, Lee B, Novais EA, Cole E, Dang S, Lu CD, Husvagt L, Waheed NK *et al*: *AN AUTOMATIC, INTERCAPILLARY AREA-BASED ALGORITHM FOR QUANTIFYING DIABETES-RELATED CAPILLARY DROPOUT USING OPTICAL COHERENCE TOMOGRAPHY ANGIOGRAPHY. Retina (Philadelphia, Pa)* 2016, *36 Suppl 1*:S93-s101.
- 18.Samara WA, Shahlaee A, Adam MK, Khan MA, Chiang A, Maguire JI, Hsu J, Ho AC: *Quantification of Diabetic Macular Ischemia Using Optical Coherence Tomography Angiography and Its Relationship with Visual Acuity. Ophthalmology* 2017, *124(2)*:235–244.
- 19.Takase N, Nozaki M, Kato A, Ozeki H, Yoshida M, Ogura Y: *ENLARGEMENT OF FOVEAL AVASCULAR ZONE IN DIABETIC EYES EVALUATED BY EN FACE OPTICAL COHERENCE TOMOGRAPHY ANGIOGRAPHY. Retina (Philadelphia, Pa)* 2015, *35(11)*:2377–2383.
- 20.Choi J, Kwon J, Shin JW, Lee J, Lee S, Kook MS: *Quantitative optical coherence tomography angiography of macular vascular structure and foveal avascular zone in glaucoma. PloS one* 2017, *12(9)*:e0184948.
- 21.Domalpally A, Danis RP, White J, Narkar A, Clemons T, Ferris F, Chew E: *Circularity index as a risk factor for progression of geographic atrophy. Ophthalmology* 2013, *120(12)*:2666–2671.
- 22.Bazvand F, Mirshahi R, Fadakar K, Faghihi H, Sabour S, Ghassemi F: *The Quantitative Measurements of Vascular Density and Flow Area of Optic Nerve Head Using Optical Coherence Tomography Angiography. Journal of glaucoma* 2017, *26(8)*:735–741.
- 23.Aiello LP, Avery RL, Arrigg PG, Keyt BA, Jampel HD, Shah ST, Pasquale LR, Thieme H, Iwamoto MA, Park JE *et al*: *Vascular endothelial growth factor in ocular fluid of patients with diabetic retinopathy and other retinal disorders. The New England journal of medicine* 1994, *331(22)*:1480–1487.
- 24.Flower RW, Fryczkowski AW, McLeod DS: *Variability in choriocapillaris blood flow distribution. Invest Ophthalmol Vis Sci* 1995, *36(7)*:1247–1258.
- 25.Soman M, Ganekal S, Nair U, Nair K: *Effect of panretinal photocoagulation on macular morphology and thickness in eyes with proliferative diabetic retinopathy without clinically significant macular edema. Clinical ophthalmology (Auckland, NZ)* 2012, *6*:2013–2017.
- 26.Augsten R, Konigsdorffer E, Schweitzer D, Strobel J: *Nonproliferative diabetic retinopathy-reflection spectra of the macula before and after laser photocoagulation. Ophthalmologica* 1998, *212(2)*:105–111.
- 27.Takahashi A, Nagaoka T, Sato E, Yoshida A: *Effect of panretinal photocoagulation on choroidal circulation in the foveal region in patients with severe diabetic retinopathy. The British journal of*

ophthalmology 2008, 92(10):1369–1373.

28.Lee SB, Yun YJ, Kim SH, Kim JY: *Changes in macular thickness after panretinal photocoagulation in patients with severe diabetic retinopathy and no macular edema. Retina* 2010, 30(5):756–760.

29.McDONALD HR, Schatz H: *Macular edema following panretinal photocoagulation. Retina* 1985, 5(1):5–10.

30.Shimura M, Yasuda K, Nakazawa T, Kano T, Ohta S, Tamai M: *Quantifying alterations of macular thickness before and after panretinal photocoagulation in patients with severe diabetic retinopathy and good vision. Ophthalmology* 2003, 110(12):2386–2394.

31.Soman M, Ganekal S, Nair U, Nair K: *Effect of panretinal photocoagulation on macular morphology and thickness in eyes with proliferative diabetic retinopathy without clinically significant macular edema. Clin Ophthalmol* 2012, 6(1):2013–2017.

32.Mirshahi A, Ghassemi F, Fadakar K, Mirshahi R, Bazvand F, Riazi-Esfahani H: *Effects of panretinal photocoagulation on retinal vasculature and foveal avascular zone in diabetic retinopathy using optical coherence tomography angiography: A pilot study. Journal of Current Ophthalmology* 2019.

33.Bresnick GH, Condit R, Syrjala S, Palta M, Groo A, Korth K: *Abnormalities of the foveal avascular zone in diabetic retinopathy. Archives of ophthalmology* 1984, 102(9):1286–1293.

34.Conrath J, Giorgi R, Raccah D, Ridings B: *Foveal avascular zone in diabetic retinopathy: quantitative vs qualitative assessment. Eye* 2005, 19(3):322–326.

35.Mansour A, Schachat A, Bodiford G, Haymond R: *Foveal avascular zone in diabetes mellitus. Retina* 1993, 13(2):125–128.

36.Di G, Weihong Y, Xiao Z, Zhikun Y, Xuan Z, Yi Q, Fangtian D: *A morphological study of the foveal avascular zone in patients with diabetes mellitus using optical coherence tomography angiography. Graefe's archive for clinical and experimental ophthalmology = Albrecht von Graefes Archiv fur klinische und experimentelle Ophthalmologie* 2016, 254(5):873–879.

37.Freiberg FJ, Pfau M, Wons J, Wirth MA, Becker MD, Michels S: *Optical coherence tomography angiography of the foveal avascular zone in diabetic retinopathy. Graefe's archive for clinical and experimental ophthalmology = Albrecht von Graefes Archiv fur klinische und experimentelle Ophthalmologie* 2016, 254(6):1051–1058.

38.Yamana Y, Oka Y, Ohnishi Y, Ishibashi T, Inoguchi T: *Reflow of obstructed capillaries in the maculae of humans with diabetic retinopathy, observed by fluorescein angiography. British journal of ophthalmology* 1988, 72(9):660–665.

- 39.Stefansson E: *Ocular oxygenation and the treatment of diabetic retinopathy. Survey of ophthalmology* 2006, *51*(4):364–380.
- 40.Lorusso M, Milano V, Nikolopoulou E, Ferrari LM, Cicinelli MV, Querques G, Ferrari TM: *Panretinal Photocoagulation Does Not Change Macular Perfusion in Eyes With Proliferative Diabetic Retinopathy. Ophthalmic surgery, lasers & imaging retina* 2019, *50*(3):174–178.
- 41.Alasil T, Waheed NK: *Pan retinal photocoagulation for proliferative diabetic retinopathy: pattern scan laser versus argon laser. Current opinion in ophthalmology* 2014, *25*(3):164–170.
- 42.Nishida K, Miura K, Sakaguchi H, Kamei M, Wakabayashi T, Hara C, Sakimoto S, Fukushima Y, Sayanagi K, Sato S *et al*: *The impact of spot size, spacing, pattern, duration and intensity of burns on the photocoagulation index in a geometric simulation of pan-retinal laser photocoagulation. Acta ophthalmologica* 2018.
- 43.Takahashi A, Nagaoka T, Sato E, Yoshida A: *Effect of panretinal photocoagulation on choroidal circulation in the foveal region in patients with severe diabetic retinopathy. British Journal of Ophthalmology* 2008, *92*(10):1369–1373.
- 44.Singh H, Garg S, Sharma R, Venkatesh P, Saxena R, Dada T: *Evaluation of the effect of pan retinal photocoagulation on optic nerve head parameters using HRT3. Journal of glaucoma* 2014, *23*(7):467–470.

Figures

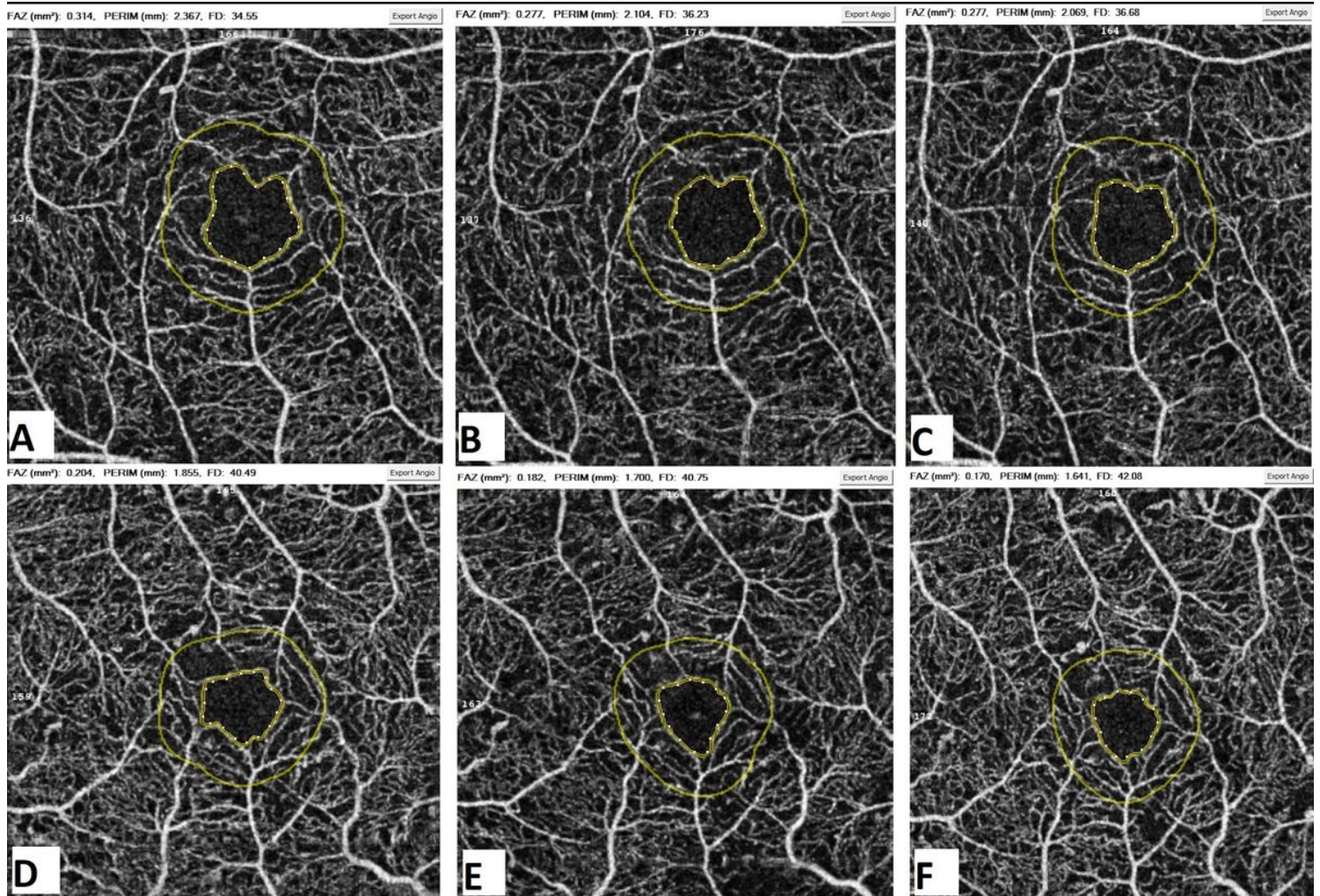


Figure 1

The FAZ area outlined in deep capillary plexus at the baseline (A and D), 1 month (B and E) and 6 months (C and F) following PRP for two different patients (upper and lower row of images). The FAZ area constricted from 0.314 mm² to 0.277 mm² in the first patient and from 0.204 mm² to 0.170 mm² in the second patient, six months after completion of PRP. The FAZ also became more circular during the study as evident by the images (A to C and D to F).