

# Matrine protects retinal ganglion cells from apoptosis in experimental optic neuritis

**Jian Kang**

the First Affiliated Hospital of Zhengzhou University

**Shu-Qing Liu**

the First Affiliated Hospital of Zhengzhou University

**Yi-Fan Song**

Peking University Third Hospital

**Meng-Ru Wang**

the First Affiliated Hospital of Zhengzhou University

**Yao-Juan Chu**

the First Affiliated Hospital of Zhengzhou University

**Ya-Min Shi**

the First Affiliated Hospital of Zhengzhou University

**Feng-Yan Zhang**

the First Affiliated Hospital of Zhengzhou University

**Hongyang Wu**

Zhengzhou University

**Lin Zhu** (✉ [zhulin66zhulin@163.com](mailto:zhulin66zhulin@163.com))

Zhengzhou University First Affiliated Hospital <https://orcid.org/0000-0001-5068-0567>

---

## Research article

**Keywords:** optic neuritis, EAE, RGCs, apoptosis

**Posted Date:** January 2nd, 2020

**DOI:** <https://doi.org/10.21203/rs.2.13687/v2>

**License:** © ⓘ This work is licensed under a Creative Commons Attribution 4.0 International License.

[Read Full License](#)

---

# Abstract

**Background:** Inflammatory demyelination and axonal injury of the optic nerve are hallmarks of optic neuritis (ON), which often occurs in multiple sclerosis and is a major cause of blindness in young adults. Although a high dose of corticosteroids can promote visual recovery, it cannot prevent permanent neuronal damage. Novel and effective therapies are thus required. Given the recently defined capacity of matrine (MAT), a quinolizidine alkaloid derived from the herb *Radix Sophorae flavescens*, in immunomodulation and neuroprotection, we tested in this study the effect of matrine on ON in rats with experimental autoimmune encephalomyelitis, an animal model of multiple sclerosis. **Results:** MAT administration, started at disease onset, significantly suppressed optic nerve infiltration and demyelination, with reduced numbers of Iba1+ macrophages/microglia and CD4+ T cells, compared to those from vehicle-treated rats. Increased expression of neurofilaments, an axon marker, and decreased apoptosis in retinal ganglion cells (RGCs) were also observed after MAT treatment. **Conclusions:** Taken as a whole, our results demonstrate that MAT attenuated inflammation, demyelination and axonal loss in the optic nerve, and protected RGCs from inflammation-induced cell death. MAT may therefore have potential as a novel treatment for this disease that causes blindness.

## Background

Optic neuritis (ON) is a disease that affects young adults ranging from 18 to 45 years of age, and also children as young as 4, which involves primary inflammation, demyelination, and axonal injury in the optic nerve (1-3). The annual incidence of ON is approximately 5 in 100,000, with a prevalence estimated to be 115 in 100,000. It can be clinically isolated or can develop as one of the manifestations of multiple sclerosis (MS) (4, 5). In 15%–20% of individuals who eventually develop MS, ON is their first sign of disease. An acute, self-limited episode of optic nerve inflammation results in demyelination, accompanied by temporary or permanent loss of vision (6, 7).

Retinal ganglion cells (RGCs), the projection neurons of the eye, undergo apoptosis with ON in the experimental autoimmune encephalomyelitis (EAE) model, and a significant loss of RGCs due to apoptosis has been demonstrated after optic nerve injury (8). Once the optic nerve is damaged, RGCs will die and axons will fail to regenerate, leading to traumatic or ischemic nerve injury or degenerative conditions in the patient (9). The death of RGCs has been considered the main cause of vision loss after an episode of ON (10, 11). In the animal model of relapsing/remitting EAE, RGC apoptosis begins within a few days after onset of optic nerve inflammation (12, 13), suggesting that axonal damage and cell loss are induced by optic nerve inflammation.

Matrine (MAT), a natural quinolizidine alkaloid compound extracted from the herb root of *Sophorae flavescens*, with a molecular weight (MW) of 258.43 (C<sub>15</sub>H<sub>24</sub>N<sub>2</sub>O) (14-16), is known for its various effects in animal models of EAE, including protection against apoptosis, tumor and fibrotic tissue development, and inflammation (17). We have recently shown that MAT can ameliorate clinical signs and alleviate neuro-axonal injury in the CNS of EAE animals by regulatory T cells, reducing Th1 and Th17 cells

in the CNS and periphery and increasing the number of neural protective molecules (18, 19). However, the ability of MAT to suppress ON and protect RGCs has not been studied.

In the present study we tested our hypothesis that MAT can not only inhibit proinflammatory response, but also promote RGC survival by protecting these cells from inflammation-induced apoptosis. By using experimental ON in an EAE rat model, we examined the effect of MAT on inflammatory cell infiltration, demyelination, and neurodegeneration and RGC apoptosis of the optic nerve.

## **Materials And Methods**

### **2.1. Animals**

Female Wistar rats, 8–10 weeks of age, were purchased from the Beijing Vital-River Experimental Animal Company, China, and housed in specific pathogen-free conditions at the Henan Province Chinese Medicine Research Institute. Every effort was made to ensure minimal animal suffering, and the guidelines of the Animal Care and Use Committee of the Henan Province Chinese Medicine Research Institute were followed for all the procedures in this study.

### **2.2. Induction of rat EAE model**

EAE was induced as described previously (20). Briefly, guinea pig spinal cord homogenate (GPSCH) was made from an equal amount of guinea pig (Beijing Vital River Experimental Animal Company) spinal cord and pre-chilled saline, and then emulsified with the same volume of complete Freund's adjuvant (CFA) (Sigma, St. Louis, MI, USA) containing 6 mg/ml *Bacillus Calmette–Guérin* vaccine (Solarbio Bio-Technology Co., Shanghai, China). Each rat was subcutaneously injected at four separate sites with 0.5 ml of antigen emulsion. All the experiments were approved by the Bioethics Committee of Zhengzhou University.

### **2.3. MAT treatment and disease assessment**

Rats immunized with antigen emulsion were randomly divided into three groups ( $n = 10$  each group). The EAE incidence was 80%, and each EAE group contained two rats that did not show clinical signs of EAE. Treatment groups include: (1) MAT (MW: 264.36, a small molecule that was purchased from Chia-Tai Tianqing Pharmaceutical Co.), was injected intraperitoneally (i.p.) at 250 mg/kg in 1 ml normal saline daily, starting from day 11 post immunization (p.i.) until the end of the experiment (day 18 p.i.); (2) immunized rats that received the same amount of saline via i.p. served as control; (3) non-immunized naïve rats that received the same amount of saline i.p. served as naïve control. All rats were monitored and scored daily from day 0 to 18 p.i. by two independent observers in a blinded manner following the standard 0–5 EAE grading scale as previously published (6, 8): 0, natural; 0.5, partial tail paralysis; 1, tail limpness or waddling gait; 1.5, loss of tail tonicity or waddling gait; 2, hind limb weakness; 2.5, partial limb paralysis; 3, paralysis of one limb; 3.5, paralysis of one limb and partial paralysis of another; 4, paralysis of two limbs; 4.5, moribund state, and 5, death.

## 2.4. Histopathological evaluation of optic nerves

To assess the extent of CNS inflammation and demyelination, the rats were sacrificed on day 18 p.i. Rats were anesthetized by intraperitoneal injection of 1% pentobarbital sodium (50 mg/kg) and extensive perfusion with 0.9% normal saline. Both sides of the optic nerves were quickly harvested and post-fixed with 4% paraformaldehyde, embedded in paraffin, and cut into paraffin sections (2–5 µm). Cross-sectional optic nerve sections (the anterior part of the optic nerve) and longitudinal optic nerve sections (the posterior part of the optic nerve) were examined from both sides of eyes for HE staining and LFB staining. The histological examination was performed and scored by light microscopy by two investigators in a blinded manner using a grading scale as previously published criteria (8): 0, no inflammatory infiltration; 1, a few scattered inflammatory cells of the optic nerve or optic nerve sheath; 2, moderate inflammatory infiltrates; 3, severe inflammatory infiltrates; 4, massive inflammatory infiltrates. Given that ON can occur either bilaterally or unilaterally, all subsequent analyses were performed using both eyes from each rat as individual data points and both cross-sectional and longitudinal optic nerve sections. An Olympus BX53 microscope (Japan Olympus Corporation) was used for the histological examination. Scores of demyelination and inflammation were calculated by Image-Pro Plus 5.0 (IPP5.0) software.

## 2.5. Immunofluorescence analysis of optic nerves and retina cross-sections

Both optic nerves and retinas from each rat were paraffin-embedded and cut into 5-µm-thick sections for immunofluorescence. CD4, Iba1 and neurofilaments (*NFs*) were assessed in the anterior part of the optic nerve, and Brn3a and TUNEL were done in the temporal retina (close to the optic nerve head). First, non-specific binding was blocked with 3% bovine serum albumin (BSA) (Serotec, UK), and permeabilized with 0.3% Triton X-100 in 1% BSA-phosphate buffer saline (PBS) for 30 min. The optic nerve sections were incubated at 4°C overnight with mouse anti-rat CD4 (1:100, Bioss, Beijing, China), mouse anti-rat Iba1 (1:100, Abcam, London, UK), rabbit anti-rat *NFs* (1:100, Bioss), followed by incubation with corresponding secondary antibodies (goat anti-mouse Cy3 conjugate, 1:200; goat anti-rabbit Alexa Fluor 488, 1:200; Invitrogen, Carlsbad, CA, USA) at room temperature for 2 h.

For double staining of RGCs and TUNEL (for apoptotic cells), comparable areas of the temporal retina were analyzed in all animals of all three groups. TUNEL reaction mixture was added before the primary antibody (Abcam) following the manufacture's instructions. RGCs-positive were detected by rabbit anti-Brn3a (1:100, both from Abcam), followed by incubation with corresponding secondary antibodies - goat anti-rabbit Cy3 conjugate (1:200, Invitrogen, Carlsbad, CA, USA) for 2 h at room temperature. To assess the number of cells, a nuclear stain 4',6-diamidino-2-phenylindole (DAPI, Roche, Shanghai, China), was added to tissue sections for 15 min prior to final washes after adding secondary antibodies. Finally, slides were visualized with confocal microscope (Olympus Fluoview FV1000).

Numbers of CD4<sup>+</sup> and Iba1<sup>+</sup> cells that had been co-stained for DAPI were counted as positive cells. Brn3a<sup>+</sup>TUNEL<sup>+</sup> cells that were co-stained for DAPI were counted as apoptotic RGCs. Image J (National

Institutes of Health, USA) was used for the cell counting. Image J was also used to assess average optical density (AOD) of NFs. The anterior part of the optic nerve was used to quantify NF intensity. Exposure time was fixed for all microscope images. All these studies were performed by two investigators in a blinded manner.

## **2.6. Statistical analysis**

All the animal groups were coded and analyses were conducted by two researchers blind to experimental conditions. Multiple comparisons were performed using one-way ANOVA, followed by Student-Newman-Keuls test. Clinical EAE scores were compared at individual time points between vehicle- and MAT-treated rats. Statistical software (GraphPad Prism 5.0; GraphPad Software) was used for statistical analyses;  $P < 0.05$  was considered significant. For all histological experiments, each eye was used as an independent data point, based on previous reports showing that optic neuritis can occur bilaterally, or unilaterally in either eye, and thus can occur as an independent event (21).

# **Results**

## **3.1. MAT treatment alleviates ongoing EAE in Wistar rats**

As shown in Fig. 1, clinical signs of EAE began on day 10 p.i., and the MAT treatment was started on day 11 p.i. The clinical scores of MAT-treated rats were significantly decreased compared with the vehicle-treated rats, starting from day 13 p.i. up to day 18 p.i. (end of the experiment) when the scores were analyzed each individual day. These results confirmed the effect of MAT treatment in ongoing EAE.

## **3.2. MAT treatment reduces optic nerve inflammation**

Consistent with the clinical scores, rats with clinical signs had massive inflammatory infiltration in the optic nerve of vehicle-treated rats, while those without clinical EAE signs also exhibited to a certain extent optic nerve inflammation. This infiltration was significantly decreased by MAT treatment ( $2.9 \pm 0.39$  vs.  $1.75 \pm 0.26$ ;  $p < 0.001$ ; Fig. 2). The number of Iba1<sup>+</sup> cells (macrophage/microglia) was largely increased in immunized rats compared to naïve rats ( $190.15 \pm 34.62$  vs.  $23.79 \pm 5.72$ ;  $p < 0.001$ ); MAT-treated rats had a significantly reduced number of Iba1<sup>+</sup> cells ( $105.56 \pm 15.04$ ) when compared to the vehicle-treated group ( $105.56 \pm 15.04$  vs.  $190.15 \pm 34.62$ ;  $p < 0.001$ ; Fig. 3A, C). A similar pattern was observed in CD4<sup>+</sup> T cells, for which a significant reduction was observed after MAT treatment compared with vehicle treatment ( $37.83 \pm 5.09$  vs.  $52.59 \pm 8.23$ ;  $p < 0.001$ ; Fig. 3B, D). These results indicate that MAT has a potent therapeutic effect in optic nerve inflammation.

## **3.3. MAT treatment decreases optic nerve demyelination**

To assess demyelination of the optic nerve after MAT treatment, all these nerves were assayed by LFB staining as described (12, 22). Optic nerves of both vehicle- and MAT-treated rats displayed significantly reduced myelin staining compared with that of naïve animals, and demyelination was markedly

decreased after MAT treatment compared to vehicle-treated rats ( $1.58 \pm 0.16$  vs.  $2.75 \pm 0.26$ ;  $p < 0.001$ ; Fig. 4A, B). Thus, MAT treatment can effectively mitigate demyelination in the optic nerves of diseased rats.

### 3.4. MAT treatment reduces axonal loss in the optic nerve

Neurofilaments (NFs), a major component of the neuronal [cytoskeleton](#), are believed to function primarily to provide structural support for the axon and to regulate axon diameter (23, 24). When optic nerve sections of all rats were therefore stained with the NF antibody (Fig. 5A), our results showed that NF expression was significantly decreased in optic nerves of immunized rats compared with naïve ones ( $50.29 \pm 8.35$  vs.  $281.51 \pm 45.98$ ;  $p < 0.001$ ), while this expression was markedly increased after MAT treatment ( $50.29 \pm 8.35$  vs.  $202.67 \pm 35.55$ ;  $p < 0.001$ ; Fig. 5B).

### 3.5. MAT treatment reduces RGC apoptosis

We then determined whether MAT has an effect in protecting RGCs from apoptosis by double staining of anti-Brn3a (for RGCs) and TUNEL (for apoptosis) (Fig. 6A). No  $\text{Brn3a}^+ \text{TUNEL}^+$  apoptotic RGCs were found in naïve rats, while the number of these cells was increased in immunized rats ( $p < 0.001$ ). There was a significant decrease after MAT treatment compared with vehicle-treated rats ( $5.40 \pm 0.82$  vs.  $11.60 \pm 1.14$ ;  $p < 0.001$ ; Fig. 6B). These results indicated that MAT treatment can reduce RGC apoptosis, and thus promote their survival.

## Discussion

ON is characterized by inflammatory demyelination and axonal injury in the optic nerve, leading to RGC loss and visual dysfunction (25). ON commonly occurs in MS patients and in its animal model, EAE, as well (8). Previous studies have described the histopathological aspects of ON, but neuronal loss in animal models of experimental ON has been less well studied. It has been found that ON is not only an inflammatory condition, but also involves significant neurodegeneration (26); however, few therapies are known to be effective for RGC protection, and neuronal loss in animal models of experimental ON has not been well addressed. We have in previous studies shown that treatment with MAT could suppress the development of EAE (27, 28); however, whether this natural alkaloid can protect neurons in ON is still unknown. Here we have for the first time provided evidence that MAT treatment resulted in clinical improvement in ON during EAE, as indicated by reduced inflammation and demyelination in the optic nerve [29]. The upregulated expression of neurofilaments and reduced RGC apoptosis after MAT treatment suggest that MAT has neuroprotective properties as well.

It has been shown that inflammatory responses play an important role in the development of ON (29), and optic nerve demyelination and infiltration have also been found to correlate with the severity of clinical disease in EAE mice (30). Among inflammatory cells, activated macrophages and microglia are the major cell types in ON that are closely associated with demyelination, axonal damage and loss of visual function (31). Indeed, when an inflammatory event occurs, such as autoimmunity, neural injuries or ischemia, microglia rapidly become activated and begin migrating to the event site while releasing pro-

inflammatory substances such as TNF- $\alpha$  and interleukins that lead to tissue damage (32). Significantly more microglia have also been found in retinas of ON, which could be a direct response to RGC degeneration (33). T cells, by secreting proinflammatory cytokines, play a major role in the inflammatory demyelination of the optic nerve (34-36). Our data show increased numbers of CD4<sup>+</sup> T cells and Iba1<sup>+</sup> microglia/macrophages in the optic nerves of ON rats, which were significantly reduced after MAT treatment. The observation in the present study on the anti-inflammatory effects of MAT in experimental ON is consistent with findings in a variety of other inflammatory diseases and animal models. MAT possesses significant anti-hepatitis, immunosuppressive, anti-tumor, and anti-hepatic fibrosis capacities (37). Previous research has shown that MAT can inhibit immune activities of T cells, B cells and macrophages, at relatively low doses, and it is known to have partially suppressed development of EAE (18). In addition, MAT therapy significantly suppressed the production of proinflammatory cytokines, such as IFN- $\gamma$ , TNF- $\alpha$  and IL-17, and blocked the migration of peripheral immune cells into the CNS (19), suggesting that it may be beneficial in ON.

NFs, which are synthesized in the neuron body and then transported into the axons, play a key role in the axonal cytoskeleton (38). Our present study suggests that an effective treatment such as MAT can preserve this axon-associated protein from inflammation-induced damage. Consistent with our observations, phosphorylated neurofilament heavy chain was found increased in serum in an ON model of MOG-specific TCR transgenic mice, indicating the NFs were released into the bloodstream from damage to optic nerve axons (39). Indeed, a 3-fold reduction in NF levels was shown in the pooled optic nerve samples from both eyes of these ON mice, which is consistent with reduced visual function and optic nerve atrophy visualized by MRI (40). Similarly, a reduced level of NF expression was observed in the spinal cord of untreated EAE mice, while this level was significantly increased after treatment, accompanied by improved clinical score of disease (41). On the other hand, demyelination of axons in the optic nerve results in apoptosis of RGCs, which is the major cause of vision loss in ON (8, 12, 42), and inhibition of proinflammatory signaling resulted in a nearly complete prevention of axonal demyelination, as well as a drastic attenuation of RGC death in ON (43). Consistent with these observations, we detected a large number of apoptotic RGCs in untreated rats, and the number was significantly reduced upon MAT treatment. These results, together with enhanced expression of NFs, suggest that MAT treatment reduces axonal loss, and then promotes RGC survival during experimental ON.

In summary, our study demonstrates that MAT effectively suppresses CNS inflammation, demyelination and axonal loss in optic nerves, as well as RGC apoptosis in experimental ON. The mechanisms underlying these effects may include: 1) its anti-inflammatory effects (18, 19, 37); 2) the potential to promote production of neurotrophic factors, such as NGF and BDNF, as previously reported (14, 15). These effects, together, could convert a hostile environment into a supportive one for neural cells, thus reducing myelin and axonal damage of the optic nerve and protecting RGCs from apoptosis. This possibility will be tested in the near future, together with a group of rats that are immunized with CFA only, without autoantigen to exclude the impact of a non-specific inflammation on the optic nerve and RGCs. Whether matrine can induce a long-term neuroprotection should also be further addressed. Taken as a

whole, our study shows that MAT is a promising potential therapy that warrants further investigation for use in ON.

## Conclusions

MAT attenuated inflammation, demyelination and axonal loss in the optic nerve, and protected RGCs from inflammation-induced cell death. MAT may therefore have potential as a novel treatment for ON.

## Abbreviations

ON, optic neuritis; MS, multiple sclerosis; RGCs, retinal ganglion cells; MAT, matrine; EAE, experimental autoimmune encephalomyelitis; NFs, neurofilaments; p.i., primary immunization; i.p., injected intraperitoneally;

## Declarations

### Ethics approval and consent to participate

This study was carried out in accordance with the recommendations of the National Institutes of Health Guide for the Care and Use of Laboratory Animals. The protocol was approved by the Institutional Animal Care and Use Committee of Zhengzhou University (2019-KY-142).

### Consent to publish

Not Applicable

### Availability of data and materials

The datasets used and/or analyzed during the current study are available from the corresponding author upon request.

### Competing interests

The authors declare that they have no conflicts of interest.

### Funding

This study was supported by the National Natural Science Foundation of China (no. 31870334) and the Province Natural Science Foundation of Henan (no. 182300410330).

### Authors' Contributions

JK and SQL drafted the article and did most of the experimental work. YFS helped to design the study, participated in the experiments and revised the article. YJC participated in the experiments. YMS helped



with the interpretation of data. FYZ and LZ designed, supported and supervised the entire work.

## Acknowledgments

The authors thank Dr. Guang-Xian Zhang for critiques and Ms. Katherine Regan, Department of Neurology, Thomas Jefferson University, USA, for editorial assistance.

## References

1. Jenna M. Gaesser, Sharyl L. Fyffe-Maricich. Intracellular signaling pathway regulation of myelination and remyelination in the CNS. *Exp Neurol*. 2016;283(Pt B):501-11.
2. Khalaj AJ, Hasselmann J, Augello C, Moore S, Tiwari-Woodruff SK. Nudging oligodendrocyte intrinsic signaling to remyelinate and repair: Estrogen receptor ligand effects. *J Steroid Biochem Mol Biol*. 2016;160:43-52.
3. Lee JY, Han J, Yang M, Oh SY. Population-based Incidence of Pediatric and Adult Optic Neuritis and the Risk of Multiple Sclerosis. *Ophthalmology*. 2019;09:032.
4. Kan QC, Pan QX, Zhang XJ, Chu YJ, Liu N, Lv P, et al. Matrine ameliorates experimental autoimmune encephalomyelitis by modulating chemokines and their receptors. *Exp Mol Pathol*. 2015;99(2):212-9.
5. Knier B, Rothhammer V, Heink S, Puk O, Graw J, Hemmer B, et al. Neutralizing IL-17 protects the optic nerve from autoimmune pathology and prevents retinal nerve fiber layer atrophy during experimental autoimmune encephalomyelitis. *J Autoimmun*. 2015;56:34-44.
6. Horstmann L, Kuehn S, Pedreiturria X, Haak K, Pfarrer C, Dick HB, et al. Microglia response in retina and optic nerve in chronic experimental autoimmune encephalomyelitis. *J Neuroimmunol*. 2016;298:32-41.
7. Amezcua L, Beecham AH, Delgado SR, Chinae A, Burnett M, Manrique CP, et al. Native ancestry is associated with optic neuritis and age of onset in hispanics with multiple sclerosis. *Ann Clin Transl Neur*. 2018;5(11):1362-71.
8. Quinn TA, Dutt M, Shindler KS. Optic neuritis and retinal ganglion cell loss in a chronic murine model of multiple sclerosis. *Front Neurol*. 2011;2:50.
9. Khan RS, Dine K, Luna E, Ahlem C, Shindler KS. HE3286 reduces axonal loss and preserves retinal ganglion cell function in experimental optic neuritis. *Invest Ophthalmol Vis Sci*. 2014;55(9):5744-51.
10. Syc SB, Saidha S, Newsome SD, Ratchford JN, Levy M, Ford E, et al. Optical coherence tomography segmentation reveals ganglion cell layer pathology after optic neuritis. *Brain*. 2012;135(Pt 2):521-33.
11. Horstmann L, Schmid H, Heinen AP, Kurschus FC, Dick HB, Joachim SC. Inflammatory demyelination induces glia alterations and ganglion cell loss in the retina of an experimental autoimmune encephalomyelitis model. *J Neuroinflammation*. 2013;10:120.
12. Shindler KS, Ventura E, Dutt M, Rostami A. Inflammatory demyelination induces axonal injury and retinal ganglion cell apoptosis in experimental optic neuritis. *Exp Eye Res*. 2008;87(3):208-13.

13. Dal Monte M, Cammalleri M, Locri F, Amato R, Marsili S, Rusciano D, et al. Fatty Acids Dietary Supplements Exert Anti-Inflammatory Action and Limit Ganglion Cell Degeneration in the Retina of the EAE Mouse Model of Multiple Sclerosis. *Nutrients*. 2018;10(3).
14. Zhu L, Pan QX, Zhang XJ, Xu YM, Chu YJ, Liu N, et al. Protective effects of matrine on experimental autoimmune encephalomyelitis via regulation of ProNGF and NGF signaling. *Exp Mol Pathol*. 2016;100(2):337-43.
15. Kan QC, Zhang HJ, Zhang Y, Li X, Xu YM, Thome R, et al. Matrine Treatment Blocks NogoA-Induced Neural Inhibitory Signaling Pathway in Ongoing Experimental Autoimmune Encephalomyelitis. *Mol Neurobiol*. 2017;54(10):8404-18.
16. Wang CY, Bai XY, Wang CH. Traditional Chinese medicine: a treasured natural resource of anticancer drug research and development. *Am J Chin Med*. 2014;42(3):543-59.
17. Yu J, Yang S, Wang X, Gan R. Matrine improved the function of heart failure in rats via inhibiting apoptosis and blocking beta3adrenoreceptor/endothelial nitric oxide synthase pathway. *Mol Med Rep*. 2014;10(6):3199-204.
18. Kan QC, Zhu L, Liu N, Zhang GX. Matrine suppresses expression of adhesion molecules and chemokines as a mechanism underlying its therapeutic effect in CNS autoimmunity. *Immunol Res*. 2013;56(1):189-96.
19. Liu N, Kan QC, Zhang XJ, Xu YM, Zhang S, Zhang GX, et al. Upregulation of immunomodulatory molecules by matrine treatment in experimental autoimmune encephalomyelitis. *Exp Mol Pathol*. 2014;97(3):470-6.
20. Jokubaitis VG, Gresle MM, Kemper DA, Doherty W, Perreau VM, Cipriani TL, et al. Endogenously regulated Dab2 worsens inflammatory injury in experimental autoimmune encephalomyelitis. *Acta Neuropathol Com*. 2013;1:32.
21. Khan, R. S., K. Dine, J. G. Geisler, and K. S. Shindler. Mitochondrial Uncoupler Prodrug of 2,4-Dinitrophenol, MP201, Prevents Neuronal Damage and Preserves Vision in Experimental Optic Neuritis. *Oxid Med Cell Longev*. 2017: 7180632.
22. Shindler KS, Guan Y, Ventura E, Bennett J, Rostami A. Retinal ganglion cell loss induced by acute optic neuritis in a relapsing model of multiple sclerosis. *Mult Scler*. 2006;12(5):526-32.
23. Jung KI, Kim EK, Park CK. Usefulness of frequency doubling technology perimetry 24-2 in glaucoma with parafoveal scotoma. *Medicine (Baltimore)*. 2017;96(24):e6855.
24. Khan RS, Dine K, Das Sarma J, Shindler KS. SIRT1 activating compounds reduce oxidative stress mediated neuronal loss in viral induced CNS demyelinating disease. *Acta Neuropathol Commun*. 2014;2:3.
25. Soelberg K, Specovius S, Zimmermann HG, Grauslund J, Mehlsen JJ, Olesen C, et al. Optical coherence tomography in acute optic neuritis: A population-based study. *Acta Neurol Scand*. 2018;138(6):566-73.
26. Mayer C, Bruehl C, Salt EL, Diem R, Draguhn A, Fairless R. Selective Vulnerability of alphaOFF Retinal Ganglion Cells during Onset of Autoimmune Optic Neuritis. *Neuroscience*. 2018;393:258-72.

27. Liu SQ, Zhang ML, Zhang HJ, Liu FZ, Chu RJ, Zhang GX, et al. Matrine promotes oligodendrocyte development in CNS autoimmunity through the PI3K/Akt signaling pathway. *Life Sci.* 2017;180:36-41.
28. Kan QC, Lv P, Zhang XJ, Xu YM, Zhang GX, Zhu L. Matrine protects neuro-axon from CNS inflammation-induced injury. *Exp Mol Pathol.* 2015;98(1):124-30.
29. Yang H, Liu C, Jiang J, Wang Y, Zhang X. Celastrol Attenuates Multiple Sclerosis and Optic Neuritis in an Experimental Autoimmune Encephalomyelitis Model. *Front Pharmacol.* 2017;8:44.
30. Stojic A, Bojcevski J, Williams SK, Bas-Orth C, Nessler S, Linington C, et al. Preclinical stress originates in the rat optic nerve head during development of autoimmune optic neuritis. *Glia.* 2018;67(3):512-24.
31. Matsunaga Y, Kezuka T, An X, Fujita K, Matsuyama N, Matsuda R, et al. Visual functional and histopathological correlation in experimental autoimmune optic neuritis. *Invest Ophthalmol Vis Sci.* 2012;53(11):6964-71.
32. Kornek B, Storch MK, Weissert R, Wallstroem E, Stefferl A, Olsson T, et al. Multiple sclerosis and chronic autoimmune encephalomyelitis: a comparative quantitative study of axonal injury in active, inactive, and remyelinated lesions. *Am J Pathol.* 2000;157(1):267-76.
33. Zhang CJ, Jiang M, Zhou H, Liu W, Wang C, Kang Z, et al. TLR-stimulated IRAKM activates caspase-8 inflammasome in microglia and promotes neuroinflammation. *J Clin Invest.* 2018;128(12):5399-412.
34. Chen GC, Tang LS, Wei W, Li Z, Li YP, Duan XC, et al. mTOR regulates neuroprotective effect of immunized CD4+Foxp3+T cells in optic nerve ischemia. *Sci Rep-Uk.* 2016;6:37805.
35. Zeka B, Hastermann M, Hochmeister S, Kogl N, Kaufmann N, Schanda K, et al. Highly encephalitogenic aquaporin 4-specific T cells and NMO-IgG jointly orchestrate lesion location and tissue damage in the CNS. *Acta Neuropathol.* 2015;130(6):783-98.
36. Das A, Guyton MK, Smith A, Wallace G, McDowell ML, Matzelle DD, et al. Calpain inhibitor attenuated optic nerve damage in acute optic neuritis in rats. *J Neurochem.* 2013;124(1):133-46.
37. Xu YX, Lin HZ, Zheng WJ, Ye XH, Yu LF, Zhuang JQ, et al. Matrine ameliorates adriamycin-induced nephropathy in rats by enhancing renal function and modulating Th17/Treg balance. *Eur J Pharmacol.* 2016;791:491-501.
38. An LH, Li GZ, Si JL, Zhang CL, Han XY, Wang SQ, et al. Acrylamide Retards the Slow Axonal Transport of Neurofilaments in Rat Cultured Dorsal Root Ganglia Neurons and the Corresponding Mechanisms. *Neurochem Res.* 2016;41(5):1000-9.
39. Talla V, Yang C, Shaw G, Porciatti V, Koilkonda RD, Guy J. Noninvasive assessments of optic nerve neurodegeneration in transgenic mice with isolated optic neuritis. *Invest Ophthalmol Vis Sci.* 2013;54(7):4440-50.
40. Costello F, Coupland S, Hodge W, Lorello GR, Koroluk J, Pan YI, et al. Quantifying axonal loss after optic neuritis with optical coherence tomography. *Ann Neurol.* 2006;59(6):963-9.
41. Neil S, Huh J, Baronas V, Li X, McFarland HF, Cherukuri M, et al. Oral administration of the nitroxide radical TEMPOL exhibits immunomodulatory and therapeutic properties in multiple sclerosis models.

42. Das A, Guyton MK, Smith A, Wallace Gt, McDowell ML, Matzelle DD, et al. Calpain inhibitor attenuated optic nerve damage in acute optic neuritis in rats. *J Neurochem*. 2013;124(1):133-46.
43. Brambilla R, Dvorianchikova G, Barakat D, Ivanov D, Bethea JR, Shestopalov VI. Transgenic inhibition of astroglial NF-kappaB protects from optic nerve damage and retinal ganglion cell loss in experimental optic neuritis. *J Neuroinflammation*. 2012;9:213.

## Figures

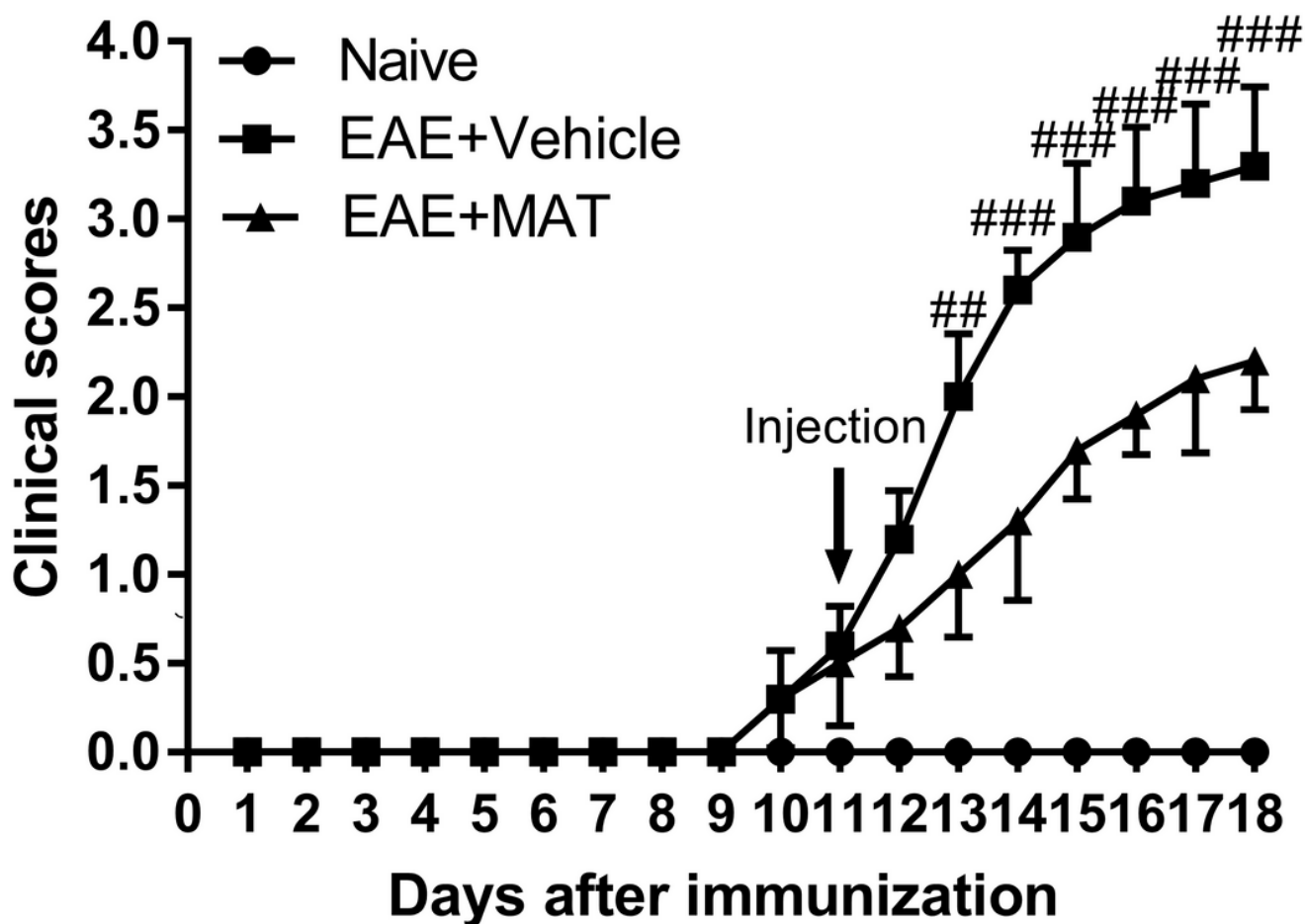


Figure 1

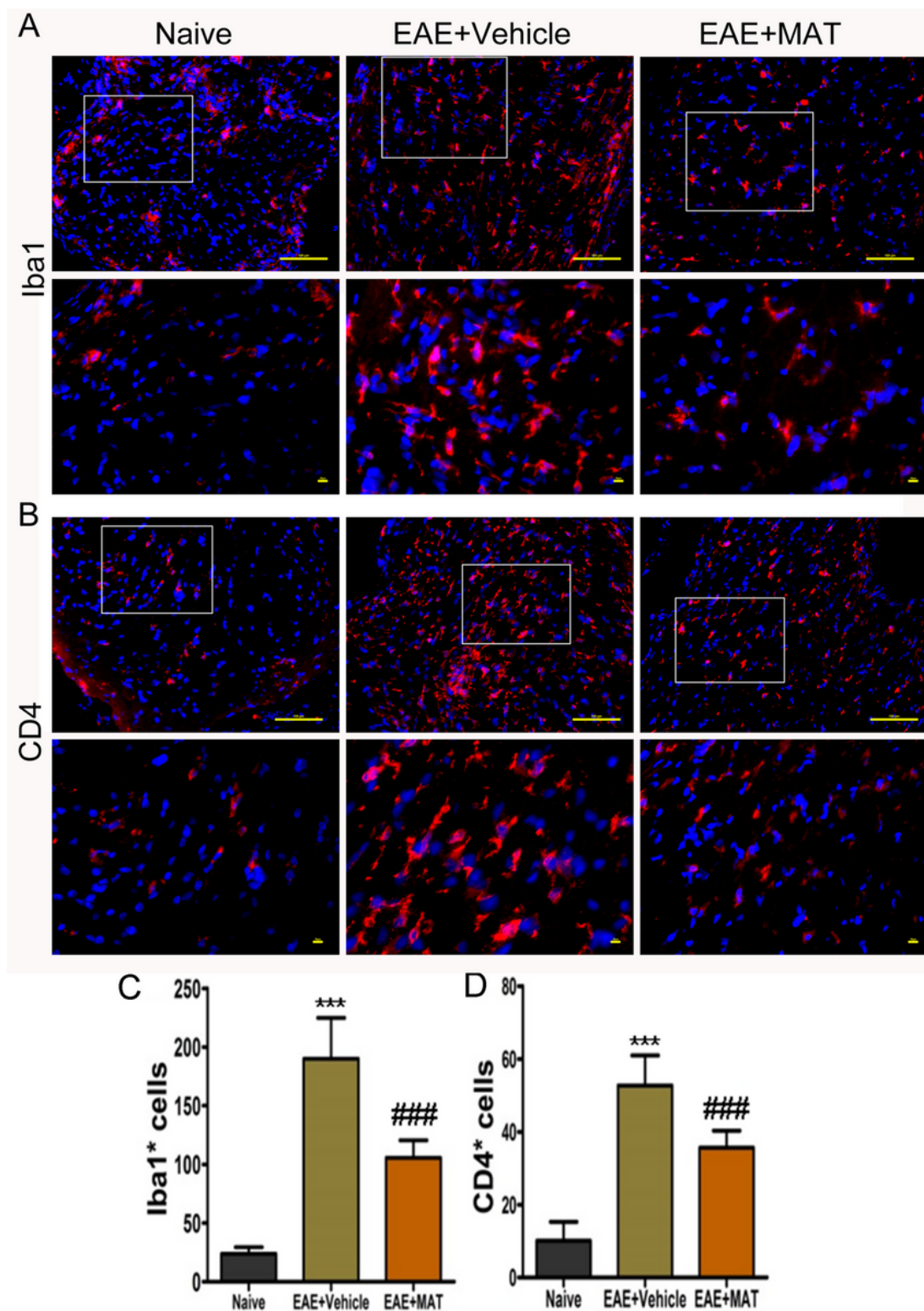
MAT ameliorates clinical signs of EAE. Wistar rats were immunized with spinal cord homogenate of guinea pig in CFA. Rats received MAT (250 mg/kg in 1 ml normal saline daily, i.p.) at onset of clinical signs of EAE until day 18 p.i., and control rats received the same volume of saline. All rats were evaluated daily for clinical scores of EAE in a blinded fashion from day 0 to 18 p.i. Clinical score - time graph of every group based on a 0–5 scale. Data represent mean  $\pm$  SD (n = 10 rats per group). Clinical EAE scores

were analyzed at single time points between treated and untreated rats using GraphPad Prism 5.0; (GraphPad Software). ## $p < 0.01$ , ### $p < 0.001$ , comparisons between vehicle- and MAT-treated groups.



## Figure 2

MAT attenuates the severity of optic nerve inflammation. (A) All rats described in Fig. 1 were euthanized and both sides of optic nerves were isolated and stained by H&E in transverse (upper row) and longitudinal (lower row) sections of optic nerves. Images were collected under the bright-field setting. Scale bars = 100  $\mu\text{m}$ . (B) Degree of inflammatory cell infiltration in optic nerves. All results are expressed as mean  $\pm$  SD ( $n = 40$  per group: both transverse and longitudinal sections, both sides of optic nerves from 10 rats per group;  $2 \times 2 \times 10 = 40$  each group). Multiple comparisons were performed using one-way ANOVA, followed by Student-Newman-Keuls test. ### $p < 0.001$ , comparisons between vehicle- and MAT-treated groups.



**Figure 3**

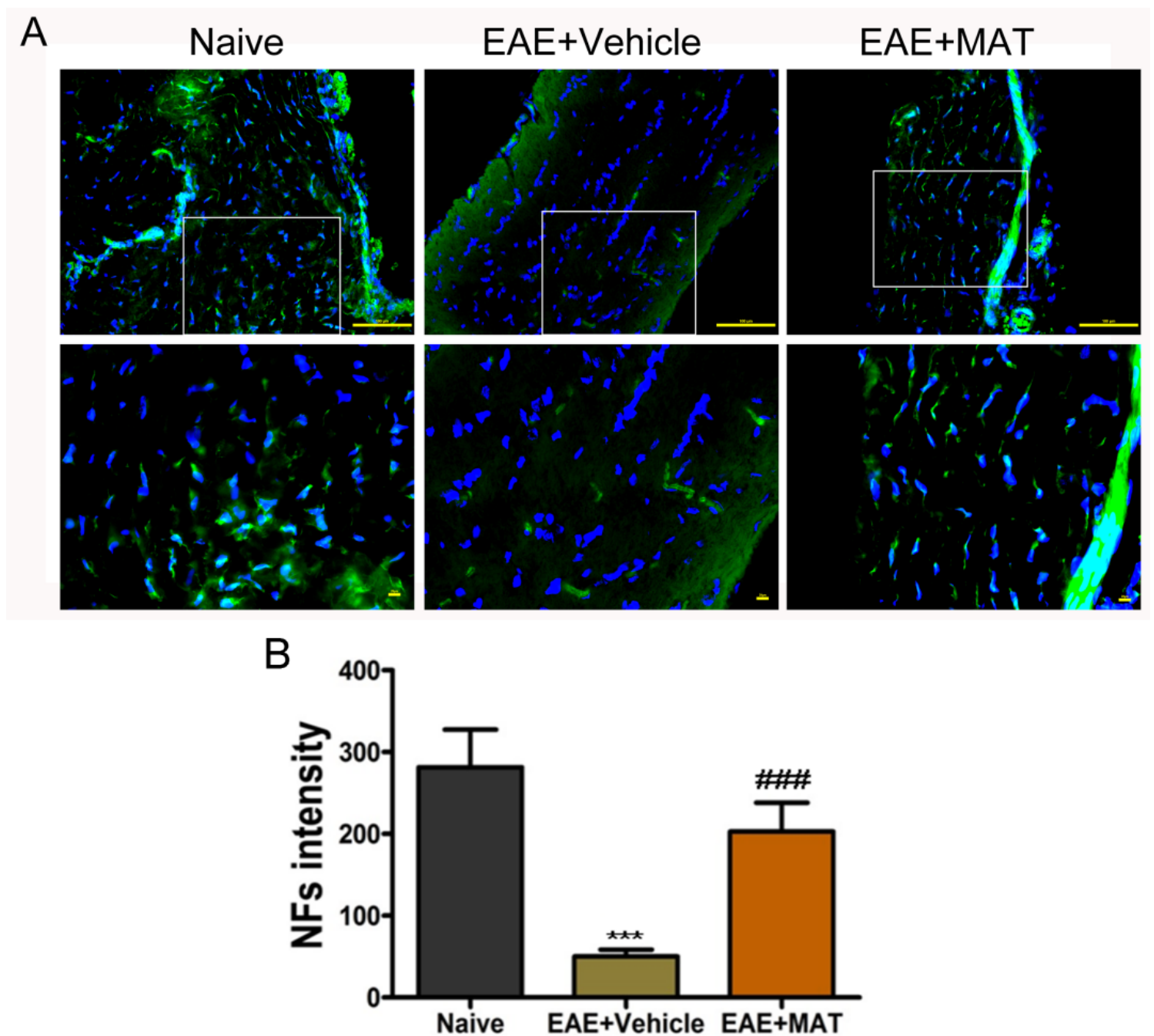
MAT treatment reduces numbers of Iba1<sup>+</sup> and CD4<sup>+</sup> cells in optic neuritis. Both sides of optic nerves were harvested from rats described in Fig. 1 at day 18 p.i. Immunofluorescence staining for Iba1 (A) and CD4 (B) in optic nerve sections. Scale bars = 100  $\mu$ m (upper row) and = 20  $\mu$ m (lower row). Quantitative analysis for the percentages of Iba1<sup>+</sup> cells (C) and CD4<sup>+</sup> (D) cells. Data are expressed as mean  $\pm$  SD (n = 20 optic nerves from 10 rats per group). Multiple comparisons were performed using one-way ANOVA,

followed by Student-Newman-Keuls test. \*\*\* $p < 0.001$ , comparison with the naive group. ### $p < 0.001$ , comparisons between vehicle- and MAT-treated groups.



#### Figure 4

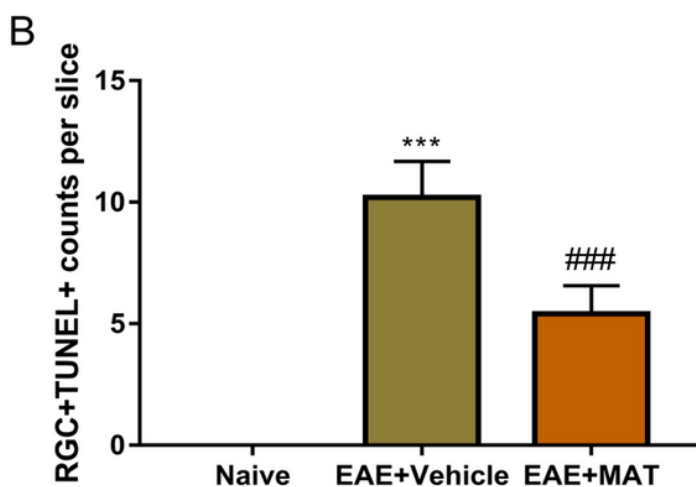
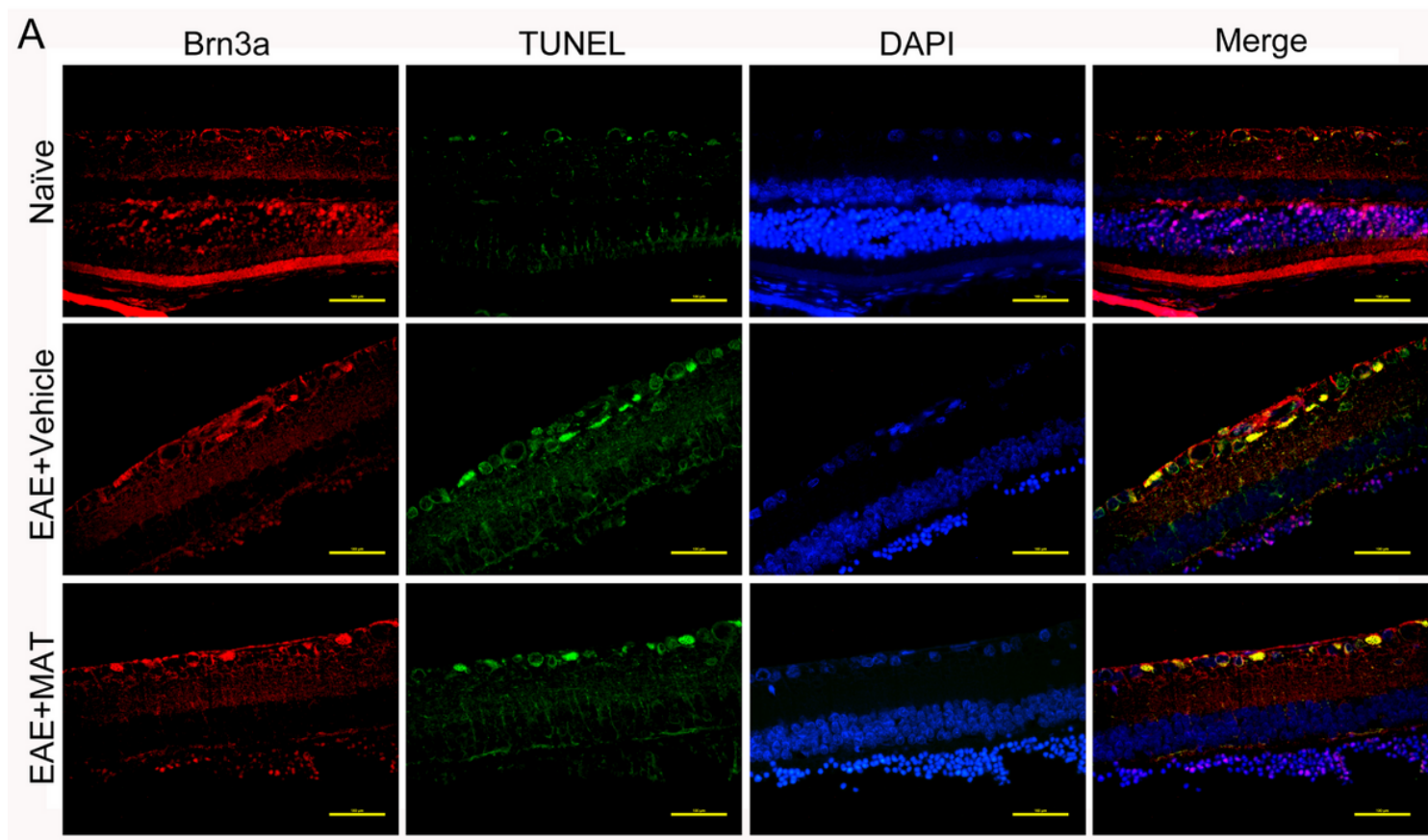
MAT attenuates demyelination in the optic nerve. (A) To confirm whether MAT can protect the optic nerve from demyelination, both sides of optic nerves were isolated from rats in Fig. 1 and stained with Luxol fast blue (LFB), which stains myelin (A). Scale bars = 100  $\mu\text{m}$ . (B) Mean scores of demyelination. For demyelination: 0, none; 1, rare foci; 2, a few areas of demyelination; and 3, large (confluent) areas of demyelination. All results are expressed as mean  $\pm$  SD ( $n = 40$  per group: both transverse and longitudinal sections, both sides of optic nerves from 10 rats per group;  $2 \times 2 \times 10 = 40$  each group). Multiple comparisons were performed using one-way ANOVA, followed by Student-Newman-Keuls test. ### $p < 0.001$ , comparisons between vehicle- and MAT-treated groups.



**Figure 5**

Effects of MAT on axonal loss in optic nerve. Both sides of optic nerves were harvested from naive and MAT- or vehicle-treated rats. (A) Detection of NF by immunofluorescence staining in optic nerve. Scale bars = 100  $\mu$ m (upper row) and = 20  $\mu$ m (lower row). (B) Quantitative analyses of immunofluorescence were expressed by average optical density (AOD) of NFs. Data are expressed as mean  $\pm$  SD (n = 20 optic nerves from 10 rats per group). Multiple comparisons were performed using one-way ANOVA, followed by Student-Newman-Keuls test. \*\*\*p<0.001, comparison with the naive group. ###p<0.001, comparisons between vehicle- and MAT-treated groups.





**Figure 6**

MAT treatment protects RGCs from apoptosis. Neuroprotective effects of MAT were evaluated by counting RGCs immune-labeled with Brn3a antibody and estimating the number of RGC deaths through TUNEL. (A) RGCs in the both sides of temporal retina were examined by immunofluorescent double staining by anti-Brn3a (red) and TUNEL (green), and all cells were co-stained with DAPI (blue). Scale bars = 100  $\mu$ m. (B) Quantitative analysis for the numbers of apoptotic RGCs (TUNEL+ Brn3a+DAPI+). Data are expressed as mean  $\pm$  SD (n = 20 temporal retina samples from 10 rats per group). Multiple comparisons

were performed using one-way ANOVA, followed by Student-Newman-Keuls test. \*\*\* $p < 0.001$ , comparison with the naive group. ### $p < 0.001$ , comparisons between vehicle- and MAT-treated groups.

## Supplementary Files

This is a list of supplementary files associated with this preprint. Click to download.

- [NC3RsARRIVEGuidelinesChecklistfilled.pdf](#)