Matrine protects retinal ganglion cells from apoptosis in experimental optic neuritis

Jian Kang
the First Affiliated Hospital of Zhengzhou University

Shu-Qing Liu
the First Affiliated Hospital of Zhengzhou University

Yi-Fan Song
Peking University Third Hospital

Meng-Ru Wang
the First Affilliated Hospital of Zhengzhou University

Yao-Juan Chu
the First Affiliated Hospital of Zhengzhou Universtity

Ya-Min Shi
the First Affiliated Hospital of Zhengzhou University

Feng-Yan Zhang
the First Affiliated Hospital of Zhengzhou University

Hongyang Wu
Zhengzhou University

Lin Zhu (zhulin66zhulin@163.com)
Zhengzhou University First Affiliated Hospital https://orcid.org/0000-0001-5068-0567

Research article

Keywords: optic neuritis, EAE, RGCs, apoptosis

Posted Date: August 30th, 2019

DOI: https://doi.org/10.21203/rs.2.13687/v1

Abstract

Background: Inflammatory demyelination and axonal injury of the optic nerve are hallmarks of optic neuritis (ON), which often occurs in multiple sclerosis and is a major cause of blindness in young adults. Although a high dose of corticosteroids can promote visual recovery, it cannot prevent permanent neuronal damage. Novel and effective therapies are thus required. Given the recently defined capacity of matrine (MAT), a quinolizidine alkaloid derived from the herb Radix Sophorae flavescens, in immunomodulation and neuroprotection, we tested in this study the effect of matrine on ON in rats with experimental autoimmune encephalomyelitis, an animal model of multiple sclerosis.

Results: MAT administration, started at disease onset, significantly suppressed optic nerve infiltration and demyelination, with reduced numbers of Iba1+ macrophages/microglia and CD4+ T cells, compared to those from vehicle-treated rats. Increased expression of neurofilaments, an axon marker, and decreased apoptosis in retinal ganglion cells (RGCs) were also observed after MAT treatment.

Conclusions: Taken as a whole, our results demonstrate that MAT attenuated inflammation, demyelination and axonal loss in the optic nerve, and protected RGCs from inflammation-induced cell death. MAT may therefore have potential as a novel treatment for this disease that causes blindness.

Background

Optic neuritis (ON) is a disease that affects young adults ranging from 18 to 45 years of age, and also children as young as 4, which involves primary inflammation, demyelination, and axonal injury in the optic nerve (1–3). The annual incidence of ON is approximately 5 in 100,000, with a prevalence estimated to be 115 in 100,000. It can be clinically isolated or can develop as one of the manifestations of multiple sclerosis (MS) (4, 5). In 15%–20% of individuals who eventually develop MS, ON is their first sign of disease. An acute, self-limited episode of optic nerve inflammation results in demyelination, accompanied by temporary or permanent loss of vision (6, 7).

Retinal ganglion cells (RGCs), the projection neurons of the eye, undergo apoptosis with ON in the experimental autoimmune encephalomyelitis (EAE) model, and a significant loss of RGCs due to apoptosis has been demonstrated after optic nerve injury (8). Once the optic nerve is damaged, RGCs will die and axons will fail to regenerate, leading to traumatic or ischemic nerve injury or degenerative conditions in the patient (9). The death of RGCs has been considered the main cause of vision loss after an episode of ON (10, 11). In the animal model of relapsing/remitting EAE, RGC apoptosis begins within a few days after onset of optic nerve inflammation (12, 13), suggesting that axonal damage and cell loss are induced by optic nerve inflammation.

Matrine (MAT), a natural quinolizidine alkaloid compound extracted from the herb root of Sophorae flavescens, with a MW of 258.43 ($C15H24N2O$) (14–16), is known for its various effects in animal models of EAE, including protection against apoptosis, tumor and fibrotic tissue development, and inflammation (17). We have recently shown that MAT can ameliorate clinical signs and alleviate neuro-

axonal injury in the CNS of EAE animals by regulatory T cells and reducing Th1 and Th17 cells in the CNS and periphery and increasing the number of neural protective molecules (18, 19). However, the ability of MAT to suppress ON and protect RGCs has not been studied.

In the present study we tested our hypothesis that MAT cannot only inhibit proinflammatory response, but also promote RGC survival by protecting these cells from inflammation-induced apoptosis. By using experimental ON in an EAE rat model, we examined the effect of MAT on inflammatory cell infiltration, demyelination, and neurodegeneration and RGC apoptosis of the optic nerve.

Materials And Methods

2.1. Animals

Female Wistar rats, 8–10 weeks of age, were purchased from the Beijing Vital-River Experimental Animal Company, China, and housed in specific pathogen-free conditions at the Henan Province Chinese Medicine Research Institute. Every effort was made to ensure minimal animal suffering, and the guidelines of the Animal Care and Use Committee of the Henan Province Chinese Medicine Research Institute were followed for all the procedures in this study.

2.2. Induction of rat EAE model

EAE was induced as described previously (20). Briefly, spinal cord homogenate of guinea pigs (Beijing Vital River Experimental Animal Company) was emulsified with the same volume of complete Freund's adjuvant (CFA) (Sigma, St. Louis, MI, USA) containing 6 mg/ml Bacillus Calmette–Guérin vaccine (Solarbio Bio-Technology Co., Shanghai, China). Each rat was subcutaneously injected at four separate sites with 0.5 ml of antigen emulsion in order to induce EAE. All the experiments were approved by the Bioethics Committee of Zhengzhou University.

2.3. MAT treatment and disease assessment

Rats immunized with antigen emulsion were randomly divided into three groups (n = 10 each group): (1) MAT (MW: 264.36, a small molecule that was purchased from Chia-Tai Tianqing Pharmaceutical Co.), was dissolved in normal saline and injected intraperitoneally (i.p.) at 250 mg/kg daily, starting from day 11 after primary immunization (p.i.) until the end of the experiment (day 19 after p.i.); (2) immunized rats that received vehicle via i.p. served as control; (3) non-immunized naïve rats that received vehicle i.p. served as naïve control.

Rats were monitored and scored daily for clinical disease severity by two independent observers following the standard 0–5 EAE grading scale as previously published (6, 8): 0, natural; 0.5, partial tail paralysis; 1, tail limpness or waddling gait; 1.5, loss of tail tonicity or waddling gait; 2, hind limb weakness; 2.5, partial limb paralysis; 3, paralysis of one limb; 3.5, paralysis of one limb and partial

paralysis of another; 4, paralysis of two limbs; 4.5, moribund state, and 5, death. Body weight was also recorded daily from the day of immunization.

2.4. Histopathological evaluation of optic nerves

To assess the extent of CNS inflammation and demyelination, the rats were sacrificed on 19 days after p.i.. Rats were anesthetized by intraperitoneal injection of 1% pentobarbital sodium (50 mg/kg) and extensive perfusion with 0.9% normal saline, the optic nerves and retinas were quickly removed and post-fixed with 4% paraformaldehyde. They were then embedded in paraffin, cut into paraffin sections (2–5 μm) and dewaxed in xylol, rehydrated. Sections were stained with hematoxylin and eosin (HE) for histological analysis and luxol fast blue (LFB) to detect demyelination. The histological examination was performed and scored by light microscopy by a blinded investigator using a grading scale as previously published criteria (Quinn, Dutt, and Shindler 2011): 0, no inflammatory infiltration; 1, a few scattered inflammatory cells of the optic nerve or optic nerve sheath; 2, moderate inflammatory infiltrates; 3, severe inflammatory infiltrates; 4, massive inflammatory infiltrates. Given that ON can occur either bilaterally or unilaterally, all subsequent analyses were performed using both eyes from each rat as individual data points. Scores of demyelination and inflammation were calculated by Image-Pro Plus 5.0 (IPP5.0) software.

2.5. Immunofluorescence analysis of optic nerves and retina cross-sections

The optic nerves and retinas from each group were paraffin-embedded and cut into 5-μm-thick sections for immunofluorescence. First, nonspecific binding was blocked with 3% bovine serum (Serotec, UK), and permeabilized with 0.3% Triton X–100 in 1% BSAPBS for 30 min. The sections were incubated at 4°C overnight with anti-Ibra1 (Abcam, London, UK), anti-CD4+ (Bioss, Beijing, China) and anti-NFs (Bioss, Beijing, China), followed by incubation with corresponding secondary antibodies at room temperature for 2 h. For double staining of RGCs and TUNEL, RGCs-positive were detected by anti-Bra3a (Abcam, London, UK), and apoptotic cells measured by TUNEL. For each group, ten sections were examined in a blinded fashion. To assess the number of cells, a nuclear stain 4',6-diamidino–2-phenylindole (DAPI, Roche, Shanghai, China), was added to tissue sections for 15 min prior to final washes after adding secondary antibodies. Finally, slides were visualized with confocal microscope (Olympus Fluoview FV1000) in 200× magnification field.

2.6. Statistical analysis

All the animal groups were coded and analyses were conducted by two researchers blind to experimental conditions. SPSS 21.0 (SPSS, IBM, USA) and GraphPad Prism 5.0 (La Jolla, CA, USA) were used for the

statistical analyses. Multiple comparisons were performed using the Kruskal-Wallis test, or ANOVA, followed by the LSD-t-test. Data are presented as mean ± SD, and $p<0.05$ was considered significant.

Results

3.1. MAT treatment alleviates ongoing EAE in Wistar rats

To observe the therapeutic effects of MAT in ongoing EAE, body weight and clinical scores were measured, and disease severity was measured using the standard 0–5 grading scale. As shown in Fig. 1, clinical signs of EAE began on day 11 after p.i., when the treatment was started. When compared with the vehicle-treated rats, the clinical score of MAT-treated rats was significantly reduced ($p< 0.05$), confirming the effect of MAT treatment in ongoing EAE.

3.2. MAT treatment reduces optic nerve inflammation

In order to determine whether MAT ameliorated the degree of optic nerve inflammation, rats were euthanized on day 19 after p.i., optic nerve sections were examined by hematoxylin-eosin (HE) staining for areas of inflammatory cell infiltration, and inflammation was graded on a 0- to 4-point scale. Optic nerve sections from naïve rats served as normal controls. Consistent with the clinical scores, massive inflammatory infiltration was found in the optic nerve of vehicle-treated rats, while this infiltration was significantly decreased by MAT treatment (Fig. 2, $P< 0.05$).

To further confirm the infiltration of inflammatory cells, sections of optic nerve were stained with a macrophage/microglia-specific marker, Iba1 (Fig. 3A), and CD4 T cells (Fig. 3B), two important immune cell types in ON (9). Our results showed that the number of $Iba1^+$ cells was largely increased in immunized rats; MAT treated rats had a significantly reduced number of $Iba1^+$ cells when compared to the vehicle-treated group (Fig. 3C). A similar pattern was observed in $CD4^+$ T cells, for which a significant reduction was observed after MAT treatment (Fig. 3D). These results indicate that MAT has a potent therapeutic effect in optic nerve inflammation.

3.3. MAT treatment decreases optic nerve demyelination

Once inflammation occurs, demyelination of the optic nerve begins and can be detected by LFB staining of myelin (12, 21). To assess demyelination of the optic nerve after MAT treatment, LFB staining was performed in all rats. Optic nerves of both vehicle- and MAT-treated rats displayed significantly reduced myelin staining compared with that of naïve animals, and demyelination was markedly decreased after MAT treatment compared to vehicle-treated rats (Fig. 4A, B). Thus, MAT treatment can effectively mitigate demyelination in the optic nerves of diseased rats.

3.4. MAT treatment reduces axonal loss in the optic nerve

Neurofilaments (NFs), a major component of the neuronal cytoskeleton, are believed to function primarily to provide structural support for the axon and to regulate axon diameter (22, 23). Optic nerve sections of all rats were therefore stained with NF antibody to test whether MAT can protect axons from inflammation-induced damage (Fig. 5A). Our results showed that NF expression was significantly decreased in optic nerves of vehicle-treated rats compared with naïve ones, while this expression was greatly profoundly restored after MAT treatment (Fig. 5B).

3.5. MAT treatment reduces RGC apoptosis

To determine whether MAT has an effect on decreasing RGC apoptosis and protecting RGC survival in ON, retinas were harvested from all rats and double staining was performed using anti-Brn3a (for RGCs) and TUNEL (for apoptosis) antibodies (Fig. 6A). Compared to naïve rats, the number of Brn3a+TUNEL+ in immunized rats was increased, while there was a significant decrease after MAT treatment compared with vehicle-treated rats (Fig. 6B). These results indicated that MAT treatment can reduce RGC apoptosis, and thus promote their survival.

Discussion

ON is characterized by inflammatory demyelination and axonal injury in the optic nerve, leading to RGC loss and visual dysfunction (24). ON commonly occurs in MS patients and in its animal model, EAE, as well (8). Previous studies have described the histopathological aspects of ON, but neuronal loss in animal models of experimental ON has been less well studied. It has been found that ON is not only an inflammatory condition, but also involves significant neurodegeneration (25); however, few therapies are known to be effective for RCG protection, and neuronal loss in animal models of experimental ON has not been well addressed. The goal of this study is to explore the potential anti-inflammatory and neuroprotective activities of MAT in ON of EAE rats. We have in previous studies shown that treatment with MAT could prevent EAE (26, 27); however, whether this natural alkaloid can protect neurons in ON is still unknown. Here we have for the first time provided evidence that MAT treatment resulted in clinical improvement in ON during EAE, as indicated by reduced inflammation and demyelination in the optic nerve [28]. The upregulated expression of neurofilaments and reduced RGC apoptosis after MAT treatment suggest that MAT has neuroprotective properties as well.

It has been shown that inflammatory responses play an important role in the development of ON (28), and optic nerve demyelination and infiltration have also been found to correlate with the severity of clinical disease in EAE mice (29). Among inflammatory cells, activated macrophages and microglia are the major cell types in ON that are closely associated with demyelination, axonal damage and loss of visual function (30). Indeed, when an inflammatory event occurs, such as autoimmunity, neural injuries or ischemia, microglia rapidly become activated and begin migrating to the event site while releasing pro-inflammatory substances such as TNF-α and interleukins that lead to tissue damage (31). Significantly more microglia have also been found in retinas of ON, which could be a direct response to RGC

degeneration (32). T cells, by secreting proinflammatory cytokines, play a major role in the inflammatory demyelination of the optic nerve (33–35). Our data show increased numbers of $CD4^+$ T cells and $Iba1^+$ microglia/macrophages in the ON rats, which were significantly reduced after MAT treatment. The observation in the present study on the anti-inflammatory effects of MAT in experimental ON is consistent with findings in a variety of other inflammatory diseases and animal models. MAT possesses significant anti-hepatitis, immunosuppressive, anti-tumor, and anti-hepatic fibrosis capacities (36). Previous research has shown that MAT can inhibit immune activities of T cells, B cells and macrophages, at relatively low doses, and it is known to have partially suppressed development of EAE (18). In addition, MAT therapy significantly suppressed the production of proinflammatory cytokines, such as IFN-γ, TNF-α and IL−17, and blocked the migration of peripheral immune cells into the CNS (19), suggesting that it may be beneficial in ON.

NFs, which are synthesized in the neuron body and then transported into the axons, play a key role in the axonal cytoskeleton (37). In the present study, a decrease in the content of NFs was observed in the vehicle-treated EAE rats, while MAT treatment effectively restored its levels to baseline. These results suggest that an effective treatment can preserve this axon-associated protein from inflammation-induced damage. Consistent with our observations, phosphorylated neurofilament heavy chain was found increased in serum in an ON model of MOG-specific TCR transgenic mice, indicating the NFs were released into the bloodstream from damage to optic nerve axons (38). Indeed, a 3-fold reduction in NF levels has been revealed in the pooled optic nerve samples from both eyes of these ON mice, which is consistent with reduced visual function and optic nerve atrophy visualized by MRI (39). Similarly, a reduced level of NF expression was observed in spinal cord of untreated EAE mice, while this level was significantly increased after treatment, accompanied by improved clinical score of disease (40). On the other hand, demyelination of axons in the optic nerve results in apoptosis of RGCs, which is the major cause of vision loss in ON (8, 12, 41), and inhibition of proinflammatory signaling resulted in a nearly complete prevention of axonal demyelination, as well as a drastic attenuation of RGC death in ON (42). Consistent with these observations, we detected a large number of apoptotic RGCs in untreated rats, and the number was significantly reduced upon MAT treatment. These results, together with enhanced expression of NFs, suggest that MAT treatment reduces axonal loss, and then promotes RGC survival during experimental ON.

In summary, our study demonstrates that MAT effectively suppresses RGCs apoptosis in experimental ON, with suppression of inflammatory demyelination and axonal loss in optic nerves. This neuroprotective effect may be due to its anti-inflammatory effects and likely other mechanisms, e.g., a direct neuroprotective capacity. Taken as a whole, our study shows that MAT is a promising potential therapy that warrants further investigation for use in ON.

Conclusions

MAT attenuated inflammation, demyelination and axonal loss in the optic nerve, and protected RGCs from inflammation-induced cell death. MAT may therefore have potential as a novel treatment for ON.

Abbreviations

ON, optic neuritis; MS, multiple sclerosis; RGCs, retinal ganglion cells; MAT, matrine; EAE, experimental autoimmune encephalomyelitis; NFs, neurofilaments; p.i., primary immunization; i.p., injected intraperitoneally;

Declarations

Ethics approval and consent to participate

This study was carried out in accordance with the recommendations of the National Institutes of Health Guide for the Care and Use Laboratory Animals. The protocol was approved by the Institutional Animal Care and Use Committee of Zhengzhou University (2019-KY–142).

Consent to publish

Not Applicable

Availability of data and materials

The datasets used and/or analyzed during the current study are available from the corresponding author on reasonable request.

Competing interests

The authors declare that that they have no conflicts of interest.

Funding

This study was supported by the National Natural Science Foundation of China (no. 31870334) and the Province Natural Science Foundation of Henan (no. 182300410330)

Authors' Contributions

JK and SQL have drafted the article and done most of the experimental work.

YFS has helped to design the study, participated the experiment and revised the article.

YJC has participated the experiment.

YMS has helped with interpretation of data.

FYZ, HYW and LZ mainly designed, support and supervised the entire work.

Acknowledgments

The authors thank Dr. Guang-Xian Zhang for critiques and Ms. Katherine Regan, Department of Neurology, Thomas Jefferson University, USA, for editorial assistance.

References

1.Jenna M. Gaesser, Sharyl L. Fyffe-Maricich. Intracellular signaling pathway regulation of myelination and remyelination in the CNS. Exp Neurol. 2016;283(Pt B):501–11.

2.Khalaj AJ, Hasselmann J, Augello C, Moore S, Tiwari-Woodruff SK. Nudging oligodendrocyte intrinsic signaling to remyelinate and repair: Estrogen receptor ligand effects. J Steroid Biochem Mol Biol. 2016;160:43–52.

3.Madill M, Fitzgerald D, O'Connell KE, Dev KK, Shen S, FitzGerald U. In vitro and ex vivo models of multiple sclerosis. Drug Discov Today. 2016;21(9):1504–11.

4.Kan QC, Pan QX, Zhang XJ, Chu YJ, Liu N, Lv P, et al. Matrine ameliorates experimental autoimmune encephalomyelitis by modulating chemokines and their receptors. Exp Mol Pathol. 2015;99(2):212–9.

5.Knier B, Rothhammer V, Heink S, Puk O, Graw J, Hemmer B, et al. Neutralizing IL–17 protects the optic nerve from autoimmune pathology and prevents retinal nerve fiber layer atrophy during experimental autoimmune encephalomyelitis. J Autoimmun. 2015;56:34–44.

6.Horstmann L, Kuehn S, Pedreiturria X, Haak K, Pfarrer C, Dick HB, et al. Microglia response in retina and optic nerve in chronic experimental autoimmune encephalomyelitis. J Neuroimmunol. 2016;298:32–41.

7.Amezcua L, Beecham AH, Delgado SR, Chinea A, Burnett M, Manrique CP, et al. Native ancestry is associated with optic neuritis and age of onset in hispanics with multiple sclerosis. Ann Clin Transl Neur. 2018;5(11):1362–71.

8.Quinn TA, Dutt M, Shindler KS. Optic neuritis and retinal ganglion cell loss in a chronic murine model of multiple sclerosis. Front Neurol. 2011;2:50.

9.Khan RS, Dine K, Luna E, Ahlem C, Shindler KS. HE3286 reduces axonal loss and preserves retinal ganglion cell function in experimental optic neuritis. Invest Ophthalmol Vis Sci. 2014;55(9):5744–51.

10.Syc SB, Saidha S, Newsome SD, Ratchford JN, Levy M, Ford E, et al. Optical coherence tomography segmentation reveals ganglion cell layer pathology after optic neuritis. Brain. 2012;135(Pt 2):521–33.

11.Horstmann L, Schmid H, Heinen AP, Kurschus FC, Dick HB, Joachim SC. Inflammatory demyelination induces glia alterations and ganglion cell loss in the retina of an experimental autoimmune encephalomyelitis model. J Neuroinflammation. 2013;10:120.

12.Shindler KS, Ventura E, Dutt M, Rostami A. Inflammatory demyelination induces axonal injury and retinal ganglion cell apoptosis in experimental optic neuritis. Exp Eye Res. 2008;87(3):208–13.

13.Dal Monte M, Cammalleri M, Locri F, Amato R, Marsili S, Rusciano D, et al. Fatty Acids Dietary Supplements Exert Anti-Inflammatory Action and Limit Ganglion Cell Degeneration in the Retina of the EAE Mouse Model of Multiple Sclerosis. Nutrients. 2018;10(3).

14.Zhu L, Pan QX, Zhang XJ, Xu YM, Chu YJ, Liu N, et al. Protective effects of matrine on experimental autoimmune encephalomyelitis via regulation of ProNGF and NGF signaling. Exp Mol Pathol. 2016;100(2):337–43.

15.Kan QC, Zhang HJ, Zhang Y, Li X, Xu YM, Thome R, et al. Matrine Treatment Blocks NogoA-Induced Neural Inhibitory Signaling Pathway in Ongoing Experimental Autoimmune Encephalomyelitis. Mol Neurobiol. 2017;54(10):8404–18.

16.Wang CY, Bai XY, Wang CH. Traditional Chinese medicine: a treasured natural resource of anticancer drug research and development. Am J Chin Med. 2014;42(3):543–59.

17.Yu J, Yang S, Wang X, Gan R. Matrine improved the function of heart failure in rats via inhibiting apoptosis and blocking beta3adrenoreceptor/endothelial nitric oxide synthase pathway. Mol Med Rep. 2014;10(6):3199–204.

18.Kan QC, Zhu L, Liu N, Zhang GX. Matrine suppresses expression of adhesion molecules and chemokines as a mechanism underlying its therapeutic effect in CNS autoimmunity. Immunol Res. 2013;56(1):189–96.

19.Liu N, Kan QC, Zhang XJ, Xv YM, Zhang S, Zhang GX, et al. Upregulation of immunomodulatory molecules by matrine treatment in experimental autoimmune encephalomyelitis. Exp Mol Pathol. 2014;97(3):470–6.

20.Jokubaitis VG, Gresle MM, Kemper DA, Doherty W, Perreau VM, Cipriani TL, et al. Endogenously regulated Dab2 worsens inflammatory injury in experimental autoimmune encephalomyelitis. Acta Neuropathol Com. 2013;1:32.

21.Shindler KS, Guan Y, Ventura E, Bennett J, Rostami A. Retinal ganglion cell loss induced by acute optic neuritis in a relapsing model of multiple sclerosis. Mult Scler. 2006;12(5):526–32.

22.Jung KI, Kim EK, Park CK. Usefulness of frequency doubling technology perimetry 24–2 in glaucoma with parafoveal scotoma. Medicine (Baltimore). 2017;96(24):e6855.

23.Khan RS, Dine K, Das Sarma J, Shindler KS. SIRT1 activating compounds reduce oxidative stress mediated neuronal loss in viral induced CNS demyelinating disease. Acta Neuropathol Commun. 2014;2:3.

24.Soelberg K, Specovius S, Zimmermann HG, Grauslund J, Mehlsen JJ, Olesen C, et al. Optical coherence tomography in acute optic neuritis: A population-based study. Acta Neurol Scand. 2018;138(6):566–73.

25.Mayer C, Bruehl C, Salt EL, Diem R, Draguhn A, Fairless R. Selective Vulnerability of alphaOFF Retinal Ganglion Cells during Onset of Autoimmune Optic Neuritis. Neuroscience. 2018;393:258–72.

26.Liu SQ, Zhang ML, Zhang HJ, Liu FZ, Chu RJ, Zhang GX, et al. Matrine promotes oligodendrocyte development in CNS autoimmunity through the PI3K/Akt signaling pathway. Life Sci. 2017;180:36–41.

27.Kan QC, Lv P, Zhang XJ, Xu YM, Zhang GX, Zhu L. Matrine protects neuro-axon from CNS inflammation-induced injury. Exp Mol Pathol. 2015;98(1):124–30.

28.Yang H, Liu C, Jiang J, Wang Y, Zhang X. Celastrol Attenuates Multiple Sclerosis and Optic Neuritis in an Experimental Autoimmune Encephalomyelitis Model. Front Pharmacol. 2017;8:44.

29.Stojic A, Bojcevski J, Williams SK, Bas-Orth C, Nessler S, Linington C, et al. Preclinical stress originates in the rat optic nerve head during development of autoimmune optic neuritis. Glia. 2018;67(3):512–24.

30.Matsunaga Y, Kezuka T, An X, Fujita K, Matsuyama N, Matsuda R, et al. Visual functional and histopathological correlation in experimental autoimmune optic neuritis. Invest Ophthalmol Vis Sci. 2012;53(11):6964–71.

31.Kornek B, Storch MK, Weissert R, Wallstroem E, Stefferl A, Olsson T, et al. Multiple sclerosis and chronic autoimmune encephalomyelitis: a comparative quantitative study of axonal injury in active, inactive, and remyelinated lesions. Am J Pathol. 2000;157(1):267–76.

32.Zhang CJ, Jiang M, Zhou H, Liu W, Wang C, Kang Z, et al. TLR-stimulated IRAKM activates caspase–8 inflammasome in microglia and promotes neuroinflammation. J Clin Invest. 2018;128(12):5399–412.

33.Chen GC, Tang LS, Wei W, Li Z, Li YP, Duan XC, et al. mTOR regulates neuroprotective effect of immunized CD4+Foxp3+T cells in optic nerve ischemia. Sci Rep-Uk. 2016;6:37805.

34.Zeka B, Hastermann M, Hochmeister S, Kogl N, Kaufmann N, Schanda K, et al. Highly encephalitogenic aquaporin 4-specific T cells and NMO-IgG jointly orchestrate lesion location and tissue damage in the CNS. Acta Neuropathol. 2015;130(6):783–98.

35.Das A, Guyton MK, Smith A, Wallace G, McDowell ML, Matzelle DD, et al. Calpain inhibitor attenuated optic nerve damage in acute optic neuritis in rats. J Neurochem. 2013;124(1):133–46.

36.Xu YX, Lin HZ, Zheng WJ, Ye XH, Yu LF, Zhuang JQ, et al. Matrine ameliorates adriamycin-induced nephropathy in rats by enhancing renal function and modulating Th17/Treg balance. Eur J Pharmacol. 2016;791:491–501.

37.An LH, Li GZ, Si JL, Zhang CL, Han XY, Wang SO, et al. Acrylamide Retards the Slow Axonal Transport of Neurofilaments in Rat Cultured Dorsal Root Ganglia Neurons and the Corresponding Mechanisms. Neurochem Res. 2016;41(5):1000–9.

38.Talla V, Yang C, Shaw G, Porciatti V, Koilkonda RD, Guy J. Noninvasive assessments of optic nerve neurodegeneration in transgenic mice with isolated optic neuritis. Invest Ophthalmol Vis Sci. 2013;54(7):4440–50.

39.Costello F, Coupland S, Hodge W, Lorello GR, Koroluk J, Pan YI, et al. Quantifying axonal loss after optic neuritis with optical coherence tomography. Ann Neurol. 2006;59(6):963–9.

40.Neil S, Huh J, Baronas V, Li X, McFarland HF, Cherukuri M, et al. Oral administration of the nitroxide radical TEMPOL exhibits immunomodulatory and therapeutic properties in multiple sclerosis models. Brain Behav Immun. 2017;62:332–43.

41.Das A, Guyton MK, Smith A, Wallace Gt, McDowell ML, Matzelle DD, et al. Calpain inhibitor attenuated optic nerve damage in acute optic neuritis in rats. J Neurochem. 2013;124(1):133–46.

42.Brambilla R, Dvoriantchikova G, Barakat D, Ivanov D, Bethea JR, Shestopalov VI. Transgenic inhibition of astroglial NF-kappaB protects from optic nerve damage and retinal ganglion cell loss in experimental optic neuritis. J Neuroinflammation. 2012;9:213.

Figures

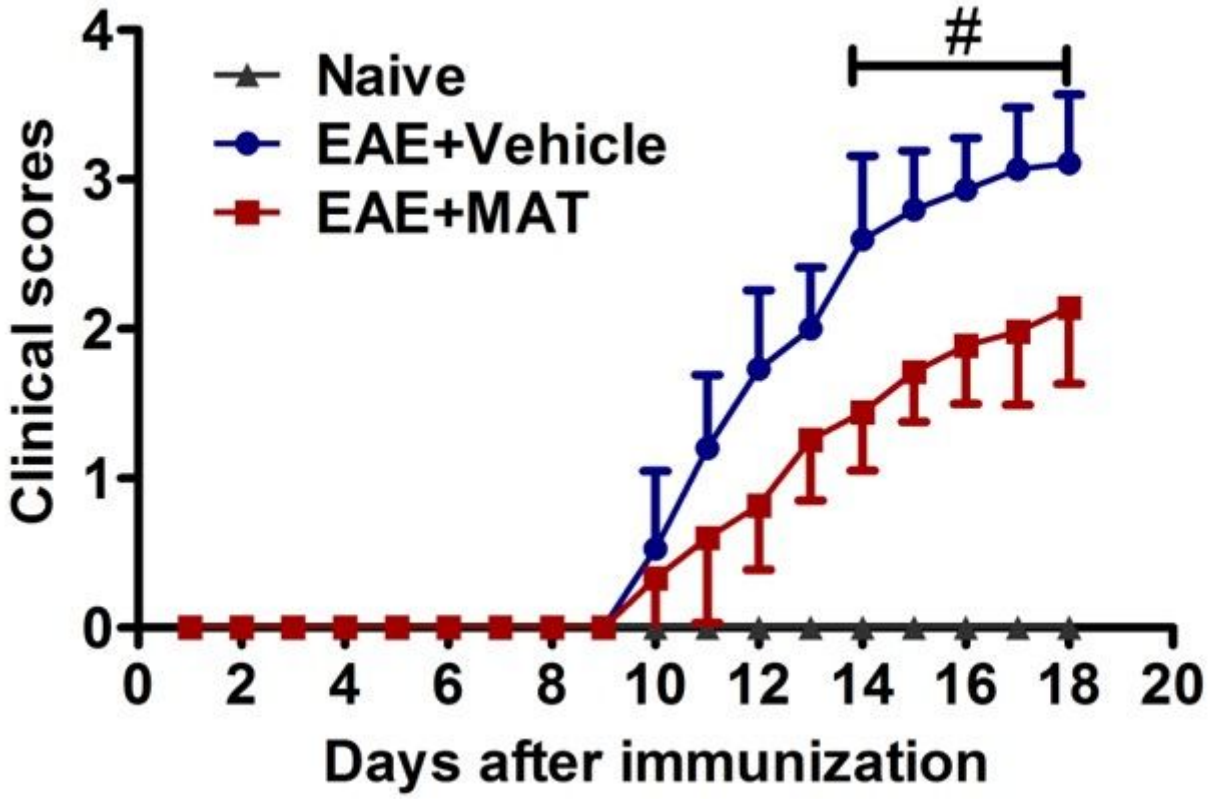

Figure 1

MAT ameliorates clinical signs of EAE. Wistar rats were immunized with spinal cord homogenate of guinea pig in CFA. Rats received MAT (250 mg/kg/daily, i.p.) at onset of clinical signs of EAE until day 18 after p.i., and control rats received the same volume of saline. All rats were evaluated daily for clinical scores of EAE in a blinded fashion from day 0 to 18 after p.i. Clinical score - time graph of every group based on a 0–5 scale. Clinical signs begin to appear at day 10 after p.i., and peaked at day 17 after p.i. Data represent mean ± SD (n = 10 rats per group). #$p < 0.05$, comparisons between vehicle- and MAT-treated groups.

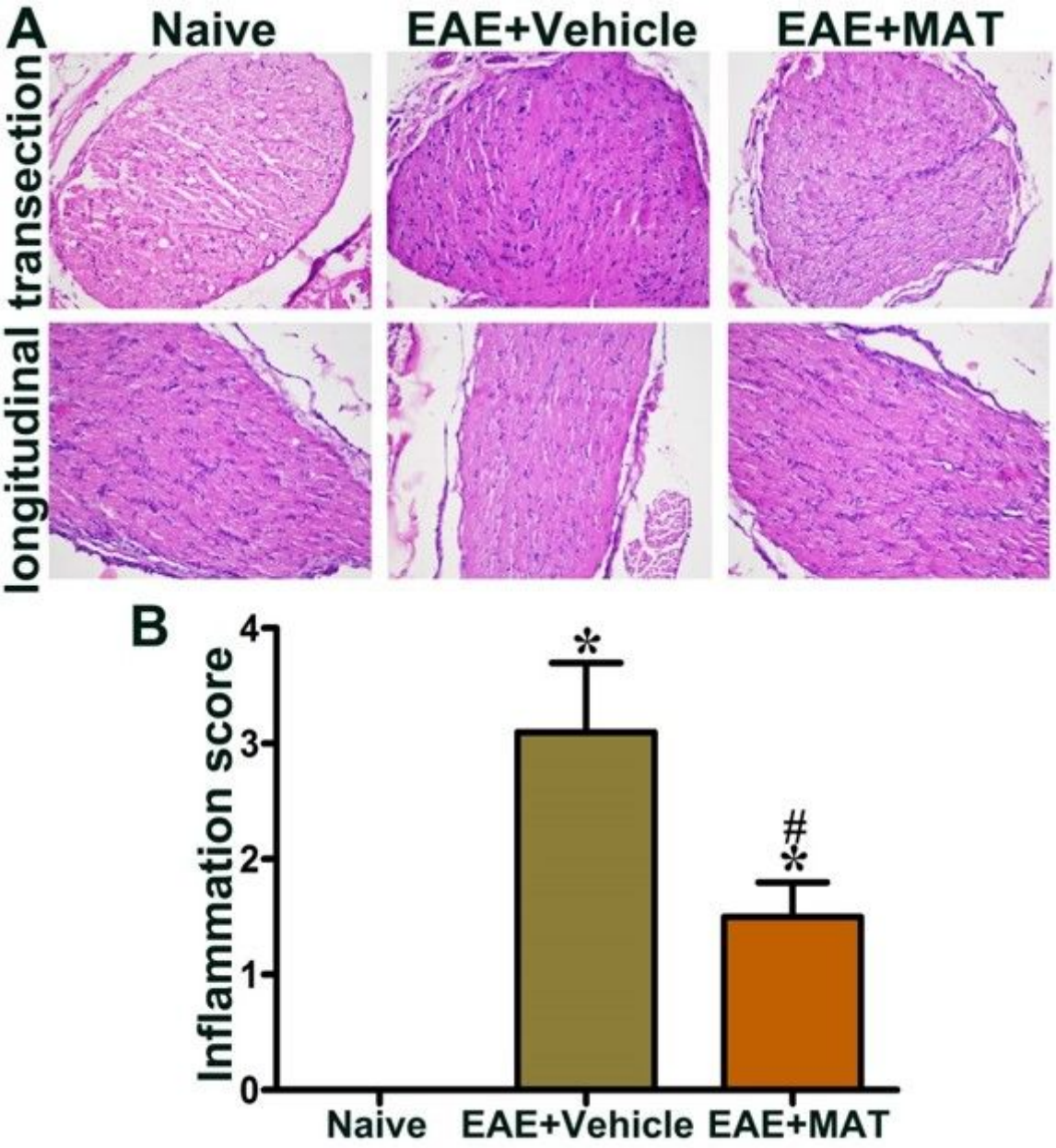

Figure 2

MAT attenuates the severity of optic nerve inflammation. (A) Rats described in Fig. 1 were euthanized and optic nerves were isolated and stained by H&E in transverse (upper row) and longitudinal (lower row) sections of optic nerves. Images were collected under bright-field setting using ×200 (HE) objective. (B) Degree of inflammatory cell infiltration in optic nerves. All results are expressed as mean ± SD (n = 10 each group). *p<0.05, comparisons with the naive group. #p<0.05, comparisons between vehicle- and MAT-treated groups.

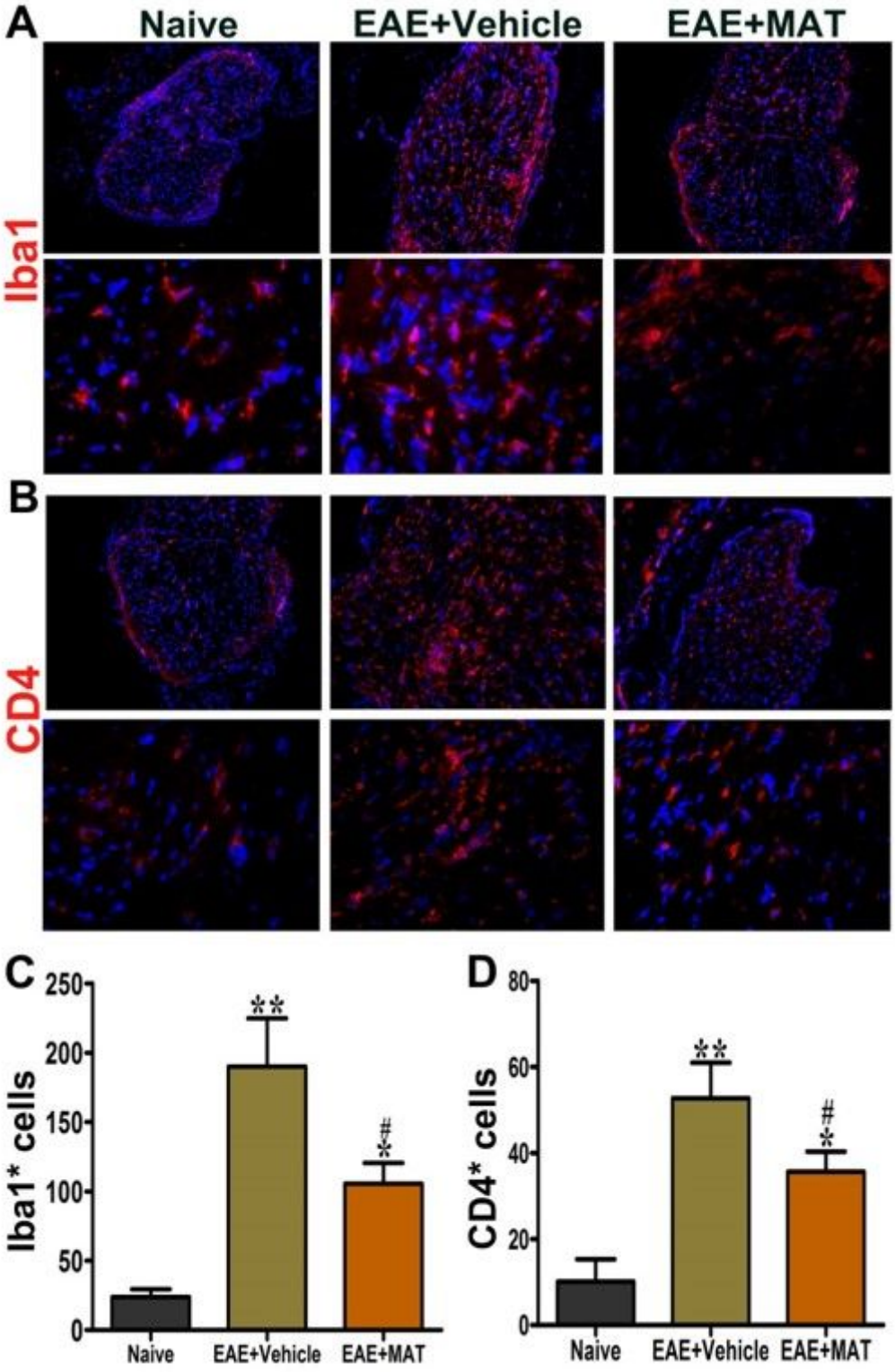

Figure 3

MAT treatment reduces numbers of Iba1+ and CD4+ cells in optic neuritis. Optic nerves were harvested from rats described in Fig. 1 at day 18 after p.i. Immunofluorescence staining for Iba1+ (A) and CD4+ (B) in optic nerve sections at x200 (upper row) and ×400 (lower row) magnifications. Quantitative analyses of numbers of Iba1+ cells (C) and CD4+ (D) cells. Data are expressed as mean ± SD (n = 10 each group).

*p<0.05, **p<0.01, comparison with the naive group. #p<0.05, comparisons between vehicle- and MAT-treated groups.

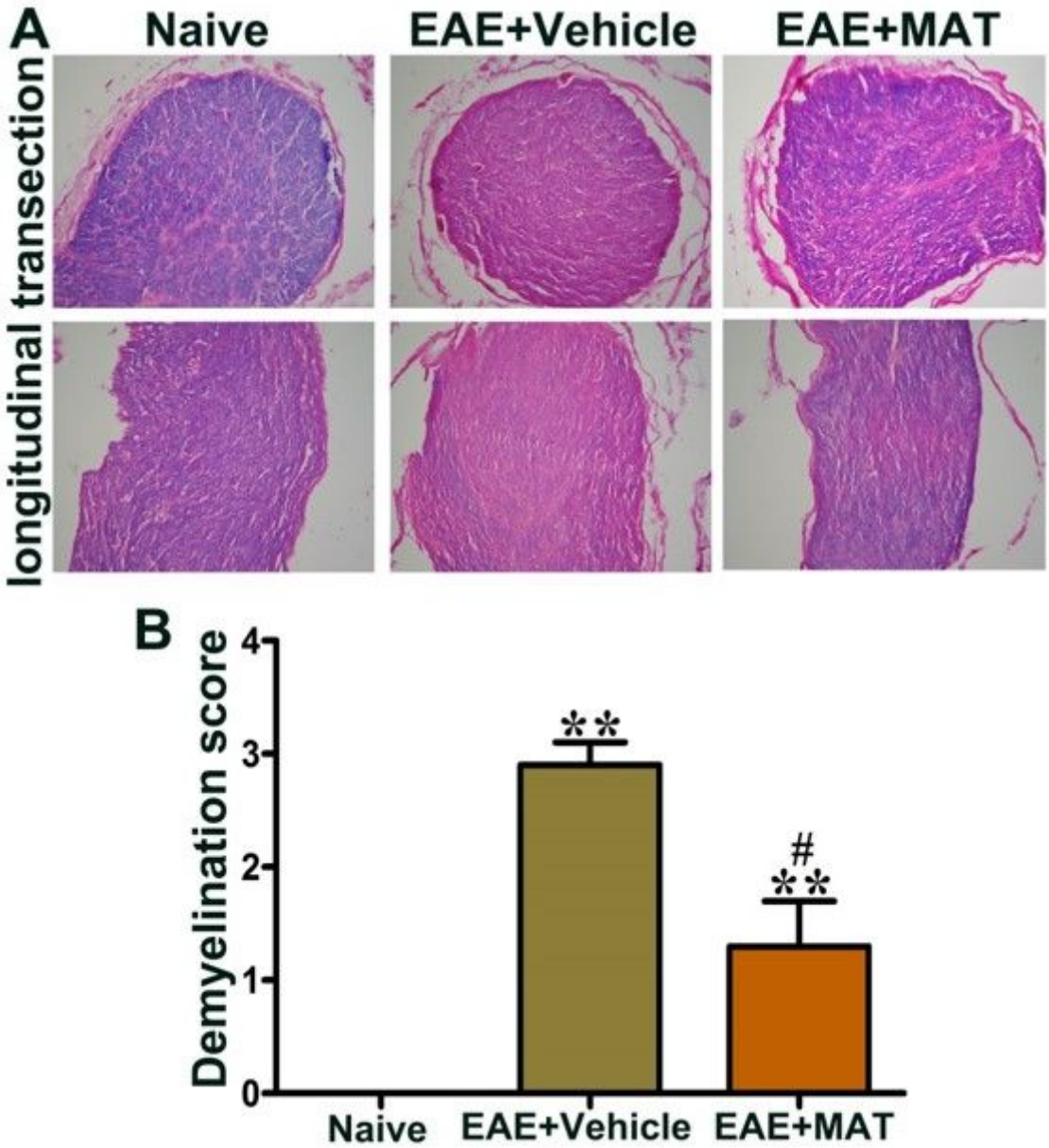

Figure 4

MAT attenuates demyelination in the optic nerve. (A) To confirm whether MAT can protect the optic nerve from demyelination, this nerve was isolated from rats in Fig. 1 and stained with Luxol fast blue (LFB), which stains myelin. (A) Luxol fast blue (FLB) staining for demyelination was performed. (B) Mean scores of demyelination. Data represent mean ± SD (n = 10 each group). **p<0.01, comparisons with the naive group. #p<0.05, comparisons between vehicle- and MAT-treated groups.

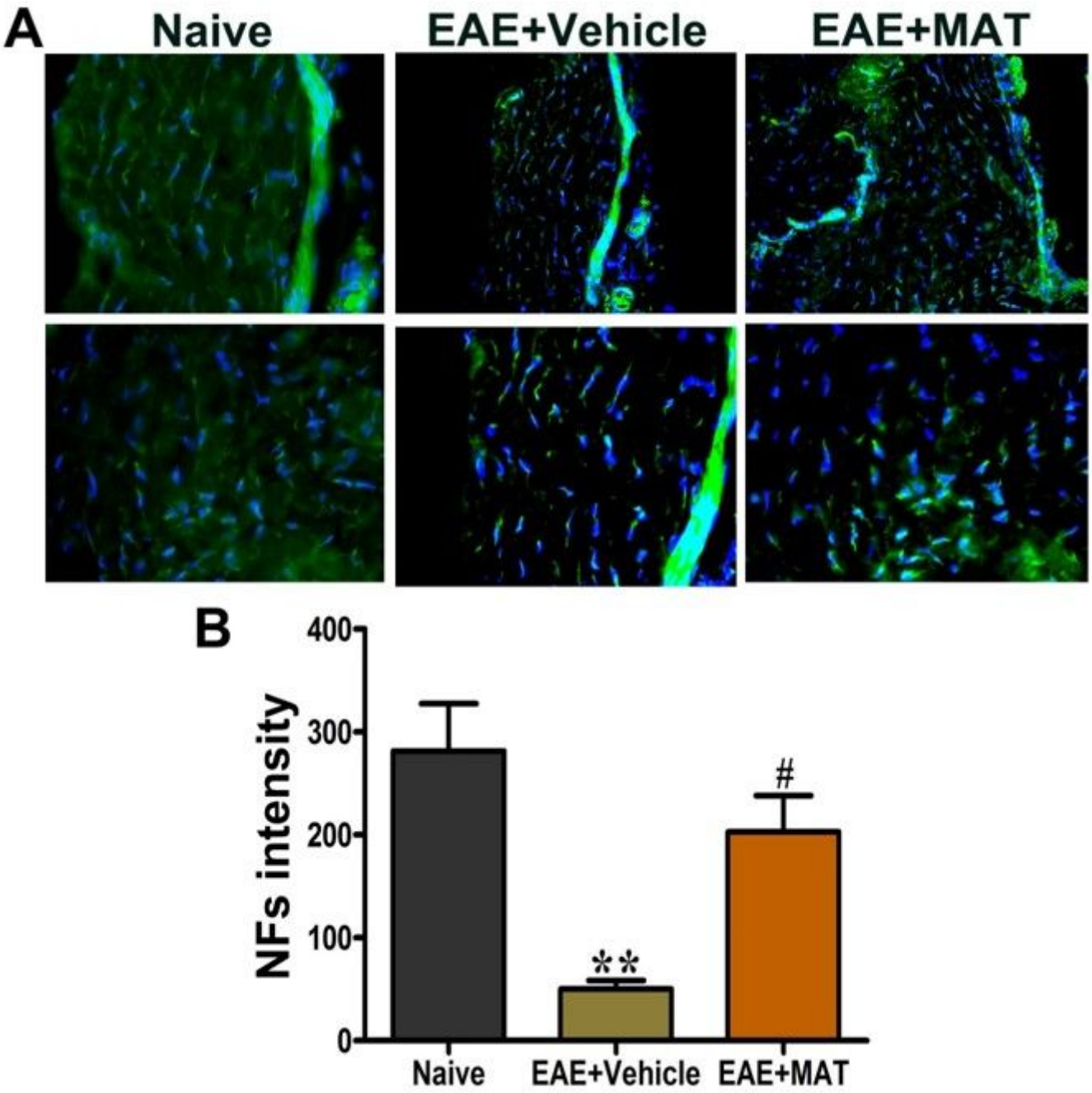

Figure 5

Effects of MAT on axonal loss in optic nerve. Optic nerves were harvested from naive and MAT- or vehicle-treated rats. (A) Detection of NF by immunofluorescence staining in optic nerve at x200 (upper row) and ×400 (lower row) magnifications. (B) Quantitative analyses of immunofluorescence were expressed by average optical density (AOD) of NFs. Data represent mean ± SD (n = 10 each group). **$p<0.01$, comparisons with the naive group. #$p<0.05$, comparisons between vehicle- and MAT-treated groups.

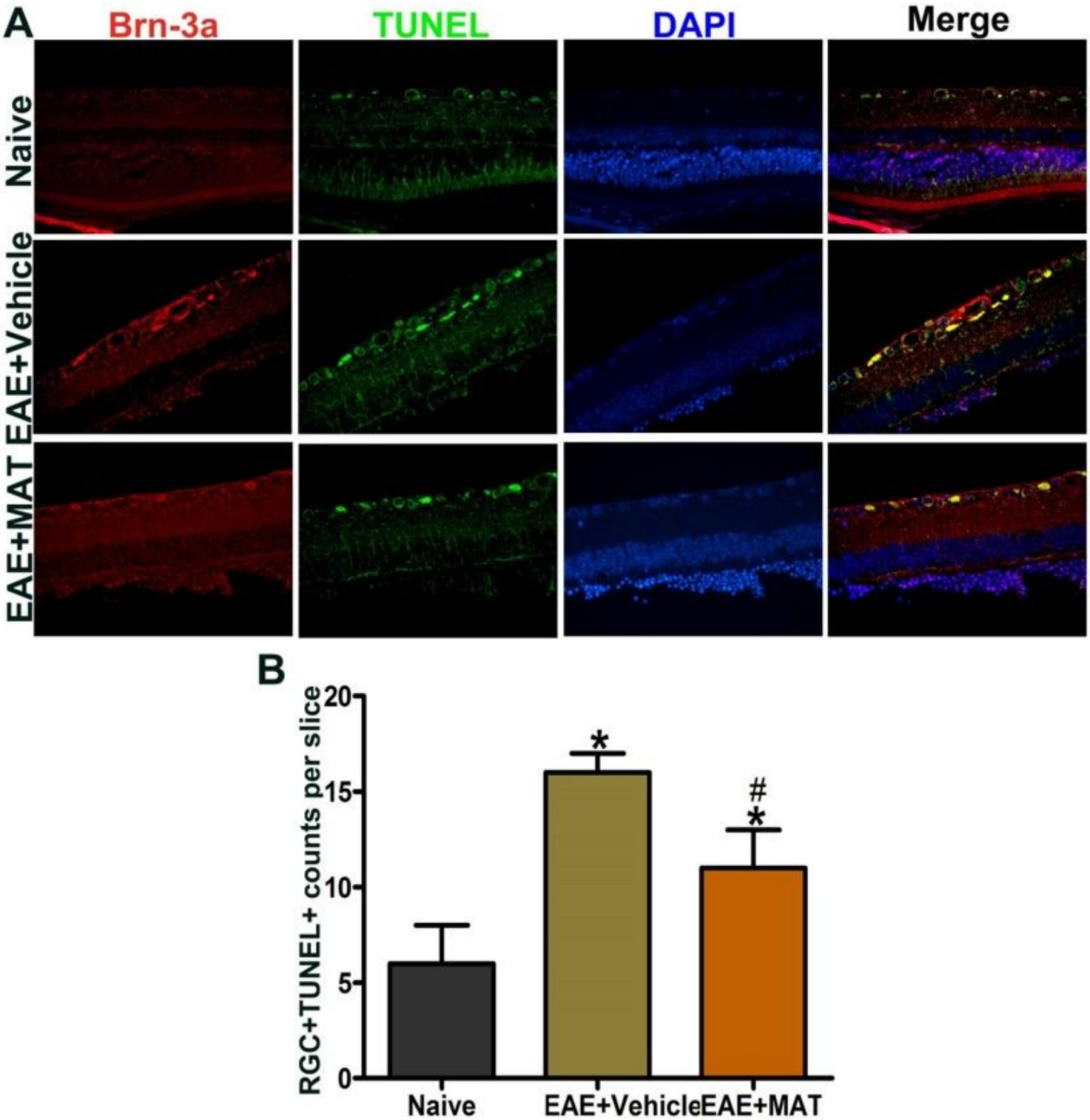

Figure 6

MAT treatment protects RGCs from apoptosis. Neuroprotective effects of MAT were evaluated by counting RGCs immune-labeled with Brn3a antibody and estimated the number of RGC deaths through TUNEL. (A) RGCs in the temporal retina were examined by immunofluorescent double staining by anti-Brn3a (red) and TUNEL (green), and all cells were co-stained with DAPI (blue). Magnifications of upper row: x200; lower row: x400. (B) Quantitative analyses of immunofluorescence are expressed by average

optical density (AOD) of TUNEL+ RGCs. Symbols represent mean ± SD; n = 10 rats per group. **p<0.01, comparisons with the naive group. #p<0.05, comparisons between vehicle- and MAT-treated groups.

Supplementary Files

This is a list of supplementary files associated with this preprint. Click to download.

- supplement1.pdf