

# Risk factors for implant failure of proximal femoral nail anti-rotation (PFNA –II) in the treatment of intertrochanteric fractures (AO/OTA 31 A1 and A2)

**Shaobo Nie**

Chinese PLA General Hospital

**Hui Ji**

Chinese PLA General Hospital

**ming li**

Chinese PLA General Hospital

**di yang**

Chinese PLA General Hospital

**Yeqing Qi**

Chinese PLA General Hospital

**mingxing lei**

Chinese PLA General Hospital

**peifu tang**

Chinese PLA General Hospital

**zhuo zhang**

Chinese PLA General Hospital

**Licheng Zhang** (✉ [zhanglicheng218@126.com](mailto:zhanglicheng218@126.com))

Chinese PLA General Hospital

---

## Research article

**Keywords:** intertrochanteric fracture, proximal femoral nail anti-rotation, implant failure, risk factor, reduction quality

**Posted Date:** July 14th, 2020

**DOI:** <https://doi.org/10.21203/rs.3.rs-41298/v1>

**License:**   This work is licensed under a Creative Commons Attribution 4.0 International License.

[Read Full License](#)

---

# Abstract

## Background

Intertrochanteric fracture is associated with severe morbidity and mortality. The results of postoperative implant failure are catastrophic. The aim of this study was to determine risk factors for implant failure in intertrochanteric fractures treated with proximal femoral nail anti-rotation (PFNA-II) through the assessment of early therapeutic effects.

## Methods

A single-center retrospective study was conducted on a continuous series of 123 intertrochanteric fracture patients treated with PFNA-II between Dec 2018 and Oct 2019. Perioperative medical and imaging data were collected. The patients were divided into two groups according to whether implant failure or not. The differences in reduction quality, nail length and tip apex distance (TAD) were analyzed to determine the risk factors of implant failure.

## Results

A total of 80 patients were enrolled, with an average age of 80.2 years old. There were 6 patients with implant failure. There was no significant difference in demographic index between the two groups. The reduction quality of failure group was good, accept and poor with each 2 patients, and that of the non-failure group was 35, 35 and 4 patients respectively. The difference of reduction quality between the two groups was statistically significant. The risk of postoperative implant failure in patients with poor reduction quality was 8.75 times that of patients with good and acceptable reduction from the Logistic regression analysis (OR = 8.75, 95% CI 1.215–62.99). The differences in nail length, ASA and bone quality were not statistically significant.

## Conclusion

Reduction quality is a risk factor of implant failure in intertrochanteric fractures treated with PFNA-II. Even if the medial femoral cortex is anatomically reduced, there will be a triangular void area between the nail and the medial femur, which are prone to coxa vara and implant failure. Therefore, good reduction is the key to treat intertrochanteric fracture.

## Introduction

Intertrochanteric fractures are common in the elderly population with an incidence of 0.1%<sup>1,2</sup>. They are characterized by the high disability and high mortality, with a one-year mortality rate as high as 36%<sup>3</sup>.

Surgical treatment especially intramedullary nailing has been the common treatment method due to the central fixation, less postoperative pain, and earlier recovery of mobilization<sup>4,5</sup>. Page et al.<sup>6</sup> reported that the rate of intramedullary nailing in intertrochanteric fracture has increased from 3.8% in 2011 to 57.6% in 2015.

At present, proximal femoral nail anti-rotation (PFNA-II) has become the main implant in the treatment of intertrochanteric fractures<sup>7</sup>. However, with the widespread use of intramedullary nails, the failure rate increases to as high as 13.3%~20.5%<sup>8,9</sup>. Salvage procedures are invariably challenging and expose a population to further complex surgery<sup>10</sup>. Given the gravity of the event, it is important to determine risk factors which contribute to and are associated with implant failure. Kraus et al.<sup>11</sup> reported that tip-apex-distance (TAD) greater than 30 mm was the main risk factor. Turgut et al.<sup>12</sup> believed that if the coxa vara cannot be corrected, the lag screw will be in a unfavorable position. Even if the TAD is small, implant failure may be inevitable. Imeric et al.<sup>13</sup> found that PFNA-II showed significantly higher failure rate in reverse intertrochanteric fractures. Hao et al.<sup>8</sup> reported that poor reduction quality and loss of posteromedial support are predictors of implant failure in reverse oblique and transverse intertrochanteric fractures treated with PFNA. Whereas, the risk factors for PFNA-II failure are still controversial. Moreover, the length less than 240 mm of PFNA-II are commonly used in Asia, but there was rarely reported the risk factors of short PFNA-II failures. Hence, in this study, a group of intertrochanteric fracture stabilized with short PFNA-II has been chosen for explored the risk factor of the implant failure. It may predict which patients might suffer a complication and guide surgeons in preventing the implant failure in the patients with intertrochanteric fracture treated with PFNA-II.

## Methods And Materials

### Subjects

There were 123 patients with intertrochanteric fractures underwent surgery in our trauma center, including 43 males and 80 females (male: female=1:1.9), with the mean age of 76 years (from 20 to 97) from Dec 2018 to Oct 2019. Inclusion criteria (1) Patients diagnosed by X-ray or Computed Tomography (CT) with intertrochanteric fracture (AO/OTA 31 A1 and A2). (2) Patients older than 55. (3) Stabilized with short PFNA-II (nail length less than 240 mm). Exclusion criteria (1) Stabilized with plate or external fixator. (2) Combined with femoral neck fracture, subtrochanteric fracture or femoral shaft fractures. (3) patients were not treated with PFNA-II, or PFNA-II length was over 240 mm. (4) Pathological fractures, metabolic bone diseases. (5) Death during follow-up or incomplete follow-up. (6) Patients who are undergoing chemotherapy or radiation, receiving corticosteroids or growth factors for therapy. The research flow chart is shown in Figure 1.

### Operation procedure

The patients were lies on a fluoroscopic surgical traction table in supine position after anesthesia (nerve block anesthesia is mostly selected to reduce the impact on cardiopulmonary function). First, the closed

reduction was carried out by traction. The fracture site was relieved by abduction and external rotation. Secondary, under traction, the affected limb was adduction and intorsion at the same time until the foot was slightly adduction and intorsion. The reduction quality was checked by fluoroscopy. The disinfection and draping were made after reduction quality was accepted. PFNA-II was implanted into the femur according to the operation procedure provided by the manufacturer. If the reduction quality is poor, additional small incision assisted reduction by instrument. Suture the deep fascia and skin without drainage after intramedullary nailing.

## Data Collection

General demographic data of patients were collected from medical record, including gender, age and so on. Image data were extracted from the imaging browsing system of the trauma center. The image data were analyzed by two experienced attending surgeon and the data was adopted when they agree with each other. Discrepancies were resolved by the chief surgeon.

The preoperative evaluation was evaluated by the American Society of Anesthesiologists (ASA) score, and bone quality was evaluated by the Singh index of the contralateral hip<sup>14</sup>. The fracture type was described by AO classification<sup>15</sup>. The reduction quality adopts the standard proposed by Baumgaertner et al.<sup>16</sup> The caput-collum-diaphysis angle was normal or slightly varus in the anterior and posterior position of X-ray or the angle of fracture site on lateral radiography is not more than 20°. The distance between fracture fragment is less than 4 mm. It is defined as good when the both conditions can be reached, accept when one condition can be reached and poor with none condition can be reached. The imaging standard of fracture union<sup>17</sup> was defined as the blur of fracture line on the X-ray plain film, and the continuous callus passing through at least three cortical bone of the fracture site. The implant failure<sup>18</sup> defined as that: lag screw cut out, coxa vara (The caput-collum-diaphysis angle less than 5° above the contralateral hip) or nonunion, implant broken, periprosthetic fracture without high energy damage.

## Assignment Definitions

For risk factor analysis, age, BMI, Singh index, reduction quality, ASA index and TAD were classified and assigned values (Table 1).

## Statistical analysis

Statistical analysis was performed with SPSS for windows software (Ver.22.0, SPSS, Chicago, USA). The continuous parameters were expressed by mean with standard deviation (mean  $\pm$  SD), and it was analysis by t test. The categorical parameters was expressed by percentage and it was analysis by  $\chi^2$  test. Analysis of risk factors were evaluated by logistic regression, and odds ratios (ORs) with their 95% confidence intervals (CIs) were also obtained.  $P < 0.05$  was defined as significant in all tests.

## Results

There were 80 patients met the inclusion criteria with 27 males (33.3%) and 53 females (66.7%). Average age of those patients was 80.2 years (range from 55-93) and the mean follow-up time was 12.3 months (range from 8 to 19). There were 37 patients with the left hip fracture and 43 for right. Implant failure occurred in 6 patients (7.5%). According to implant failure, the patients were divided into implant failure group and non-failure group. The general conditions of the two groups are shown in table2. There was no significant difference in demographic data between two groups, so the baseline characteristics were the same.

In implant failure group, there were 2 cases of A1 type intertrochanteric fractures and while 4 of A2 type, 4 case of nail length were 200 mm and 2 of 240 mm, the difference of fracture type and nail length between the two groups was no statistically significant ( $p>0.05$ ). The implant failure rate was 5.7% in patients with good and acceptable reduction quality and 33.3% in patients with poor reduction. The difference between the two groups was statistically significant ( $p<0.05$ ). The TAD was  $18.3\pm 6.1$  mm in failure group and  $22.3\pm 6.3$  mm in non-failure group. In term of hospital stay, the failure group was  $10.3\pm 3.3$  days and the non-failure group was  $8.9\pm 3.2$  days. The difference of TAD and hospital stay between the two groups was no statistically significant. The perioperative data of the two groups are shown in Table 3.

The reduction quality was the independent risk factor of implant failure through logistic regression analysis of multiple factors ( $p<0.05$ ). It was found in table 3 that the incidence of implant failure of patients with poor reduction quality was 8.75 times higher than that of patients with good and acceptable reduction (table 4).

The failure of internal fixation revealed that three patients had cut out, one patient had the periprosthetic fracture, two patients had slight coxa vara after reduction and lead to nonunion during the process of weight bearing. Among the patients with implant failure, we found that four patients have been not reconstructed the medial femoral support, two patients showed good reduction at first in postoperative X-ray but then they were found the reduction loss, hip varus and cut out of helical blade during the follow-up. In order to clarify the causes of implant failure, we conducted further analysis of postoperative X-ray and classified three typical types of fixation effect in all patients. There was cortical support type (Fig 2), the helical blade support type (Fig 3) and the nail support type (Fig 4).

## Discussion

PFNA-II has been the mainly method for the treatment of intertrochanteric fractures due to its advantages of short operative time and less bleeding<sup>19</sup>. AO/OTA 31-A1 and A2 accounted for 80%-94.7%<sup>20</sup> of all intertrochanteric fractures. The fracture line distribution of A1 and A2 is different from that of the reverse intertrochanteric fractures (A3), and the implant failure mechanism is also different with each other<sup>21</sup>. Many studies have not analyzed these two types of intertrochanteric fractures separately<sup>22</sup>, which may lead to different results. For patients with A1 and A2, PFNA-II with nail length less than 240 mm is generally recommended<sup>23</sup>. Therefore, A1 and A2 intertrochanteric fractures stabilized with short PFNA-II

(nail length less than 240 mm) is the most common clinical case. It is important to determine the risk factors of implant failure for guiding intertrochanteric fractures treatment.

In this study, the difference of reduction quality between the failure group and the non-failure group was statistically significant and the incidence of implant failure in failure group was higher than that in non-failure group. This may be suggested that reduction quality and implant failure were directly related. Morvan A et al.<sup>24</sup> retrospective analyzed 228 patients aged over 75 years operated by Gamma 3 and Dynamic hip screw (DHS). Cut-out rate was 0.89% in good reduction and 12.12% in poor reduction. To minimize mechanical complications, great attention should be paid to fracture reduction and lag-screw position. The same results found in De Bruijn's study<sup>25</sup>. In our study, reduction quality is risk factor of implant failure in intertrochanteric fracture treated with short PFNA-II. Implant failure rate was 33.3% in poor reduction and 4.5% in good and acceptable reduction. In multivariate analysis, the risk of implant failure in poor reduction was 8.75 times higher than that in good and acceptable reduction (OR = 8.75, 95%CI 1.215–62.99, p = 0.0313).

According to the postoperative X-rays, the medial femoral cortex was discontinuous in 66.7% of the patients with implant failure in this study. Posterior medial support is considered to be an important factor affecting the stability of intertrochanteric fractures, which has been confirmed in both basic and clinical studies. Do et al.<sup>26</sup> reported that fixation strength was approximately 5 times greater in small defect of femoral medial cortex than in large defect of femoral medial cortex. Nie et al.<sup>27</sup> confirmed by biomechanics that medial reconstruction is more important than lateral wall reconstruction. Similar findings have been found in clinical research. Mariani et al.<sup>28</sup> analyzed 20 patients with nonunion of intertrochanteric fractures and found that all of them were unstable fractures and the reason of implant failure was related to posterior medial comminuted. In this study, 66.7% of the patients with implant failure had poor medial reconstruction suggested that medial reconstruction is a keystone of intertrochanteric fractures (A1 and A2) treated with short PFNA-II.

Even if the continuity of the femoral medial cortex is restored, the implant failure such as cut out may still occur during the weight bearing. Our previous study proposed the concepts of secondary stability and cortical or implant support<sup>29</sup>. In this study, we confirmed this phenomenon (Fig. 1 to 3). If the medial femoral shaft cortex or helical blade forms a support to the medial cortex of the head-neck fragment, the fracture is healed (Figs. 1 and 2). Otherwise, the fracture will result in loss of reduction, secondary stabilization may result in implant support (Fig. 3). According to our team's early research in recent years<sup>30</sup>, most of the anterior cortex of intertrochanteric fracture is simple fracture, so the anterior medial cortex needs to provide stable support. In patients with intertrochanteric fractures, osteoporosis is severe, and the strength of the anterior medial cortex is limited. In Ender's classification<sup>31</sup>, this fracture of varus deformity and retrocurvature proximal fragment impacted into trochanteric spongiosa, leaving a cavity after reduction danger of secondary varus was defined as impacted fractures. In 2013, Gotfried et al.<sup>32</sup> also reported a similar phenomenon and defined it as negative and neutral support. Since then, there have been a lot of relevant reports, but the reasons for the failure of neutral support have not been

explained<sup>33,34</sup>. We found that the compressed area of cancellous bone in the medullary cavity forms a triangular void structure after reduction of head-neck fragment. If the medial femoral cortex fails to provide stable mechanical buttress during the weight bearing, the head-neck fragment is prone to varus again. Hence, we considered this triangular void structure may have a strong association with postoperative implant failure.

There are some limitations in this study. First of all, it was a retrospective study that the data which were not collected initially could not be evaluated. We only included a few common indicators for evaluation. Nonetheless, we have specified strict inclusion and exclusion criteria to reduce confounders and minimize interference with the results. Besides, the sample size is relatively small which may cause statistical bias.

## Conclusion

Reduction quality is a risk factor for implant failure of short PFNA-II in the treatment of Intertrochanteric fractures (OA/OTA 31-A1 and A2). Anatomic reduction and reconstruction of medial femoral support are important means to reduce the implant failure. Even if the reduction is good, there might be still a triangle void area between PFNA-II and medial femoral cortex, which is prone to cause displacement of medial cortex, coxa vara or implant failure.

## Abbreviations

PFNA

proximal femoral nail antirotation.

TAD

tip apex distance.

ASA

American Society of Anesthesiologists

BMI

Body Mass Index

OR

Odds ratio

CI

confidence interval

## Declarations

### Ethical approval and Consent to participate

The study design and conduction complied with the Declaration of Helsinki. It has been reviewed and approved by Ethics Committee. All inclusive subjects have agreed to participate in this study, and signed on the Informed consent.

## **Consent for publication**

Not applicable

## **Availability of data and materials**

The datasets used and analyzed during the current study are available from the corresponding author on reasonable request.

## **Competing interests**

The authors declare that they have no competing interests.

## **Funding**

Not applicable.

## **Authors' contributions**

Nie S: Designed the study, performed the experiments, collected, analyzed, and interpreted the data, drafted and revised the manuscript.

Ji H and Li M: Performed the experiments, collected, analyzed, and interpreted the data, drafted and revised the manuscript.

Hui Ji: Performed the experiments, collected the data, read and approved the final manuscript.

Yang D, Qi Y and Lei M collected and analyzed the data, read and approved the final manuscript.

Tang P: collected the data, read and approved the final manuscript.

Zhang Z and Zhang L: Designed the study, revised the manuscript.

## **Acknowledgements**



## References

1. Ren Y, Hu J, Lu B, et al. Prevalence and risk factors of hip fracture in a middle-aged and older Chinese population. *Bone*. 2019;122:143–149. doi:10.1016/j.bone.2019.02.020
2. Dorotka R, Schoechnner H, Buchinger W. The influence of immediate surgical treatment of proximal femoral fractures on mortality and quality of life: operation within six hours of the fracture versus later than six hours. *J Bone Joint Surg Br* 2003; 85: 1107-13. DOI: 10.1302/0301-620x.85b8.14282
3. Mavrogenis AF, Panagopoulos GN, Megaloikonomos PD, et al. Complications After Hip Nailing for Fractures. *Orthopedics*. 2016 Jan-Feb;39(1):e108-16. DOI: 10.3928/01477447-20151222-11
4. Hoffmann MF, Khoriaty JD, Sietsema DL, et al. Outcome of intramedullary nailing treatment for intertrochanteric femoral fractures. *J Orthop Surg Res*. 2019; 14(1):360. doi: 10.1186/s13018-019-1431-3.
5. Tomás-Hernández J, Núñez-Camarena J, Teixidor-Serra J, et al. Salvage for intramedullary nailing breakage after operative treatment of trochanteric fractures. *Injury*. 2018;49 Suppl 2:S44-S50. doi:10.1016/j.injury.2018.07.018
6. Page PR, Lord R, Jawad A, et al. Changing trends in the management of intertrochanteric hip fractures - A single centre experience. *Injury*. 2016 Jul;47(7):1525-9. doi:10.1016/j.injury.2016.05.002
7. Ma KL, Wang X, Luan FJ, et al. Proximal femoral nails antirotation, Gamma nails, and dynamic hip screws for fixation of intertrochanteric fractures of femur: A meta-analysis. *Orthop Traumatol Surg Res*. 2014; 100 (8):859–866.
8. Hao Y, Zhang Z, Zhou F, et al. Risk factors for implant failure in reverse oblique and transverse intertrochanteric fractures treated with proximal femoral nail antirotation (PFNA). *J Orthop Surg Res*. 2019;14(1):350. doi:10.1186/s13018-019-1414-4
9. Liu W, Zhou D, Liu F, et al. Mechanical complications of intertrochanteric hip fractures treated with trochanteric femoral nails. *J Trauma Acute Care Surg*. 2013; 75 (2):304–310.
10. Johnson NA, Uzoigwe C, Venkatesan M, et al. Risk factors for intramedullary nail breakage in proximal femoral fractures: a 10-year retrospective review. *Ann R Coll Surg Engl*. 2017;99(2):145-150. doi:10.1308/rcsann.2016.0297
11. Kraus M, Krischak G, Wiedmann K, et al. Klinische Evaluation des PFNA® und Zusammenhang zwischen Tip-Apex-Distanz und mechanischem Versagen [Clinical evaluation of PFNA® and relationship between the tip-apex distance and mechanical failure] . *Unfallchirurg*. 2011;114(6):470–478. doi:10.1007/s00113-011-1975-0
12. Turgut A, Kalenderer Ö, Karapınar L, et al. Which factor is most important for occurrence of cutout complications in patients treated with proximal femoral nail antirotation? Retrospective analysis of 298 patients. *Arch Orthop Trauma Surg*. 2016;136(5):623–630. doi:10.1007/s00402-016-2410-3

13. İmerci A, Aydogan NH, Tosun K. A comparison of the InterTan nail and proximal femoral nail antirotation in the treatment of reverse intertrochanteric femoral fractures. *Acta Orthop Belg.* 2018;84(2):123–131.
14. Singh M, Nagrath AR, Maini PS. Changes in trabecular pattern of the upper end of the femur as an index of osteoporosis. *J Bone Joint Surg Am.* 1970;52(3):457–467.
15. Marsh JL, Slongo TF, Agel J, et al. Fracture and dislocation classification compendium - 2007: Orthopaedic Trauma Association classification, database and outcomes committee. *J Orthop Trauma.* 2007;21(10 Suppl): S1–S133. doi:10.1097/00005131-200711101-00001
16. Baumgaertner MR, Curtin SL, Lindskog DM. Intramedullary versus extramedullary fixation for the treatment of intertrochanteric hip fractures. *Clin Orthop Relat Res.* 1998;(348):87–94.
17. Holzman MA, Hanus BD, Munz JW, et al. Addition of a Medial Locking Plate to an In Situ Lateral Locking Plate Results in Healing of Distal Femoral Nonunions. *Clin Orthop Relat Res.* 2016;474(6):1498- doi:10.1007/s11999-016-4709-3
18. Abram SG, Pollard TC, Andrade AJ. Inadequate 'three-point' proximal fixation predicts failure of the Gamma nail. *Bone Joint J.* 2013;95-B(6):825–830. doi:10.1302/0301-620X.95B6.31018
19. Singh NK, Sharma V, Trikha V, et al. Is PFNA-II a better implant for stable intertrochanteric fractures in elderly population ? A prospective randomized study. *J Clin Orthop Trauma.* 2019;10(Suppl 1):S71-S76. doi:10.1016/j.jcot.2019.02.004
20. Makki D, Matar HE, Jacob N, Lipscombe S, Gudena R. Comparison of the reconstruction trochanteric antigrade nail (TAN) with the proximal femoral nail antirotation (PFNA) in the management of reverse oblique intertrochanteric hip fractures. *Injury.* 2015;46:2389–2393. doi: 10.1016/j.injury.2015.09.038.
21. Okcu G, Ozkayin N, Okta C, Topcu I, Aktuglu K. Which implant is better for treating reverse obliquity fractures of the proximal femur: a standard or long nail? *Clin Orthop Relat Res.* 2013;471:2768–2775. doi: 10.1007/s11999-013-2948-0
22. Meinberg EG, Agel J, Roberts CS, Karam MD, Kellam JF. Fracture and dislocation classification compendium-2018. *J Orthop Trauma.* 2018;32(Suppl 1):S1–S170. doi: 10.1097/BOT.0000000000001063.
23. Müller F, Doblinger M, Kottmann T, Füchtmeier B. PFNA and DHS for AO/OTA 31-A2 fractures: radiographic measurements, morbidity and mortality [published online ahead of print, 2019 Oct 31]. *Eur J Trauma Emerg Surg.* 2019;10.1007/s00068-019-01251-w. doi:10.1007/s00068-019-01251-w
24. Morvan A, Boddaert J, Cohen-Bittan J, et al. Risk factors for cut-out after internal fixation of trochanteric fractures in elderly subjects. *Orthop Traumatol Surg Res.* 2018;104(8):1183- doi:10.1016/j.otsr.2018.06.021
25. De Bruijn K, den Hartog D, Tuinebreijer W, et al. Reliability of predictors for screw cutout in intertrochanteric hip fractures. *J Bone Joint Surg Am.* 2012;94(14):1266- doi:10.2106/JBJS.K.00357
26. Do JH, Kim YS, Lee SJ, et al. Influence of fragment volume on stability of 3-part intertrochanteric fracture of the femur: a biomechanical study. *Eur J Orthop Surg Traumatol.* 2013;23(4):371-

doi:10.1007/s00590-012-0983-2

27. Nie B, Chen X, Li J, et al. The medial femoral wall can play a more important role in unstable intertrochanteric fractures compared with lateral femoral wall: a biomechanical study. *J Orthop Surg Res.* 2017;12(1):197. Published 2017 Dec 28. doi:10.1186/s13018-017-0673-1
28. Mariani EM, Rand JA. Nonunion of intertrochanteric fractures of the femur following open reduction and internal fixation. Results of second attempts to gain union. *Clin.Orthop. Relat.Res.*1987:81–9.
29. Yu Q. Imaging study of stabilization factors after intramedullary fixation of intertrochanteric fractures. Beijing, Military Medical College. 2012.37-39.
30. Li J, Tang S, Zhang H, et al. Clustering of morphological fracture lines for identifying intertrochanteric fracture classification with Hausdorff distance-based K-means approach. *Injury.* 2019; 50(4):939–949. doi:10.1016/j.injury.2019.03.032
31. Biber R, Berger J, Bail HJ. The art of trochanteric fracture reduction. *Injury.* 2016;47 Suppl 7:S3-S6. doi:10.1016/S0020-1383(16)30845-2
32. Gotfried Y, Kovalenko S, Fuchs D. Nonanatomical reduction of displaced subcapital femoral fractures (Gotfried reduction). *J Orthop Trauma.* 2013;27(11):e254-e259. doi:10.1097/BOT.0b013e31828f8ffc
33. Chang SM, Zhang YQ, Ma Z, Li Q, Dargel J, Eysel P. Fracture reduction with positive medial cortical support: a key element in stability reconstruction for the unstable pertrochanteric hip fractures. *Arch Orthop Trauma Surg.* 2015;135(6):811-818. doi:10.1007/s00402-015-2206-x
34. Ye KF, Xing Y, Sun C, et al. Loss of the posteromedial support: a risk factor for implant failure after fixation of AO 31-A2 intertrochanteric fractures. *Chin Med J (Engl).* 2020;133(1):41-48. doi:10.1097/CM9.0000000000000587

## Tables

Table 1 Parameters of the assignment

Risk factor	assignment
Age	
<60	0
60-79	1
≥80	2
BMI	
<25	0
≥25	1
Singh index	
>3	0
≤3	1
Reduction quality	
Good or acceptable	0
poor	1
ASA index	
<3	0
≥3	1
TAD	
<25	0
≥25	1

Table 2 Demographic data for implant failure and non-failure groups

variable	Implant failure group(n=6)	Non-failure group(n=74)	P
Age	80±7.2	80.2±8.8	0.957
Gender			0.669
Male	2[33.3%]	25[33.8%]	
Female	4[66.7%]	49[66.2%]	
Injured hip			0.815
Left	3[50%]	34[45.9%]	
Right	3[50%]	40[54.1%]	
BMI*kg/m <sup>2</sup>	23.7±4.1	23.4±5	0.887
ASA			0.078
1	3[3.8%]	21[26.3%]	
2	0	27[33.8%]	
3	1[1.3%]	20[25%]	
4	2[2.5%]	6[7.5%]	
Singh index			0.867
1	4[5%]	37[46.3%]	
2	1[1.3%]	20[25%]	
3	0	6[7.5%]	
4	1[1.3%]	9[11.3%]	
5	0	2[2.5%]	

\*BMI=Body Mass Index

Table 3 The perioperative data of the two groups

variable	Implant failure group(n=6)	Non-failure group(n=74)	P
Fracture type			0.731
A1	2[33.3%]	23[31.1%]	
A2	4[66.7%]	51[68.9%]	
Nail length(mm)			0.35
170	0	7[9.5%]	
200	4[66.7%]	57[77%]	
240	2[33.3%]	10[13.5%]	
Reduction quality			0.044
Good	2[33.3%]	35[47.3%]	
Acceptable	2[33.3%]	35[47.3%]	
poor	2[33.3%]	4[5.4%]	
TAD *(mm)	18.3±6.1	22.3±6.3	0.138
Hospital stay(day)	10.3±3.3	8.9±3.2	0.307

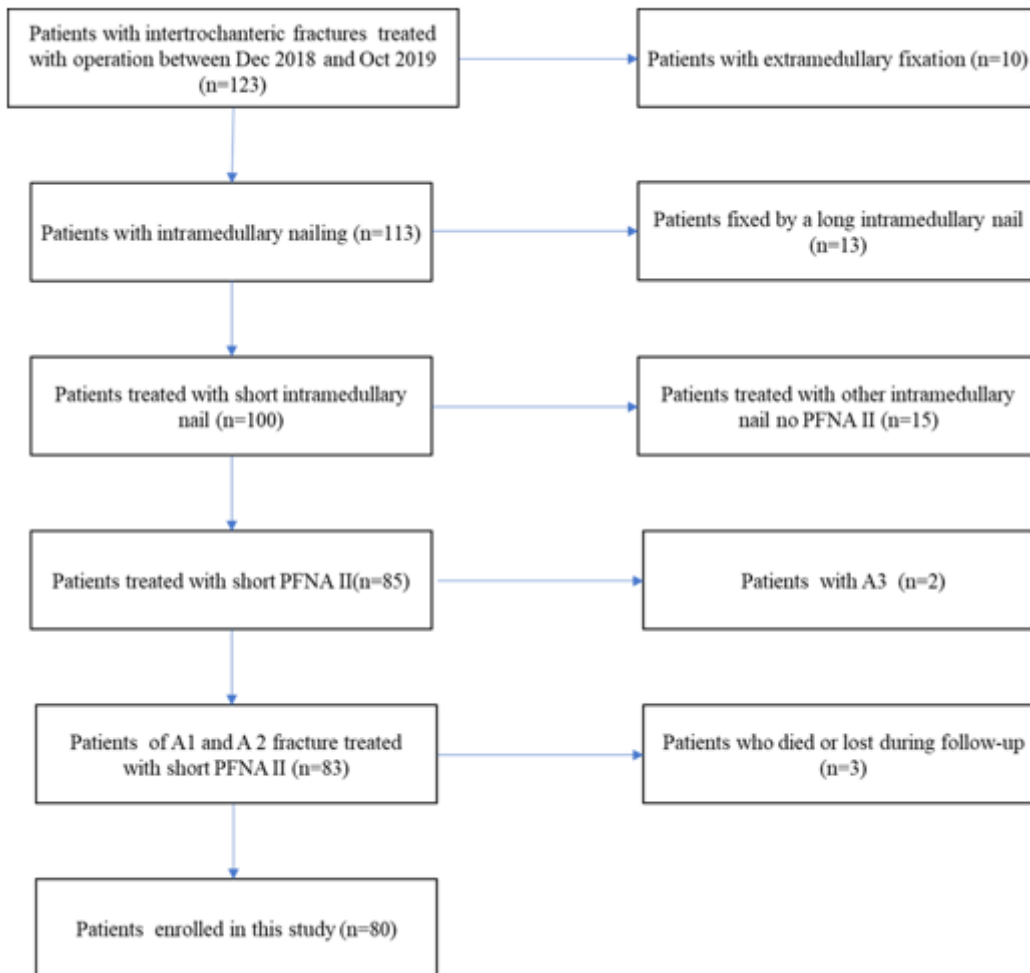
\*TAD= tip apex distance

Table 4 multi factor analysis on risk factors of implant failure of PFNA-II

parameter	OR	95% CI	P
Reduction quality	8.75	1.215-62.99	0.0313

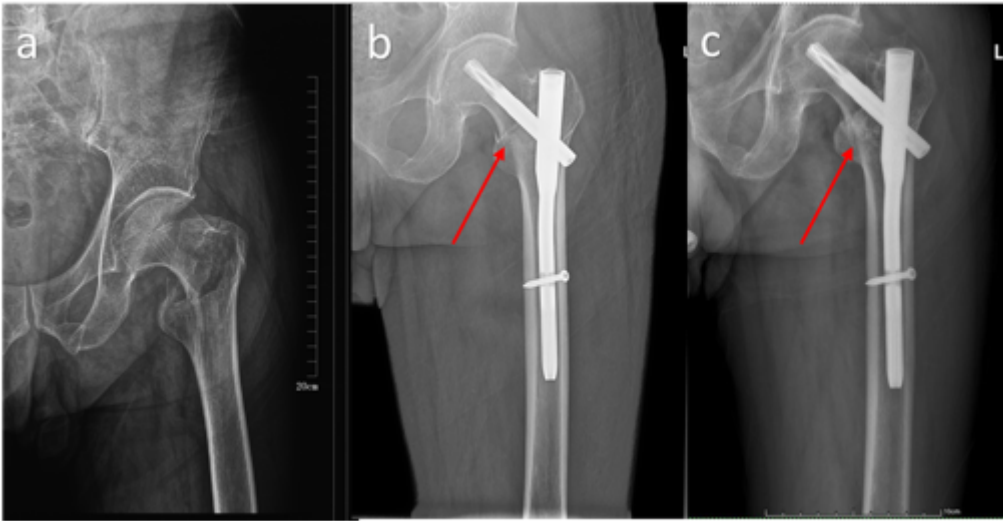
OR=odds ratio. CI= Confidence interval

## Figures



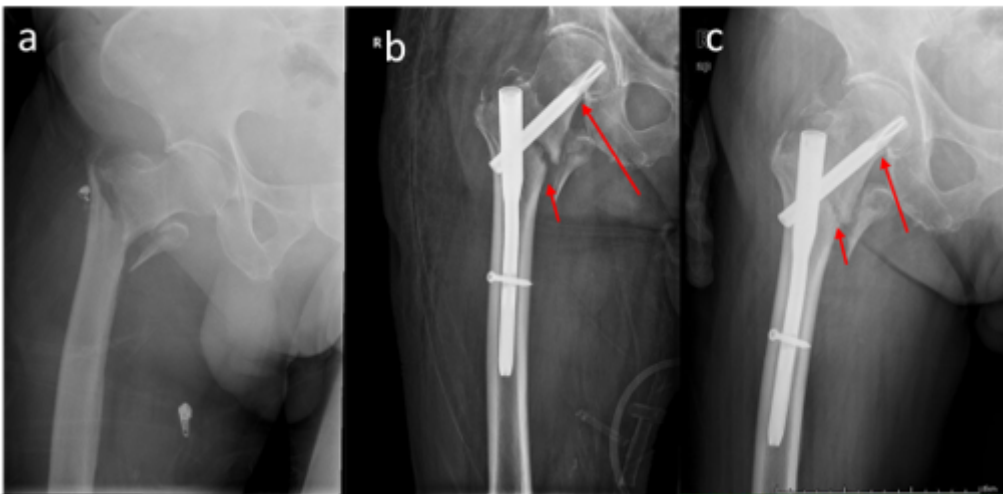
**Figure 1**

The research flow chart describing the process of patient inclusion and exclusion.



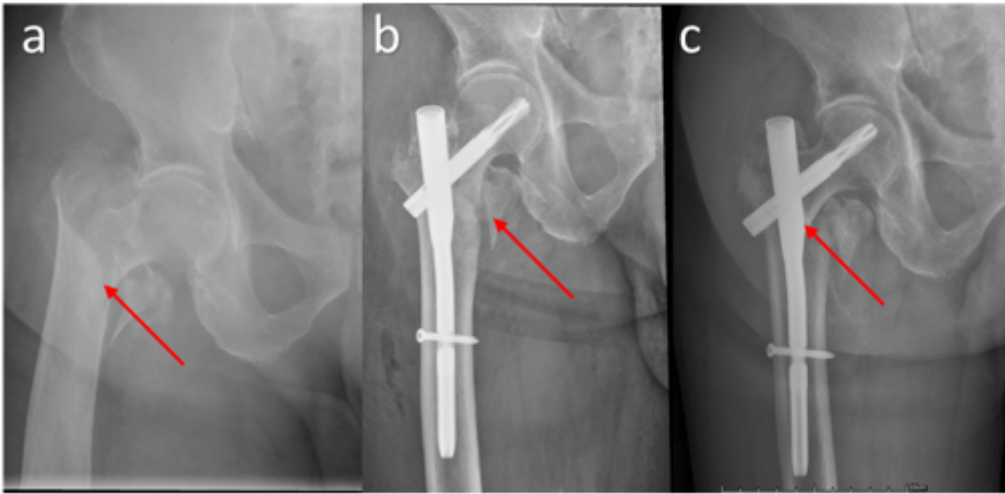
**Figure 2**

Cortical support is shown in a typical case. a: perioperative radiographs of intertrochanteric fracture. b: postoperative radiographs showed that the medical cortex of the head-neck fragment was supported by the medical cortex of the femur. c: radiographs of six months after surgery showed fracture union without reduction loss.



**Figure 3**

helical blade support shown in radiographs. a: intertrochanteric fracture with lesser trochanter free. b: The radiographs on the second day postoperative showed that the inferior cortex of head-neck fragment was blocked to varus by the helical blade (long red arrow). A gap was formed in fracture site (short red arrow). c: The femoral cervicodiaphyseal angle in three months was consistent with that the second day postoperative due to the helical blade support (long red arrow), but the gap in the fracture site was blurred (short red arrow).



**Figure 4**

Nail support shown in radiographs. a: intertrochanteric fracture with lateral wall less than 25 mm. b: postoperative radiographs showed that the fracture reduction was acceptable and the continuity of medial cortex was restored (red arrow). c: The reduction loss was showed in radiographs 3 months postoperative. The head-neck fragment was varus and the inferior cortex was blocked by the nail (red arrow).