

Endoscopic Versus Minimally Invasive Transforaminal Lumbar Interbody Fusion In 1-Segment Lumbar Spondylolisthesis: A Prospective Randomised Pilot Study

You Lv

Lianyungang Clinical College of Nanjing Medical University

Ming Chen

Lianyungang Clinical College of Nanjing Medical University

Ru-Jie Qin

Lianyungang Clinical College of Nanjing Medical University

Cheng Ma

Jiangsu Province Hospital and Nanjing Medical University First Affiliated Hospital

Qi-Rui Ding

Jiangsu Province Hospital and Nanjing Medical University First Affiliated Hospital

Hao-Nan Qin

Jiangsu Province Hospital and Nanjing Medical University First Affiliated Hospital

Jing-Yang Chen

Ningbo Medical Center, Lihuili Hospital

Xiang-fu Wang

Gansu Provincial Hospital of Traditional Chinese Medicine

Shou-Lin Wang

Nanjing Medical University School of Public Health

Yong-Xin Ren (✉ renyongxin2021@163.com)

Jiangsu Province Hospital and Nanjing Medical University First Affiliated Hospital

Research article

Keywords: minimally invasive, endoscopy, spondylolisthesis, interbody fusion, bone morphogenetic protein

Posted Date: May 28th, 2021

DOI: <https://doi.org/10.21203/rs.3.rs-397849/v2>

License: © ⓘ This work is licensed under a Creative Commons Attribution 4.0 International License. [Read Full License](#)

Abstract

Background: There are currently several minimally invasive techniques for lumbar spine interbody fusion that have been shown to minimize surgical and perioperative morbidity. We aimed to evaluate the curative efficacy of endoscopic transforaminal lumbar interbody fusion (Endo-TLIF) by comparing perioperative characteristics and 1.5-year observational outcomes in 1-segment lumbar spondylolisthesis between the minimally invasive TLIF (MIS-TLIF) technique and the optimized Endo-TLIF technique.

Methods: One hundred and two patients treated by MIS-TLIF (48 cases) or Endo-TLIF (54 cases) were included from March 2018 to April 2019. Perioperative parameters and clinical outcomes were evaluated. Inflammatory biomarkers were measured for postoperative traumatic stress and muscle injury. Fusion rates were determined at 18 months after surgery by CT.

Results: The Endo-TLIF group had similar incision length, return to work time and rate ($p>0.05$). Blood loss, left bed time and analgesic ratio were significantly less in Endo-TLIF group ($p<0.05$). The Endo-TLIF group had a significantly longer operative and radiation exposure time compared with MIS-TLIF group ($p<0.05$). The CRP and ESR levels were lower in the Endo-TLIF group compared with the MIS-TLIF group ($p<0.05$). The VAS and ODI improved significantly in both groups after surgery. Significant decreases in low back VAS in the Endo-TLIF group were found at postoperative day 1 and 3 months after surgery ($p<0.05$). The fusion rate in the Endo-TLIF group (90.7%) was similar to that in the MIS-TLIF group (95.8%).

Conclusions: Endo-TLIF has comparable perioperative analysis and clinical outcomes in comparison to MIS-TLIF and manifests a greater improvement in less multifidus muscle damage, inflammation and faster patient recovery. Thus, Endo-TLIF should be considered as a feasible and effective technique for 1-segment lumbar spondylolisthesis patients with similar fusion rate.

Trial registration: ChiCTR1800015197, 13 March 2018. Trial registry: Chinese Clinical Trial Registry. Registered 13 March 2018. <http://www.chictr.org.cn/showproj.aspx?proj=25865>

Background

Spinal fusion has been shown to be the preferred surgical option to reduce chronic back pain, back-related leg pain, and increase quality of life in the treatment of lumbar degenerative disorders (LDD) [1]. Although conventional posterior open fusion surgeries can achieve wide decompression of neural structures and provide stabilization for surgically treated segments, they could also result in extensive destruction of posterior anatomical structures, requiring long periods of recovery. Meanwhile, the psychological, economic and social costs of the postoperative period should not be underestimated. Therefore, various types of minimally invasive (MIS) spine surgeries have been attempted to treat LDD [2–5]. These MIS techniques have resulted in less pain, reduced blood loss and shorter hospital stays for patients, enabling spinal surgeons to offer fusion surgery to those who may otherwise be wary of it [6]. Recent studies [7], including our previous research [8], have shown that MIS techniques, such as minimally invasive transforaminal interbody fusion (MIS-TLIF), might offer comparable clinical results with traditional open TLIF, such as a shorter hospital stay, less blood loss and shorter recovery time. However, MIS-TLIF still requires an open incision, including partial paravertebral musculature separation, partial laminotomy and facetectomy to achieve a successful discectomy and place the cage.

The transforaminal endoscopic posterolateral approach is a well-known standard in endoscopic spine surgery that allows direct access to the disc with minimal invasive techniques. With the advancement of endoscopic technique, several percutaneous endoscopic fusion techniques have been reported for treating LDD [9, 10]. Since 2017, we have explored the endoscopic transforaminal lumbar interbody fusion (Endo-TLIF), and tried to achieve improved recovery rates. This approach utilizes a combination of endoscopic visualization, discectomy, cages, percutaneous fixation and osteobiologics. However, several studies reported that the endoscopic interbody fusion techniques had shown limitations, especially in the insertion of the rigid bullet-shaped cage [10]. The standard cage is too large and rigid to pass through the conventional endoscopic working channel. Thus, a smaller but expandable cage was inserted into the intervertebral space [11]. In addition, some clinicians used more allogeneic bone to increase the amount of bone graft, which may reduce the rate of intervertebral fusion. Thus, bone morphogenetic protein (BMP) was combined with the application [10–12]. In this study, we used a novel C-shaped working cannula system, which not only allowed the insertion of a larger cage, but also allowed the channel to be inserted into the posterior margin of the intervertebral space. In this way, the nerve root is protected on the lateral side. BMP was not applied in this study, though

allogeneic bone was the main bone grafting material in Endo-TLIF group. Furthermore, the use of cages without size reduction could be expected to reduce side effects such as the collapse of the endplate and increase the success rate of interbody fusion.

Typically, investigations of MIS assess outcomes from a variety of pathologies, such as lumbar spinal stenosis, lumbar instability syndrome and spondylolisthesis, and different diagnoses may lead to bias in assessing clinical outcomes. Therefore, we aimed to compare the perioperative characteristics and 1.5-years observational outcomes for the treatment of patients with one-segment spondylolisthesis using the Endo-TLIF or MIS-TLIF technique.

Methods

Patient Collection

Our clinical study proposal was approved by the medical ethics committee of Lianyungang Clinical College of Nanjing Medical University. Written informed consents were obtained from 102 consecutive patients prior to inclusion in the study. The inclusion criteria of this study included complaints of unilateral or bilateral radicular leg pain; single-level lumbar disc herniation or stenosis with one-grade or two-grade lumbar spondylolisthesis demonstrated by anteroposterior, lateral and flexion extension plain radiographs, computed tomography (CT) scans and magnetic resonance imaging (MRI); and a lack of response to extensive conservative therapy for at least 3 months before surgery. Patients with osteoporosis, drug abuse, neoplasm, bone infection, or systemic diseases were excluded. Patients were assigned by a single-blind quasi-randomization within the spine department. Briefly, after the patients met the inclusion criteria and gave consent for the study, they were numbered serially at the spine department and were randomly assigned to MIS-TLIF or Endo-TLIF group. The surgeons were not informed of the group to which a patient was assigned until immediately before surgery. Finally, 102 consecutive patients with new onset spondylolisthesis were treated between March 2018 and April 2019, in which 48 patients received MIS-TLIF and 54 cases received Endo-TLIF.

Operative Techniques

All operations in Endo-TLIF group were performed under general anesthesia. With the patient placed in the prone position on a radiolucent operating table, percutaneous pedicle screws were placed using an anteroposterior fluoroscopic technique with Jamshidi needles and an intervertebral spreader was applied (Fig. 1A). The endoscopic procedure was begun by accessing Kambin's triangle on the side. Successive dilation of the access site was performed to allow for the introduction of a 7.5-mm-diameter working channel (Joimax). The traversing and exiting nerve roots were visualized with the working channel endoscope and decompressed directly by removing any compressive bone or cartilaginous tissues using electrocautery, pituitary rongeurs, microosteotomes and automatic power drills. The disc space was cleared, and the intervertebral spreader was opened (Fig. 1A). Discectomy and endplate preparation for interbody fusion were performed after adequate transforaminal decompression. Epidural bleeding was controlled by radiofrequency probes. A 9-mm-diameter working channel was used and various kinds of reamer, curettes, endplate shavers and dissectors were used for complete preparation of the endplate under clear endoscopic view. Specifically, the remaining cartilaginous endplate could be detached from the osseous endplate with the tongue of the channel under full endoscopic guidance without endplate injury (Fig. 1E). After fusion site preparation, removing the endoscope and absorbing endoscopic water flow, the intervertebral spreader was expanded and the working cannula was then replaced with a larger C-shaped working channel (Fig. 1A and D) that protected the nerve root and facilitated the delivery and placement of the polyether-etherketone interbody cage (Capstone, Medtronic Sofamor Danek, USA) under fluoroscopic guidance (Fig. 1A,B and C). Meanwhile, the anterior disc space was filled with allograft bone chips (Fig. 1A). Finally, the intervertebral spreader was removed and percutaneous pedicle screws or facet screws were inserted and reset lumbar spondylolisthesis. Upon completing the instrumentation procedure, direct closure of the skin incision was performed (Fig. 1F) and the patient was monitored for complications.

The technique of our previous study for unilateral MIS-TLIF included bilateral screw fixation and was performed on the more symptomatic side [8]. Briefly, fluoroscopic guidance was used to determine the disc space and mark the lateral pedicle line and the lateral view was checked for tubular retractor system insertion. After a vertical skin incision (25 mm for the segment) at the lateral pedicle line, a tubular retractor (diameter: 22 mm, Medtronic Sofamor Danek, Memphis, TN) was introduced to the facet joint under

fluoroscopic guidance and unilateral total facetectomy and laminectomy were performed (Fig. 2A). After a complete facetectomy, the ligamentum flavum was removed to expose the lateral border of the ipsilateral exiting and traversing the nerve root. Decompression of the central or contralateral stenosis was then performed. A discectomy was performed, and a polyether-etherketone interbody cage (Capstone, Medtronic Sofamor Danek, USA) filled with autologous local bone was inserted. Then, the percutaneous pedicle screw system (Sextant; Medtronic Sofamor Danek, USA) was placed through the minute incision under fluoroscopic guidance (Fig. 2B and C).

Clinical Outcome Assessment and Radiological Evaluation

Perioperative parameters such as operation time, blood loss, analgesic ratio, incision length, return to work time and rate, complications, postoperative hospitalization days and radiation exposure time were recorded during the operations. Postoperative complications and symptom recurrence requiring reoperation were assessed through review of medical record documentation and/or telephone interviews with patients. Visual Analog Scale (VAS) and Oswestry Disability Index (ODI) scores were evaluated for patients’ symptoms at preoperation and postoperative days 1 and 3 and 18 months after surgery. Inflammatory responses such as the concentration of white blood cells (WBC), c-reactive protein (CRP), tumor necrosis factor alpha (TNF-α) and erythrocyte sedimentation rate (ESR) of the enrolled patients were measured at preoperation and postoperative day 1 and 4. The inflammatory markers were tested by the clinical laboratory of our institution. Segmental lordosis was measured by Cobb’s angle between the upper and lower endplates of the vertebrae that formed the operative segments. Fusion rates were determined by CT and ranked according to five grades based on the anterior fusion criteria described by Brantigan (Fig. 3E) [13]. Two radiologists who were blinded to the patients’ data performed all evaluations independently.

Statistical Analyses

Statistical analysis was performed using SPSS 20.0 software (SPSS Inc, Chicago, IL, USA). All data are presented as the mean ± S.D. (standard deviation). Unpaired t-test was used to compare the operation parameters between the two groups, and a paired t-test was used to compare preoperation and postoperation parameters in each group. The differences of the fusion rates among groups were compared using χ^2 test for comparison. Statistically significant differences were considered when *P* values were less than 0.05.

Results

Patients Characteristics

The analysis identified 102 patients meeting the study criteria, with a follow-up of 18 months. During the study, no patients within the series were excluded or lost to follow-up. There were no significant differences among the 2 groups regarding sample size, age, sex, symptom duration, operation level and body mass index ($p > 0.05$, Table 1).

Table 1 Demographic characteristic of the enrolled patients

	MIS-TLIF group	Endo-TLIF	<i>P</i>
Cases	48	54	0.65
Age (years)	53.98±11.51	55.36±12.75	0.51
Gender			0.66
Male	26	32	
Female	22	22	
symptoms duration (years)	8.5±4.2	10.2±6.1	0.28
operation level			0.31
L3-L4	10	14	
L4-L5	24	30	
L5-S1	14	10	
body mass index	25.3±4.2	25.3±4.1	0.77
MIS = minimally invasive; TLIF = transforaminal lumbar interbody fusion; Endo = endoscopic; rhBMP-2 = recombinant human bone morphogenetic protein-2			

Changes of perioperative parameters of patients in Endo-TLIF and MIS-TLIF groups

Perioperative analysis showed that the Endo-TLIF group had comparative incision length, rate of return to work and mean return to work time compared with the MIS-TLIF group ($p > 0.05$, Table 2), and it also had a significantly longer operative time and radiation exposure time compared with the MIS-TLIF group ($p < 0.05$, Table 2). However, blood loss, left bed time, postoperative hospitalization days and analgesic ratio were significantly less in the Endo-TLIF group in comparison to the MIS-TLIF group during the hospitalization ($p < 0.05$, Table 2). In addition, there was one case of cage migration without any symptoms in the Endo-TLIF group and revisions were not performed. One superficial infection occurred in a single patient in the MIS-TLIF group, which was treated conservatively.

Table 2 Perioperative and return to work results comparison between patients in two groups

	MIS-TLIF group n=48	Endo-TLIF group n=54	<i>P</i>
Operative time (minutes)	104.1±17.2	188.1±23.4	0.01
Blood loss (ml)	146.2±41	45.1±12.4	0.01
postoperative hospitalization (days)	7.2±2.7	3.6±1.6	0.01
leaving bed time (days)	3.5±1.2	1.5±0.7	0.01
incision length cm	7.5±0.5	7.7±0.3	0.78
Analgesic ratio %	75	35	0.01
Mean return to work time (weeks)	7.8±1.9	7.2±1.4	0.49
Rate of return to work (%)	93.8	96.3	0.55
Radiation exposure time s	19.5±6.1	37.7±6.8	0.01
Complications	One superficial infection	one case of cage migration	
MIS = minimally invasive; TLIF = transforaminal lumbar interbody fusion; Endo = endoscopic			

Inflammatory responses of patients in Endo-TLIF and MIS-TLIF groups

The concentration level of CRP was lower in the Endo-TLIF group compared with the MIS-TLIF group, and the CRP levels rose gradually on days 1 and 4 after surgery ($p < 0.05$, Table 3). The ESR level also increased gradually after surgery, and the level in the Endo-TLIF group was significantly lower than that in the MIS-TLIF group on day 4 ($p < 0.05$, Table 3). There were no significant differences with respect to WBC and TNF- α between the 2 groups ($p > 0.05$, Table 3).

Table 3 Serum levels of inflammatory markers measured at 3 time points

	Preoperative			First Day			Fourth Day		
	MIS-TLIF	Endo-TLIF	<i>P</i>	MIS-TLIF	Endo-TLIF	<i>P</i>	MIS-TLIF	Endo-TLIF	<i>P</i>
WBC (10 ⁹ /L)	5.76±0.82	5.68±1.06	0.35	10.75±1.5	10.58±1.42	0.66	7.56±1.37	7.34±1.12	0.73
TNF- α (pg/mL)	5.49±0.44	5.66±0.28	0.49	6.36±0.83	6.23±0.43	0.72	6.35±0.82	6.53±0.97	0.43
CRP (mg/L)	4.81±1.20	4.96±1.11	0.87	19.31±2.15	15.78±2.12	0.01	25.53±5.24	21.29±3.43	0.01
ESR(mm/60min)	7.03±2.66	7.35±2.13	0.92	16.38±2.13	15.86±2.57	0.46	24.88±5.32	18.55±3.83	0.01
WBC = white blood cells; CRP = c-reactive protein; TNF- α = tumor necrosis factor alpha; ESR = erythrocyte sedimentation rate;									

Comparison of VAS and ODI between Endo-TLIF and MIS-TLIF groups

The VAS was measured on a scale of 0 for no pain to 10 for the worst pain imaginable. The mean VAS for lower back pain and leg pain indicated that the 1.5 year postoperative pain levels in the two groups were both significantly lower than the preoperative levels and relief of pain was consistent throughout the entire observation time ($p < 0.05$, Table 4). Significant differences for low back pain were found between the two groups at postoperative day 1 and 3 months after surgery ($p < 0.05$, Table 4). The ODI demonstrated comparable results with the VAS, with patients experiencing consistent symptom reduction throughout the 18 months ($p < 0.05$, Table 4) and there was no significant difference between the two groups during the observation time ($p > 0.05$, Table 4).

Table 4 Clinical results and segmental lordosis comparison between patients in two groups

	MIS-TLIF group n=48	Endo-TLIF group n=54	P
Low back VAS			
Preoperative	7.82±0.71	7.51±0.92	0.72
1 day after surgery	5.31±0.51	4.21±0.43	0.01
3 months after surgery	3.59±0.41	2.96±0.38	0.01
18 months after surgery	2.64±0.38	2.61±0.32	0.24
Lower extremity VAS			
Preoperative	8.11±0.85	7.59±0.95	0.31
1 day after surgery	4.43±0.65	4.31±0.47	0.79
3 months after surgery	3.33±0.49	3.53±0.59	0.51
18 months after surgery	2.36±0.38	2.61±0.33	0.59
ODI			
Preoperative	62±8.1	57.3±7.9	0.72
1 day after surgery	36.2±4.7	38.5±4.5	0.52
3 months after surgery	27.1±3.4	25.7±5.1	0.42
18 months after surgery	15.7±4.6	16.2±3.1	0.29
Segmental lordosis			
Preoperative	15.4±1.51	15.1±1.66	0.57
18 months after surgery	21.2±2.75	20.1±3.17	0.37
P	0.001	0.001	
VAS = Visual Analog Scale; ODI = Oswestry Disability Index;			

Segmental lordosis and Fusion status of patients in Endo-TLIF and MIS-TLIF groups

The intragroup comparison was done according to operation methods. Segmental lordosis revealed significant changes 1.5 years postoperatively compared with the preoperative state and no differences were found between the two groups (Table 4). Fusion status at the review time was assessed by CT scan at 1.5 years postoperatively. According to the anterior fusion criteria described by Brantigan, grades 4 and 5 were considered fused [13]. Forty-six out of 48 patients (95.8 %) in MIS-TLIF group and 49 out of 54 patients (90.7%) in Endo-TLIF group (Fig. 3E) met the fusion criteria, respectively. And the fusion rate in Endo-TLIF (90.7%) was similar to that in the MIS-TLIF group (95.8 %) (p = 0.202).

Discussion

Over the past decade, minimally invasive lumbar interbody fusion has become very popular for treating a variety of lumbar spinal disorders. Our previous study [8] had indicated that MIS-TLIF allowed for decreased soft-tissue manipulation, which may have the benefits of reducing blood loss and facilitating expeditious postoperative recovery. Meanwhile, it could lead to a reduction in nerve root traction while being able to address central and neural foraminal stenosis [14]. However, surgical techniques based on the Mast Quadrant still require articulectomy and partial paravertebral musculature separation. Recently, new minimally invasive spine surgeries have been applied to further reduce the trauma and enhance postoperative recovery. Specifically, endoscopic spine and lumbar interbody fusion procedures minimize the skin incision and traumatization of posterior muscles and ligaments [15, 16]. However, endoscopic fusion techniques remain a challenging and technically complex procedure associated with the

transforaminal endoscopic approach [17]. In the present study, we tested TLIF using the endoscopic approach to achieve maximal preservation of normal musculo-ligamentous structures versus using tubular retractors.

Anatomically, the size of the intervertebral foramen is the main factor affecting the puncture and catheterization in the process of Endo-TLIF. Because the superior articular process of the lower vertebral body is directly opposite the upper intervertebral disc, it is difficult to accommodate the conventional 7.5mm diameter or bigger channels [18]. A recent study reported the rate of dysesthesia for Endo-TLIF was higher than for regular endoscopic procedures. This could be due to a bigger outer diameter of the Endo-TLIF cannula (14–16 mm) compared to regular endoscopic cannulas (7.5 mm) and strong vibrations when placing the cannula and inserting the expandable cage [19]. In addition, several studies showed that when performing the endoscopy-guided interbody cage placement, the smaller fusion cage had to be used because of the limitation that the conventional cage was too large to pass through the working channel. This may result in an increased risk of nonunion, delayed cage subsidence, or migration, especially in patients with severe osteoporosis [17–19]. Therefore, novel techniques to enlarge the intervertebral foramen, place the endoscopic channel in the intervertebral space smoothly and safely, obtain more effective decompression and implant a conventional cage are crucial.

In this study, we demonstrated how to directly enlarge the intervertebral foramen by improving the design of the intervertebral spreader while avoiding extensive damage to the surrounding tissue and superior facet (Fig. 1A). Meanwhile, the novel C-shaped working cannula system, which aims to place the cage into the intervertebral space safely and quickly, is able to achieve minimally invasive endoscopic decompression and protect the nerves (Fig. 1A and D). Although the diameter of the channel is 12mm (Fig. 1D), its C-shaped construction, especially the forward structure occupies about half space of the circular passage, which can be safely placed into the intervertebral space. This greatly reduces the risk of nerve damage and tissue trauma. Fusion devices less than 11mm in width and less than 14mm in height can be implanted through this channel easily, although the height of a conventional interbody cage is usually no more than 13 mm. With a converter, we can still perform intraspinal processing and bone graft under this channel (Fig. 1D).

Our study showed that the Endo-TLIF group had comparative incision length, mean return to work time, and rate of return to work compared with MIS-TLIF group. However, Endo-TLIF reported less blood loss, decreased postoperative hospitalization days, left bed time and lower analgesic ratio compared with the MIS-TLIF group (Table 2). The endoscopic spine approach minimizes the skin incision and traumatization of posterior muscles and ligaments such as multifidus muscles. Moreover, early studies show percutaneous endoscopic surgery can be performed under local anesthesia or epidural anesthesia [11, 12]. In addition, the VAS and ODI in the MIS-TLIF and Endo-TLIF groups were both significantly lower than the preoperative levels, and the decrease was consistent throughout the entire observation time. The long-term clinical outcomes demonstrate durable and meaningful functional status improvements following these MIS procedures. The low back VAS in the Endo-TLIF group was significantly lower than in the MIS-TLIF group at day 1 and 3 months after surgery (Table 2). Thus, our results suggest that Endo-TLIF manifests more improvements in postoperative quicker recovery.

Several studies consider that hypertrophied facet joints and thickened transverse processes, especially high iliac crests (HIC) are considered a relative contraindication for transforaminal percutaneous disc decompression at L5-S1[22]. While they provide a definition and classification of HIC, the highest point of the iliac crest used in the classification is not actually the position of the puncture needle or working cannula contacting the ilium. Yang et al [23] studied one hundred patients and introduce a lumboiliac triangular technique based on biplane oblique fluoroscopy which facilitated transforaminal percutaneous disc decompression for patients with L5-S1 lumbar disc herniation (LDH) combined with HIC. Thus, this technique has been used to complete some Endo-TLIF with L5 spondylolisthesis combined with HIC in our study.

Previous studies have documented the harmful effects of extensive paraspinal muscular dissection and retraction lumbar surgery [8]. Indeed, retractor blades have been shown to increase intramuscular pressure that can ultimately lead to postoperative LBP and ischemia. We took inflammatory markers and white blood cells (WBC) as the observation indices. The CRP level rose gradually over the first and fourth day after surgery and was lower in the Endo-TLIF group compared with the MIS-TLIF group after surgery. The ESR level also rose after surgery, and the level in Endo-TLIF group was significantly lower than that in MIS-TLIF group on day 4 (Table 3). Thus, all of these results indicate that Endo-TLIF technology has a more positive influence in improving postoperative LBP and analgesic ratio compared with MIS-TLIF. However, the operative time and radiation exposure time in the Endo-TLIF group

was significantly longer than that in the MIS-TLIF group and suggests the limitation of Endo-TLIF lies in the long learning curve required to ensure each step of the procedure is safe and effective. Several steps of endoscopic TLIF require fluoroscopic guidance and it goes without question that methods for reducing radiation exposure in the setting of Endo-TLIF will have significant long-term health benefits.

Endo-TLIF reached a similar fusion rate to that in MIS-TLIF (90.7% vs 95.8%) in our study. This indicates that Endo-TLIF could have a good fusion rate. Before the experiment, we were concerned about the possibility of low fusion rate due to more allografts and very little amount of autografts were implanted in the Endo-TLIF group and the osteogenic capacity of allograft may weaker than autologous bone in the MIS-TLIF group [24]. Studies have shown high fusion rates were appeared in MIS-TLIF, such as 88.9% at postoperative 1 year and 96.0% at postoperative 3 years [8, 25]. Dong Hwa Heo[26] presented the fusion rate of the Endo-TLIF group was 73.9% at postoperative 1 year. Thus, the similar fusion rate between two groups indicating that BMP may not be necessary in Endo-TLIF. Theoretically, trauma of paraspinal soft tissue in open posterior procedures has an adverse effect on adjacent segments and reduces the blood supply for fusion [27]. Our result was in accord with the theory and minimal muscle injury in Endo-TLIF is conducive to an improvement in fusion rate. Meanwhile, the conventional large cage with large amount of allografts was allowed to pass through the novel C-shaped working cannula system. This may also help to improve the fusion rate.

Limitations of this study include a small sample size and limited follow-up period. Randomized controlled trials with long-term follow-up and a larger number of patients are needed to obtain more accurate clinical results.

Conclusions

Endo-TLIF surgery technique seems to be associated with less multifidus muscle damage, inflammation and faster patient recovery compared with MIS-TLIF group. Meanwhile both two technologies can be used to effectively treat 1-segment lumbar spondylolisthesis with similar fusion rate.

Abbreviations

MIS: minimally invasive; TLIF: transforaminal lumbar interbody fusion; Endo: endoscopic; VAS: Visual Analog Scale; ODI: Oswestry Disability Index; WBC: white blood cells; CRP: c-reactive protein; TNF- α : tumor necrosis factor alpha; ESR: erythrocyte sedimentation rate; LDD: lumbar degenerative disorders; rhBMP-2: recombinant human bone morphogenetic protein

Declarations

Acknowledgements

Not applicable.

Authors' contributions

Conception and design: Y Lv, M Chen, YX Ren, XF Wang; Provision of study materials or patients: Y Lv, C Ma, QR Ding, HN Qin; Collection and assembly of data: Y Lv, C Ma, XF Wang, HN Qin; Data analysis and interpretation: Y Lv, JY Chen; Manuscript writing: All authors; Final approval of manuscript: All authors.

Availability of data and materials

The datasets used and/or analyzed during the current study are available from the corresponding author on reasonable request.

Competing interests

The authors declare that they have no competing interests.

Authors' contributions

You Lv and Ming Chen contributed equally to this work.

Funding

The study was supported by the project of youth talent fund of the First people's hospital of Lianyungang, Jiangsu, China (QN1708), and Health Science and Technology Project of Lianyungang (QN202001)

Ethics approval and consent to participate

Data acquisition and analysis were performed in accordance with ethical guidelines and approved by the Ethics Committee of Lianyungang Clinical College of Nanjing Medical University. Lianyungang Approved No. of ethic committee 2017-099-02. All patients provided written informed consent for participation.

References

1. Pearson AM, Lurie JD, Tosteson TD, Zhao W, Abdu WA, Weinstein JN. Who should undergo surgery for degenerative spondylolisthesis? Treatment effect predictors in SPORT. *Spine (Phila Pa 1976)* 2013;38:1799-811.
2. Hammad A, Wirries A, Ardeschiri A, Nikiforov O, Geiger F. Open versus minimally invasive TLIF: literature review and meta-analysis. *J Orthop Surg Res.* 2019 Jul 22;14(1):229
3. Vazan M, Gempt J, Meyer B, Buchmann N, Ryang YM. Minimally invasive transforaminal lumbar interbody fusion versus open transforaminal lumbar interbody fusion: a technical description and review of the literature. *Acta Neurochir (Wien)* 2017;159:1137- 1146.
4. Hwa Eum J, Hwa Heo D, Son SK, Park CK. Percutaneous biportal endoscopic decompression for lumbar spinal stenosis: a technical note and preliminary clinical results. *J Neurosurg Spine* 2016;24:602-607.
5. Wu M, Li J, Zhang M, Ding X, Qi D, Li G, Shen Y. Efficacy and radiographic analysis of oblique lumbar interbody fusion for degenerative lumbar spondylolisthesis. *J Orthop Surg Res.* 2019 Nov 28;14(1):399.
6. Yong Ahn. Current techniques of endoscopic decompression in spine. *Ann Transl Med* 2019;7(Suppl 5):S169.
7. Kim TY, Kang KT, Yoon DH, Shin HC, Kim KN, Yi S. et al. Effects of lumbar arthrodesis on adjacent segments: differences between surgical techniques. *Spine (Phila Pa 1976)* 2012;37:1456-62.
8. You Lv, Jingyang Chen, Jinchuan Chen, Yuling Wu, Xiangyang Chen, Yi Liu, et al. Three-year postoperative outcomes between MIS and conventional TLIF in 1-segment lumbar disc herniation. *Minim Invasive Ther Allied Technol* 2017;26:168-176.
9. Jacquot F, Gastambide D. Percutaneous endoscopic transforaminal lumbar interbody fusion: is it worth it? *Int Orthop* 37;2013:1507-10.
10. Wang MY, Grossman J. Endoscopic minimally invasive transforaminal interbody fusion without general anesthesia: initial clinical experience with 1-year follow-up. *Neurosurg Focus* 2016;40:E13.
11. Youn MS, Shin JK, Goh TS, Lee JS. Full endoscopic lumbar interbody fusion (FELIF): technical note. *Eur Spine J* 2018;27:1949-1955.
12. Wang MY, Wang PY, Grossman J. Development of an Enhanced Recovery After Surgery (ERAS) approach for lumbar spinal fusion. *J Neurosurg Spine* 2017;26:411-418.
13. Brantigan JW, Steffee AD. A carbon fiber implant to aid interbody lumbar fusion. Two-year clinical results in the first 26 patients. *Spine (Phila Pa 1976)* 1993;18:2106-7.
14. Wu J, Zhang C, Lu K, Li C, Zhou Y. A Novel Inextensible Endoscopic Tube Versus Traditional Extensible Retractor System in Single-Level Minimally Invasive Transforaminal Lumbar Interbody Fusion: A Prospective Observation Study. *Pain Physician* 2019;22:E587-E599.
15. Kang MS, Hwang JH, Choi DJ, Chung HJ, Lee JH, Kim HN, Park HJ. Clinical outcome of biportal endoscopic revisional lumbar discectomy for recurrent lumbar disc herniation. *J Orthop Surg Res.* 2020 Nov 23;15(1):557.

16. John GK , Damian B, Michael YW. Endoscopic transforaminal lumbar interbody fusion without general anesthesia: technical innovations and outcomes. *Ann Transl Med* 2019;7(Suppl 5):S167.
17. Ahn Y, Youn MS, Heo DH. Endoscopic transforaminal lumbar interbody fusion: a comprehensive review. *Expert Rev Med Devices* 2019 16(5):373-380.
18. He EX, Guo J, Ling QJ, Yin ZX, Wang Y, Li M. Application of a narrow-surface cage in full endoscopic minimally invasive transforaminal lumbar interbody fusion. *Int J Surg* 2017;42:83-89.
19. Morgenstern C, Yue JJ, Morgenstern R. Full Percutaneous Transforaminal Lumbar Interbody Fusion Using the Facet-sparing, Trans-Kambin Approach. *Clin Spine Surg* 2020;33:40-45.
20. Lewandrowski KU, Ransom NA, Ramírez León JF, Yeung A. The concept for a Standalone Lordotic Endoscopic Wedge Lumbar Interbody Fusion: the LEW-LIF. *Neurospine* 2019;16:82-95.
21. Zhang YW, Xia WH, Gao WC, Xiao X, Xiao Y, Gong FP. Direct foraminoplasty in endoscope-assisted transforaminal lumbar interbody fusion for the treatment of lumbar disc herniation. *J Int Med Res* 2020;48:30.
22. Eun SS, Lee SH, Liu WC, Erken HY. A novel preoperative trajectory evaluation method for L5-S1 transforaminal percutaneous endoscopic lumbar discectomy. *Spine J* 2018; 18:1286-1291
23. Yang JS, Liu KX, Kadimcherla P, Chu L, Deng ZL, Chan YK, et al. Can the Novel Lumbolliac Triangle Technique Based on Biplane Oblique Fluoroscopy Facilitate Transforaminal Percutaneous Endoscopic Lumbar Discectomy for Patients with L5-S1 Disc Herniation Combined with High Iliac Crest? Case-Control Study of 100 Patients. *Pain Physician*. 2020;23(3):305-314.
24. Yoo JS, Ahn J, Patel DS, Hrynewycz NM, Brundage TS, Singh K. An evaluation of biomaterials and osteobiologics for arthrodesis achievement in spine surgery. *Ann Transl Med* 2019;7(Suppl 5):S168.
25. Kim JY, Park JY, Kim KH, Kuh SU, Chin DK, et al. Minimally Invasive Transforaminal Lumbar Interbody Fusion for Spondylolisthesis: Comparison Between Isthmic and Degenerative Spondylolisthesis. *World Neurosurg*. 2015;84(5):1284-1293.
26. Heo DH, Park CK. Clinical results of percutaneous biportal endoscopic lumbar interbody fusion with application of enhanced recovery after surgery. *Neurosurg Focus*. 2019;46(4):E18.
27. Jin-Tao Q, Yu T, Mei W, Xu-Dong T, Tian-Jian Z, Guo-Hua S, et al. Comparison of MIS vs. open PLIF/TLIF with regard to clinical improvement, fusion rate, and incidence of major complication: a meta-analysis. *Eur Spine J* 2015;24:1058 –65.

Figures

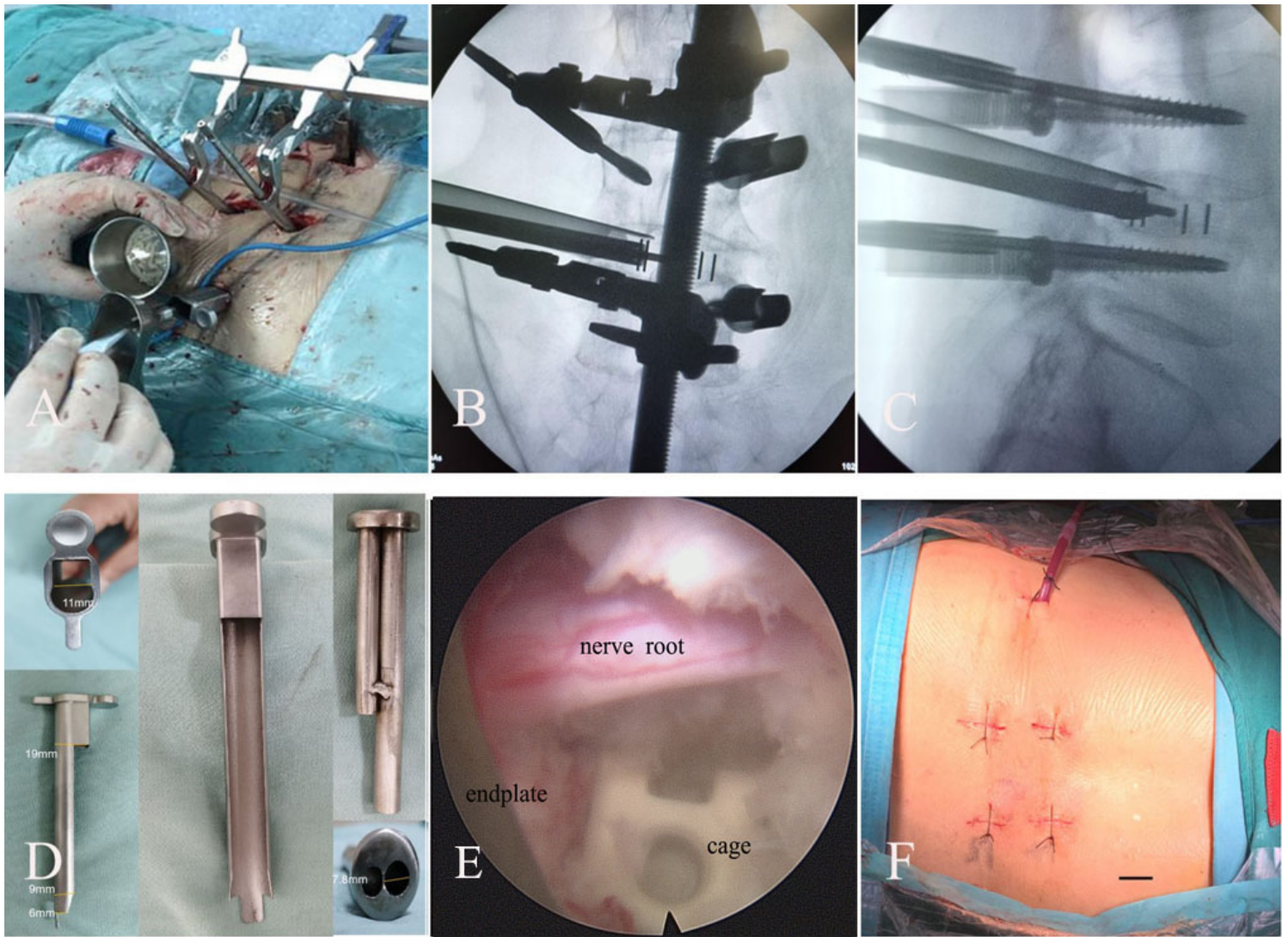


Figure 1

Intraoperative and postoperative view for endoscopic TLIF underwent bilateral screw fixation. A: The C-shaped working channel was introduced to the intervertebral space under full-endoscopic guidance after the pedicle screws were inserted and the homemade intervertebral spreader was applied. B: Intraoperative C-arm film in anteroposterior view: the percutaneous pedicle screw system was inserted accurately and the interbody fusion cage was implanted under fluoroscopic guidance. C: Intraoperative C-arm film in lateral view: the percutaneous pedicle screw system and cage were inserted accurately. D: The C-shaped working channel and a converter. E: Endoscopic view of fully decompressed roots, the vertebral endplate after preparation and the fusion cage after implantation. F: Postoperative view of minute incision, the bar represents 10mm.

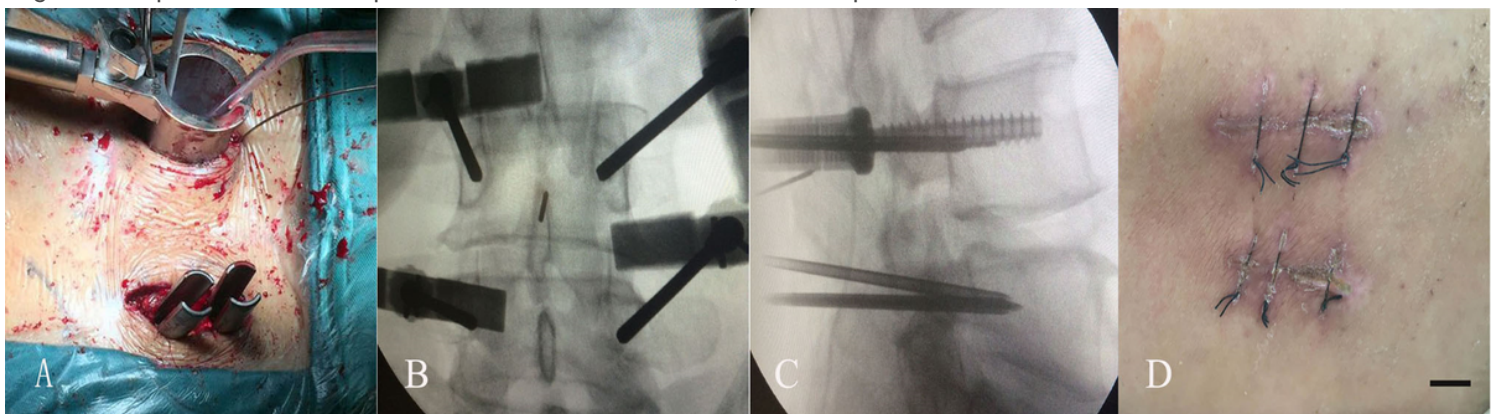


Figure 2

Intraoperative and postoperative view for unilateral MIS-TLIF underwent bilateral screw fixation. A: The tubular retractor was introduced to the facet joint under fluoroscopic guidance after the pedicle screws were inserted. B: Intraoperative C-arm film in anteroposterior view. The percutaneous pedicle screw system was inserted accurately. C: Intraoperative C-arm film in lateral view. The percutaneous pedicle screw system was inserted accurately. D: Postoperative view of minute incision, bar = 10 mm.

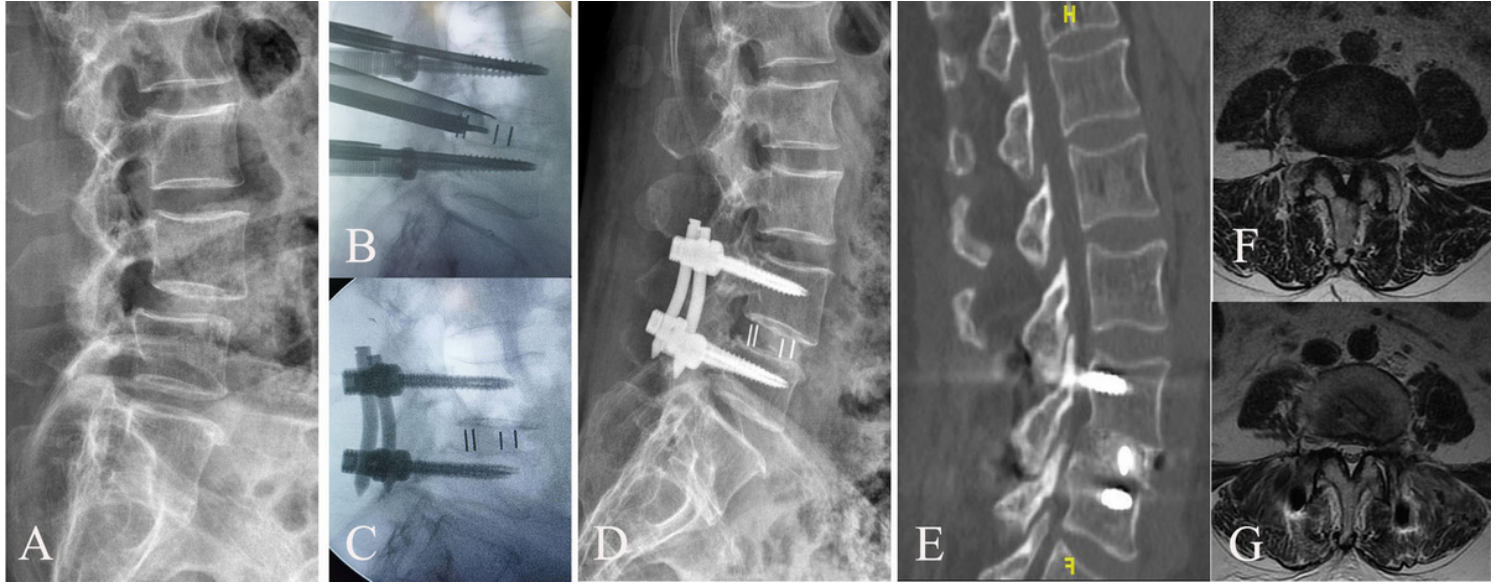


Figure 3

Images obtained in a 62-year-old female patient who complained of left-sided leg pain and LBP. A and F: The preoperative X and MRI scan showed L4-5 Grade I spondylolisthesis with left-sided migrated disc herniation. B: Fluoroscopic images showed the final implantation with a conventional cage and percutaneous pedicle screws. C: Postoperative lumbar spine lateral radiography at third day after Endo-TLIF surgery. D: Postoperative lumbar spine lateral radiography at 3 months demonstrated proper fusion and reduction of spondylolisthesis. E: Postoperative lumbar spine CT sagittal image at 1 year after surgery showed solid fusion. G: Axial MR image showed that spinal left-sided migrated disc herniation was completely removed after endoscopic TLIF surgery.

Supplementary Files

This is a list of supplementary files associated with this preprint. Click to download.

- [supplementaryfile1.docx](#)
- [Supplementaryfile3.doc](#)
- [supplementaryfile2.doc](#)