

Prospective, Randomised, Double-Masked Comparison of 0.1% Tacrolimus Ointment and 0.2% Olopatadine Eye Drops in the Treatment of Refractory Allergic Conjunctivitis

Shivananda Narayana

Aravind Eye Care System

Ashish Khodifad

Aravind Eye Care System

Bharat Gurnani (✉ drgumanibharat25@gmail.com)

Aravind Eye Care System <https://orcid.org/0000-0003-0848-5172>

Kirandeep Kaur



Aravind Eye Care System

Research Article

Keywords: Refractory, Allergic Conjunctivitis, Tacrolimus, Olopatadine

Posted Date: April 26th, 2021

DOI: <https://doi.org/10.21203/rs.3.rs-394712/v1>

License:   This work is licensed under a Creative Commons Attribution 4.0 International License. [Read Full License](#)

Abstract

Purpose- To analyse and compare the outcomes of topical tacrolimus 0.1% and 0.2 % olopatadine eye drops in refractory allergic conjunctivitis.

Methods- Prospective, double masked, randomized control trial conducted from January to December 2015 at a tertiary eye care centre with a follow up of 3 months. A total of 100 patients were enrolled. Fifty patients were allocated into the tacrolimus group (Group A) and olopatadine group (Group B) each. Detailed demographics, systemic history, uncorrected, best corrected visual acuity, intraocular pressure (IOP), anterior and posterior segment findings were recorded. Subjective symptoms and objective signs were recorded in the data forms at baseline and 1, 4, 8 & 12 weeks. The score of the worse eye was considered for analysis. On follow up, vision, IOP, side effects, objective signs and symptoms were recorded.

Results- Out of 100 patients, 4 were lost to follow up. The mean age in Group A was 18.63 ± 7.89 years and Group B was 17.21 ± 9.17 years. The M:F ratio was 1.5:1. Among 96 patients, 6 (6.66%) had allergic rhinitis and 3 (3.33%) were asthmatic. The mean sign score, symptom score, giant papillae score, palpebral conjunctival hyperaemia and bulbar conjunctival hyperaemia score was statistically significant between two groups. In Group A, 22.9% patients had punctate epithelial erosions while none had in Group B at 1 month follow up.

Conclusion- Topical tacrolimus 0.1% is safe and effective with minimal side effects. It should be considered for patients refractory to conventional treatment or requiring long term treatment, to avoid steroid related complications.

Introduction

Allergic conjunctivitis is a bilateral, allergic inflammation of the ocular surface, involving tarsal and/or bulbar conjunctiva. It is more common in children and young adults who have an atopic background. Although allergic conjunctivitis has traditionally been considered as a classical IgE-mediated disease (type I hypersensitivity), recent findings implicate more complex pathogenesis with particular involvement of T helper 2 (Th2) lymphocytes.^[1, 2, 3] Severe allergic conjunctival diseases (ACDs), such as atopic keratoconjunctivitis (AKC) and vernal keratoconjunctivitis (VKC), are occasionally complicated by keratopathy. Severe keratopathy, such as shield ulcer, is a serious pathological condition because it may result in reduced visual acuity. Keratopathy associated with severe ACD is primarily caused by histotoxic proteins produced by eosinophils which massively infiltrate giant papillae.^[4] For treatment of allergic conjunctivitis, a variety of medications have been used which include anti-histaminics, mast-cell stabilizers, and non-steroidal anti-inflammatory drugs. However, anti-allergic agents often have insufficient efficacy and long-term management is usually required. Topical steroids are the mainstay of treatment for moderate–severe forms of allergic conjunctivitis. However, some cases remain symptomatic despite treatment with topical steroids. Furthermore, prolonged use of steroids is associated with increased risk of ocular infections, cataract and glaucoma.^[5] A novel treatment for severe allergic conjunctivitis with potent anti-inflammatory action as well as sufficient safety is thus needed.

To avoid steroid related complications, immunomodulatory agents such as topical cyclosporine and tacrolimus have been used recently.^[6, 7, 8] Tacrolimus is a non-steroidal immunomodulator derived from *Streptomyces tsukubaensis*. Tacrolimus binds to FK506-binding proteins within T lymphocytes and inhibits calcineurin activity. Calcineurin inhibition suppresses dephosphorylation of the nuclear factor of activated T cells and its transfer into the nucleus, which results in suppressed formation of T helper 1 (Th1) cytokines (interleukin (IL)-2, interferon γ) and T helper 2 (Th2) cytokines (IL-4, IL-5).^[9] Tacrolimus has been reported to inhibit histamine release from mast cells and is thought

to alleviate symptoms.^[10] Topical tacrolimus with concentrations of 0.02–0.1% in ointment form has successfully been used for treatment of atopic keratoconjunctivitis (AKC), giant papillary conjunctivitis, and allergic conjunctivitis.^[11, 12, 13] However, there is paucity of literature regarding the outcome of tacrolimus in Indian setup. We conducted a prospective trial to evaluate the efficacy of tacrolimus ointment 0.1% in patients with severe allergic conjunctivitis refractory to conventional treatment.

Methodology

The study was a prospective double masked, randomized control trial done at the cornea clinic of our tertiary eye care centre from January to December 2015 with a follow up of 3 months. Informed consent was obtained from all the study participants. Study was approved by the ethics committee of the institutional review board (IRB). The study followed the tenets of declaration of Helsinki. This study included 100 patients who had symptomatic disease despite conventional treatment, that was defined as topical steroids (loteprednol 0.5% in tapering dose), and olopatadine (0.2% once a day) for 3 weeks or more. The inclusion criteria's were (1)Patients diagnosed with allergic conjunctivitis based on clinical signs and symptoms (2)Patient refractory to conventional treatment (3)Age > 5 years. The exclusion criteria's were (1)Patients with history of infectious eye disease (2)Pregnancy or lactating patients (3)Patients with known drug hypersensitivity (4)Patients with cardiac, hepatic, renal or pancreatic disease (5)Age < 5 years.

The diagnosis was based on history and clinical evaluation. Patients with ambiguous history regarding earlier treatment were first treated with conventional treatment for 3 weeks. The patients who were refractory to treatment were enrolled in the study. Eligible patients were randomized by simple randomization in a 1:1 ratio to the tacrolimus/olopatadine or olopatadine group. In group A, patients were treated with tacrolimus (0.1% thrice a day) and olopatadine (0.2% once a day). In group B, patients were treated with olopatadine (0.2% once a day) for 3 months. If topical corticosteroids, vasoconstrictors, and/or non-steroidal anti-inflammatory agents were used before enrolling in study, they were discontinued and switched to study drugs. Concomitant use of no other drugs for allergic conjunctivitis was allowed. Detailed demographic history, systemic history, uncorrected, best corrected visual acuity (VA), and Intraocular pressure (IOP) was recorded along with detailed anterior and posterior segment findings.

Objective signs and subjective symptoms were recorded in the data forms at baseline and 1, 4, 8 & 12 weeks after treatment initiation. Ten objective signs for the palpebral conjunctiva (hyperaemia, edema, follicles, papillae, and giant papillae), bulbar conjunctiva (hyperaemia and chemosis), limbus (Trantas' dot and edema), and corneal involvement were assessed using 4 grades (0 = Absent; 1 + = Mild; 2 + = Moderate; 3 + = Severe). The severity of 6 subjective symptoms (itching, discharge, lacrimation, eye pain, foreign body sensation, and photophobia) was also assessed using 4 grades (0 = Normal; 1 + = Mild; 2 + = Moderate; 3 + = Severe). The score of the worse eye was considered for analysis. On follow up, VA, IOP, side effects, objective signs and symptoms were recorded in data collection forms. Mean (SD) or Frequency (Percentage) was used to describe summary information. Student's t-test or paired t-test was used to assess the difference of continuous variable. Chi-square test was used to assess association between categorical variables. P-value less than 0.05 was considered as statistically significant. All statistical analysis was done by STATA 11.1 (Texas, USA).

Results

Out of 100 patients, 4 were lost to follow up. Overall the mean age of patients was 17.92 ± 8.54 years (range 6 to 35 years). The mean age in group A was 18.63 ± 7.89 years and group B was 17.21 ± 9.17 years. There were 58 males and 38 females with a M:F ratio of 1.5:1 (Fig. 1). Out of 96 patients 6 (6.66%) had allergic rhinitis and 3 (3.33%) were asthmatic. The baseline characteristics of the patients in 2 groups are as shown in Table 1.

Table 1
The baseline characteristics of the patients in the 2 groups are as shown.

Parameter	Tacrolimus + Olopatadine	Olopatadine	P value
Mean age	17.21 ± 9.17 years	18.63 ± 7.89 years	0.2908
Gender	28 Male 20 Female	30 Male 18 Female	
Systemic associations	Allergic rhinitis : 2 patients Asthma : 2 patient	Allergic rhinitis : 4 patients Asthma : 1 patient	
Mean baseline sign score	15.48 ± 4.65	14.54 ± 4.40	0.3126
Mean baseline symptom score	8.71 ± 3.48	8.27 ± 2.32	0.4710
Mean Baseline Sign + Symptom Score	24.19 ± 7.89	22.81 ± 6.63	0.3577

Table 2
A-Change in Symptoms Score

Timeline	Tacrolimus + Olopatadine Mean(SD) n = 48	Olopatadine Mean(SD) n = 48	P value
Baseline	8.71(3.48)	8.27(2.32)	0.4710
1 month	3.21(1.89)	6.27(2.18)	< 0.0001
2 month	2.29(1.43)	5.69(2.17)	< 0.0001
3 month	2.13(1.41)	5.29(1.91)	< 0.0001

Table 2
B- Change in Signs Score

Timeline	Tacrolimus + Olopatadine Mean(SD) n = 48	Olopatadine Mean(SD) n = 48	P value
Baseline	15.48(4.65)	14.54(4.40)	0.3126
1 month	7.33(1.94)	10.81(3.21)	< 0.0001
2 month	6.81(1.14)	9.67(2.84)	< 0.0001
3 month	6.40(0.94)	9.21(2.48)	< 0.0001

Considering change in symptom score, in group A, the mean symptom score at baseline, 1, 2 and 3 months was 8.71(3.48), 3.21(1.89), 2.29(1.43) and 2.13(1.41) respectively. In comparison in group B the mean symptom score at baseline, 1, 2 and 3 months was 8.27 (2.32), 6.27 (2.18), 5.69 (2.17) and 5.29 (1.91) respectively. The difference was

statistically significant between two groups from 1 to 3 months follow up (p value < 0.0001). The total score of 6 symptoms in 2 groups at baseline and follow-up is depicted in Table 2A (Fig. 2).

In group A, the mean sign score at baseline, 1, 2 and 3 months was 14.54(4.40), 10.81(3.21), 9.67(2.84) and 9.21(2.48) respectively. In group B the mean sign score at baseline, 1, 2 and 3 months was 15.48(4.65), 7.33(1.94), 6.81(1.14) and 6.40(0.94) respectively. The difference was statistically significant between two groups from 1 to 3 months follow up (p value < 0.0001). The total score of 10 clinical signs (0 to 30) in 2 groups at baseline and follow-up are described in Table 2B (Fig. 3).

The changes in giant papillae scores in both the groups at baseline and follow up are shown in Table 3. In Group A, the proportion of patients with score ≤ 1 giant papillae or no giant papillae at baseline was 37.5% which improved to 91.5% at 3 months. In Group B, the proportion of patients with score ≤ 1 at baseline was 52.1% which improved to 70.8% at 3 months. The difference between the two groups was statistically significant. (Fig. 4)

Table 3
Changes in Giant Papillae Score

Group	Tacrolimus + Olopatadine Group				Olopatadine Group			
	Baseline (n = 48)	1 month (n = 48)	2 month (n = 48)	3 month (n = 48)	Baseline (n = 48)	1 month (n = 48)	2 month (n = 48)	3 month (n = 48)
Score 0	4(8.3%)	23(47.9%)	23(47.9%)	23(47.9%)	16(33.3%)	11(22.9%)	12(25.0%)	12(25.0%)
Score 1	14(29.2%)	11(22.9%)	13(27.1%)	21(43.8%)	9(18.8%)	21(43.8%)	21(43.8%)	22(45.8%)
Score 2	17(35.4%)	14(29.2%)	12(25.0%)	4(8.3%)	13(27.1%)	12(25.0%)	16(33.3%)	13(27.1%)
Score 3	13(27.1%)	0	0	0	10(20.8%)	4(8.3%)	2(4.2%)	1(2.1%)

Table 4
A- Change in Palpebral Conjunctival Hyperaemia Score

Group	Tacrolimus + Olopatadine Group				Olopatadine Group			
	Baseline (n = 48)	1 month (n = 48)	2 month (n = 48)	3 month (n = 48)	Baseline (n = 48)	1 month (n = 48)	2 month (n = 48)	3 month (n = 48)
Score 0	0	22(45.8%)	20(41.7%)	15(31.3%)	0	7(14.6%)	6(12.5%)	7(14.6%)
Score 1	16(33.3%)	15(31.3%)	20(41.7%)	30(62.5%)	19(39.6%)	15(31.3%)	18(37.5%)	25(52.1%)
Score 2	18(37.5%)	11(22.9%)	8(16.7%)	3(6.3%)	15(31.3%)	20(41.7%)	23(47.9%)	15(31.3%)
Score 3	14(29.2%)	0	0	0	14(29.2%)	6(12.5%)	1(2.1%)	1(2.1%)

Table 4
B- Change in Bulbar conjunctival hyperaemia Score

Group	Tacrolimus + Olopatadine Group				Olopatadine Group			
	Baseline (n = 48)	1 month (n = 48)	2 month (n = 48)	3 month (n = 48)	Baseline (n = 48)	1 month (n = 48)	2 month (n = 48)	3 month (n = 48)
Score 0	9(18.8%)	23(47.9%)	22(45.8%)	24(50.0%)	11(22.9%)	11(22.9%)	12(25.0%)	12(25.0%)
Score 1	4(8.3%)	16(33.3%)	18(37.5%)	23(47.9%)	11(22.9%)	15(31.3%)	24(50.0%)	29(60.4%)
Score 2	25(52.1%)	9(18.8%)	8(16.7%)	1(2.1%)	20(41.7%)	16(33.3%)	11(22.9%)	6(12.5%)
Score 3	10(20.8%)	0	0	0	6(12.5%)	6(12.5%)	1(2.1%)	1(2.1%)

The proportion of patients with palpebral conjunctival hyperaemia and their severity grading in both the groups at baseline and follow up is shown in Table 4A. In Group A, the proportion of patients with mild or no palpebral conjunctival hyperaemia (score ≤ 1) at baseline was 33.3% which improved to 93.8% at 3 months. In Group B, the proportion of patients with score ≤ 1 at baseline was 39.6% which improved to 66.7% at 3 months. The difference between the two groups was statistically significant.

The proportion of patients with bulbar conjunctival hyperaemia and their severity grading in both the groups at baseline and follow up is shown in Table 4B. In Group A, the proportion of patients with mild or no bulbar conjunctival hyperaemia (score ≤ 1) at baseline was 27.1% which improved to 97.9% at 3 months. In Group B, the proportion of patients with score ≤ 1 at baseline was 45.8% which improved to 85.4% at 3 months. The difference between the two groups was statistically significant.

The proportion of patients with corneal involvement and their severity grading in both the groups at baseline and follow up is shown in Table 5. In Group A, the proportion of patients with punctate epithelial erosions (PEE's) (score = 1) at baseline was 58.3% which resolved in all the patients by 1 month. In Group B, the proportion of patients with score = 1 at baseline was 47.9% which decreased to 22.9% at 1 month and resolved in all the patients at 2 months.(Fig. 5)

Table 5
Change in Corneal involvement Score

Group	Olopatadine Group				Tacrolimus + Olopatadine Group			
	Baseline (n = 48)	1 month (n = 48)	2 month (n = 48)	3 month (n = 48)	Baseline (n = 48)	1 month (n = 48)	2 month (n = 48)	3 month (n = 48)
Score 0	20(41.7%)	48(100%)	48(100%)	48(100%)	25(52.1%)	37(77.1%)	48(100%)	48(100%)
Score 1	28(58.3%)	0	0	0	23(47.9%)	11(22.9%)	0	0
Score 2	0	0	0	0	0	0	0	0
Score 3	0	0	0	0	0	0	0	0

Discussion

The treatment of severe allergic conjunctivitis (VKC, AKC) is often challenging. These are usually young patients requiring long term treatment. Conventionally, steroids have been used as the mainstay of treatment for severe cases. Considering the young age of the patients and need for long term treatment, the use of steroids raises serious concerns. There is a need for potent steroid sparing therapy for treatment of such patients. Recently, some of the investigators have evaluated the role of tacrolimus in treatment of severe allergic conjunctivitis.^[14-17]

We found a significant improvement in the clinical sign score of patients treated with tacrolimus. In Group A, the mean sign score at baseline was 15.48 ± 4.65 which improved to 6.40 ± 0.94 at 3 months. The maximum improvement was noted in first month after initiation of treatment. In Group B, the mean sign score at baseline was 14.58 ± 4.40 , which improved to 9.21 ± 2.48 at 3 months. The difference between two treatment groups was clinically significant. These findings are similar to those reported by Fukushima et al^[15] and Ohashi et al.^[16] In study by Fukushima et al^[15] the mean total score of clinical signs was 15.3 ± 5.0 at the start of treatment and decreased to 5.9 ± 4.6 till last observation. Ohashi et al^[16] reported that mean change from baseline in total score for objective signs at end of treatment (1 month) was -5.6 ± 5.1 in the tacrolimus and -0.1 ± 4.5 in the placebo group.

With improvement in clinical signs, there was a parallel improvement in symptom score and total sign + symptom score of the patients. The mean symptom score in Group A at baseline was 8.71 ± 3.48 which improved to 2.13 ± 1.41 at 3 months. The mean symptom score in Group B improved from 8.27 ± 2.32 at baseline to 5.29 ± 1.91 at 3 months. The difference between the two groups was statistically significant. The mean sign + symptom score in Group A at baseline was 24.19 ± 7.89 which improved to 8.52 ± 1.94 at 3 months and in Group B improved from 22.81 ± 6.63 at baseline to 14.50 ± 4.17 at 3 months. The difference was again statistically significant. Fukushima et al^[15] reported that the total clinical symptom score decreased from 8.1 ± 4.5 at baseline to 1.8 ± 2.8 at the last observation (mean change -6.3). Ohashi et al^[16] also reported a significant improvement in symptoms of patients treated with tacrolimus, using VAS (Visual Assessment Scale) for evaluation of symptoms.

Severe allergic conjunctivitis is commonly associated with proliferative changes such as giant papillae. Vision-threatening keratopathy commonly develops in an adjacent location to the giant papillae. In this study, we found that giant papillae responded well to treatment with tacrolimus. In Group A, the proportion of patients with score ≤ 1 at baseline was 37.5% which improved to 91.5% at 3 months follow up. The proportion of patients with score ≥ 2 at baseline was 62.5% which decreased to 8.5% at 3 months follow up. In study by Fukushima et al^[15], 87.2% of patients had giant papillae at baseline, with 62.8% having active-stage giant papillae (score ≥ 2). At the time of last observation, only 15.8% patients had active-stage giant papillae, with alleviation of giant papillae (score ≤ 1) in 84.2% of patients. Ohashi et al^[16] reported that giant papillae became less inflamed and flattened, with profound decrease in ropy discharge, finally resulting in flat giant papillae in about 60% of patients and disappearance of giant papillae in 20%. Vichyanond et al^[17] reported that the mean size of tarsal papilla was significantly reduced with tacrolimus. In study by Kheirkhah et al^[14], mean giant papillae score at baseline was 1.10 ± 1.45 which decreased to 0.20 ± 0.42 at 1 month (p value ≥ 0.05). All the other investigators have reported an improvement in giant papillae in their studies. But the proportion of patients who had score ≤ 1 at 3 months was higher in our study as compared to other studies. The probable reason for this is that out of 48 patients in tacrolimus treated group, 36 (75%) had score ≤ 2 at baseline. Only 12(25%) patients had severe giant papillae (score = 3).

Severe allergic conjunctivitis may lead to corneal involvement (keratopathy) which may cause decreased vision. We found that patients with corneal signs responded well to tacrolimus. In Group A, 58.3% patients had corneal involvement at baseline which resolved in all patients at 1 month follow up. In group B, 47.9% patients had keratopathy (score = 1) at baseline. At 1 month, 22.9% patients still had corneal signs which resolved in all the patients at 2 months. Thus, mild corneal involvement responded well in both the groups but the improvement was earlier in group A.

Fukushima et al^[15] reported that Superficial punctate keratopathy (SPK) was seen in 67.8% of patients at baseline which decreased to 22.3% at last reading. In addition, the percentage of patients with a score ≥ 2 (large impact on VA) decreased from 41.3% at baseline to 6.7% at the final evaluation. Ohashi et al^[16] reported that corneal involvement significantly improved in the tacrolimus group compared with the placebo group from week 1 through week 4. No corneal epithelial disturbance was observed in 40.0% (10/25) of patients in the tacrolimus and 7.7% (2/26) in placebo group at end of treatment. In study by Kheirkhah et al^[14], mean score of corneal PEE's at baseline was 1.10 ± 1.20 which decreased to 0 at 1 month. They reported that in addition to conjunctival signs, limbal hypertrophy and corneal signs such as corneal PEE's, pannus, and to some degrees corneal stromal opacity showed improvement.

Conjunctival hyperaemia is an indicator of disease activity. In group A, the proportion of patients with palpebral conjunctival hyperaemia score ≤ 1 at baseline was 33.3% which improved to 93.8% at 3 months follow up. In group B, the proportion of patients with score ≤ 1 at baseline was 39.6% which improved to 66.7% at 3 months follow up. In group A, the proportion of patients with bulbar conjunctival hyperaemia score ≤ 1 at baseline was 27.1% which improved to 97.9% at 3 months. In group B, the proportion of patients with score ≤ 1 at baseline was 45.8% which improved to 85.4% at 3 months. There was a significant improvement in conjunctival hyperaemia in both groups. The response was better in group A. The difference between the 2 groups was statistically significant. These findings are similar to those reported by other investigators.

The common symptoms of severe allergic conjunctivitis are itching, watering and foreign body sensation. All these symptoms responded well in group A. In group A, the proportion of patients with minimal or no itching (Score ≤ 1) at baseline was 43.8%, which reached to 100% at 1 month follow-up. Similarly, the proportion of patients with minimal or no watering (Score ≤ 1) at baseline was 4.2%, which improved to 100% at 1 month follow-up. The proportion of patients with minimal or no foreign body sensation (Score ≤ 1) at baseline was 33.3%, which reached to 91.7% at 1 month and 100% at 2 months. The improvement in symptoms paralleled the improvement in clinical signs. These findings are similar to those reported by other researchers.

The side effects reported with the use of tacrolimus include burning sensation, irritation, lacrimation, corneal infections (viral, bacterial), lid infections (hordeolum, herpes, molluscum), conjunctival hyperaemia, foreign body sensation, pruritis, pain. In our study, 6.3% patients in group A complained of burning sensation. No other side effects were noted. No rise in IOP was noted. Fukushima et al^[15] reported side effects in 8.15% patients, which included burning sensation (3.2%), irritation (3.27%) and corneal infections (0.28%) patients. Ohashi et al^[16] reported ocular irritation in 42.9% (12/28 patients) and herpetic keratitis in 1 patient (3.5%). Kheirkhah et al^[14] reported no significant side effects with topical tacrolimus. Vichyanond et al^[17] reported transient eye stinging (7 patients) and 1 patient had infectious conjunctivitis, which responded satisfactorily to topical antibiotics. They explained that low concentration of the medication and no additional compound other than balanced salt solution in their preparation may be the reason for this. Corneal infections though uncommon are a serious side effect of topical tacrolimus which must always be considered.

In our study, all the patients enrolled had no response to topical steroids. All patients responded well to tacrolimus plus olopatadine treatment. No serious side effects were noted on treatment with tacrolimus. Thus, tacrolimus can be considered as an option for replacement of steroids in refractory cases or those requiring long term treatment. The strengths of the study are randomized control trial, larger sample size compared to previous studies and it gives insights into outcome of tacrolimus in refractory allergic conjunctivitis in Indian setup. Few of the limitations are modest duration (3 months) of follow up and lack of cases with severe corneal involvement so that outcomes of tacrolimus in patients with severe corneal involvement could not be studied satisfactorily.

Conclusion

This study suggests that topical tacrolimus 0.1% is safe and effective in treatment of severe allergic conjunctivitis patients with minimal side effects. It should be considered for treatment of patients refractory to conventional treatment or patients requiring long term treatment, to avoid steroid related complications. The possibility of corneal infection should always be considered while treating the patient with tacrolimus. A larger scale study with longer follow up duration would validate the findings further.

Declarations

Acknowledgement Aravind Eye Hospital and Post Graduate Institute of Ophthalmology, Cuddalore main road, Thavalukuppam, Pondicherry, India, 605007

Proprietary interest statement- Nil

Conflicts of interest- There are no conflicts of interest

Disclosure of any funding received for this work – None

Name and postal address of corresponding author –

Dr Bharat Gurnani-

MBBS,DNB, FCRS, FICO(2)

Consultant Cornea and Refractive Services,

Aravind Eye Hospital and Post Graduate Institute of Ophthalmology,

Pondicherry , India.605007

Email -drgurnanibharat25@gmail.com

Declaration of patient consent

The authors certify that they have obtained all appropriate patient consent forms. In the form the patient (s) has/have given his/her/their consent for his/her/their images and other clinical information to be reported in the journal. The patients understand that their names and initials will not be published and due efforts will be made to conceal their identity, but anonymity cannot be guaranteed

Financial support and sponsorship

Nil.

Conflicts of interest

There are no conflicts of interest.

References

1. Bielory L, Frohman LP. Allergic and immunologic disorders of the eye. *J Allergy Clin Immunol* 1992; 89(1 Part 1): 1–15.
2. Leonardi A, Motterle L, Bortolotti M. Allergy and the eye. *Clin Exp Immunol* 2008;1:17-21.
3. Tabbara KF. Ocular complications of vernal keratoconjunctivitis. *Can J Ophthalmol* 1999;34:88-92.
4. Takamura E, Ebihara N, et al. Japanese guideline for allergic conjunctival diseases. *Allergol Int* 2011;60:191-203.
5. Bonini S, Lambiase A, Marchi S, Pasqualetti P, Zuccaro O et al. Vernal keratoconjunctivitis revisited: a case series of 195 patients with long-term follow-up. *Ophthalmology* 2000; 107(6): 1157–1163.
6. BenEzra D, Pe'er J, Brodsky M, Cohen E. Cyclosporine eye drops for the treatment of severe vernal keratoconjunctivitis. *Am J Ophthalmol* 1986; 101(3): 278–282.
7. Secchi AG, Tognon MS, Leonardi A. Topical use of cyclosporine in the treatment of vernal keratoconjunctivitis. *Am J Ophthalmol* 1990; 110(6): 641–645.
8. Bleik JH, Tabbara KF. Topical cyclosporine in vernal keratoconjunctivitis. *Ophthalmology* 1991; 98(11): 1679–1684.
9. Sakuma S, Higashi Y, Sato N, et al. Tacrolimus suppressed the production of cytokines involved in atopic dermatitis by direct stimulation of human PBMC system. (Comparison with steroids) *Int immunopharmacol* 2001;1:1219-26.
10. Zhai J, Gu J, Yuan J, et al. Tacrolimus on the treatment of ocular diseases. *Biodrugs* 2011;25:89–103.
11. Rikkers SM, Holland GN, Drayton GE, Michel FK, Torres MF, Takahashi S. Topical tacrolimus treatment of atopic eyelid disease. *Am J Ophthalmol* 2003; 135(3):297–302.
12. Virtanen HM, Reitamo S, Kari M, Kari O. Effect of 0.03% tacrolimus ointment on conjunctival cytology in patients with severe atopic blepharoconjunctivitis: a retrospective study. *Acta Ophthalmol Scand* 2006; 84(5): 693–695.
13. Zribi H, Descamps V, Hoang-Xuan T, Crickx B, Doan S. Dramatic improvement of atopic keratoconjunctivitis after topical treatment with tacrolimus ointment restricted to the eyelids. *J Eur Acad Dermatol Venereol* 2009; 23(4): 489–490
14. Kheirkhah A, Zavareh MK, Farzbod F, Mahbod M, Behrouz MJ. Topical 0.005% tacrolimus eye drop for refractory vernal keratoconjunctivitis. *Eye (Lond)*. 2011 Jul;25(7):872-80.
15. Fukushima A, Ohashi Y, Ebihara N, Uchio E, Okamoto S, Kumagai N, Shoji J, Takamura E, Nakagawa Y, Namba K, Fujishima H, Miyazaki D. Therapeutic effects of 0.1% tacrolimus eye drops for refractory allergic ocular diseases with proliferative lesion or corneal involvement. *Br J Ophthalmol*. 2014 Aug;98(8):1023-7.
16. Ohashi Y, Ebihara N, Fujishima H, Fukushima A, Kumagai N, Nakagawa Y, Namba K, Okamoto S, Shoji J, Takamura E, Hayashi K. A randomized, placebo-controlled clinical trial of tacrolimus ophthalmic suspension 0.1% in severe allergic conjunctivitis. *J Ocul Pharmacol Ther*. 2010 Apr;26(2):165-74.
17. Vichyanond P, Tantimongkolsuk C, Dumrongkigchaiporn P, Jirapongsananuruk O, Visitsunthorn N, Kosrirukvongs P. Vernal keratoconjunctivitis: Result of a novel therapy with 0.1% topical ophthalmic FK-506 ointment. *J Allergy Clin Immunol*. 2004 Feb;113(2):355-8.

Figures

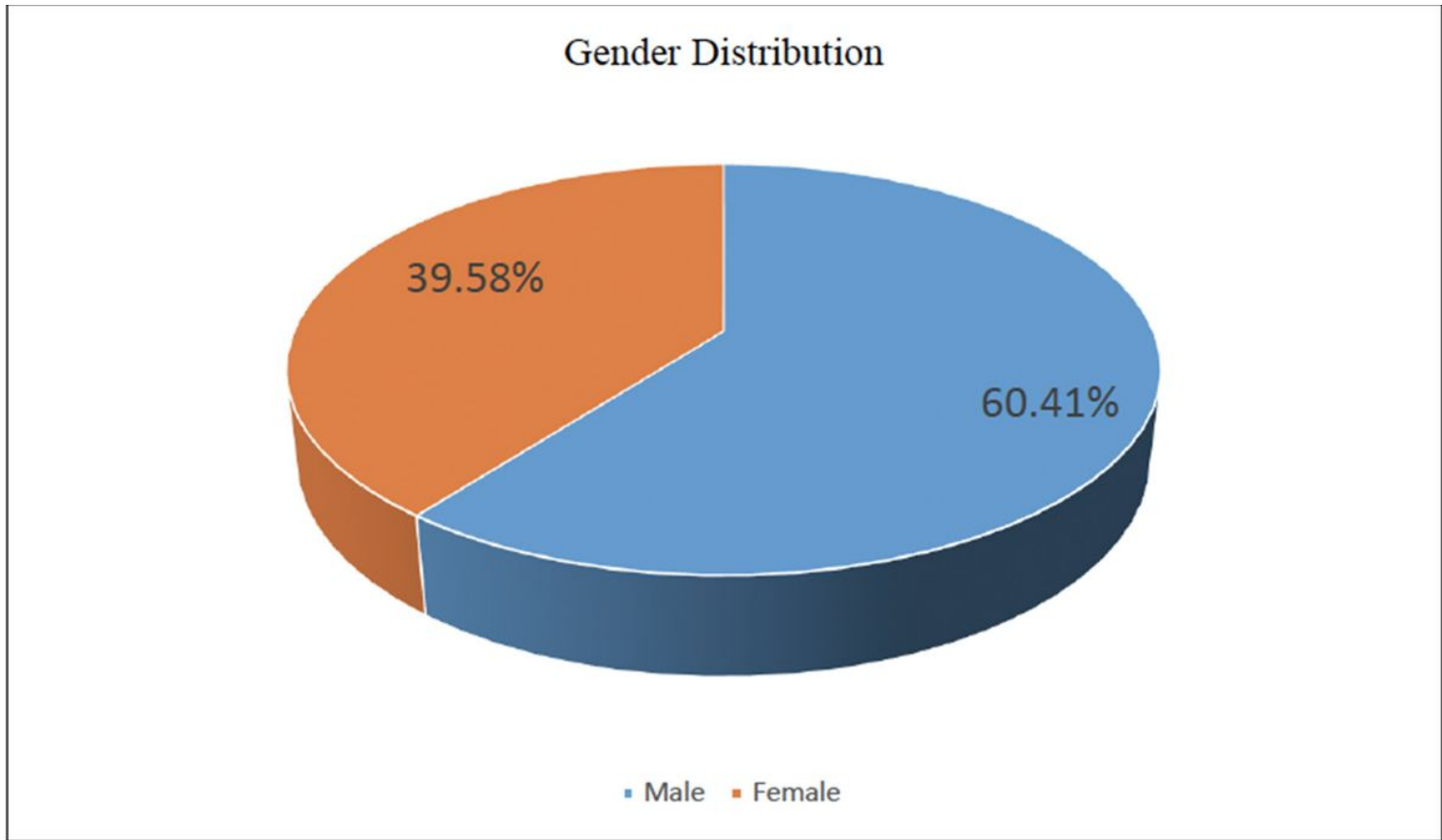


Figure 1

Pie chart depicting gender distribution of patients enrolled in study.

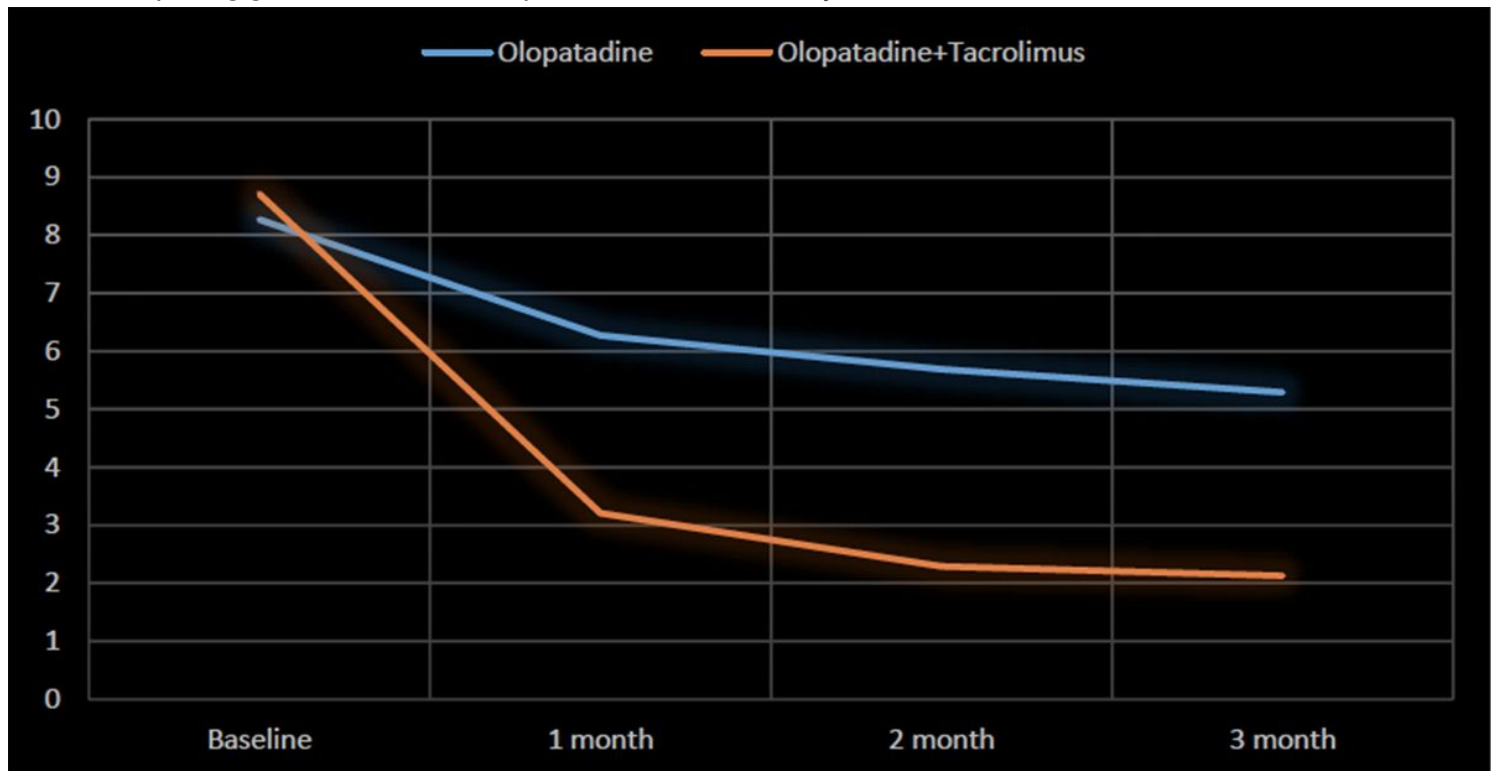


Figure 2

Line graph depicting Mean clinical symptoms score in 2 groups at baseline and follow-up.

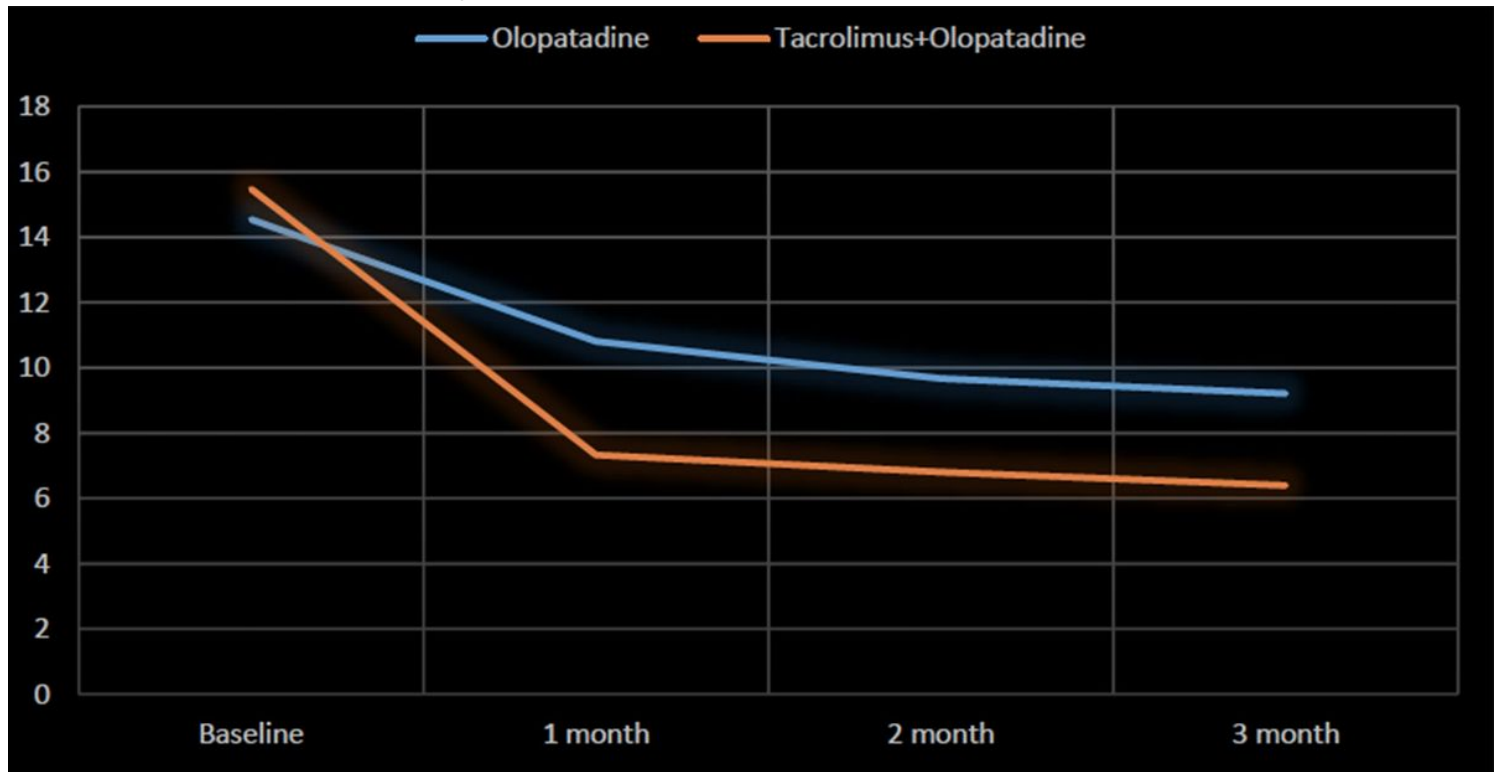


Figure 3

Line graph depicting change in mean clinical sign score in 2 groups over follow-up period of 3 months.

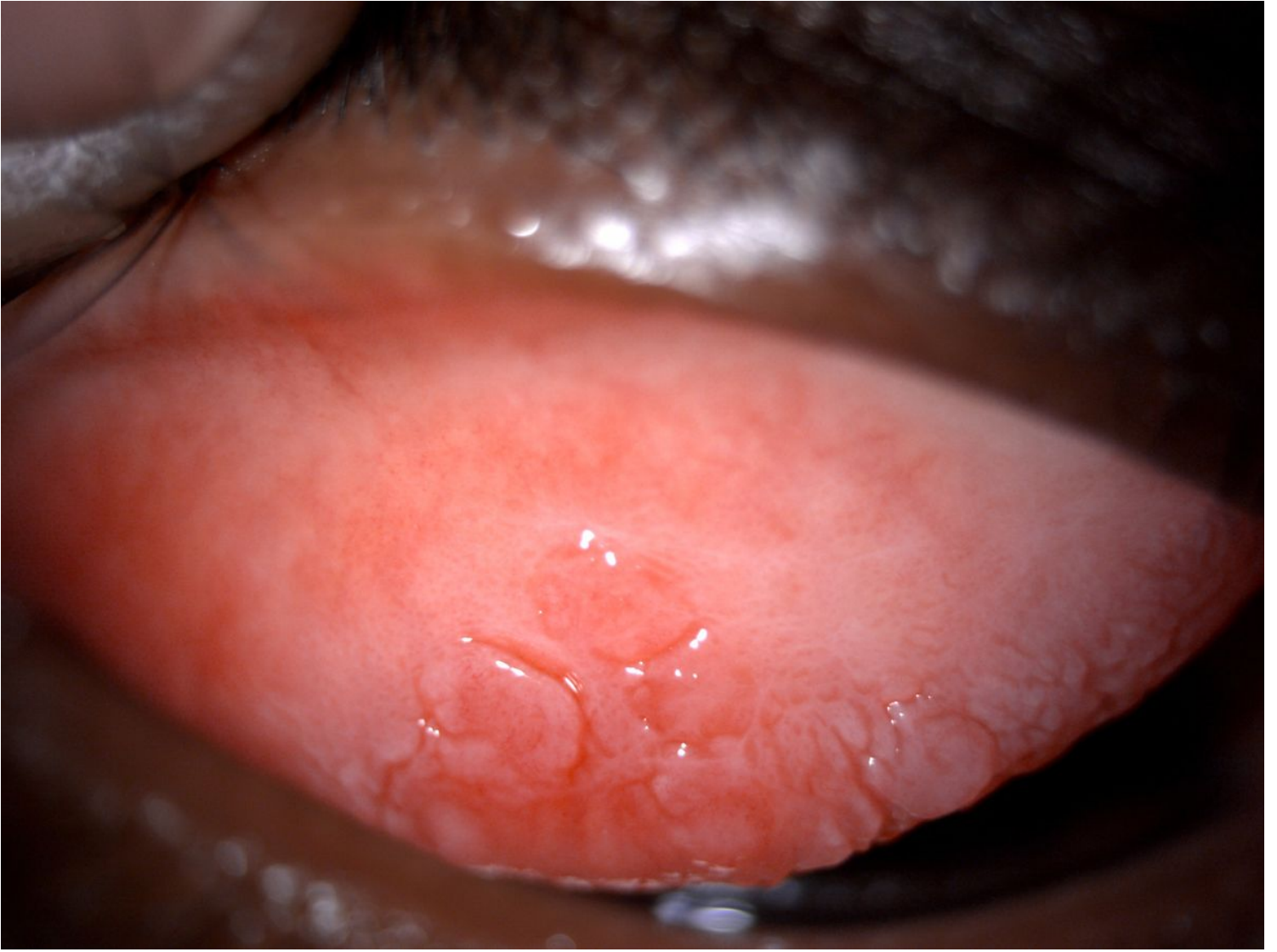

Figure 4

Slit lamp depicting giant papillae with palpebral conjunctival hyperaemia and edema

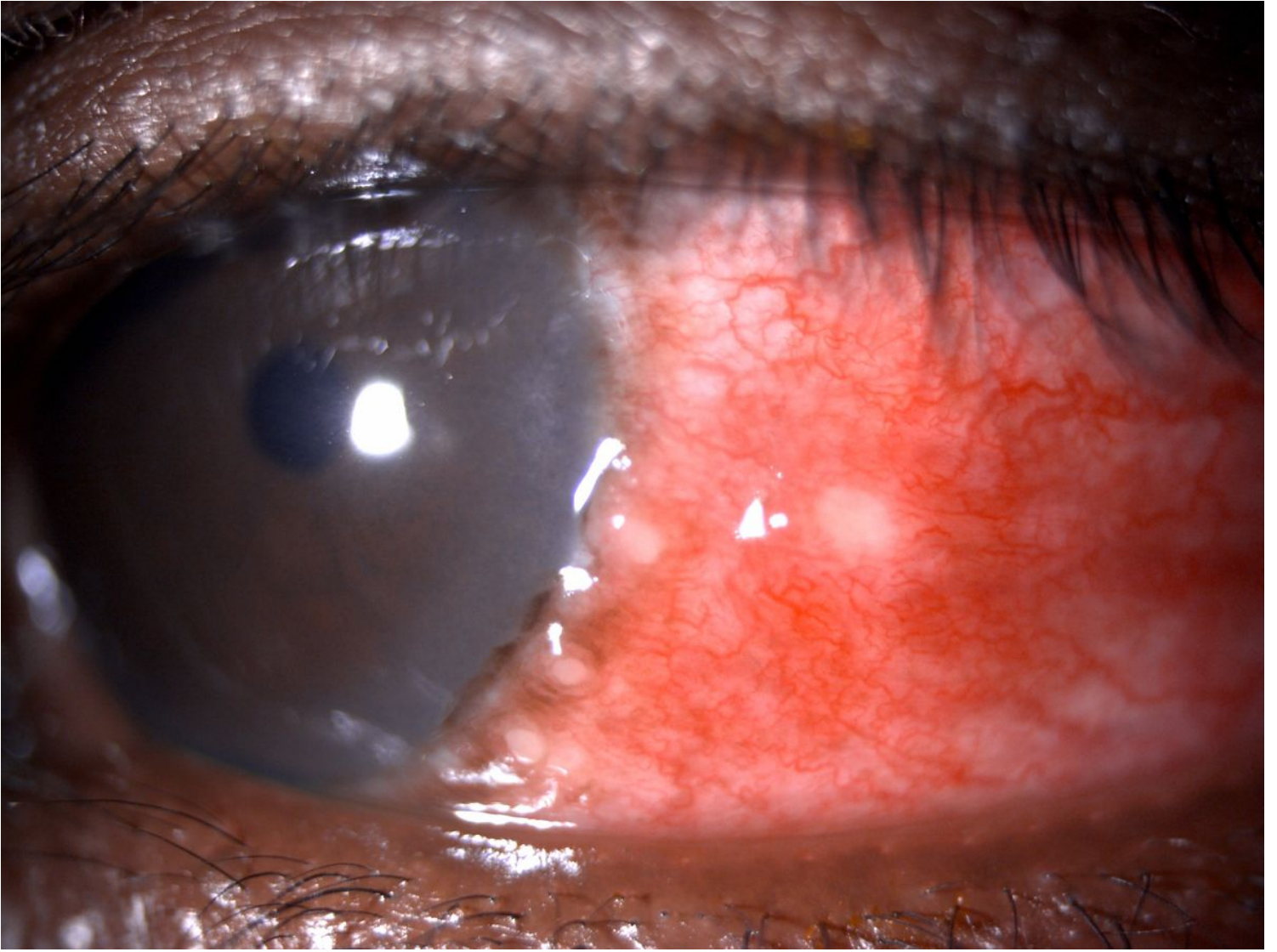

Figure 5

Slit lamp image depicting limbal thickening and Horner Trantas spots