

Development of a Prognostic Score for Recommended TACE Candidates with Hepatocellular Carcinoma Spontaneous Rupture

Jixue Zou

Liver cancer institute, Zhongshan hospital, Fudan university

Jia Yuan

Liver Cancer Institute, Zhongshan Hospital, Fudan University

Xinghao Zhou

Liver Cancer Institute, Zhongshan Hospital, Fudan University

Tongchun Xue

Liver Cancer Institute, Zhongshan Hospital, Fudan University

Rongxin Chen

Liver Cancer Institute, Zhongshan Hospital, Fudan University

Lan Zhang (✉ 13918876432@163.com)

Zhenggang Ren

Liver Cancer Institute, Zhongshan Hospital, Fudan University

Research

Keywords: hepatocellular carcinoma, spontaneously rupture, transarterial chemoembolization, nomogram

Posted Date: July 1st, 2020

DOI: <https://doi.org/10.21203/rs.3.rs-39216/v1>

License:  This work is licensed under a Creative Commons Attribution 4.0 International License.

[Read Full License](#)

Abstract

Background: Although transarterial chemoembolization (TACE) has been widely used for spontaneously ruptured hepatocellular carcinoma (HCC), no existing models can be used for survival prediction. Thus, the aim of the present study was to develop and validate a nomogram for risk prediction of HCC rupture after TACE treatment.

Methods: The medical records of patients who underwent transarterial chemoembolization therapy from January 2015 to April 2019 at our Hospital were retrospectively screened. HCC was diagnosed by either imaging or histological evaluation according to the AASLD guideline. Factors that were found to be significant in univariate analysis were subjected to multivariate analysis. Factors in the nomogram were identified by multivariate Cox hazard analysis. The concordance index was calculated.

Results: This study consisted of 55 patients with spontaneously ruptured HCC receiving TACE at our center from January 2015 to April 2019. The median overall survival was 6.4 months, with 0.5-year and 1-year survival being 52.7% and 41.8%, respectively. In univariate analysis, largest tumor size, total bilirubin level, and aspartate aminotransferase level were associated with overall survival. Multivariate analysis suggested that total bilirubin level and the max diameter of the tumors were independent prognostic factors to predict overall survival. Based on these variables, we developed and validated a nomogram for individual patient risk stratification of HCC rupture after TACE treatment. The concordance index for overall survival prediction was 0.748 (95% CI: 0.691-0.805).

Conclusions: Based on the nomogram, we have provided an intuitive tool for estimating the prediction of ruptured HCC patients. This study may help to improve the perioperative strategy and treatment outcome.

Introduction

One of the life-threatening complications of hepatocellular carcinoma (HCC) is the spontaneous rupture of the tumor and intratumoral hemorrhage. Several studies have indicated that emergency hepatectomy and Transarterial chemoembolization (TACE) are the main treatments of patients with HCC rupture[1–3]. Hepatectomy is an effective therapy for the treatment of tumor rupture[4]. However, severe cirrhosis or poor hepatic function usually reduce the tolerance of patients to surgical hepatic resection. TACE as a less invasive operation has been widely used for unresectable HCC.

Several studies have reported a promising outcome following TACE treatment in spontaneously ruptured HCC patients[5–7]. However, the timing of TACE and prognosis are affected by several determinants such as age, Barcelona Clinic Liver Cancer (BCLC) staging system, Child-Pugh score, maximum tumor size, and extrahepatic invasion[8]. Considering these associated risk factors, accurate predicting outcome tools and taking operation in time may be most effective for HCC patients with spontaneous rupture. Nevertheless, there were very few studies have investigated the predictive factors associated with this life-

threatening complication of HCC. Moreover, there are no existing models or guidelines that can help making decisions about whether it is appropriate to have a TACE treatment.

Individualized prediction has been considered as necessary for an optimal prognostic model. A predictive nomogram might make a different decision for HCC ruptured patients who might take TACE treatment. However, to our knowledge, there is no study using nomogram model on this issue. Thus, the aim of the present study was to analyze the risk factors associated with overall survival of ruptured HCC patients with TACE treatment. Moreover, this study developed and validated a nomogram model based on widely available pretreatment clinical and laboratory data for risk prediction of ruptured hepatocellular carcinoma.

Methods

Patients

The medical records of HCC patients with spontaneous tumor rupture were retrospectively screened. These patients underwent transarterial chemoembolization therapy from January 2015 to April 2019 at the Department of Hepatic Carcinoma of Fudan University Affiliated Zhongshan Hospital (Shanghai, China). We reviewed clinical data, such as age, gender, clinical presentation, and disease history. The results of laboratory examinations at diagnosis were also reviewed. HCC tumor status including tumor number, tumor extent size, the presence of portal vein thrombosis and distant metastasis were obtained by contrast-enhanced computed tomography (CT) or magnetic resonance imaging (MRI) scans.

HCC was diagnosed by imaging or histological evaluation according to the American Association for the Study of Liver Diseases (AASLD) guideline[9]. No HCC treatment within 1 month prior to the diagnosis of HCC rupture was accepted within the subjects. All patients were staged according to the BCLC staging system[10]. Diagnosis of spontaneous HCC rupture was based on disruption of the peritumoral liver capsule with surrounding fluid in the perihepatic region. These were detected by dynamic CT and abdominal puncture, which showed the presence of bloody fluid in the abdomen. The present study was approved by the Clinical Research Ethics Committee of Fudan University Affiliated Zhongshan Hospital.

Treatment procedures

Under the guidance of digital subtraction angiography (DSA), TACE was performed through femoral artery puncture using the Seldinger technique. Based on the tumor number, size and the degree of hemorrhage, 5–20 ml lipiodol mixed with epirubicin suspension and gelatin sponge fragments or granules was injected into the tumor-feeding arteries under the guidance of digital subtraction angiography by a catheter. Then, 100–150 mg oxaliplatin or 5-fluorouracil was slowly perfused into the feeding artery according to the body weight and liver function status of patients. Finally, post-embolization angiography was performed to determine the extent of embolization.

Statistical analysis

Categorical data was expressed as frequencies and percentages and was analyzed with the chi-square test or Fisher exact test. Continuous variables were expressed as medians and ranges and were analyzed using the independent sample t-test. Overall survival (OS) rates were estimated using the Kaplan–Meier method. Factors that were found to be significant in univariate analysis (p values less than 0.1) were subjected to multivariate analysis. Factors in the nomogram were identified by multivariate Cox hazard analysis. The concordance index was calculated. Statistical analyses were performed using the SPSS 21.0 software. Statistical analyses of the nomogram were performed using the R software version 3.2.0. The difference was considered as statistically significant for p values less than 0.05.

Results

Baseline characteristics

Between January 2015 and April 2019, 55 patients with spontaneously ruptured HCC underwent transarterial chemoembolization therapy were retrospectively reviewed. Of these, 47 were men and 8 were women. The median age was 55 years old (range 28–86 years) (Table 1). There were 42 men and 13 women. Hepatitis B virus (HBV) infection was the main aetiology of HCC (49, 89.0%). Only one patient exhibited Hepatitis C virus (HCV) infection. A total of 23 (41.8%) patients presented with a tumor number of more than 2, whereas 32 (58.2%) patients presented with a single tumor. The Child-Pugh classification indicated that 19 (34.5%) patients were included in class A, 28 (50.9%) in class B and 8 (14.5%) in class C. There were 28 (50.9%) patients were in BCLC B stage and 27 (49.1%) patients were in BCLC C stage respectively. There was no patient in BCLC A stage at diagnosis in our study. Vascular invasion was observed in 21 (38.2%) patients. Distant metastasis was found in 14 (25.5%) patients.

Table 1
Clinical characteristics of spontaneously ruptured HCC patients.

| Variables | Cases (%) |
|--|--------------------------------------|
| Age over 60 years | 22 (40.0%) |
| Hypertension history | 18(32.7%) |
| Child Pugh: A / B / C | 19 (34.5%) / 28 (50.9%) / 8 (14.5%) |
| AFP > 400 ng/L | 33(60.0%) |
| ALT > 120 U/L(3N) | 12(21.8%) |
| AST > 120U/L(3N) | 27(49.1%) |
| TBIL > 30umol/L(1.5N) | 13(23.6%) |
| ALB ≤ 35 g/L | 24(43.6%) |
| PT > 16 s | 7(12.7%) |
| Hb (g/L) > 90 / 90 – 60/<60 | 21 (38.2%)/ 30 (54.5%) / 4 (7.3%) |
| Scr > 1.5 N | 2(3.6%) |
| Positive HBsAg/HCV Ab status | 49 (89.0%)/1(1.8%) |
| Maximum tumor size (cm): ≤5/>5 and ≤ 10/>10 | 11 (20.0%) / 26 (47.3%) / 18 (32.7%) |
| Tumor number: single/multiple | 23 (41.8%) / 32 (58.2%) |
| Capsule formation: Yes/No | 25 (45.5%)/30 (54.5%) |
| Vascular thrombus: Yes/No | 21 (38.2%) / 34 (61.8%) |
| Extrahepatic invasion: Yes/No | 14 (25.5%) / 41 (74.5%) |
| BCLC stage : A / B/ C | 0 (0%) /28 (50.9%) / 27 (49.1%) |
| AFP: alpha-fetoprotein; N: normal level; ALT: alanine aminotransferase; AST: aspartate aminotransferase; TBIL: total bilirubin; ALB: albumin; PT: prothrombin time; Hb: hemoglobin; Scr: serum creatinine; HbsAg: hepatitis B surface antigen; HCV: Hepatitis C virus; BCLC: Barcelona Clinic Liver Cancer | |

Overall survival

The median follow-up was 23.0 months (range 11.8–40.1 months). The median overall survival was 6.4 months, with 0.5-year and 1-year survival being 52.7% and 41.8%, respectively.

Univariate and multivariate analysis

Univariate analyses showed that largest tumor size, total bilirubin level, and aspartate aminotransferase (AST) were associated with overall survival ($p < 0.1$, Table 2). The multivariate Cox regression analysis suggested that largest tumor diameter ($P = 0.044$) and total bilirubin level ($P = 0.036$) were independent prognostic factors to predict overall survival (Table 3).

Table 2
Univariate analysis of factors related with overall survival

| Factors | P value |
|-----------------------|---------|
| Hypertension history | 0.826 |
| Child Pugh score | 0.164 |
| AFP > 400 ng/L | 0.533 |
| ALT > 3N | 0.336 |
| AST > 3N | 0.045 |
| TBIL > 1.5N | 0.001 |
| Maximum tumor size | 0.002 |
| Vascular thrombus | 0.446 |
| Extrahepatic invasion | 0.231 |
| BCLC stage | 0.108 |

AFP: alpha-fetoprotein; N: normal level; ALT: alanine aminotransferase; AST: aspartate aminotransferase; TBIL: total bilirubin; BCLC: Barcelona Clinic Liver Cancer

Table 3
Multivariate analysis of factors related with overall survival

| Factors | HR | 95% C.I. | P value |
|----------------------------|-------|-------------|---------|
| TBIL \geq 30 μ mol/L | 0.358 | 0.137–0.934 | 0.036 |
| Maximum tumor size | 1.012 | 1.000–1.025 | 0.044 |
| AST | 1.560 | 0.641–3.794 | 0.327 |

HR: hazard ratios; C.I.: confidence interval; TBIL: total bilirubin; AST: aspartate aminotransferase

Development of the risk score model

A nomogram for individual patient risk stratification was created based on 2 clinically detectable preoperative parameters: Largest tumor diameter and total bilirubin level (Fig. 1). Largest tumor diameter was treated as a continuous variable and total bilirubin level ($> 30\mu\text{mol/L}$, and $\leq 30\mu\text{mol/L}$) was treated as a categorical factor.

The 1-year and 2-year survival probability of individual patient could be predicted before the TACE procedure with the total points of largest tumor size and total bilirubin level (Fig. 2). The C-index of the nomogram for OS prediction was 0.748 (95% CI: 0.691–0.805).

Discussion

Spontaneous rupture of HCC is one of the most common and lethal complications in liver emergencies[11]. Previous studies have shown a very poor prognosis because of various degrees of complications with HCC rupture, such as hypovolemic shock, acute hepatic or renal failure, and recurrent tumor rupture[12, 13].

Several studies have indicated that emergency hepatectomy and TACE are the main treatments of patients with HCC rupture[14–17]. As ruptured HCC always accompanied with coagulopathy or poor liver function, only a limited number of patients can tolerate surgical hepatic resection[18, 19]. Several studies have reported that TACE can be effective for patients with HCC rupture and achieves immediate hemostasis[7, 20]. Kim and colleagues reported that TACE effectively achieved hemodynamic stability and increased the 30-day survival in patients with a ruptured HCC[6]. Byung Seok Shin et al[5] reported an overall median survival time of 179.6 days in patients with ruptured HCC and the 3-month, 6-month, and 12-month survival rates were 54%, 48%, and 43%, respectively. Similar to their study, we found the median overall survival of HCC rupture patients was 6.4 months (192 days), with 0.5-year and 1-year survival being 52.7% and 41.8%, respectively.

To improve our understanding of HCC rupture, several researchers have investigated the possible predictive factors. Shin et al[5] revealed that higher blood transfusion requirement, Child-Pugh class C, presence of portal vein thrombosis, and tumors involving both lobes were significant predictors of poor survival. However, in Shin's study, there were no significance of total bilirubin level, which was an independent prognostic factor for overall survival in our study. The reason of the difference may be that their subjects were all having a serum bilirubin level $< 3.0\text{ mg/dL}$. Kam-Ho Lee et al[21] also reported that bilirubin level was associated with early mortality in patients with spontaneous rupture of HCC following hemostasis by emergency transarterial embolization. Kirikoshi et al[22] revealed that a maximum tumor size exceeding 7 cm was the only independent factor determining long-term survival in patients with initial TACE successfully performed after spontaneous HCC rupture. However, in our study, there were no significance of largest tumor diameter over 7 cm on the survival rate, as determined by multivariate analysis. In the present study, the endpoint of maximum tumor size over 10 cm was determined to be an independent predictor of survival rate. This discrepancy may be associated with the different follow up

time and the different baseline characteristics of the subjects. Additional investigations are required to address this discrepancy.

A prognostic score system could facilitate clinical counseling and guide doctor's treatment and follow-up plans. In recent years, an increasing number of nomograms have been used in cancer and other fields[23–25]. The nomograms are easy and convenient, highly accurate, and can help to make more suitable clinical decisions. Qiuhe Wang et al[26] developed a six-and-twelve score that can predict individual outcome with prognostic model for recommended or ideal TACE candidates with hepatocellular carcinoma. Although TACE has been widely used for spontaneously ruptured HCC, no existing models can be used for survival prediction. In the present study, we developed and validated a nomogram for risk prediction of HCC rupture after TACE treatment. And our study was the first investigation that this nomogram was applied in HCC rupture and TACE risk. Moreover, the C-index of this nomogram for OS prediction was 0.748 (95% CI: 0.691–0.805). The C-index in the interval validation indicated that this nomogram can be widely and accurately used. Based on the nomogram, we have provided an easy-to-used tool for predicting OS of ruptured HCC patients. With an estimate of individual risk, clinicians are able to make more suitable decisions on HCC rupture treatment. However, this nomogram requires external validation, and a larger sample size is needed to determine whether the nomogram is suitable for predicting TACE in HCC ruptured patients. Multicenter research may further improve and validate it.

Conclusions:

Our results indicated that largest tumor diameter and total bilirubin level were independent prognostic factors to predict overall survival of ruptured HCC patients. The present study developed a novel nomogram with a relatively good accuracy to estimate the prediction in ruptured HCC patients when starting TACE treatment. This study may help to improve the perioperative strategy and treatment outcome.

Abbreviations

TACE: transarterial chemoembolization; HCC: hepatocellular carcinoma; BCLC: Barcelona Clinic Liver Cancer; CT: contrast-enhanced computed tomography; MRI: magnetic resonance imaging; AASLD: American Association for the Study of Liver Diseases; OS: Overall survival; DSA: digital subtraction angiography; AFP: alpha-fetoprotein; N: normal level; ALT: alanine aminotransferase; AST: aspartate aminotransferase; TBIL: total bilirubin; ALB: albumin; PT: prothrombin time; Hb: hemoglobin; Scr: serum creatinine; HbsAg: hepatitis B surface antigen; HBV: Hepatitis B virus; HCV: Hepatitis C virus; HR: hazard ratios; C.I.: confidence interval

Declarations

Authors' contributions

JZ participated in the acquisition, analysis, and interpretation of data, as well as in the manuscript drafting; JY and XZ participated in data acquisition and manuscript drafting; TX and RC contributed to the conception, design, and data interpretation; LZ and ZR conceived of the presented idea, as well as revised the manuscript for important intellectual content. All authors read and approved the final manuscript.

Funding

The present study was supported by the Young Scientists Fund of the National Natural Science Foundation of China (grant nos. 81702310 and 81502007) and Outstanding Youth Science Foundation of Zhongshan Hospital (2019ZSYXQN22).

Acknowledgements

Not applicable.

Availability of data and materials

The datasets used and/or analyzed during the current study are available from the corresponding author on reasonable request.

Ethics approval and consent to participate

All procedures followed were in accordance with the ethical standards of the responsible committee on human experimentation (institutional and national) and with the Helsinki Declaration of 1964 and later versions. The retrospective study was approved by the Clinical Research Ethics Committee of Fudan University Affiliated Zhongshan Hospital. The informed consent requirement was waved.

Consent for publication

Not applicable.

Competing interests

The authors declare that they have no competing interests.

References

1. Zhu Q, Qiao GL, Xu C, Guo DL, Tang J, et al. Partial hepatectomy for spontaneous tumor rupture in patients with hepatocellular carcinoma: a retrospective cohort study. *Cancer Manag Res.* 2017;9:525-537.
2. Wu JJ, Zhu P, Zhang ZG, Zhang BX, Shu C, et al. Spontaneous rupture of hepatocellular carcinoma: Optimal timing of partial hepatectomy. *Eur J Surg Oncol.* 2019;45:1887-1894.
3. Jin YJ, Lee JW, Park SW, Lee JI, Lee DH, et al. Survival outcome of patients with spontaneously ruptured hepatocellular carcinoma treated surgically or by transarterial embolization. *World J Gastroenterol.* 2013;19:4537-4544.
4. Zhang XF, Wei T, Liu XM, Lv Y, et al. Spontaneous tumor rupture and surgical prognosis of patients with hepatocellular carcinoma. *Scand J Gastroenterol.* 2012;47:968-974.
5. Shin BS, Park MH, Jeon GS, et al. Outcome and prognostic factors of spontaneous ruptured hepatocellular carcinoma treated with transarterial embolization. *Acta Radiol.* 2011;52:331-335.
6. Kim JY, Lee JS, Oh DH, Yim YH, Lee HK, et al. Transcatheter arterial chemoembolization confers survival benefit in patients with a spontaneously ruptured hepatocellular carcinoma. *Eur J Gastroenterol Hepatol.* 2012;24:640-645.
7. Maoz D, Sharon E, Chen Y, Grief F, et al. Spontaneous hepatic rupture: 13-year experience of a single center. *Eur J Gastroenterol Hepatol.* 2010;22:997-1000.
8. Zou J, Li C, Chen Y, Chen R, Xue T, et al. Retrospective analysis of transcatheter arterial chemoembolization treatment for spontaneously ruptured hepatocellular carcinoma. *Oncology letters.* 2019;18:6423-6430.
9. Marrero JA, Kulik LM, Sirlin CB, Zhu AX, Finn RS, et al. Diagnosis, Staging, and Management of Hepatocellular Carcinoma: 2018 Practice Guidance by the American Association for the Study of Liver Diseases. *Hepatology.* 2018;68:723-750.
10. Gomez-Rodriguez R, Romero-Gutierrez M, Artaza-Varasa T, Gonzalez-Frutos C, Ciampi-Dopazo JJ, et al. The value of the Barcelona Clinic Liver Cancer and alpha-fetoprotein in the prognosis of hepatocellular carcinoma. *Rev Esp Enferm Dig.* 2012;104:298-304.
11. Rathor M, Lal A, Dhiman RK, et al. Spontaneous rupture of hepatocellular carcinoma. *J Clin Exp Hepatol.* 2014;4:188-189.
12. Hsin IF, Hsu CY, Huang HC, Huang YH, Lin HC, et al. Liver failure after transarterial chemoembolization for patients with hepatocellular carcinoma and ascites: incidence, risk factors, and prognostic prediction. *J Clin Gastroenterol.* 2011;45:556-562.
13. Zhu Q, Li J, Yan JJ, Huang L, Wu MC, et al. Predictors and clinical outcomes for spontaneous rupture of hepatocellular carcinoma. *World J Gastroenterol.* 2012;18:7302-7307.
14. Chen ZY, Qi QH, Dong ZL, et al. Etiology and management of hemorrhage in spontaneous liver rupture: a report of 70 cases. *World J Gastroenterol.* 2002;8:1063-1066.
15. Han XJ, Su HY, Shao HB, Xu K, et al. Prognostic factors of spontaneously ruptured hepatocellular carcinoma. *World J Gastroenterol.* 2015;21:7488-7494.

16. Li J, Huang L, Liu CF, Cao J, Yan JJ, et al. Risk factors and surgical outcomes for spontaneous rupture of BCLC stages A and B hepatocellular carcinoma: a case-control study. *World J Gastroenterol*. 2014;20:9121-9127.
17. Lee HS, Choi GH, Choi JS, Han KH, Ahn SH, et al. Staged partial hepatectomy versus transarterial chemoembolization for the treatment of spontaneous hepatocellular carcinoma rupture: a multicenter analysis in Korea. *Ann Surg Treat Res*. 2019;96:275-282.
18. Dewar GA, Griffin SM, Ku KW, Lau WY, Li AK, et al. Management of bleeding liver tumours in Hong Kong. *Br J Surg*. 1991;78:463-466.
19. Lai EC, Wu KM, Choi TK, Fan ST, Wong J, et al. Spontaneous ruptured hepatocellular carcinoma. An appraisal of surgical treatment. *Ann Surg*. 1989;210:24-28.
20. Singh Bhinder N, Zangan SM, et al. Hepatocellular carcinoma rupture following transarterial chemoembolization. *Semin Intervent Radiol*. 2015;32:49-53.
21. Lee KH, Tse MD, Law M, Cheng AK, Wong HF, et al. Development and validation of an imaging and clinical scoring system to predict early mortality in spontaneous ruptured hepatocellular carcinoma treated with transarterial embolization. *Abdom Radiol (NY)*. 2019;44:903-911.
22. Kirikoshi H, Saito S, Yoneda M, Fujita K, Mawatari H, et al. Outcomes and factors influencing survival in cirrhotic cases with spontaneous rupture of hepatocellular carcinoma: a multicenter study. *BMC Gastroenterol*. 2009;9:29.
23. Tang X, Zhou X, Li Y, Tian X, Wang Y, et al. A Novel Nomogram and Risk Classification System Predicting the Cancer-Specific Survival of Patients with Initially Diagnosed Metastatic Esophageal Cancer: A SEER-Based Study. *Ann Surg Oncol*. 2019;26:321-328.
24. Ding Y, Mao Z, Ruan J, Su X, Li L, et al. Nomogram-Based New Recurrence Predicting System in Early-Stage Papillary Thyroid Cancer. *Int J Endocrinol*. 2019;2019:1029092.
25. Chou WC, Chang KP, Lu CH, Chen MF, Cheng YF, et al. Complementary role of the Memorial Sloan Kettering Cancer Center nomogram to the American Joint Committee on Cancer system for the prediction of relapse of major salivary gland carcinoma after surgery. *Head Neck*. 2017;39:860-867.
26. Wang Q, Xia D, Bai W, Wang E, Sun J, et al. Development of a prognostic score for recommended TACE candidates with hepatocellular carcinoma: A multicentre observational study. *J Hepatol*. 2019;70:893-903.

Figures

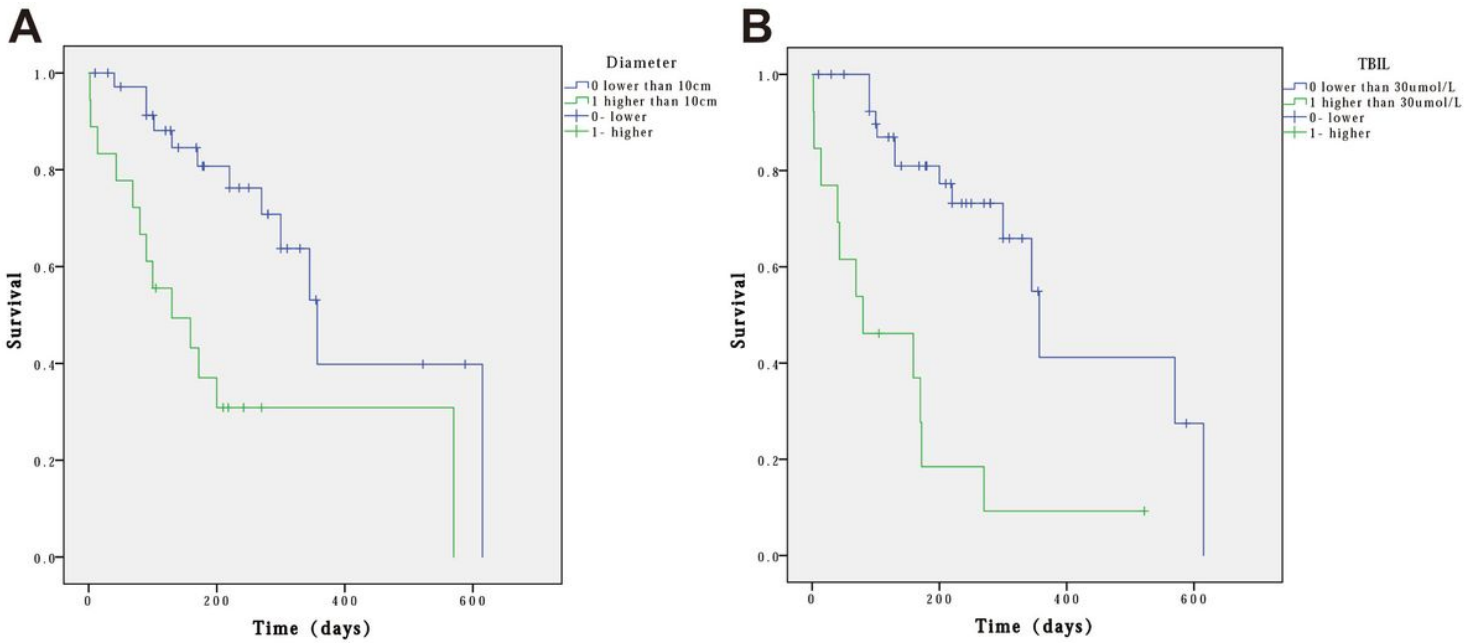


Figure 1

Kaplan-Meier curves for overall survival probability according to maximum tumor diameter and TBIL levels. (A) Kaplan Meier survival curves for comparison of OS in the low- maximum tumor diameter level ($\leq 10\text{cm}$) and high-maximum tumor diameter level ($> 10\text{cm}$) groups ($P < 0.05$). (B) Kaplan Meier survival curves for comparison of OS in the low-TBIL level ($\leq 30\text{umol/L}$) and high-TBIL level ($> 30\text{umol/L}$) groups ($P < 0.05$).

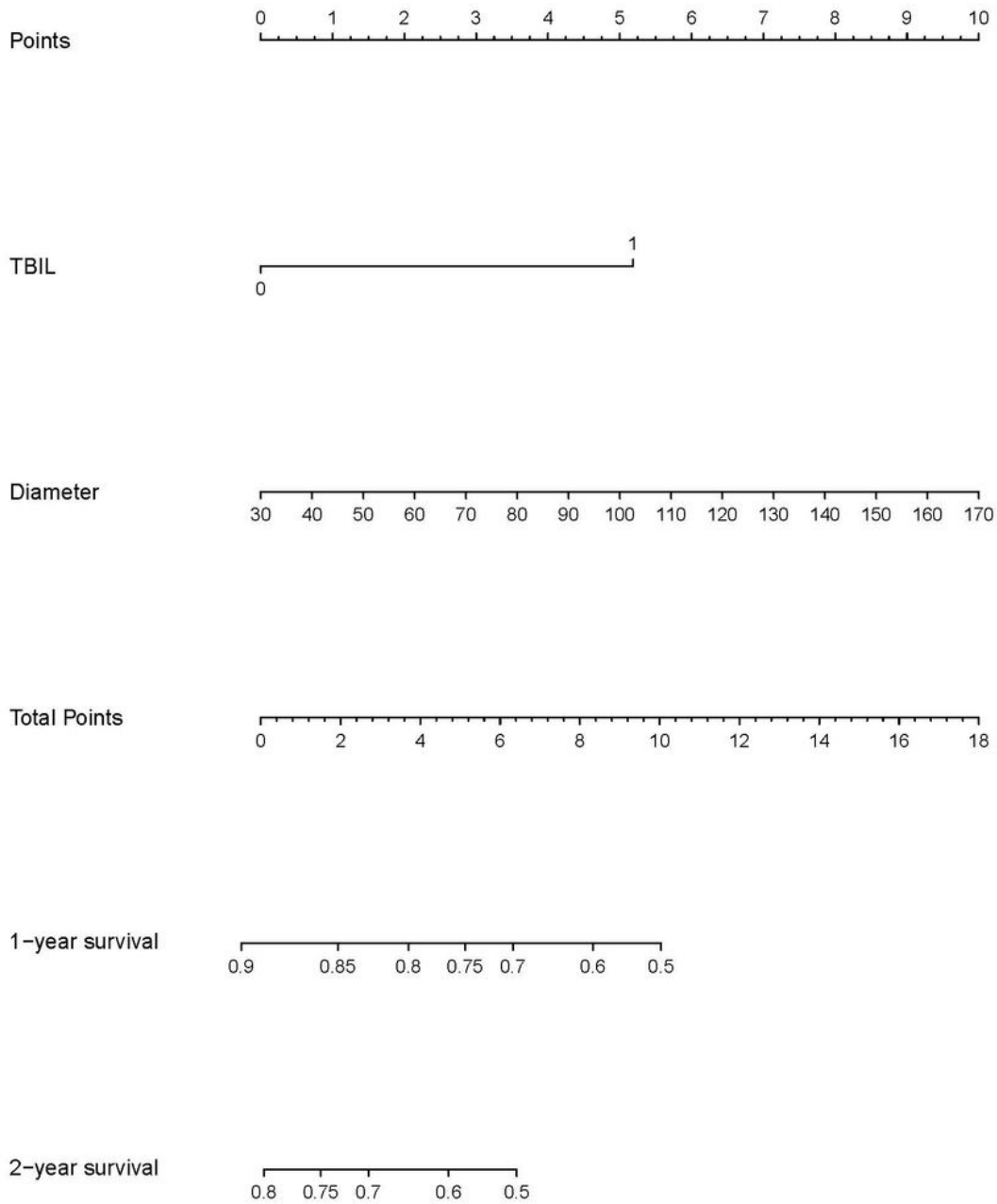


Figure 2

Nomogram of the model for individual survival prediction. TBIL: total bilirubin; Diameter: maximum tumor diameter