

Efficacy of closed reduction for developmental dysplasia of the hip: midterm outcomes and risk factors associated with treatment failure and avascular necrosis

Ge Zhang

Chongqing Medical University Affiliated Children's Hospital <https://orcid.org/0000-0001-6174-5274>

Ming Li

Chongqing Medical University Affiliated Children's Hospital

Xiangyang Qu

Chongqing Medical University Affiliated Children's Hospital

Yujiang Cao

Chongqing Medical University Affiliated Children's Hospital

Xing Liu

Chongqing Medical University Affiliated Children's Hospital

Cong Luo

Chongqing Medical University Affiliated Children's Hospital

Yuan Zhang (✉ yuanz2008@126.com)

Chongqing Medical University Affiliated Children's Hospital

Research article

Keywords: Developmental dislocation of the hip, closed reduction, avascular necrosis of femoral head

Posted Date: July 2nd, 2020

DOI: <https://doi.org/10.21203/rs.3.rs-38289/v1>

License:   This work is licensed under a Creative Commons Attribution 4.0 International License.

[Read Full License](#)

Version of Record: A version of this preprint was published on December 2nd, 2020. See the published version at <https://doi.org/10.1186/s13018-020-02098-3>.

Abstract

Background: The purpose of this study was to evaluate the efficacy after closed reduction (CR) in the treatment of developmental dysplasia of the hip (DDH) and investigate risk factors associated with CR failure and avascular necrosis (AVN) occurrence in the follow-ups.

Primary and secondary outcome measures: The study retrospectively included 110 patients and 138 hips with DDH diagnosis between February 2012 and November 2015 in our single tertiary medical institution and underwent closed reduction. The failure rate of CR and the underlying risk factors were evaluated. meanwhile, the incidence of AVN and the related risk factors among the successful CR cases were assessed.

Results: The overall failure rate of DDH treated by CR in present study was 31.16% (43/138). Risk factors for the CR failure was older age at the time of CR (≥ 18.35 month), large medical interval before CR (≥ 35.35 millimeters), and severer dislocation of the affected hip (IDHI grade III and IV). The incidence of AVN was 8.33% (6/72) in the patients with successful CR at last follow-up. No significant risk factors had been established in present study that associated with the AVN occurrence.

Conclusions: For the treatment of DDH with CR, patients with younger age might achieve better outcomes, early diagnosis and early treatment might be the key point in the DDH treatment.

Background

Developmental dysplasia of the hip (DDH) is a common hip deformity among infants which affects 1–3% of newborns ^[1]. The DDH encompasses a spectrum of disorders according to the relationship between acetabulum and femoral head which are ranged from mild acetabular dysplasia to hip subluxation and eventually dislocation. It has been reported that DDH is the most common cause of hip arthritis in women younger than 40 years and accounts for 5–10% of all total hip replacements in the United States ^[2]. Different treatment modalities for DDH have been well established and appropriate procedures should be applied depends on the patient's age and the severity of the disorder ^[3]. In any circumstances, the primary goal of treatment is to achieve a stable, concentric reduction to enable normal femoral head development and continued acetabular growth and remodeling ^[4]. Early diagnosis and treatment for the DDH are essential to avoid further surgical interventions in some cases. A successful initial treatment of DDH with the Pavlik harness appears to restore the natural development of the hip to normal ^[5]. Unfortunately, many patients, especially those in developing countries, miss this early treatment window ^[6].

Closed reduction (CR) followed by 3–4 months immobilization in spica casting is considered the standard method for children presenting at 6–18 months of age, whereas the success rates varied in the literature. In order to improve the success of CR for the treatment of DDH, it is necessary to identify true predictors of failure ^[7]. In addition, the avascular necrosis (AVN) of the femoral head is the most feared

and frequent complication after CR procedure. The probable etiologies and the risk factors associated to the AVN has been widely discussed but controversies still remained, which indicating a need for more rigorous identification of AVN risk factors for prognostic and preventive purposes.

Therefore, this study aims to evaluate the efficacy of CR in treating patients with DDH, and to determine the risk factors for CR failure and investigate AVN occurrence among patients after preliminary successful CR.

Methods

2.1 Patients selection

We screened patients with DDH diagnosis between February 2012 and November 2015 in our single tertiary medical institution and underwent CR. Our inclusion criteria were 1) Patients with late-presenting DDH that more than six months at diagnosis and patients who failed to the prior treatment including Pavlik harness or Ilfield abduction orthosis; 2) DDH patients with hip subluxation and dislocation (IHDI \geq grade II); 3) patients were received CR following spica cast immobilization; 4) patients and their radiographic data were followed for at least 24 months. Exclusion criteria were 1) Patients with acetabular dysplasia only or slight subluxation. 2) the hip dislocation was associated with a syndrome or other congenital hip abnormality; 3) patients with history of open reduction before initial CR; 5) patients with incomplete clinical and radiographic data at presentation.

After screened, one hundred and ten DDH patients with 138 affected hips were included in present study. There were 17 males and 93 females. There were 82 patients had unilateral DDH (82 hips) and 28 patients had bilateral DDH (56 hips). The average age at the initial treatment was 16.57

- 4.96 months which was range from 6.40 to 33.20 months.

2.2 Closed reduction procedure

The prereduction was not employed in any patients in present series, owing to the uncertain outcomes and poor compliance among infants, otherwise, the prereduction may increase the skin traction complications such as skin irritation, pain, superficial infection^{[8][9]}. Arthrography was performed through an adductor longus muscle approach using 1 cm³ of Iohexol as a contrast to evaluate hip position and assist reduction^[10]. The reduction was performed by Ortolani manoeuvre gently, and CR was considered to have been achieved when the centre of the femoral head had been pulled down to a position opposite the triradiate cartilage (Fig. 1). Furthermore, if the adductor contracture impeding the hip reduction, the percutaneous adductor tenotomy was performed to reach a reliable safe zone^[11]. Thereafter, as concentric and stable reduction was achieved, the hip was immobilized by the hip spica cast at 90° to 110° of flexion and 40° to 60° of abduction for 12 weeks, with a plaster change at six weeks. All patients were treated with an abduction orthosis was after removal of the spica cast for a period of more

than three months until concentric reduction was stable. During follow-ups, affected hips with redislocation and/or the residual acetabular dysplasia would be suggested to CR failure, and the open procedures will be conducted only if informed consents were obtained from these patients' parents. All patients were followed-up every three months in the first year after cast removed, and then followed up every six months during the second year, and every year thereafter. Anteroposterior pelvic radiographs were performed preoperatively, immediately postoperatively, and at each visit in follow-ups. All the enrolled patients' radiographs were reviewed individually by two researchers (Y. Z. and G. Z.) and all the classifications were determined by two authors with a consensus.

2.3 Radiographic evaluation before initial closed reduction

2.3.1 IHDH (International Hip Dysplasia Institute classification): The degree of the hip dislocation was assessed on the basis of the IHDH classification ^[12].

2.3.2 Presence of ossific nucleus of femoral head: The presence of a proximal femoral ossific nucleus in each patient was reviewed and recorded based on the pelvic plain radiographs before the initial CR.

2.3.3 AI measurements: The acetabular index was measured on the AP pelvic radiographs to evaluate the acetabular developmental situation at the time of CR ^[13].

2.3.4 Medial interval (MI) after CR: the medial interval was defined as the vertical distance between the medial edge of the ischium to the middle point of the proximal metaphyseal border of the femur ^[14].

2.3.5 Osteonecrosis of femoral head: The definition of femoral head osteonecrosis was graded according to the Bucholz-Ogden system ^[15]. As the Bucholz and Ogden type I and II is not currently thought to affect the functional and radiological outcome at skeletal maturity ^[16]. We therefore defined that type III and IV as the femoral head osteonecrosis in present study.

2.3.6 Severin Classification: The radiographic outcomes were assessed on the basis of the Severin radiographic classification ^[17]. Severin types I and II were considered to represent a success of CR, however, the types III, IV, V, and VI were considered to a failure of CR.

2.4 Primary outcomes

Our primary outcome was to evaluate the efficacy of CR in the treatment of DDH and further investigate the underlying risk factors associated to the CR failure. Failure of CR was defined as follow: 1) a hip that underwent the OR procedures owing to the redislocation or persistent acetabular dysplasia after initial CR; 2) a hip with a grade range from III to VI according to the Severin radiographic classification at the latest follow-up. For the determination of the risk factors related to the CR failure, it is logical to adopt case number instead of hips as the independent variable because the demographic data (age, sex, etc.) was

unique in each case with bilateral DDH. Therefore, cases would be defined as failure even if only single side failure occurred in the bilateral DDH..

2.5 Secondary outcomes

As osteonecrosis of femoral head after CR in the treatment of DDH was also a widely concerned issues. Thus, we have to further assess the AVN occurrence among the cases with preliminary successful CR.

2.6 Statistic analysis

All variables were analyzed by SPSS 22.0. Statistical software, and continuous data were indicated by $X \pm SD$. Chi-square test and ANOVA analysis were used for univariate comparison and binary logistic regression analysis for multivariate analysis. When investigate the relevant risk factors, the ROC curve was used to determine the grouping node, and the $AUC > 0.5$ was considered the model have predictive value. Determined the level of statistical significance with the P value set at 0.05 ($P \leq 0.05$).

Results

After screened, there were 110 patients with 138 hips included in present study. Patient demographics and radiographic findings are shown in Table. 1.

As described in the methods part, the failure of CR treatment was defined hips which underwent OR procedures following CR treatment or hips with grade Severin III or above at the latest follow-up. There were 27 patients with 32 hips underwent OR following CR treatment owing to the recurrence of dislocation (10 hips) or sustained acetabular dysplasia (22 hips) at any time during follow-ups. Among the patients underwent OR procedures, 19 hips from 19 unilateral DDH patients and 13 hips from 8 bilateral DDH patients. Among bilateral cases, there were 10 hips in 5 bilateral DDH patients underwent bilateral OR and 3 hips in 3 bilateral DDH patients under single side OR. And there were 11 patients with 11 hips were defined as failure because of the unsatisfactory Severin grading (grade III or more), including 10 hips from 10 unilateral DDH patients and one hip from one bilateral patient with single side failure, In conclusion, the overall failure rate of DDH hips treated by CR in present study was 31.16% (43/138). .

For the inclusion of the hip radiographic indices of CR failed cases, we selected the 82 affected hips of the 82 unilateral DDH cases and 4 affected hips of the four bilateral DDH cases with single side failure occurrence into analysis. Otherwise, we selected the left hips and their radiographic indices into analysis of cases that bilateral success (19 patients) or failure (5 patients) among bilateral DDH cases because of a general preponderance of the left hip is the frequently involvement side in DDH. Ultimately, 110 patients with 110 hips were included for the prognostic factor evaluation in the CR treatment. According to the different endings, there were 72 cases in the successful group and 38 cases in the failed group. In the univariate analysis, the mean age at the CR was significant older in failure group than that in the

satisfactory group (15.72 ± 4.74 vs. 18.17 ± 5.04 , $P = 0.013$). We constructed a receiver operating characteristic (ROC) curve of the age at CR treatment and showed the optimal cut-off point was 18.35 months (area under the curve [AUC] = 0.655, 95% CI = 0.547 to 0.763, $P = 0.008$) (Fig. 2a). Cases underwent initial CR at lower age (≤ 18.35 month) were significantly more likely to result a satisfactory outcome than those older age cases (>18.35 month) ($P < 0.001$). The MI after CR immediately was higher in failed group than that in successful group ($P < 0.001$). The ROC curve established the cutoff was 35.35 mm, and case with MI less than 35.35 mm showed significant higher successful CR rate ($P < 0.001$) (Fig. 2b). Cases that classified with IHDII grade II were significantly more likely to result a success than grade III ($P = 0.048$) or grade IV ($P = 0.002$), respectively. On the contrary, there was no significant difference between two groups among other prognostic factors (Table 2). Furthermore, the Binary logistic regression model retained initial age at CR and MI after CR immediately as the significant diagnostic variables (Table 3).

Table 1
Patient demographics of 110 patients included in the study.

Number of patients / hips (n)	110 patients / 138 hips
Age at initial CR (m)	16.57 ± 4.96 (6.40 to 33.20)
Follow-up (m)	51.22 ± 13.35 (24.03 to 79.37)
AI at the initial CR (°)	36.48 ± 6.17
MI after CR	36.28 ± 6.16
Sex (n)	
Male	17 patients
Female	93 patients
Laterality (n)	
Unilateral DDH	82 patients
Bilateral DDH	28 patients
Percutaneous adductor tenotomy (n)	
Yes	64 patients / 85 hips
No	46 patients / 53 hips
Presence of femoral ossific nucleus (n)	
Yes	64 patients / 120 hips
No	15 patents / 18 hips
IHDI grade (n)	
II	29 patients / 37 hips
III	40 patients / 48 hips
IV	41 patients / 53 hips

Table 2
The univariate analysis of the risk factors related to the CR in the treatment of DDH.

	Satisfactory group	Unsatisfactory group	P
Number of patients (n)	72	38	
Age at initial CR (m)	15.72 ± 4.74	18.17 ± 5.04	0.013
MI after CR	31.38 ± 4.75	34.69 ± 3.81	< 0.001
Age grading at initial CR (n)			0.007
≤ 18.35 months	48	16	
> 18.35 months	24	22	
Sex (n)			0.532
Male	10	7	
Female	62	31	
Laterality (n)			0.757
unilateral DDH	53	29	
bilateral DDH	19	9	
MI after CR			< 0.001
< 35.35 mm	57	16	
> 35.35 mm	15	22	
Seniority of orthopedists (n)			0.137
≤ 15 years	25	8	
> 15 years	47	30	
Presence of femoral ossific nucleus (n)			0.49
Yes	61	34	
No	11	4	
IHDI grade (n)			0.010
II	25	4	
III	26	14	
IV	21	20	
AI at the initial CR (°)	35.92 ± 6.49	37.53 ± 5.45	0.196

Table 3

The Binary logistic regression model of the risk factors related to the CR in the treatment of DDH.

	Regression coefficient	95% CI of coefficient	Odds ratio	P
Intercept (constant)	-1.656			
Age grading at initial CR				
> 18.35 months VS. ≤ 18.35 months	0.990	1.124 to 6.447	2.692	0.026
MI after CR				
< 35.35 mm VS > 35.35 mm	1.581	2.013 to 11.741	4.862	< 0.001

To evaluate the incidence of AVN of femoral head after preliminary success of CR, we excluded the 38 failure cases (29 unilateral cases and 9 bilateral cases) and all of their 47 hips regardless of the primary outcomes of the CR. There were 72 patients with 91 hips enrolled analysis after excluded the unsatisfactory cases with their accompanied hips. We also adopted cases instead of hips into analysis owing to the characteristic of bilateral cases mentioned above. For the radiographic data extraction, we selected the affected hip in bilateral DDH patients with single side AVN; otherwise we selected the left hip in bilateral DDH patients with two sides AVN or without AVN. The incidence of AVN was 6/72 (8.33%) assessed from the latest radiographs. Thereafter, we assessed the risk factors associated with the development of AVN after preliminary successful CR. The univariate analysis revealed that occurrence of AVN was not affected by any prognostic factors as shown in Table 4.

Table 4

The univariate analysis of the risk factors related to the incidence of AVN of femoral head after CR.

	non-AVN	AVN	P
Number of patients (n)	66	6	
Age at initial CR (m)	15.97 ± 4.67	12.98 ± 45.04	0.141
Sex (n)			1
Male	9	1	
Female	57	5	
Laterality (n)			0.936
Unilateral DDH	48	5	
Bilateral DDH	18	1	
Percutaneous adductor tenotomy (n)			0.308
Yes	24	4	
No	42	2	
Seniority of orthopedists (n)			0.086
≤ 15 years	25	0	
> 15 years	41	6	
Presence of femoral ossific nucleus (n)			1
Yes	10	1	
No	56	5	
IHDI grade (n)			0.703
II	23	2	
III	23	3	
IV	20	1	
MI after CR	31.83 ± 3.40	26.55 ± 4.64	0.008
AI at the initial CR (°)	35.80 ± 6.60	37.33 ± 5.48	0.582
Tables			

Discussion

The successful rates of CR in the treatment of DDH were inconsistent in the literature which ranged from 43% to 92% [18][19]. In practical, if concentric, stable reduction of the hip cannot be achieved, OR procedure is an alternative for DDH. For efficacy evaluation of CR in the treatment of DDH, most studies only defined OR following CR as an endpoint of failure. However, we believed that hips with unsatisfactory radiographic outcomes such as residual acetabular dysplasia or subluxation in the long-term follow-ups who did not receive further intervention should be also take into consideration when determining the failure of CR. Because most of these cases should have been received further interventions in case of progressing into a high incidence of degenerative hip disease. But the fact is that not all these patients got further treatment because of their parents refused owing to the asymptomatic state till the latest follow-up [20]. For instance, Yamada et al. [16] reported a satisfactory successful rate of 92% CR in treating DDH, but 48% of patients who were over six-years old at last follow-up showed residual subluxation. Consequently, the diversity failure rates of CR in the treatment DDH might be partially dependent on the different evaluating criteria for failure. The Severin classification is a widely acceptable assessing system for long-term results after DDH treatment, and the unsatisfactory Severin grades (grading III to VI) deemed to poor containment of acetabulum on femoral head which may be strongly indicated a poor prognosis that may leads to early degenerative joint disease even though these hips had not yet received surgical intervention. It is reported that 46% of the Severin III/IV hips had severe degenerative changes compared with only 3% of the Severin I/II hips [21]. Altogether, the failure should be comprised of the OR cases following CR at early stage and cases with unsatisfactory Severin grades during follow-ups. In present study, we defined the failure of CR combined the cases which had undergone secondary OR (27 patients with 32 hips) and cases that showed unsatisfactory radiographic outcomes with Severin III or above grades (11 patients with 11 hips) at last follow-up. In conclusion, the overall failure rate of DDH after CR treatment in present study was 31.16% (43/138). Furthermore, if the prognosis and the related risk factors of failure can be predicted at the time of initial CR, the parents can be informed regarding the outcome and future managements of the child. Many factors have been reported to as the risk factors for the failed CR including an older age, high dislocation grade or large AI and so on [10][22]. It has been documented that age is an important prognostic factor in the treatment of DDH with CR [23]. Terjesen et al. [24] reported that the most important independent risk factors for a poor long-term outcome was an age of eighteen months or older at the time of reduction. On the contrary, Barakat et al. [25] concluded that CR in children between 19 months of age to 36 months should be deliberately conducted by an experienced pediatric orthopaedic surgeon with ability to shift timely to open reduction once the complication occurred in the close follow-up. Unfortunately, a typical study from Bolland's research reported that 83% of patients over the age of 18 months who underwent CR initially required further open procedures [26]. Herein, we observed the similar outcomes that patients older than 18.35 months at the age of CR may have poor outcomes when compared with younger patients. Altogether, we concluded that using CR as a treatment regime for DDH among patients whose age over than 18 months might not be a reasonable choice.

The failure rate of CR in treating DDH was increased with the severe grading of the dislocation of hips [27]. The higher dislocation grading correlating with increased risk of open reduction [28]. In present study, our results also showed that the more severe dislocation of the DDH before treatment is significantly associated to the inferior outcomes after CR. The successful rate in IHDl grade II were significantly higher than grade III ($P = 0.048$) or grade IV ($P = 0.002$) respectively. Although there is no difference in successful rate between grade III and grade IV ($P = 0.209$), whereas the failed incidence in grade III was 35% (14/40) was also lower than that in grade IV 48.79% (20/41). We inferred that more included cases in future research might be demonstrate more predictable outcomes. Theoretically there are more soft tissues between femoral head and acetabulum in the affected hips with higher IHDl grade, and the pressure between the femoral head and the acetabulum was greater after the closed reduction that would be acted as the obstructs in the “docking” process subsequently result in a failed outcomes including the redislocation, sustained subluxation and/or insufficient acetabular remodeling [29]. Actually, in present study, we employed the medial interval (MI) value attempting to determine the soft tissue obstruction between the acetabulum and femoral head after initial reduction. Our results showed that the satisfactory group demonstrated a less MI than unsatisfactory group, and we also constructed that MI more than 35.35 mm after CR immediately might be strongly indicated a poor outcomes. In present study, we included patients with with treatment history of Pavlik harness or abduction orthosis. Our results showed the orthosis treatment did not affected the CR results. However, this points should be further discussed in further studies, because the failure of orthosis treatment for DDH in infants may involve many variables, especially the compliance to the standard treatment regimen, and these patient-related variables lead to the bias outcomes [30].

Avascular necrosis (AVN) of femoral head is one of the most concerning complications following CR, which might be result in hip pain, limb-length discrepancy, abnormal gait and premature hip degenerative disease that affect hip function and need further interventions in adulthood [18]. Previous studies reported a discrepant rates of AVN were ranged from 0–67% [31]. Earlier studies have reported that various possible factors related to the AVN, including the age at the onset of treatment [32], genders [33], the utilization of prereduction traction [34], the severity of hip dislocation at treatment [35], laterality (unilateral/bilateral DDH) [36], absence of proximal femoral ossific nucleus [37], failed Pavlik harness treatment [38], or adductor tenotomy [39]. However, either of these underlying factors was disputed, especially in recent evidence-based studies [40]. Whilst these variations may be a consequence of natural variation due to the relatively small case numbers, different cases selection or the diversities in therapeutic regimes. As there is currently no consensus on whether the prereduction traction is beneficial and efficacy to help reduction, thus we abandoned this procedure before CR in all patients. In present study, our results showed that the AVN occurs in 6/72 (8.33%) of patients with satisfactory outcomes after CR. Furthermore, the occurrence of AVN was unaffected by gender, laterality, the age at CR, presence of the ossific nucleus, adductor tenotomy, seniority of orthopedists, prereduction AI or severity of dislocation. These results are similar to the results from a recent prospective, multicenter research [41]. As

AVN after CR was a multifactorial event, the high quality, prospective studies with large samples is still need to elucidate the precise risk factors associated to the AVN after DDH treatment.

Conclusion

In general, the CR is still an effective procedure for the treatment of infant and toddler patients with DDH. For DDH patients with older age and severer dislocation, it is important to keep closed followed after CR and take appropriate intervention to avoid progressive dysfunction of the hip. No determined factors had been confirmed associating with the AVN occurrence after preliminary CR success.

The study showed the CR is still an effective procedure for the treatment of infant and toddler patients with DDH. However, there are still some limitations in present study. The AVN evaluation after CR should be include more case and longer follow-up as osteonecrosis secondary to the treatment of DDH is a relatively benign condition in children and teenagers.

Error can be introduced when radiographic induces measurements such as AI or MI, either by incorrectly positioning of child for radiographs (hip flexion/extension and rotation) or by inter- or intraobserver errors.

Abbreviations

DDH: Developmental Dislocation of the Hip, CR: Closed Reduction, OR: Open Reduction, AI: Acetabular Index, AVN: Avascular necrosis of femoral head, IHDI: International Hip Dysplasia Institute classification, RAD: the residual acetabular dysplasia, AP: Anteroposterior. MI: Medial interval

Declarations

Compliance with Ethical Standards

Disclosure of potential conflicts of interest, including funding

All authors declare that they have no conflict of interest and no financial associations that may be relevant or seen as relevant to the submitted manuscript.

Patient and public involvement We did not involve patients or the public in our work as a retrospective study based on medical records.

Ethics approval and consent to participate

The study was institutional review board approval by Children's Hospital of Chongqing Medical University (No.2017001).

Consent for publication:

Not applicable

Availability of data and materials:

The datasets used and/or analysed during the current study are available from the corresponding author on reasonable request.

Competing interests:

The authors declare that they have no competing interests.

Funding:

This research received no specific grant from any funding agency in the public, commercial or not-for-profit sectors.

Authors' contributions:

YZ, ML and GZ were involved in the conception and design of the project. All authors participated the surgery implementation. YZ and GZ collected and extracted the data. YZ and GZ conducted the analysis and data interpretation. YZ drafted the manuscript. YZ and ML made the critical revisions. All authors read, provided feedback and approved the final manuscript.

References

1. Sewell MD, Rosendahl K, Eastwood DM. Developmental dysplasia of the hip. *BMJ: British Medical Journal (Overseas & Retired Doctors Edition)* 2009;339(7732):1242-1248.
2. Shaw BA, Segal LS. Evaluation and Referral for Developmental Dysplasia of the Hip in Infants. *PEDIATRICS* 2016;138(6): e20163107-e20163107.
3. Cooper AP, Doddabasappa SN, Mulpuri K. Evidence-based Management of Developmental Dysplasia of the Hip. *Orthopedic Clinics of North America* 2014;45(3):341-354.
4. Yang S, Zusman N, Lieberman E, et al. Developmental Dysplasia of the Hip. *Pediatrics* 2019;143(1):e20181147.
5. Swarup I, Penny CL, Dodwell ER. Developmental dysplasia of the hip: an update on diagnosis and management from birth to 6 months. *Current Opinion in Pediatrics* 2018;30:84-92.
6. Murgai RR, Harris LR, Choi PD, et al. Socioeconomic risk factors for poor outcomes of developmental dysplasia of the hip. *J Pediatr* 2019;211:159-163.
7. Schaeffer EK, Study GI, Mulpuri K. Developmental dysplasia of the hip: addressing evidence gaps with a multicentre prospective international study. *Med J Aust* 2018;208:359-364.
8. Walton Sarah, Schaeffer Emily, Mulpuri Kishore, Cundy Peter, Williams Nicole. Evaluating the role of prereduction hip traction in the management of infants and children with developmental dysplasia of the hip (DDH): protocol for a systematic review and planned meta-analysis. *BMJ Open*, 2018: 8(1), e019599.

9. Sucato Daniel J, De La Rocha Adriana, Lau Karlee, Ramo Brandon A. Overhead Bryant's Traction Does Not Improve the Success of Closed Reduction or Limit AVN in Developmental Dysplasia of the Hip. *J Pediatr Orthop*, 2017; 37(2), e108-e113.
10. Li Y, Guo Y, Li M, et al. Multi-center Pediatric Orthopedic Study Group of China. Acetabular index is the best predictor of late residual acetabular dysplasia after closed reduction in developmental dysplasia of the hip. *Int Orthop* 2018;42:631-640.
11. Ramsey PL, Lasser S, MacEwen GD. Congenital dislocation of the hip. use of the Pavlik harness in the child during the first six months of life. *J Bone Joint Surg Am* 1976;58:1000-1004.
12. Narayanan U, Mulpuri K, Sankar WN, et al. reliability of a new radiographic classification for developmental dysplasia of the hip. *J PediatrOrthop* 2015;35(5):478-484.
13. Albinana J, Dolan L A, Spratt K F, Morcuende J, Meyer M D, Weinstein S L. Acetabular dysplasia after treatment for developmental dysplasia of the hip. Implications for secondary procedures. *J Bone Joint Surg Br*, 2004: 86(6), 876-86.
14. Ohmori Takao, Endo Hiroshuke, Mitani Shigeru, Minagawa Hiroshi, Tetsunaga Tomonori, Ozaki Toshifumi. Radiographic prediction of the results of long-term treatment with the Pavlik harness for developmental dislocation of the hip. *Acta Med. Okayama*, 2009: 63(3), 123-8.
15. Reimers J. The stability of the hip in children: A radiological study of the results of muscle surgery in cerebral palsy. *Acta OrthopScand Suppl* 1980;51(S184):1-100.
16. Roposch A, Liu LQ, Offiah AC, et al. Functional outcomes in children with osteonecrosis secondary to treatment of developmental dysplasia of the hip. *J Bone Joint Surg Am* 2011;93(24):e145.
17. Carroll KL, Murray KA, MacLeod LM, et al. Measurement of the center edge angle and determination of the Severin classification using digital radiography, computer-assisted measurement tools, and a Severin algorithm: intraobserver and interobserver reliability revisited. *J PediatrOrthop* 2011;31(4):e30-35.
18. Cha SM, Shin HD. Long-term results of closed reduction for developmental dislocation of the hip in children of walking age under eighteen months old. *Int Orthop* 2018;42:175-182.
19. Yamada N, Maeda S, Fujii G, et al. Closed reduction of developmental dislocation of the hip by prolonged traction. *J Bone Joint Surg Br* 2003;85:1173-1177.
20. Kim HT, Kim JI. Acetabular development after closed reduction of developmental dislocation of the hip. *J PediatrOrthop* 2000;20:701-708.
21. Malvitz TA, Weinstein SL. Closed reduction for congenital dysplasia of the hip. Functional and radiographic results after an average of thirty years. *J Bone Joint Surg Am* 1994;76:1777-1792.
22. Kitoh H, Kitakoji T, Katoh M. Prediction of acetabular development after closed reduction by overhead traction in developmental dysplasia of the hip. *J Orthop Sci* 2006;11:473-477.
23. Perajit E, Tanatip S, Thunchanok J, et al. The Factor Causing Poor Results in Late Developmental Dysplasia of the Hip (DDH). *J Med Assoc Thai* 2015;8(19):32-37.

24. Terjesen T, Horn J, Gunderson RB. Fifty-year follow-up of late-detected hip dislocation: clinical and radiographic outcomes for seventy-one patients treated with traction to obtain gradual closed reduction. *J Bone Joint Surg Am* 2014;96:e28.
25. Barakat AS, Zein AB, Arafa AS, et al. Closed reduction with or without adductor tenotomy for developmental dysplasia of the hip presenting at walking age. *Current Orthopaedic Practice*, 2017; 28(2):195-199.
26. Bolland BJ, Wahed A, Al-Hallao S, et al. Late reduction in congenital dislocation of the hip and the need for secondary surgery: radiologic predictors and confounding variables. *J PediatrOrthop* 2010;30: 676-682.
27. Tennant SJ, Hashemi-Nejad A, Calder P, et al. Bilateral developmental dysplasia of the hip: does closed reduction have a role in management? outcome of closed and open reduction in 92 hips. *J PediatrOrthop* 2019;39:e264-e271.
28. Ramo BA, De La Rocha A, Sucato DJ, et al. A new radiographic classification system for developmental hip dysplasia is reliable and predictive of successful closed reduction and late pelvic osteotomy. *J PediatrOrthop* 2016; 38:16-21.
29. Talathi NS, Chauvin NA, Sankar WN. Docking of the femoral head following closed reduction for DDH: does it really occur? *J PediatrOrthop* 2018;38:e440-e445.
30. Ömeroglu. Treatment of developmental dysplasia of the hip with the Pavlik harness in children under six months of age: indications, results and failures. *Journal of children's orthopaedics*,2018;12(4):308-316.
31. Chen C, Doyle S, Green D, et al. Presence of the ossific nucleus and risk of osteonecrosis in the treatment of developmental dysplasia of the hip: a meta-analysis of cohort and case-control studies. *J Bone Joint Surg Am* 2017;99:760-767.
32. Kruczynski J. Avascular necrosis of the proximal femur in developmental dislocation of the hip. Incidence, risk factors, sequelae and MR imaging for diagnosis and prognosis. *Acta OrthopScand Suppl* 1996;268:1-48.
33. Schur MD, Lee C, Arkader A, et al. Risk factors for avascular necrosis after closed reduction for developmental dysplasia of the hip. *J Child Orthop* 2016;10:185-192.
34. Park KB, Vaidya VN, Shin H. Prereduction traction for the prevention of avascular necrosis before closed reduction for developmental dysplasia of the hip: a meta-analysis. *Ther Clin Risk Manag* 2018;14:1253-1260.
35. Sibiński M, Marek S, Marcin D, et al. Risk factors for avascular necrosis after closed hip reduction in developmental dysplasia of the hip. *OrtopediaTraumatologiaRehabilitacja* 2004; 6(1):60-66.
36. Morbi AH, Carsi B, Gorianinov V, Clarke NM. Adverse Outcomes in Infantile Bilateral Developmental Dysplasia of the Hip. *J PediatrOrthop* 2015;35:490-495.
37. Segal LS, Boal DK, Borthwick L, et al. Avascular necrosis after treatment of DDH: the protective influence of the ossific nucleus. *J PediatrOrthop* 1999;19:177-184.

38. Tiruveedhula M, Reading IC, Clarke NM. Failed Pavlik harness treatment for DDH as a risk factor for avascular necrosis. *J PediatrOrthop* 2015;35:140-143.
39. Carney BT, Clark D, Minter CL. Is the absence of the ossific nucleus prognostic for avascular necrosis after closed reduction of developmental dysplasia of the hip? *J Surg Orthop Adv* 2004;13(1):24-29.
40. Bradley CS, Perry DC, Wedge JH, eaak. Avascular necrosis following closed reduction for treatment of developmental dysplasia of the hip: a systematic review. *J Child Orthop* 2016;10:627-632.
41. Sankar WN, Gornitzky AL, Clarke NMP, et al. Closed reduction for developmental dysplasia of the hip: early-term results from a prospective, multicenter cohort. *J PediatrOrthop* 2019;39:111-118.

Figures

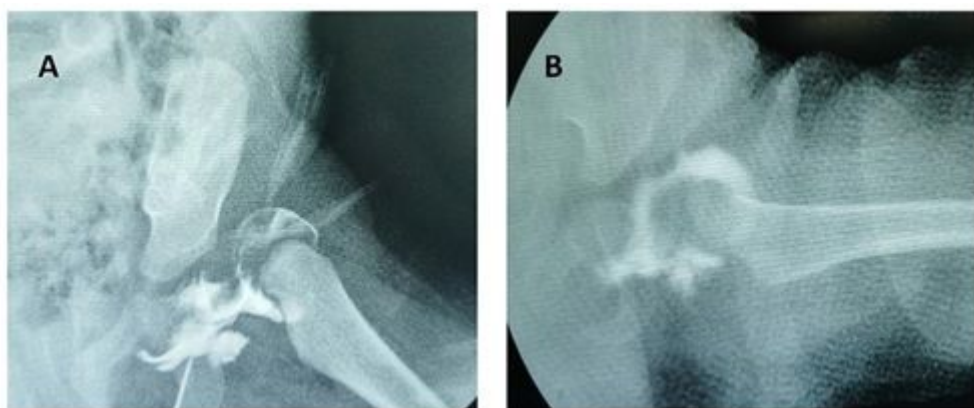


Figure 1

The hip was dislocated from the acetabulum before CR (a); The concentric reduction has been achieved after CR.

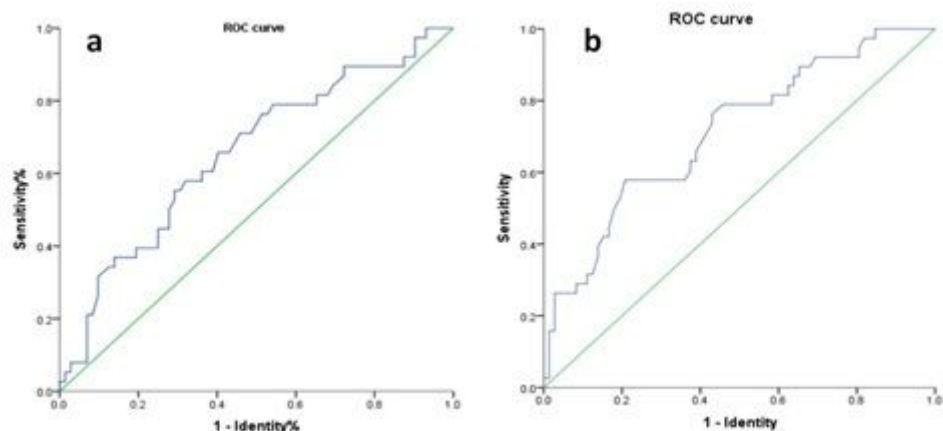


Figure 2

The ROC curve of the age at initial CR (a); The ROC curve of MI after CR immediately (b).