

Novel Promising Technique for Traumatic Pancreatic Injury Management.

Mohammed Hamada Takrouney (✉ m.takrouney1988@aun.edu.eg)

Assiut University Faculty of Medicine

Vipul Prakash Bothara

Kokilaben Dhirubhai Ambani Hospital and Medical Research Institute

Bhushan Jahhavi

Noah's Ark Children's Hospital for Wales

Mohamed Abdelkader Osman

Assiut University Faculty of Medicine

Ibrahim Ali Ibrahim

Assiut University Faculty of Medicine

Almoutaz Ahmed Eltayeb

Assiut University Faculty of Medicine

Mahmoud Mohamed Mostafa

Assiut University Faculty of Medicine

Gursev Sandlas

Kokilaben Dhirubhai Ambani Hospital and Medical Research Institute

Research article

Keywords: Pancreatic trauma, Endoscopic (Laparoscopic and Robotic) Simple Primary Pancreatic Repair, Postoperative Somatostatin

Posted Date: June 18th, 2020

DOI: <https://doi.org/10.21203/rs.3.rs-35661/v1>

License:   This work is licensed under a Creative Commons Attribution 4.0 International License.

[Read Full License](#)

Abstract

Introduction: Pancreatic injuries in children are relatively uncommon. The precise location of the injury, the status of the main pancreatic duct, and the time between diagnosis and intervention are a potentially useful guide for management decisions. We report a successful endoscopic simple primary repair with the pancreatic preservation even with transected main pancreatic duct without duct stenting.

Patients and Methods: Between May 2017 and December 2019, 3 patients with pancreatic trauma and duct transection underwent endoscopic (laparoscopic and robotic) repair. Demographics, Operative data, Postoperative complications, and clinical outcomes were documented and analyzed.

Results: Three patients with pancreatic fractures, 2 patients with grade IV, and one patient grade III injury. The median age was 11 years, the median time of hospital admission after the trauma was 72 hours. The median time of surgical intervention was 24 hours. Average operative time was 160 minute and the average hospital stay was 9 days with no recorded postoperative or follow up complications till now.

Conclusion: Primary simple pancreatic repair is a promising and plausible technique for the management of pancreatic trauma, especially with duct transaction it maybe instead of all other modalities of pancreatic trauma treatment. We implore all pediatric surgery centers to espouse this technique.

Introduction:

Pediatric Pancreatic injuries (PI) are uncommon compared to the other abdominal organ injuries (1). Furthermore, the main pancreatic duct transection is fraught with high morbidity and mortality rate (2, 3). Conservative management or distal pancreatectomy with the internal drainage procedure of the remaining pancreas is currently the benchmark of management. Recent studies have advocated the trend of treatment simplification. Rather, damage control surgery is gaining greater acceptance (4). From this point of contingency, minimally invasive primary pancreatic repair comprises a reliable method of meticulous management of PI. Intimate alignment of transacted edges is a substantial step in the healing of the injured tissues.

Based on the notion that repairing of the two edges of the transected pancreas with proper opposition of two margins will consequently allow the duct edges to heal similarly without repair. (5) Likewise in this study, we have attempted primary simple repair of the transected pancreas and its duct by the Minimal Access Approach resulting in a good outcome in all patients.

Material And Methods:

This study amended and strictly followed the ethical guidelines of the Helsinki declaration, between May 2017 and December 2019, 3 patients who had abdominal trauma including pancreatic injury and main duct transaction were surveyed in this study retrospectively.

Diagnoses of pancreatic fracture and the transected duct were based on Contrast CT of the abdomen in addition to clinical presentation in the form of abdominal pain, distension, and epigastric tenderness with preemptive laboratory investigations. [Complete blood picture, amylase, lipase, and indicators of septicemia].

The patients were classified according to the pancreatic injury scale (table 1) based on the CT finding of pancreatic transection, duct injury, hematoma, and ascitic fluid collection in the lesser sac.

A flow sheet of patients was done containing all paramount data which analyzed precisely (table 2, 3).

Informed consent was obtained from all patients.

Preoperative Preparations:

Pre-Operative optimization, ensuring hemodynamic stability, precise examination of all other organs, dealing with emergent fractures are the main task in the first hours of admission. Proper antibiotics, laboratory investigation, blood grouping, and imaging investigation were done preemptively. Informed consent was obtained from all patients.

Operative Technique:

10 mm Umbilical port inserted by Open technique and 5 mm additional ports placed in each Iliac Fossae respectively. Gastro-colic Omentum was opened to access the lesser sac

The stomach was hitched up to the anterior abdominal wall and fluid was drained from the lesser sac. Head of the pancreas identified and traced distally along the body of the pancreas till the site of injury and thorough wash done. Full-thickness suturing of pancreatic parenchyma with 4-0 PDS in an interrupted manner and hemostasis confirmed. The drain was kept in the lesser sac and somatostatin was given as an infusion for the first 48 hours and then given subcutaneously for 3 weeks. Drain removed once the output of fewer than 50 ml.

Results:

There were three patients with pancreatic fractures and complete transection of the main pancreatic duct (two patients with grade IV and one patient grade III. After abdominal trauma (two cases due to motor vehicle accidents and one patient due to blunt abdominal trauma), with a median age of 11 years, the median time for admission into the hospital after the trauma was 72 hours and the median time for surgical intervention was 24 hours after admission, to make sure of hemodynamic stability as mean blood pressure was 87.78 mmHg, pulse 87 bpm, and temperature 38.1o C

Concerning radiological investigations for elucidating concomitant organ injuries, they comprised of a right clavicle fracture treated with an arm sling in the first case and right tibia fracture treated by a simple leg cast in the second case. [Table reference]

All patients presented by abdominal pain, distention, and peritonism.

As per the existing departmental protocol for stable Acute Abdomen cases, two cases underwent Exploratory Laparoscopy and one case underwent Exploratory Robot-Assisted Laparoscopy. All cases displayed a considerable amount of ascites in the lesser sac with various degrees of omental saponification and transection of the main pancreatic duct. As mentioned in the operative technique simple primary repair of properly opposed edges of the pancreas was done with average operative time was 160 min.

Post-operative Sequelae And Follow Up Course:

After a successful surgery, all patients were started with early mobilization protocol within the first 6 hours post-operatively except the 3rd patients due to her right leg cast.

There no need for opioids analgesia only NSAID in the form of paracetamol as a pain killer and 3rd generation cephalosporin given to all patients.

Rather, anti-secretory therapy, somatostatin inform of intravenous infusion in dose 1mg/kg \day in the first 48 hours and was continued subcutaneously till the end of 21 days.

Expediently patients started oral feeding in day 2 post the surgery and the average period of drain removal was 9 days [5 days to 21 days]. Amylase values improved dramatically post-operatively on average 193 U/L.

Moreover, the average hospital stay period was 9 days.

Up-to-date, patients were followed up optimally with no complications in the form of Intraperitoneal or lesser sac fluid collection, Pseudocyst formation, Dilatation of pancreatic duct, or formation of a pancreatic fistula. All patients on follow up had Normal Ultrasound examination along with normal Sr. Amylase & C- Peptide levels.

Discussion:

Historically, there were many speculations concerning dealing with the pancreas itself due to many wrong concepts around its healing process, and for fear of touching its main duct.

Till now, no agreed criteria for advancing to repair the traumatic pancreas is available, many surgeons are proponents of deliberate conservative management which nonetheless results in the inevitable formation of pancreatic pseudocyst which increases the morbidity, surgical intervention, hospital stay and economic cost (6).

In Recent years, Minimal Invasive surgery especially laparoscopy, preferentially pursued in all medical domains and acquisition of the pediatric surgery field. A proclivity to treat the pancreatic injury

laparoscopically nowadays is becoming more popular, laparoscopic distal pancreatectomy, and internal drainage of its remaining portion represents a formidable challenge for leakage, postoperative complication and increase the operative time(7). Looking to all these ramifications performing primary pancreatic repair without stenting or repair the main transected duct and relay on accurate alignment of pancreatic transected parts imposing the tissue healing principles can be successfully done with satisfactory and robust long term results.

Conclusion:

The restoration of the normalcy in pediatric major trauma patients is elusive, especially with Major pancreatic trauma. From this point, we do our best for alleviating the burden and rescuing the child and the family by presenting this new and promising technique. For the establishment of the minimally invasive surgical simple primary pancreatic repair procedure as described previously we encourage all pediatric surgery centers to begin to render it as the first line in the management of pancreatic injury.

Declarations

Compliance with Ethical Standards:

Conflict of interest:

Author\ **Mohammed HamadaTakrouney** declares that he has no conflict of interest. Author **Vipul Prakash Bothara** declares that he has no conflict of interest. Author **BhushanJadhav** declares that he has no conflict of interest. Author \ **Mohamed Abdelkader Osman** declares that he has no conflict of interest. Author \ **Ibrahim Ali Ibrahim** declares that he has no conflict of interest .Author\ **Almoutaz Ahmed Eltayeb** declares that he has no conflict of interest .Author\ **Mahmoud Mohamed Mostafa** declares that he has no conflict of interest.Author \ **Gursev Sandlas*** declares that he has no conflict of interest.

Ethical approval: All procedures performed in studies involving human participants were in accordance with the ethical standards of the institutional and/or national research committee and with the 1964 Helsinki declaration and its later amendments or comparable ethical standards.

Informed consent:

Detailed written informed consent had been taken from patients, s parents of case No 1, case No 2, and case No 3 for publishing this article with concern not to publish any personal details or names of the patients.

Availability of Data and Materials:

Not many pediatric surgery centers in section of pediatric abdominal trauma using minimal invasive methods for treatment especially in pancreatic trauma.

In literature we found few publications like from the Department of Surgery, Nagoya City University Medical School, Nagoya, Japan which tried that technique with good outcomes.

Authors' contributions;

1-Mohammed Hamada Takrouney: Interpretation, writing, and drafting of manuscript

2-Vipul Prakash Bothara: Data Collection.

3- Ibrahim Ali Ibrahim: Data acquisition

4- Mohamed Abdelkader Osman:Data analysis and collection.

5-Almoutaz Ahmed Eltayeb: Study conception, reviewing the article.

6-Mahmoud Mohamed Mostafa: study conception and design

7- Gursev Sandlas:Conduct of the study, and the main operator of cases.

Acknowledgements:

Not applicable.

References

1. Moore EE, Cogbill TH, Malangoni MA, et al. Organ injury scaling, II: pancreas, duodenum, small bowel, colon, and rectum. *J Trauma*. 1990;30:1427–9.
2. Madiba TE, Mokoena TR. Favorable prognosis after surgical drainage of the gunshot, stab, or blunt trauma of the pancreas.*Br. JSurg*. 1995;82:1236–9.
3. Berni GA, Bandyk DF, Oreskovich MR, Carrico CJ. Role of intra-operative pancreatography in patients with injury to the pancreas. *Am J Surg*. 1982;143:602–5.
4. Jones RC. Management of pancreatic trauma. *Am J Surg*. 1985;150:698–704.
5. Nikfarjam M, Rosen M, Ponsky T. Early management of traumatic pancreatic transection spleen preserving laparoscopic distal pancreatectomy. *J Pediatr Surg*. 2009;44(2):455–8.
6. Leva E, Huscher C, Rode H, Fava G, Napolitano M, Maestri L, Pansini A, et al. Management of traumatic complete pancreatic fracture in a child: case report and review of the literature. *J Laparoendosc Adv Surg Tech A*. 2008;18(2):321–3.
7. Thomas H, Madanur M, Bartlett A, Marangoni G, Heaton N, Rela M. Pancreatic trauma—12-year experience from a tertiary center. *Pancreas*. 2009;38(2):113–6.

Figures

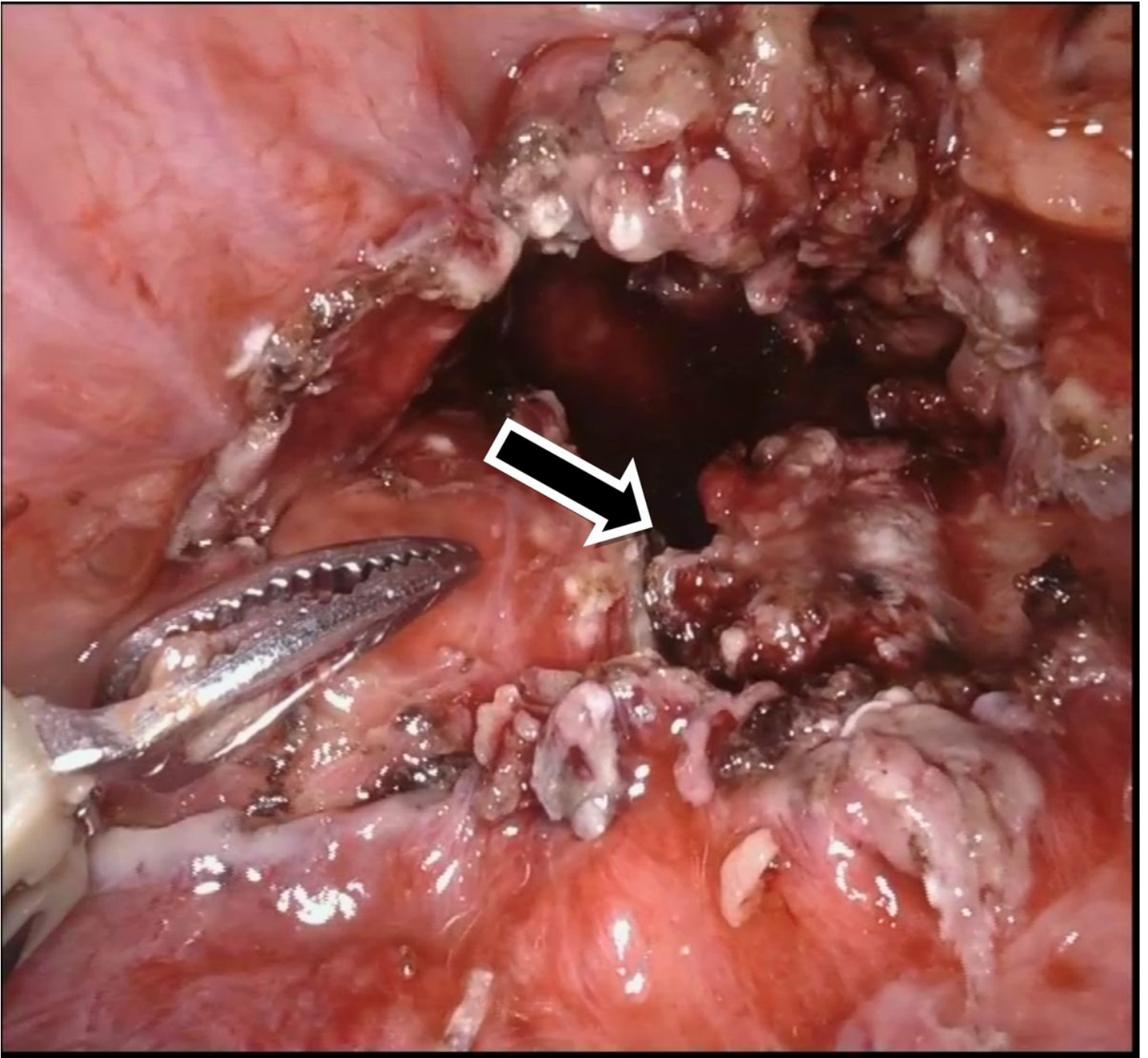


Figure 1

Complete Pancreatic Transection (Arrowed)

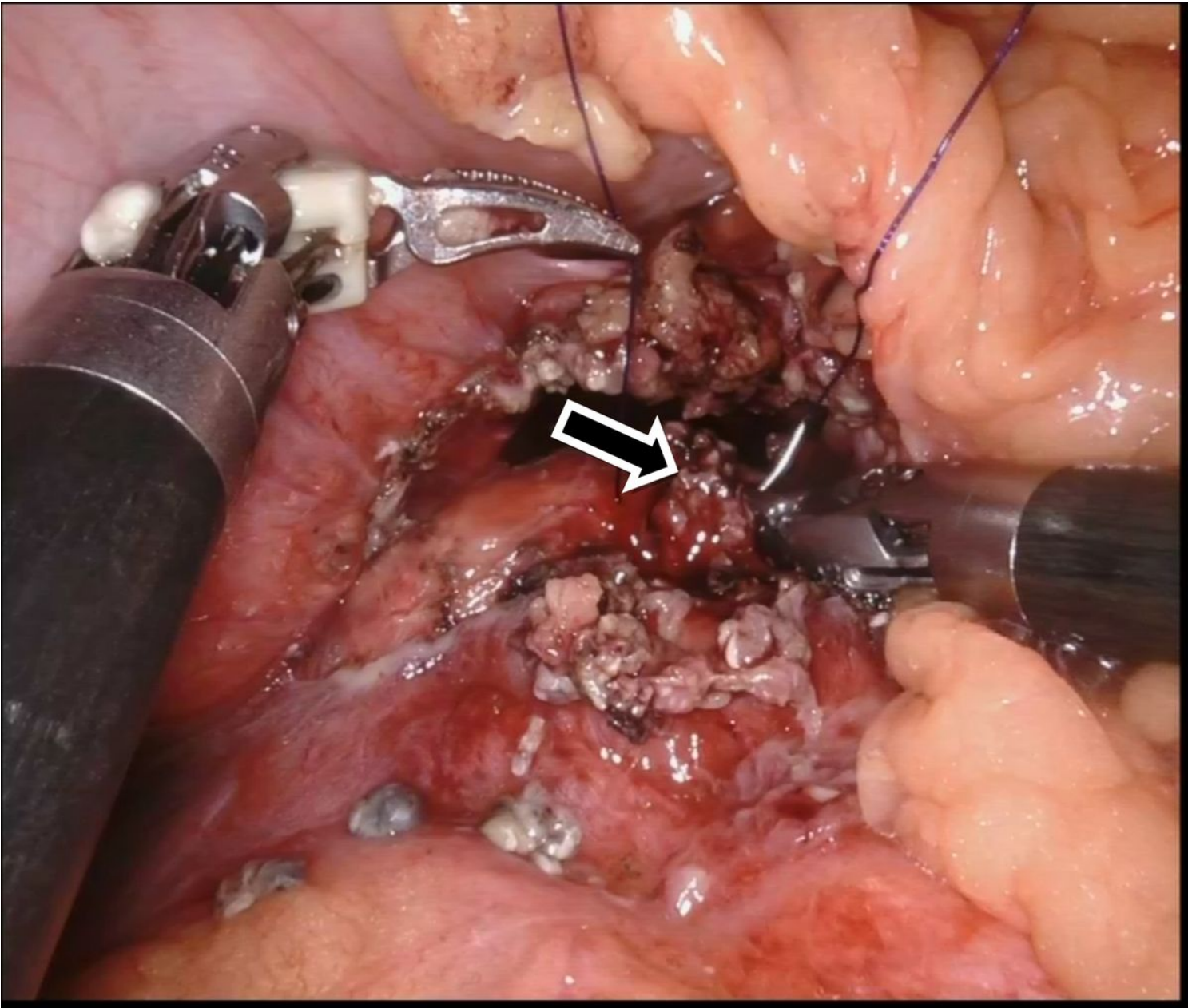


Figure 2

Process of simple Pancreatic Repair Technique (arrowed)

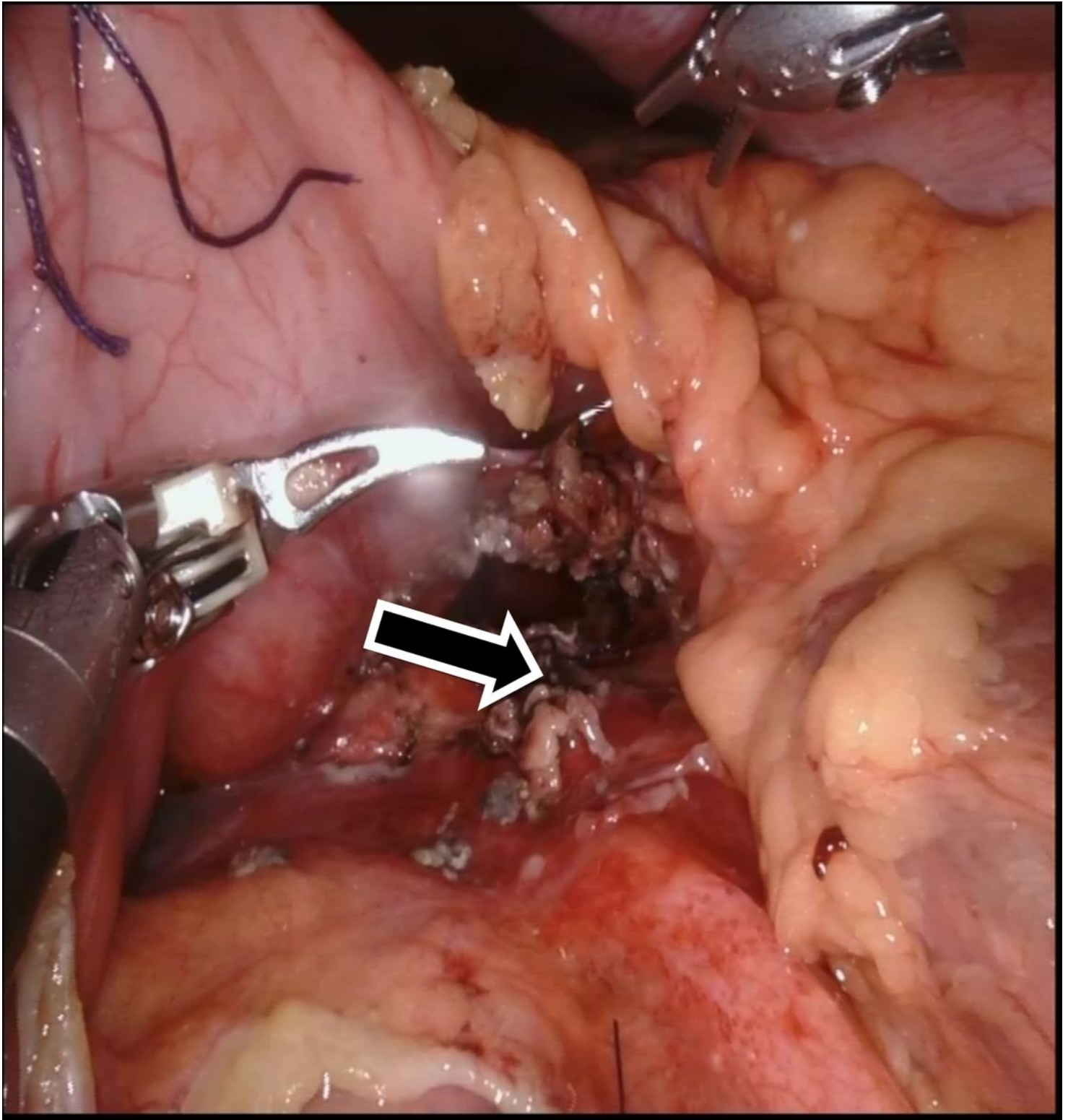


Figure 3

Simple Pancreatic Repair Completed (Arrowed)

Supplementary Files

This is a list of supplementary files associated with this preprint. Click to download.

- [supplement10.docx](#)