

Decrease in the Cortex/striatum Metabolic Ratio on ^{18}F -FDG PET: a Biomarker of Dysimmune Encephalitis

Nicolas De Leiris

CHU Grenoble: Centre Hospitalier Universitaire Grenoble Alpes

Berengere Ruel

AP-HM: Assistance Publique Hopitaux de Marseille

Jean Vervandier

CHU Grenoble: Centre Hospitalier Universitaire Grenoble Alpes

José Boucraut

AP-HM: Assistance Publique Hopitaux de Marseille

Stephan Grimaldi

AP-HM: Assistance Publique Hopitaux de Marseille

Tatiana Horowitz

AP-HM: Assistance Publique Hopitaux de Marseille

Jean Pelletier

AP-HM: Assistance Publique Hopitaux de Marseille

Frederique Fluchere

AP-HM: Assistance Publique Hopitaux de Marseille

Elsa Kaphan

AP-HM: Assistance Publique Hopitaux de Marseille

Eric Guedj (✉ eric.guedj@ap-hm.fr)

CHU Timone <https://orcid.org/0000-0003-1912-6132>

Research Article

Keywords: Encephalitis, ^{18}F -FDG PET/CT, statistical parametric mapping, biomarker, inflammation

Posted Date: March 22nd, 2021

DOI: <https://doi.org/10.21203/rs.3.rs-334802/v1>

License:   This work is licensed under a Creative Commons Attribution 4.0 International License.

[Read Full License](#)

Abstract

Purpose: The aim was to determine the diagnostic value of the cortex/striatum metabolic ratio in ^{18}F -FDG PET in a large cohort of patients suffering from dysimmune encephalitis (DE) and to search for clinical correlations with the course of the disease.

Methods: We retrospectively collected complete clinical and paraclinical data of DE patients, including brain ^{18}F -FDG PET/CT. Whole-brain statistical analysis was performed using SPM8 software after activity parametrization to the striatum and in comparison to healthy subjects. Conventional discriminant analysis between the DE group and controls was performed using cluster metabolic ratios. A correlation analysis between cluster metabolic ratios and clinical/paraclinical data was assessed.

Results: Seventy-three patients with DE were included. In comparison to 44 controls, voxel-based statistical analysis identified one large cluster ($p\text{-voxel} < 0.001$ uncorrected; $p\text{-cluster} < 0.05$, FWE corrected) of widespread decreased cortical metabolism relative to the striatum in DE patients. The mean parametrized cluster metabolic value was significantly lower for DE patients (1.06 ± 0.13) than for the control group (1.46 ± 0.08 ; $p < 0.001$). This cluster metabolic ratio correctly classified 97.4% of the individuals between patients with DE and healthy controls. Correlation analyses showed that a low cluster metabolic ratio was associated with higher risk of death ($p = 0.04$), the absence of autoantibodies ($p = 0.05$), and an increased delay between onset of symptoms and diagnostic ($p = 0.01$).

Conclusion: The decrease in the cortex/striatal metabolic ratio has a good diagnostic performance for the differentiation of DE patients from controls and seems to provide prognostic information on the clinical course.

Introduction

Dysimmune encephalitis (DE) is a rare and complex disease consisting of severe inflammatory brain damage caused by autoantibodies targeting intracellular antigens or cell-surface antigens. DE is clinically characterized by the subacute onset of various unspecific symptoms such as confusion, behavioural changes, psychiatric troubles, short-term memory loss and seizures [1]. Such symptoms may, however, overlap with those of other conditions.

There is a need to identify accurate biomarkers allowing the diagnosis of DE as the early initiation of immunosuppressive treatment is associated with improved outcomes [2–4].

DE diagnosis currently relies on a set of arguments based on clinical symptoms, standard diagnostic tests (brain imaging, cerebrospinal fluid (CSF) analysis) and autoantibody testing. This diagnosis of DE remains challenging because of the polymorphic clinical presentations of the disease and the limitations of usual additional tests [5]. The collection of antibody testing results may be delayed for several weeks, thereby impairing the early initiation of treatment. Moreover, although many antibodies have been increasingly identified as associated with DE, many cases of genuine DE, estimated at approximately

50% [6], remain seronegative without detected antibodies. In addition, the CSF white blood cell count and protein level are within the normal range in up to 20% of patients with DE [7, 8].

Brain magnetic resonance imaging (MRI) is the most widely used imaging modality for DE diagnosis, typically showing T2-FLAIR hyperintensity of medial temporal lobes [9]. However, it has been shown that a significant proportion of patients—for example, 70% of patients with anti-NMDAR antibody encephalitis—have normal or non-specific brain MRI [1].

^{18}F -Fluorodeoxyglucose positron emission tomography/computed tomography (^{18}F -FDG PET/CT) could be a valuable biomarker of suspected DE [10, 11]. While whole-body ^{18}F -FDG PET/CT is often performed to detect occult malignancies [12], brain ^{18}F -FDG PET/CT can also support the diagnosis of DE by providing information on synaptic activity. According to the currently available diagnostic criteria by Graus et al. [5], three levels of evidence exist in the initial diagnosis workup, i.e., possible, probable and definite DE. In this context, the role of ^{18}F -FDG PET/CT is limited to the diagnosis of definite DE through the evidence of bilateral medial temporal hypermetabolism, as an alternative to cerebral MRI, with no contribution of ^{18}F -FDG PET/CT for the definition of possible or probable DE, and, as mentioned, only limbic metabolic anomalies are taken into account. In clinical practice, the Graus criteria seem to lack sensitivity and to be too narrow to allow the diagnosis of all DE whose spectrum no longer relates only to limbic encephalitis [13, 14].

Several studies have nevertheless addressed the role of ^{18}F -FDG PET/CT in the early diagnosis process of suspected DE, with also a recent meta-analysis [15], suggesting that ^{18}F -FDG PET/CT is more sensitive for this purpose than brain MRI [16]. Indeed, hypometabolism or hypermetabolism was observed in patients with normal MRI [17–19], as were extra-limbic abnormalities [16]. These previous studies highlighted distinct ^{18}F -FDG PET/CT patterns in DE patients, including medial temporal and striatal hypermetabolism contrasting with diffuse cortical hypometabolism [20–24]. However, these previous studies included a substantial proportion of case reports [25–31] and were mostly limited to the identification of autoantibodies [21, 32, 33]. Above all, the methodology used for brain PET analysis in this issue is highly heterogeneous and hampered by several considerations: reduced spatial resolution of brain data extracted from whole-body ^{18}F -FDG PET/CT [34, 35], lack of reproducibility of visual interpretation, and absence of standards for semi-quantitative analyses [36–38]; methods for intensity normalization are especially variable. Whereas some authors performed a standardization on global cerebral activity (i.e., proportional scaling) [32, 34, 35], others normalized to a supposedly preserved region of interest, which is always difficult to select in cases of encephalic impairment (for example the pons) [39]; finally, the method used is not specified in some studies [33, 40]. In this context, larger cohort studies of patients suspected of DE are required, along with the standardization of ^{18}F -FDG PET/CT interpretation based on reproducible and efficient biomarkers to clarify the potential role of ^{18}F -FDG PET/CT in the diagnosis of DE [16].

In greater detail, since absolute quantification is inappropriate in this clinical setting, the choice of intensity normalization method appears to be a crucial step for the semi-quantitative analysis, with a potential impact on the sensitivity and specificity of the obtained results. Semi-quantitative analyses have been successfully applied in neurodegenerative disorders such as Alzheimer's disease, where biomarkers correspond to hypometabolism, by proportional scaling or intensity normalization on a preserved reference region such as the cerebellum or the pons. Nevertheless, in patients with abnormally low cerebral glucose metabolic rates, the proportional scaling method has shown limitations, underestimating the extent of hypometabolic areas and falsely identifying 'hypermetabolism' corresponding to brain regions that were best metabolically preserved [41]. As mentioned, intensity normalization is therefore alternatively performed on regions known to be preserved in this disease (e.g., the pons or the sensory-motor cortex) [42, 43]. In the context of DE, this method of normalization cannot be applied because diffuse hypometabolism coexists with regional hypermetabolism. Specifically, few reports have suggested that the increase in the metabolic ratio between the striata and the cortex was a potential biomarker of DE [23]. To overcome the methodological limitation of activity normalization in this population, we thus suggest dividing brain metabolism by those of the striatum to obtain parametric images, assuming that the relative cortical metabolism would be decreased in patients and not in controls.

Therefore, the aim of this study was to determine the diagnostic value of this cortex/striatum ^{18}F -FDG PET/CT metabolic biomarker in a large cohort of patients suffering from DE and to search for clinical/paraclinical correlations with the course of the disease.

Materials And Methods

Study design and patients:

We conducted a single-centre retrospective study at Timone Hospital, Marseille, since 2011. All patients were informed about the registry and gave their consent.

DE cases were identified as those meeting Graus' criteria or as those presenting with a clinical feature consistent with DE albeit not fulfilling Graus' criteria (cancer with unexplained neurological symptomatology or patient with anti-neural or anti-neuropile autoantibody (in the serum or CSF) or an unexplained intrathecal immunoglobulin synthesis or showing a T2-FLAIR hypersignal from the medial temporal lobes). Patients had subacute onset of neurological (anterograde memory disorders, confusion for more than 24 hours, unexplained inaugural seizure, unexplained vigilance disorders, subacute cerebellar syndrome, unexplained dysautonomia or abnormal movements) or psychiatric symptoms (disturbances in behaviour, mood or character, psychosis or hallucinations) with atypia (lack of sensitivity or poor tolerance to psychotropic treatment, occurrence of catatonia, visual hallucinations, presence of associated somatic or neurological symptoms). Because of the known limitations of Graus' criteria [13], a second neurologist blinded to the patients' history performed validation to retain this final diagnosis for patients who did not initially meet Graus' criteria. A complete clinical and paraclinical evaluation,

including a lumbar puncture, an autoantibody test, a brain MRI and a brain ^{18}F -FDG PET/CT, was also required for inclusion. Patients were excluded if an alternative aetiology was identified, such as herpetic encephalitis, Gayet-Wernicke encephalopathy, neurodegenerative disease or focal brain lesion. The data concerning the population (age, sex), associated neoplasia, clinical symptoms, cerebrospinal fluid analysis (cellularity, proteinorrachia, intrathecal immunoglobulin synthesis), autoantibody testing in the serum and CSF, brain MRI, brain ^{18}F -FDG PET/CT, treatments and clinical evolution were collected for all patients using our institution database. In details, on the 89 patients identified on clinical criteria, 3 were excluded because of lack of CSF results, and 13 in absence of ^{18}F -FDG PET/CT. The final cohort included 73 patients. The study was approved by the local ethics committee.

Brain ^{18}F -FDG PET/CT

Dedicated ^{18}F -FDG brain PET scans were acquired at the same centre with an acquisition protocol conforming to European guidelines; the measurements were performed in a resting state after at least 4 hours of fasting with control of normal glycaemic levels. An integrated PET/CT General Electric camera (Waukesha, WI) was used, and ^{18}F -FDG was administered intravenously at 150 MBq per 15 min acquisition, with each acquisition beginning at 30 to 40 min post-injection. The duration of this dedicated brain PET acquisition was proportionally reduced according to the administrated dose in patients having both cerebral then whole-body PET exams during the same procedure (for example 7min30 of acquisition for 300 MBq). Images were reconstructed on a 192×192 matrix using the ordered subset expectation maximization algorithm and corrected for attenuation using a CT transmission scan.

Thereafter, whole-brain statistical analysis was performed at the voxel level using SPM8 software (Wellcome Department of Cognitive Neurology, University College, London, UK). The PET images were spatially normalized to the Montreal Neurological Institute (MNI) atlas. The dimensions of the resulting voxels were $2 \times 2 \times 2$ mm. The images were smoothed with a Gaussian filter (8 mm full width at half-maximum) to blur individual variations in gyral anatomy and to increase the signal-to-noise ratio. As mentioned, the limitations of proportional scaling for the efficient detection of diffuse hypometabolism associated with regional hypermetabolism have thus led to the evaluation of the activity parameterization to the striata in the current study to improve the discrimination of DE patients from controls. This choice was based on the demonstration of a decreased cortex/striatum ratio in previous studies [23] with the hypothesis of a diagnostic value of this gradient. The individual bilateral striatal value was obtained for each subject using the “Anatomical ROIs (regions of interest) Analysis” toolbox of SPM, allowing the automatic extraction of the labelled region mean value from the Anatomical Automatic Labeling (AAL) atlas [44].

This data set was compared to that of healthy subjects from a local database of normal ^{18}F -FDG PET/CT previously acquired under the same technical conditions. This control group included 44 healthy subjects comparable in age and sex to our sample of patients with DE ($p > 0.05$, 24 women (54%), median age 56 years, range 35–78 years). These individuals were free of neurologic and psychiatric disease and had normal brain MRI.

Whole-brain group analysis (two-sample t-test) was performed to evaluate the ^{18}F -FDG PET/CT metabolic patterns in DE patients. The threshold was set at $p_{\text{voxel}} < 0.001$ uncorrected, $p_{\text{cluster}} < 0.05$, FWE (family-wise error) corrected for multiple comparisons at the cluster level. The level of significance was set at 200 contiguous voxels as determined by Monte Carlo simulation. The AAL atlas was used to determine the brain metabolic regions involved.

Statistical analysis

Continuous variables are reported as the means and interquartile ranges (IQRs) or as medians and ranges (min, max), and categorical variables are reported as frequencies and percentages. Differences in mean values were tested with Student's t-test. Conventional discriminant function analysis between the dysimmune encephalitis group and controls was performed using the values of the cluster(s), age and sex. A forward stepwise analysis was performed using Wilks' lambda method and standard F values for an entry of 3.84 and removal of 2.71. The analysis was performed with equal prior probability for any subject to be classified into the two groups. The correlation between cluster metabolic ratio and clinical or paraclinical data was assessed by Pearson's correlation coefficient for quantitative variables and by Student's t-test for binary variables. For these correlation analyses, we hypothesized that a lower metabolic ratio would be associated with a poorer prognosis. The variables associated with the prognosis (evolution under treatment, death) were therefore tested unilaterally, while the other variables were tested bilaterally. A two-sided p-value of < 0.05 was considered to indicate statistical significance.

Results

Patient characteristics

Patients' characteristics are summarized in Table 1. The median age of the population was 60 years (range 14–83). The patients comprised 41 women (56%) and 32 men (44%). According to the existing diagnostic criteria from Graus and colleagues, 40 patients (55%) had definite encephalitis, 5 patients (7%) had probable encephalitis, 14 patients (19%) had possible encephalitis, and 14 patients (19%) did not initially meet Graus' criteria, but the final diagnosis of encephalitis was retained by two local experts.

At the initial stage of the disease, the main symptoms of subacute onset as described by patients were cognitive impairments, including confusion and anterograde amnesia for 47 patients (64%), seizures for 34 patients (47%), atypical psychiatric symptoms for 24 patients (33%) and cerebellar ataxia for 19 patients (26%).

The oncological work-up including whole-body ^{18}F -FDG PET/CT initially identified an underlying tumour in 24 patients (33%). These cancers were located to the lungs of 9 patients (5 adenocarcinoma and 4 small cell lung cancers) and were of gynaecologic origin in 6 patients (3 ovarian, 1 breast, 1 cervical and 1 fallopian tube neoplasm), urologic origin in 3 patients (2 prostatic adenocarcinomas and 1 seminoma) and digestive origin in 2 patients (1 colorectal carcinoma and 1 pancreatic neuroendocrine tumour). We also found 2 lymphomas, a thymoma and a thyroid neoplasia.

Other paraclinical findings

Concerning paraclinical data (Table 1), cerebrospinal fluid analysis was normal in 21 patients (29%), while abnormalities were detected in 52 patients (71%). Among these abnormalities, hyperproteinorrachia was observed in 32 patients (44%), pleocytosis in 22 patients (30%) and intrathecal immunoglobulin synthesis in 32 patients (44%).

Autoantibodies were identified in 37 patients (51%), while 36 patients (49%) had seronegative encephalitis. Of the antibodies detected, 18 targeted intracellular antigens and 19 targeted cell-surface antigens (Table 2). Among the seronegative encephalitis patients, 14 patients had normal CSF analysis results.

On average, brain MRI was performed 8 ± 15 months after the onset of symptoms. Unilateral or bilateral mesial temporal lobe T2 FLAIR hypersignal was observed in 23 patients (32%). Fifty patients (68%) had normal brain MRI or non-specific findings with hypersignal outside the medial temporal lobe.

A total of 12/73 patients (16%) had normal CSF analysis, normal brain MRI and seronegative encephalitis.

Brain ^{18}F -FDG PET/CT and SPM analysis

In comparison to healthy subjects, voxel-based statistical analysis identified a large cluster in patients ($p < 0.05$, FWE corrected), including 59,454 voxels and involving 81 regions of the AAL atlas. Following parameterization to the striatum, this cluster corresponded to a widespread decrease in the cortical ratio in DE patients, predominant in the associative cortices, involving the frontal, parietal, occipital and temporal cortices, as well as in the anterior and posterior cingulate. The preserved regions were the rolandic and temporal limbic regions. No increased metabolic ratio was identified. The brain regions with ^{18}F -FDG metabolic ratio distinct from those of the control group as identified by SPM analysis are summarized in Fig. 1.

Discriminant function analysis

For DE patients, the mean parameterized cluster metabolic ratio was 1.06 ± 0.13 , with a range from 0.55 to 1.39. In the control group, the mean parameterized cluster metabolic ratio was significantly higher, with a mean value of 1.46 ± 0.08 and a range from 1.25 to 1.66 ($p < 0.001$). Only 3/73 (4%) patients in the DE group had a cluster metabolic ratio higher than the lowest value in the control group (1.25) (Fig. 2).

We included the cluster metabolic ratio, age and sex in the discriminant analysis. In the stepwise statistics, cluster metabolic ratio was the only variable entered at the first step with $F = 274.8$, Wilks' $\lambda = 0.295$, $\chi^2 = 139.8$, $P < 0.001$, while the other variables were not retained in the analysis. Only the first

canonical discriminant functions were used in the analysis. This cluster metabolic ratio correctly classified 97.4% of the individuals, with only three DE patients misclassified in the control group (Table 3), corresponding to a sensitivity of 95.9% and a specificity of 100%. These three misclassified patients presented abnormalities in the CSF analysis and identified autoantibodies, and had therefore defined encephalitis according to the currently used criteria. In contrast, all DE patients with a negative standard paraclinical evaluation (12/73 patients) had a lower cluster metabolic ratio compared to controls.

Correlations between cluster metabolic ratio and clinical/paraclinical data

Correlation analyses of the cluster metabolic ratio with clinical and paraclinical data showed that a low cluster metabolic ratio was associated with higher risk of death ($p = 0.04$; one-tailed t-test), the absence of autoantibodies in the serum or the CSF ($p = 0.05$; two-tailed t-test) and a longer delay between the onset of symptoms and diagnostic ($p = 0.01$; Pearson correlation test). Crossing the presence of autoantibodies with the presence or absence of intrathecal immunoglobulin synthesis did not increase the significance. Moreover, no correlation was observed between the ratio and either the presence of intrathecal immunoglobulin synthesis or a suspected humoral or cellular pathophysiology of encephalitis deduced from the types of antibodies (membranous or intracellular). No significant association was finally found with clinical symptoms, MRI results or clinical course under treatment ($p > 0.05$) (Table 4).

Discussion

This brain ^{18}F -FDG PET/CT voxel-based analysis demonstrates a large and predominantly associative cortical decreased metabolism compared to the striata in patients with DE in comparison with healthy subjects. This decrease in the metabolic ratio between the cortex and the striata accurately identifies patients, and could be used as a biomarker of DE.

In the present study, we retrospectively evaluated a cohort of 73 patients with a diagnosis of DE regardless of their autoantibody status who underwent a complete clinical and paraclinical evaluation including ^{18}F -FDG PET/CT. To our knowledge, this is the largest study evaluating the cerebral metabolic profile using ^{18}F -FDG PET/CT in this setting.

DE is a relatively rare but serious disease with the potential to cause disability. Since immunosuppressive therapeutics have been shown to have a major impact on prognosis, the early diagnosis of DE is essential. However, it is consensually acknowledged that such a diagnosis remains problematic since it is often missed or delayed in patients with heterogeneous and unspecific clinical presentations. Furthermore, standard additional tests may be within normal limits in a significant proportion of patients. Accordingly, in our population of 73 patients with a validated diagnosis of DE, the analysis of cerebrospinal fluid was normal in 21 patients (29%). Similarly, in a recently published study evaluating

the prevalence of CSF markers associated with inflammation in patients with active DE, Hebert et al. [7] identified 26/95 (27%) patients with white blood cell counts and protein levels within normal limits, comparable to the values found in our study. Likewise, brain MRI showed a mesial temporal lobe T2-FLAIR hypersignal in only 23 of our patients (32%) as well as some non-specific findings. The suboptimal sensitivity of brain MRI has been described in several studies [36, 45]. Probasco et al. [24] found only 23 MRIs (40%) consistent with the diagnosis of DE in a retrospective study including 57 dysimmune encephalitis patients evaluated by brain MRI. A meta-analysis by these same authors identified 68/114 (60%) patients for whom MRI was supposedly consistent with DE without describing the image abnormalities justifying such a diagnosis. The rather variable delay before MRI, which can extend up to several years following symptom onset, may have contributed to the decrease in sensitivity. Finally, seronegative DE constitutes a major diagnostic issue, estimated at approximately 50% of cases [6] and comparable to what is observed in our population (36/73 patients with seronegative DE). Thus, the identification of a sensitive biomarker would be relevant in establishing the diagnosis of DE.

The role of brain ^{18}F -FDG PET/CT in the currently used diagnostic criteria [5] is restricted because it represents an alternative to brain MRI for the diagnosis of definite encephalitis only, and because it is limited to the demonstration of temporal lobe hypermetabolism. Graus and colleagues underlined two major drawbacks for the use of brain ^{18}F -FDG PET/CT, namely, the lack of large studies with homogeneous patient cohorts and the lack of image standardization using more objective semi-quantitative measures.

Recent studies [39, 46] have shown a significant diagnostic contribution of semi-quantification in comparison to visual analysis alone in this context, leading to more comparable and accurate results. For example, Lv et al. identified striatal hypermetabolism upon semi-quantitative analysis in 73% of patients who did not present with a visual metabolic striatal abnormality. Indeed, visual analysis is a subjective process that depends on the physician's experience, and has limitations in evaluating hypermetabolism. Visual analysis requires auto-windowing of the image according to a reference region with the greatest ^{18}F -FDG uptake (e.g., the striatum). This point may partly account for the great heterogeneity of the metabolic profiles described in the literature [20, 24, 36], since most of these descriptions were based on qualitative analysis in which some hypometabolism probably corresponded to a relative decrease in cortical metabolism in comparison with the striatum or limbic hypermetabolism.

Result heterogeneity was also observed among studies that investigated DE by means of a semi-quantitative analysis. Such heterogeneity may be explained by methodologies not suited for the combined detection of hypometabolism and hypermetabolism in DE patients. More precisely, some investigators have carried out their analysis following proportional scaling [32, 34, 35], while others have used intensity normalization on a region of interest [39]. However, it is now acknowledged that the intensity normalization method could lead to poor detection of hypometabolic areas or to the artefactual identification of hypermetabolism in the best-preserved areas, as demonstrated in the field of dementia.

Based on 3 cases of dysimmune encephalitis with anti-VGKC antibodies, Rey et al. [23] detected a common ^{18}F -FDG PET/CT pattern of relative striatal hypermetabolism contrasting with diffuse cortical hypometabolism. Moloney et al. [28] also performed qualitative and semi-quantitative analysis of brain ^{18}F -FDG PET/CT in one patient over the course of the symptomatic phase of VGKC encephalitis. They identified an increase in the metabolic gradient between the striatum and cortex in semi-quantitative analysis and hypothesized that such a pattern may be specific for encephalitis, at least in the setting of VGKC encephalitis. In a cohort of 24 patients with anti-NMDAR, anti-GAD and anti-VGKC encephalitis, Tripathi et al. [47] identified heterogeneous metabolic profiles, with more often cortical parieto-occipital hypometabolism and striatal hypermetabolism, on semi-quantitative analysis.

In our study, we hypothesized that the metabolic gradient between striata and the cortex may have diagnostic value in DE. Therefore, we parameterized the intensity of all ^{18}F -FDG PET/CT images on striatal activity. In comparison with a set of healthy control subjects, voxel-based statistical analysis identified a widespread cortical decreased metabolism compared to the striata, predominant on the associative cortex and essentially preserving the rolandic and temporal limbic regions. This aspect confirms a decrease in the metabolic gradient between the cortex and the striata in patients with DE, regardless of the type of antibody.

The ratio of cluster to striatal metabolic values (cluster metabolic ratio) was significantly lower in patients with DE than in controls. The cluster metabolic ratio effectively classified 97.4% of patients and controls in the discriminant analysis, with only three patients misclassified due to a ratio comparable to that of controls. All DE patients (12/73) with a negative standard paraclinical evaluation had a lowered cluster metabolic ratio. This metabolic gradient was more frequently affected than other paraclinical parameters evaluated. ^{18}F -FDG PET/CT with semi-quantitative analysis therefore appears to be an effective biomarker in DE.

A lower cluster metabolic ratio was significantly correlated with longer-established disease as evidenced by the link with a longer delay between the onset of symptoms and the diagnostic. This association is consistent with previous studies in which the authors visually described cortical hypometabolism in advanced encephalitis [17]. Similarly, the link with the absence of identification of antibodies could also involve delayed management, and worse prognosis. In this line, this cluster metabolic ratio also was associated with a higher risk of death.

Beyond its diagnostic role, brain ^{18}F -FDG PET/CT likely has the potential for the assessment of therapeutic responses associated with an improvement in the cortex/striatum ratio [22, 23, 34] and for the identification of recurrence [40]. Further studies are required to elucidate the potential of ^{18}F -FDG PET/CT for these indications.

There are several limitations to the present study. First, this is a single-centre retrospective study performed in a tertiary referral hospital, and there is a risk of selection bias. A significant difference in disease duration prior to ^{18}F -FDG PET/CT was noted, and some patients were evaluated years after the

onset of symptoms. The observed metabolic patterns are probably variable depending on the stages of the disease. However, this variable mirrors clinical practice with a diagnosis that remains difficult and sometimes delayed.

Future prospective studies are now warranted to confirm the diagnostic performance of the decreased cortex/striatum metabolic ratio in DE patients. The currently used Graus criteria lack sensitivity, and this justifies the development of new diagnostic criteria integrating ^{18}F -FDG PET/CT.

Conclusion

This voxel-based study performed on a large cohort of DE allowed us to identify a diffuse decrease in cortical vs striatal metabolism. This ratio demonstrated good diagnostic performance for the differentiation of encephalitis patients from control subjects and seemed to provide prognostic information on the clinical course. Brain ^{18}F -FDG PET/CT with semi-quantitative analysis of the cortex/striatum ratio provides an effective biomarker that should be used in the diagnosis of DE in addition to the visual interpretation.

Declarations

Funding

The local PET database of healthy controls was funded by APMH (regional PHRC; NCT00484523)

Conflicts of interest/Competing interests

The authors declare that they have no conflicts of interest

Ethics approval

The retrospective observations required no ethical approval requirement other than informed consent.

The local PET database of healthy controls was acquired in accordance with the Declaration of Helsinki, with informed written consent from the patients and approval from the “CPP Sud Méditerranée V” ethics committee.

Consent to participate

Informed written consent was obtained from all individual participants included in the study

Consent for publication

Informed written consent was obtained from all individual participants included in the study

Availability of data and material

The PET data that support the findings are available from the corresponding author upon reasonable request

Code availability

Not applicable

References

1. Dalmau J, Graus F. Antibody-Mediated Encephalitis. *N Engl J Med*. 2018;378:840–51.
2. Titulaer MJ, McCracken L, Gabilondo I, Armangué T, Glaser C, Iizuka T, et al. Treatment and prognostic factors for long-term outcome in patients with anti-NMDA receptor encephalitis: an observational cohort study. *Lancet Neurol*. 2013;12:157–65.
3. Balu R, McCracken L, Lancaster E, Graus F, Dalmau J, Titulaer MJ. A score that predicts 1-year functional status in patients with anti-NMDA receptor encephalitis. *Neurology*. 2019;92:e244–52.
4. Hébert J, Day GS, Steriade C, Wennberg RA, Tang-Wai DF. Long-Term Cognitive Outcomes in Patients with Autoimmune Encephalitis. *Can J Neurol Sci*. 2018;45:540–4.
5. Graus F, Titulaer MJ, Balu R, Benseler S, Bien CG, Cellucci T, et al. A clinical approach to diagnosis of autoimmune encephalitis. *Lancet Neurol*. 2016;15:391–404.
6. Ducray F, Demarquay G, Graus F, Decullier E, Antoine J-C, Giometto B, et al. Seronegative paraneoplastic cerebellar degeneration: the PNS Euronetwork experience. *Eur J Neurol*. 2014;21:731–5.
7. Hébert J, Gros P, Lapointe S, Amtashar FS, Steriade C, Maurice C, et al. Searching for autoimmune encephalitis: Beware of normal CSF. *J Neuroimmunol*. 2020;345:577285.
8. Dubey D, Pittock SJ, Kelly CR, McKeon A, Lopez-Chiriboga AS, Lennon VA, et al. Autoimmune encephalitis epidemiology and a comparison to infectious encephalitis. *Ann Neurol*. 2018;83:166–77.
9. Gultekin SH, Rosenfeld MR, Voltz R, Eichen J, Posner JB, Dalmau J. Paraneoplastic limbic encephalitis: neurological symptoms, immunological findings and tumour association in 50 patients. *Brain*. 2000;123 (Pt 7):1481–94.
10. Ances BM, Vitaliani R, Taylor RA, Liebeskind DS, Voloschin A, Houghton DJ, et al. Treatment-responsive limbic encephalitis identified by neuropil antibodies: MRI and PET correlates. *Brain*. 2005;128:1764–77.

11. Morbelli S, Djekidel M, Hesse S, Pagani M, Barthel H, Neuroimaging Committee of the European Association of Nuclear Medicine (EANM), et al. Role of (18)F-FDG-PET imaging in the diagnosis of autoimmune encephalitis. *Lancet Neurol.* 2016;15:1009–10.
12. Sheikhabaei S, Marcus CV, Fragomeni RS, Rowe SP, Javadi MS, Solnes LB. Whole-Body 18F-FDG PET and 18F-FDG PET/CT in Patients with Suspected Paraneoplastic Syndrome: A Systematic Review and Meta-Analysis of Diagnostic Accuracy. *J Nucl Med.* 2017;58:1031–6.
13. Wagner JN, Kalev O, Sonnberger M, Krehan I, von Oertzen TJ. Evaluation of Clinical and Paraclinical Findings for the Differential Diagnosis of Autoimmune and Infectious Encephalitis. *Front Neurol.* 2018;9:434.
14. Li L, Sun L, Du R, Zheng Y, Dai F, Ma Q, et al. Application of the 2016 diagnostic approach for autoimmune encephalitis from Lancet Neurology to Chinese patients. *BMC Neurol.* 2017;17:195.
15. Bordonne M, Chawki MB, Doyen M, Kas A, Guedj E, Tyvaert L, et al. Brain 18F-FDG PET for the diagnosis of autoimmune encephalitis: a systematic review and a meta-analysis. *Eur J Nucl Med Mol Imaging* [Internet]. 2021 [cited 2021 Mar 8]; Available from: <https://doi.org/10.1007/s00259-021-05299-y>
16. Morbelli S, Arbizu J, Booij J, Chen M-K, Chetelat G, Cross DJ, et al. The need of standardization and of large clinical studies in an emerging indication of [18F]FDG PET: the autoimmune encephalitis. *Eur J Nucl Med Mol Imaging.* 2017;44:353–7.
17. Cistaro A, Caobelli F, Quartuccio N, Fania P, Pagani M. Uncommon 18F-FDG-PET/CT findings in patients affected by limbic encephalitis: hyper-hypometabolic pattern with double antibody positivity and migrating foci of hypermetabolism. *Clin Imaging.* 2015;39:329–33.
18. Turpin S, Martineau P, Levasseur M-A, Meijer I, Décarie J-C, Barsalou J, et al. 18F-Fluorodeoxyglucose positron emission tomography with computed tomography (FDG PET/CT) findings in children with encephalitis and comparison to conventional imaging. *Eur J Nucl Med Mol Imaging.* 2019;46:1309–24.
19. Fisher RE, Patel NR, Lai EC, Schulz PE. Two different 18F-FDG brain PET metabolic patterns in autoimmune limbic encephalitis. *Clin Nucl Med.* 2012;37:e213-218.
20. Quartuccio N, Caobelli F, Evangelista L, Alongi P, Kirienko M, De Biasi V, et al. The role of PET/CT in the evaluation of patients affected by limbic encephalitis: A systematic review of the literature. *J Neuroimmunol.* 2015;284:44–8.
21. Probasco JC, Solnes L, Nalluri A, Cohen J, Jones KM, Zan E, et al. Decreased occipital lobe metabolism by FDG-PET/CT: An anti-NMDA receptor encephalitis biomarker. *Neurol Neuroimmunol Neuroinflamm.* 2018;5:e413.
22. Wei Y-C, Tseng J-R, Wu C-L, Su F-C, Weng W-C, Hsu C-C, et al. Different FDG-PET metabolic patterns of anti-AMPA and anti-NMDAR encephalitis: Case report and literature review. *Brain Behav.* 2020;10:e01540.
23. Rey C, Koric L, Guedj E, Felician O, Kaphan E, Boucraut J, et al. Striatal hypermetabolism in limbic encephalitis. *J Neurol.* 2012;259:1106–10.

24. Probasco JC, Solnes L, Nalluri A, Cohen J, Jones KM, Zan E, et al. Abnormal brain metabolism on FDG-PET/CT is a common early finding in autoimmune encephalitis. *Neurol Neuroimmunol Neuroinflamm.* 2017;4:e352.
25. Castagnoli H, Manni C, Marchesani F, Rossi G, Fattori S, Capocchetti F. The role of 18F-FDG PET/CT in management of paraneoplastic limbic encephalitis combined with small cell lung cancer: A case report. *Medicine (Baltimore).* 2019;98:e16593.
26. Cózar Santiago MDP, Sanchez Jurado R, Sanz Llorens R, Aguilar Barrios JE, Ferrer Rebolleda J. Limbic Encephalitis Diagnosed With 18F-FDG PET/CT. *Clin Nucl Med.* 2016;41:e101-103.
27. Maffione AM, Chondrogiannis S, Ferretti A, Al-Nahhas A, Rubello D. Correlative imaging with (18)F-FDG PET/CT and MRI in paraneoplastic limbic encephalitis. *Clin Nucl Med.* 2013;38:463–4.
28. Moloney P, Boylan R, Elamin M, O’Riordan S, Killeen R, McGuigan C. Semi-quantitative analysis of cerebral FDG-PET reveals striatal hypermetabolism and normal cortical metabolism in a case of VGKCC limbic encephalitis. *Neuroradiol J.* 2017;30:160–3.
29. Moubtakir A, Dejust S, Godard F, Messaoud L, Morland D. 18F-FDG PET/CT in Anti-NMDA Receptor Encephalitis: Typical Pattern and Follow-up. *Clin Nucl Med.* 2018;43:520–1.
30. Scheid R, Lincke T, Voltz R, von Cramon DY, Sabri O. Serial 18F-fluoro-2-deoxy-D-glucose positron emission tomography and magnetic resonance imaging of paraneoplastic limbic encephalitis. *Arch Neurol.* 2004;61:1785–9.
31. Gaeta MC, Godani M, Nunziata R, Capellini C, Ciarmiello A. Early detection of encephalitis with (18)F-FDG PET/CT. *Rev Esp Med Nucl Imagen Mol.* 2015;34:188–90.
32. Liu X, Shan W, Zhao X, Ren J, Ren G, Chen C, et al. The Clinical Value of 18 F-FDG-PET in Autoimmune Encephalitis Associated With LGI1 Antibody. *Front Neurol.* 2020;11:418.
33. Dodich A, Cerami C, Iannaccone S, Marcone A, Alongi P, Crespi C, et al. Neuropsychological and FDG-PET profiles in VGKC autoimmune limbic encephalitis. *Brain Cogn.* 2016;108:81–7.
34. Leypoldt F, Buchert R, Kleiter I, Marienhagen J, Gelderblom M, Magnus T, et al. Fluorodeoxyglucose positron emission tomography in anti-N-methyl-D-aspartate receptor encephalitis: distinct pattern of disease. *J Neurol Neurosurg Psychiatry.* 2012;83:681–6.
35. Wegner F, Wilke F, Raab P, Tayeb SB, Boeck A-L, Haense C, et al. Anti-leucine rich glioma inactivated 1 protein and anti-N-methyl-D-aspartate receptor encephalitis show distinct patterns of brain glucose metabolism in 18F-fluoro-2-deoxy-d-glucose positron emission tomography. *BMC Neurol.* 2014;14:136.
36. Baumgartner A, Rauer S, Mader I, Meyer PT. Cerebral FDG-PET and MRI findings in autoimmune limbic encephalitis: correlation with autoantibody types. *J Neurol.* 2013;260:2744–53.
37. Lee BY, Newberg AB, Liebeskind DS, Kung J, Alavi A. FDG-PET findings in patients with suspected encephalitis. *Clin Nucl Med.* 2004;29:620–5.
38. Masangkay N, Basu S, Moghbel M, Kwee T, Alavi A. Brain 18F-FDG-PET characteristics in patients with paraneoplastic neurological syndrome and its correlation with clinical and MRI findings. *Nucl Med Commun.* 2014;35:1038–46.

39. Moreno-Ajona D, Prieto E, Grisanti F, Esparragosa I, Sánchez Orduz L, Gállego Pérez-Larraya J, et al. 18F-FDG-PET Imaging Patterns in Autoimmune Encephalitis: Impact of Image Analysis on the Results. *Diagnostics (Basel)*. 2020;10.
40. Novy J, Allenbach G, Bien CG, Guedj E, Prior JO, Rossetti AO. FDG-PET hyperactivity pattern in anti-NMDAr encephalitis. *J Neuroimmunol*. 2016;297:156–8.
41. Yakushev I, Landvogt C, Buchholz H-G, Fellgiebel A, Hammers A, Scheurich A, et al. Choice of reference area in studies of Alzheimer's disease using positron emission tomography with fluorodeoxyglucose-F18. *Psychiatry Res*. 2008;164:143–53.
42. Yakushev I, Hammers A, Fellgiebel A, Schmidtman I, Scheurich A, Buchholz H-G, et al. SPM-based count normalization provides excellent discrimination of mild Alzheimer's disease and amnesic mild cognitive impairment from healthy aging. *Neuroimage*. 2009;44:43–50.
43. Nugent S, Croteau E, Potvin O, Castellano C-A, Dieumegarde L, Cunnane SC, et al. Selection of the optimal intensity normalization region for FDG-PET studies of normal aging and Alzheimer's disease. *Sci Rep*. 2020;10:9261.
44. Tzourio-Mazoyer N, Landeau B, Papathanassiou D, Crivello F, Etard O, Delcroix N, et al. Automated anatomical labeling of activations in SPM using a macroscopic anatomical parcellation of the MNI MRI single-subject brain. *Neuroimage*. 2002;15:273–89.
45. Solnes LB, Jones KM, Rowe SP, Pattanayak P, Nalluri A, Venkatesan A, et al. Diagnostic Value of 18F-FDG PET/CT Versus MRI in the Setting of Antibody-Specific Autoimmune Encephalitis. *J Nucl Med*. 2017;58:1307–13.
46. Lv R-J, Pan J, Zhou G, Wang Q, Shao X-Q, Zhao X-B, et al. Semi-quantitative FDG-PET Analysis Increases the Sensitivity Compared With Visual Analysis in the Diagnosis of Autoimmune Encephalitis. *Front Neurol*. 2019;10:576.
47. Tripathi M, Tripathi M, Roy SG, Parida GK, Ihtisham K, Dash D, et al. Metabolic topography of autoimmune non-paraneoplastic encephalitis. *Neuroradiology*. 2018;60:189–98.

Tables

Table 1

Clinical and paraclinical characteristics of patients with dysimmune encephalitis

Characteristics	Values
N	73
Age, years, median (range)	60 (14-83)
Sex, female, n (%)	41 (56)
Level of evidence for dysimmune encephalitis, n (%)	
Unclassifiable	14 (19)
Possible	14 (19)
Probable	5 (7)
Definite	40 (55)
Clinical symptoms, n (%)	
Seizures	34 (47)
Cognitive disorders, confusion, amnesia	47 (64)
Psychiatric symptoms	24 (33)
Cerebellar ataxia	19 (26)
Cancer, n (%)	24 (33)
CSF abnormalities, n (%)	
Hyperproteinorrhachia (≥ 0.5 g/L)	32 (44)
Pleocytosis	22 (30)
Intrathecal Ig synthesis	32 (44)
Normal CSF	21 (29)
Autoantibodies, n (%)	
Positive	37 (51)
Negative	36 (49)
Brain MRI findings, n (%)	
Temporal T2 hypersignal	23 (32)
Normal or non-specific MRI	50 (68)
Treatment response, n (%)	

Full response	26 (35)
Partial response	19 (26)
No response	21 (29)
Not evaluable	7 (10)
Death, n (%)	12 (16)

Abbreviations: CSF: cerebrospinal fluid; Ig: immunoglobulin; MRI: magnetic resonance imaging.

Table 2

Antibody status of patients with dysimmune encephalitis

Autoantibodies, n (%)	
Against intracellular antigens (total)	18 (25)
YO	4 (5.5)
GAD	7 (10)
Ma2	2 (3)
SOX1	4 (5.5)
Hu	1 (1)
Against cell-surface antigens (total)	19 (26)
CASPR2	4 (5.5)
LGI1	2 (3)
VGKC	5 (6.5)
NMDAR	8 (11)
Seronegative DE	36 (49)
Total	73 (100)

Abbreviations: GAD: glutamic acid decarboxylase; CASPR2: contactin-associated protein-like 2; LGI1: leucine-rich glioma inactivated 1; NMDAR: N-methyl-D-aspartate receptor; VGKC: voltage-gated potassium channel-complex; DE: dysimmune encephalitis.

Table 3

Classification of dysimmune encephalitis patients and controls based on PET cluster metabolic ratios

	Dysimmune encephalitis	Controls	Total
Dysimmune encephalitis	70 (95.9)	3 (4.1)	73
Controls	0 (0)	44 (100)	44

A total of 97.4% of the original observations were correctly classified.

The numbers and percentages are expressed in relation to the total number of patients in each class of the cohort.

Table 4

Correlations between PET cluster metabolic ratio and clinical/paraclinical data

N (%)	Coefficients	P value
Sex (female)	0.397	0.69
Cancer	-1.136	0.26
Seizures	-0.347	0.73
Cognitive disorders, confusion, amnesia	0.107	0.92
Psychiatric symptoms	-1.280	0.21
Cerebellar ataxia	1.120	0.27
Pleocytosis	0.859	0.39
Hyperproteinorrhachia	0.034	0.97
Detected autoantibodies	1.976	0.05
MRI profile of encephalitis	-0.292	0.77
Delay between symptoms onset and diagnostic	-0.295	0.01
Full response	0.553	0.29
No clinical benefit	0.241	0.60
Death	-1.737	0.04

The correlation between PET cluster metabolic ratio and the delay between symptoms onset and diagnostic was assessed using Pearson's correlation coefficient. The correlations with the other clinical or paraclinical data were assessed by Student's t-test (unilateral t-test for the variables of full response, no clinical benefit and death, and bilateral t-test for the other variables).

Figures

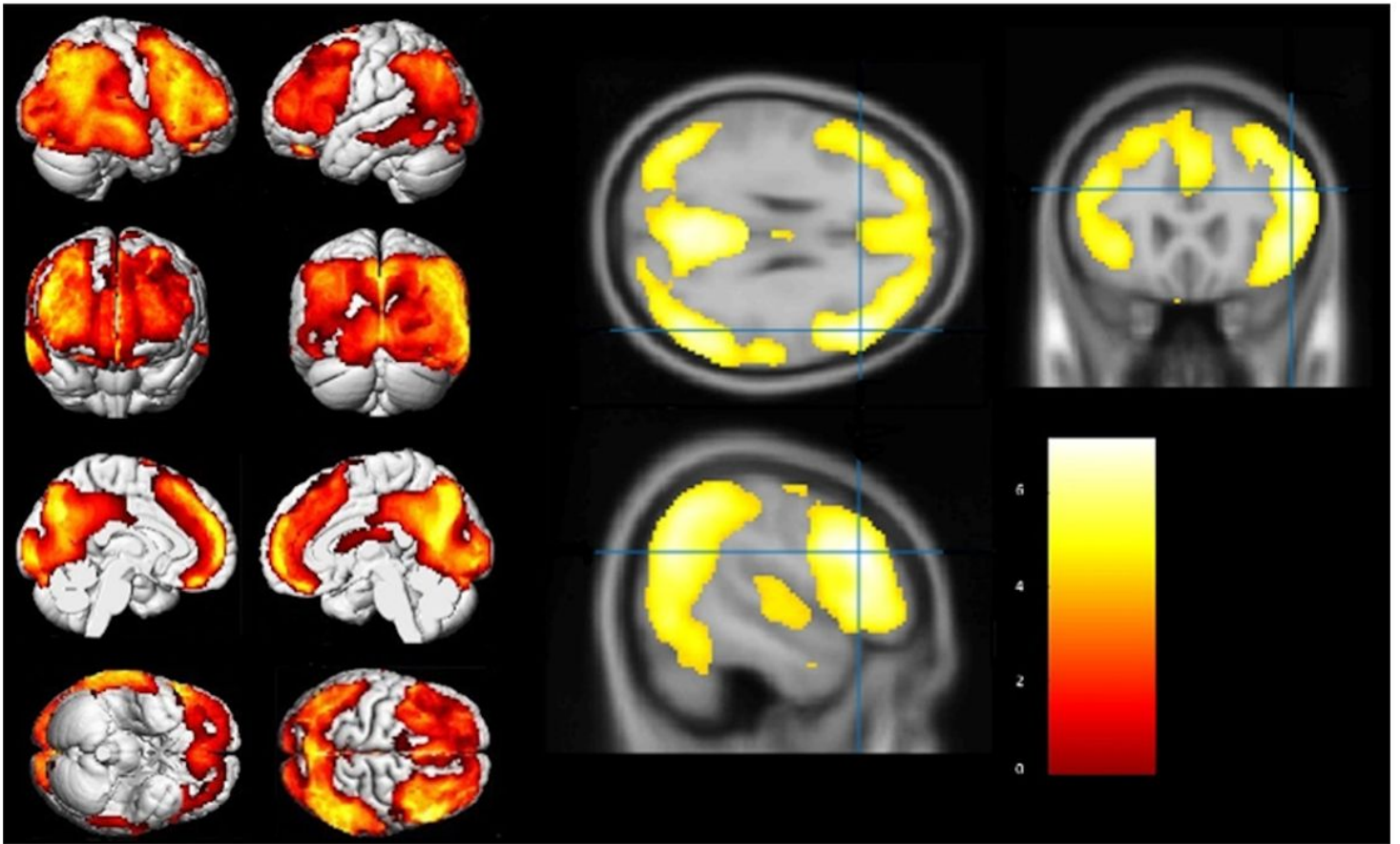


Figure 1

The brain regions with 18F-FDG metabolic radio distinct from those of the control group as identified by SPM analysis

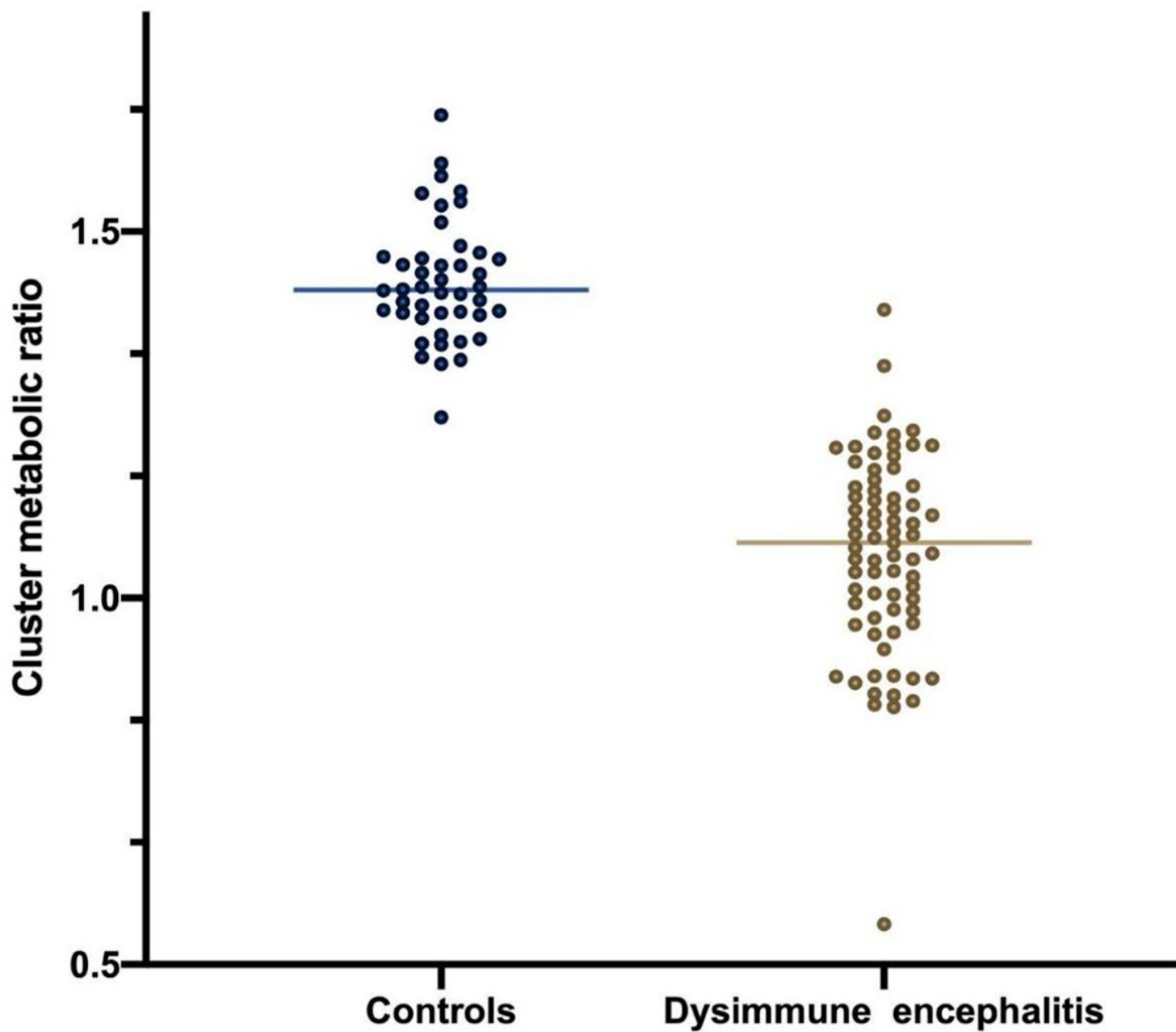


Figure 2

Patients in the DE group had a cluster metabolic ratio higher than the lowest value in the control group